



Research Brief

Safety and efficacy of larger ASD devices in small children of less than 2 years



M. Kalyanasundaram

Institution: G.K.N.M.Hospital, Coimbatore, India

ARTICLE INFO

Article history:

Received 9 August 2020

Received in revised form

16 June 2021

Accepted 13 July 2021

Available online 20 July 2021

Indexing words:

Larger device in small children

ASD device in less than two years

Early ASD closure

Amplatzer ASD device

Keywords:

Atrial septal defects

Large ASD

Small children

ABSTRACT

We herein report our single center experience of safety and efficacy of device closure of large sized ostium secundum atrial septal defects (OS ASD) in small children with less than 2 years of age performed over the period of 10 years from 2009 to 2019. 148 symptomatic children with ASD size of more than 8 mm were included in our study. We obtained a high rate of successful deployment (98 %) with no major complications.

© 2021 Cardiological Society of India. Published by Elsevier B.V. This is an open access article under the CC BY-NC-ND license (<http://creativecommons.org/licenses/by-nc-nd/4.0/>).

1. Introduction

Atrial septal defect (ASD) is a common congenital heart disease (CHD) which accounts for 8–10 % of all CHD and is considered to be the most common type of CHD in adults. Among various types of ASD, the ostium secundum defect exceeds other types in prevalence and is a good candidate for device closure. The therapeutic strategy for secundum ASD has shown a remarkable change in the last decade because of the evolution of device technology, and currently transcatheter closure has become the primary treatment option for most patients in many centers. The reported outcomes of transcatheter ASD closure have been excellent with low complication rates. On the other hand, this “usually straightforward” procedure has several influencing factors that play a role in the procedural outcomes, such as morphologic characteristics of the defect, as well as individual factors including age and weight of the patient. Because the risk-benefit in the very young patients has not been clearly defined yet, closure of an ASD with device may be potentially subtracted from the treatment option in this patient group.

2. Methods

This is a single center, retrospective study of 10 years duration (2009–2019) involving 148 children (Female 89 and male 59) with age ranged from 7½ months to 2 years (median age 1 year 8 months) and the weight ranged from 5.5 to 14 kg (median weight 9 kg). The children included in this study were symptomatic (Recurrent RTI, poor weight gain) with ASD size of more than 8 mm and adequate atrial septal rims (rim length more than 5 mm). All these children underwent the procedure with standard protocol of 6 h fasting and prophylactic IV antibiotic (Cefazolin of 50 mg/kg, subject to maximum of 1 g) administered 5 min before start of the procedure. All the procedures were done with written consent from the parents of the children.

The procedure was done in most of our cases under general anesthesia with endotracheal intubation and in some cases with IV sedation only. We used Amplatzer septal occluder (AGA Medical Corporation, Plymouth, MN), Life tech ASD device (Lifetech Scientific Co. Ltd. Shenzhen, China) and Cocoon ASD device (Vascular Innovations co Ltd, Thailand) and Amplatzer delivery system, in all our cases. Procedure was done through femoral venous access and deployment of the device was done either from left or right upper pulmonary venous approach. We used transesophageal

E-mail address: kalyanocardio@yahoo.com.

echocardiography (TEE), transthoracic echocardiography (TTE) and fluoroscopic guidance to deploy the device. We did not use balloon or catheter assisted technique to deploy the device in any of our cases.

3. Result

Out of 148 children taken up for the device closure of ASD, 3 children did not undergo the procedure due to failure in positioning the device and they were sent for surgical closure. All patients who had successful deployment showed immediate total occlusion of the defect. During the procedure none experienced major complications like severe haemodynamic instability and device embolization. But eight patients (5.5%) developed minor complications which include six patients developing multiple premature atrial complexes and two patients developed atrial bigeminy during the procedure. But all these atrial arrhythmias subsided within 12 h of the procedure. None of our patients developed atrioventricular conduction abnormalities. The size of the devices used in our study population ranged from 10 mm to 24 mm with median size of 16 mm and the device size/body weight ratio ranged from 0.8 to 2.8 (mean 1.7). During the procedure we had to upsize the device in 8 patients and downsize the device in 5 patients from the original estimated size due to size mismatch noticed on fluoroscopy. This inappropriate selection of devices was probably due to difficulty in identifying the thin and pliable atrial septal rims by echocardiography. Out of 145 patients, 57 patients received 10 mm–14 mm devices (Fig. 1), 79 patients received 15–20 mm devices and 9 patients received 22–24 mm devices (Figs. 2 and 3). All the patients underwent transthoracic echocardiogram before discharge and showed no residual shunt, no AV valve regurgitation and normal systemic and pulmonary venous flows.

4. Discussion

We had 98 % (145/148) success rate in implanting ASD device in these small children with no major complications. We selected the

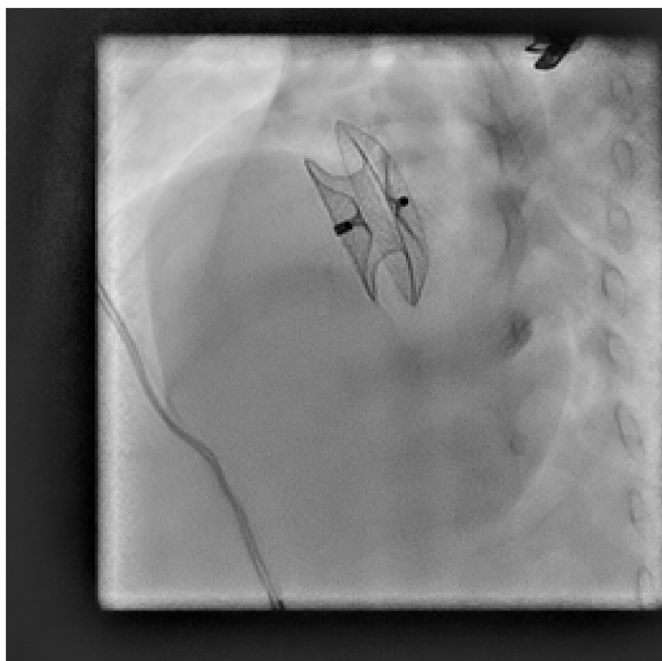

Fig. 1. 8 months old male child weight 5.8 Kg, 72 cm - 15 mm device.

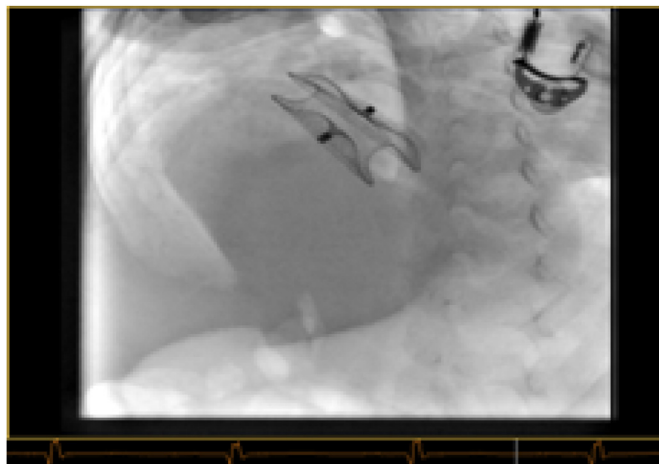


Fig. 2. 1 year old female, weight 8.2 kg, height 70.5 cm - 22 mm device.

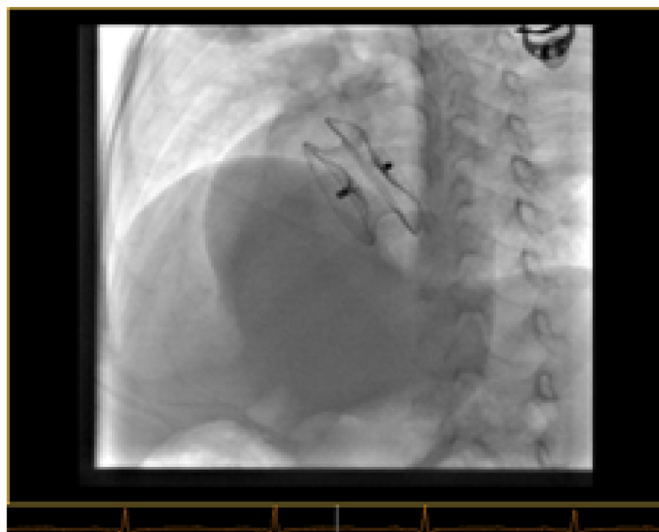


Fig. 3. 2 years old female, weight 10.5 kg, height 90.5 cm - 24 mm device.

device size of 2–3 mm more than the actual size of the ASD with important aspect of adequate IVC rim. Patients with isolated ASD are usually asymptomatic through infancy and early childhood and the elective surgery may be deferred to 2–4 years of age.¹ However, it has also been well documented that substantial numbers of small children are in need of earlier intervention, especially when the disease is complicated by chronic lung disease in prematurely-born infants or associated with certain chromosomal anomalies.^{2,3} ASD with large left to right shunt usually produce symptoms of heart failure, recurrent respiratory tract infection and poor weight gain from early childhood. Nevertheless, the need for early treatment has been recognized in small children who are showing rapidly enlarging defects rendering a suitable ASD to an unsuitable ASD for device closure.^{4,5} Hence we decided to take up the children with large ASDs to close early. The vessels are relatively small in younger children compared to the large delivery system, which leaves the possibility for potential damage to vascular access. Moreover, because of the rigid coupling mechanism between the device and delivery cable as well as excessive atrial rims, there is a latent risk for damage to the cardiac tissue, encroach on the adjacent cardiac structures or atrioventricular valves and erosion. All our patients were followed for minimum period of 2 years–9 years from the

date of procedure. But none experienced any complications. 95% of our patients showed weight gain and decreased frequency of respiratory infection during the first 6 months of follow up which indicated that early intervention is effective in controlling the symptoms. Remaining 5 % of patients did not have adequate weight gain but their frequency of respiratory infection was reduced. Our initial concern was whether thin and floppy margins would hold the device. However we did not find any difficulties in deploying the device. Our other concern was whether larger sized sheath and device would create hemodynamic instability and vessel damage. But none of our patient had any haemodynamic instability or vascular complications during or following the procedure. Indeed, in our follow up on the change in morphology of ASD, some small children with thin and floppy margins underwent resorption of their margins and becoming unsuitable for device closure due to deficit margins, especially IVC rim. We acknowledge that we did not do Qp/Qs calculation in our study group. But the indications to close the large ASD (>8 mm) in the recent times are dilated right heart and symptomatic children.⁶

5. Conclusion

We conclude by saying that transcatheter closure of ASD is feasible, relatively safe and effective in controlling symptoms in

very small children without any major complications by an experienced operator.

Declaration of competing interest

I did't have any financial support or sponsorship to this study. I declare no conflict of interest.

References

1. Park MK. *Pediatric Cardiology for Practitioners*. 5th ed. Philadelphia: Mosby Elsevier; 2008:161–191 [Google Scholar].
2. Bull C, Deanfield J, de Leval M, Stark J, Taylor JF, Macartney FJ. Correction of isolated secundum atrial septal defect in infancy. *Arch Dis Child*. 1981;56:784–786 [PMC free article][PubMed] [Google Scholar].
3. Lammers A, Hager A, Eicken A, Lange R, Hauser M, Hess J. Need for closure of secundum atrial septal defect in infancy. *J Thorac Cardiovasc Surg*. 2005;129:1353–1357 [PubMed][Google Scholar].
4. Hijazi ZM, Celiker A. Closure of atrial septal defects. *Anadolu Kardiyol Derg*. 2005;5:331 [PubMed] [Google Scholar].
5. Holzer R, Hijazi ZM. Interventional approach to congenital heart disease. *Curr Opin Cardiol*. 2004;19:84–90 [PubMed] [Google Scholar].
6. Taniguchi M, Akagi T, Kijima Y, et al. Clinical advantage of real-time three-dimensional transesophageal echocardiography for transcatheter closure of multiple atrial septal defects. *Int J Cardiovasc Imag*. 2013;29:1273–1280.