



Review Article

# Intracranial arachnoid cysts: Review of natural history and proposed treatment algorithm

John Carbone, Ananthababu Pattavilakom Sadasivan

Department of Neurosurgery, Princess Alexandra Hospital, Woolloongabba, QLD, Australia.

E-mail: \*John Carbone - john.carbone50@gmail.com; Ananthababu Pattavilakom Sadasivan - ananthababu@hotmail.com



**\*Corresponding author:**

John Carbone,  
Department of Neurosurgery,  
Princess Alexandra Hospital,  
Woolloongabba, 4102  
Queensland, Australia.

[john.carbone50@gmail.com](mailto:john.carbone50@gmail.com)

Received : 19 September 2021

Accepted : 15 November 2021

Published : 20 December 2021

DOI

10.25259/SNI\_946\_2021

Quick Response Code:



## ABSTRACT

**Background:** With a prevalence of 1.4%, intracranial arachnoid cysts are a frequent incidental finding on MRI and CT. Whilst most cysts are benign in the long-term, clinical practice, and imaging frequency does not necessarily reflect this.

**Methods:** A literature review was conducted searching the Medline database with MESH terms. This literature was condensed into an article, edited by a consultant neurosurgeon. This was further condensed, presented to the neurosurgery department at Princess Alexandra Hospital for final feedback and editing.

**Results:** This review advises that asymptomatic patients with typical cysts have a low risk of cyst growth and development of new symptomatology, thus do not require surveillance or intervention. The minority of symptomatic patients or those with cysts in sensitive areas may require referral to a neurosurgeon for clinical follow-up or intervention.

**Conclusion:** Greater than 94% of patients are asymptomatic, practitioners can be confident in reassuring patients of the benign nature of a potentially worrying finding. Recognizing the small number of symptomatic patients and those with cysts in areas sensitive to causing hydrocephalus is where GP decision making in conjunction with specialty input is of highest yield.

**Keywords:** Arachnoid cyst, Communication, General practice, Neurosurgery, Treatment algorithm

## INTRODUCTION

Intracranial arachnoid cysts are collections of cerebrospinal fluid (CSF) encased in a layer of collagen and arachnoidal cells.<sup>[17]</sup> Whilst the cysts consist of normal cells, the disrupted CSF flow dynamics, mass effect, and pressure can rarely cause hydrocephalus or symptomatic presentation. Incorrect management can lead to unnecessary testing, wasted resources and increased patient anxiety or missed intervention opportunities in the minority of cases it is required. It is therefore pertinent that treating clinicians are aware of the condition as many cysts are discovered incidentally.<sup>[1]</sup>

### Aim

This article aims to improve risk stratification skills of General Practitioners (GPs) in their daily practice, reduce unnecessary imaging, increase confidence in reassuring the majority of patients, and provide appropriate access to tertiary care for patients who may require intervention or follow-up. Recognizing the small number of symptomatic patients and those with cysts in areas

This is an open-access article distributed under the terms of the Creative Commons Attribution-Non Commercial-Share Alike 4.0 License, which allows others to remix, tweak, and build upon the work non-commercially, as long as the author is credited and the new creations are licensed under the identical terms.

©2021 Published by Scientific Scholar on behalf of Surgical Neurology International

sensitive to causing hydrocephalus is where GP decision making in conjunction with specialty input is of highest yield.

## ETIOLOGY/PATHOGENESIS

Arachnoid cysts are thought to form through splitting of the arachnoid membrane, allowing for abnormal collection of fluid. They may occur anywhere along the neuro-axis from head to spine. Histopathologically, the cysts demonstrate splitting of the arachnoid membrane at the margin of the cyst, thick collagen layers, absent trabecular processes, and hyperplastic arachnoid cells in the cyst wall.<sup>[17]</sup> Hypothesized formation mechanisms include osmotic gradient,<sup>[2]</sup> ball-and-valve mechanism, or internal production of fluid similar to CSF.<sup>[4]</sup> A minority of the patients may present symptomatically, due to hydrocephalus, mass effect or cyst rupture. Whilst intracystic pressure in arachnoid cysts has explicitly been correlated with symptoms; the mean intracystic pressure appears in normal adult limits.<sup>[3,13]</sup> This finding implies alternate factors such as CSF flow and altered compliance may contribute to the pathogenesis of symptomatic cysts.

## EPIDEMIOLOGY

Estimates of cyst prevalence in adults have historically been 1%.<sup>[18]</sup> The modern use of magnetic resonance image (MRI) and CT for cranial imaging has led to the increasing discovery and more accurate estimates of prevalence. Two major epidemiological studies, Al-Holou *et al.*<sup>[1]</sup> and Hall *et al.*<sup>[10]</sup> have outlined the natural history of arachnoid cysts in adults, estimating a prevalence of 1.4% of the population by retrospectively reviewing MRI sequences.

## IMAGING

CT and MR studies demonstrate that intracranial arachnoid cysts are well-circumscribed, extra-axial, and simple cystic lesions. They are isodense to CSF on CT, and isointense to CSF on all MRI sequences.<sup>[12]</sup> Unlike dermoid or epidermoid cysts, they do not exhibit diffusion restriction on MRI and are not lobulated with heterogeneous signal characteristics on MRI FLAIR imaging.<sup>[15]</sup> Ruptured arachnoid cysts can fill with blood products, resulting in imaging studies reflecting progressive blood degradation pathways. Thus, a lesion located extra-axially, typical morphological features [Table 1], and signal intensity matching that of CSF on MRI can confidently be diagnosed as an arachnoid cyst.<sup>[12]</sup>

## CLINICAL PRESENTATION

Greater than 94%<sup>[1,10]</sup> of patients are asymptomatic, a statistic that is influenced by cyst location. Those most commonly diagnosed were middle fossa (34%), retrocerebellar (33%), and convexity (14%). Middle fossa cysts were associated

with clinically significant decreased incidence of symptoms. Conversely, cerebellopontine angle and subarachnoid cistern located cysts had a clinically significant increased rate of symptoms.<sup>[1]</sup> The high rates of hydrocephalus in these areas, particularly in children, demonstrate the potential for structural obstruction.<sup>[8]</sup> Headache is the most common presenting symptom leading to the diagnosis of an arachnoid cyst. This is followed by cranial nerve dysfunction and nausea/vomiting. Symptomatic cysts are likely to be larger, having a single dimension >2.5 cm on average. Cysts appear unlikely to change in size, with only 3–5%<sup>[1,10]</sup> increasing or decreasing in size. Between the two studies, 300 patients followed up with serial imaging, only one developed new neurological symptoms. Therefore, clinicians can be confident that asymptomatic cysts will remain so, with a high rate of stability.

## ASYMPTOMATIC PATIENTS

Given the benign nature of the majority of adult arachnoid cysts, asymptomatic patients with typical cysts have a low risk of cyst growth and development of new symptomatology.<sup>[1]</sup> Therefore, formal clinical follow-up for asymptomatic patients with small cysts (<2.5 cm) that are not located in sensitive areas [Table 2] is not necessary. Special attention may be paid to abnormally large cysts or those in delicate regions associated with the higher rates of symptoms. Reports of cyst rupture spontaneously<sup>[9]</sup> or with trauma are scant; therefore, there does not appear to be a role for prophylactic surgery. Referral to a neurosurgical service may be sought in the unlikely event of new symptom onset. [Figure 1] outlines an algorithm for outpatient approach to a cyst presentation.

## SYMPTOMATIC PATIENTS

### Diagnosis

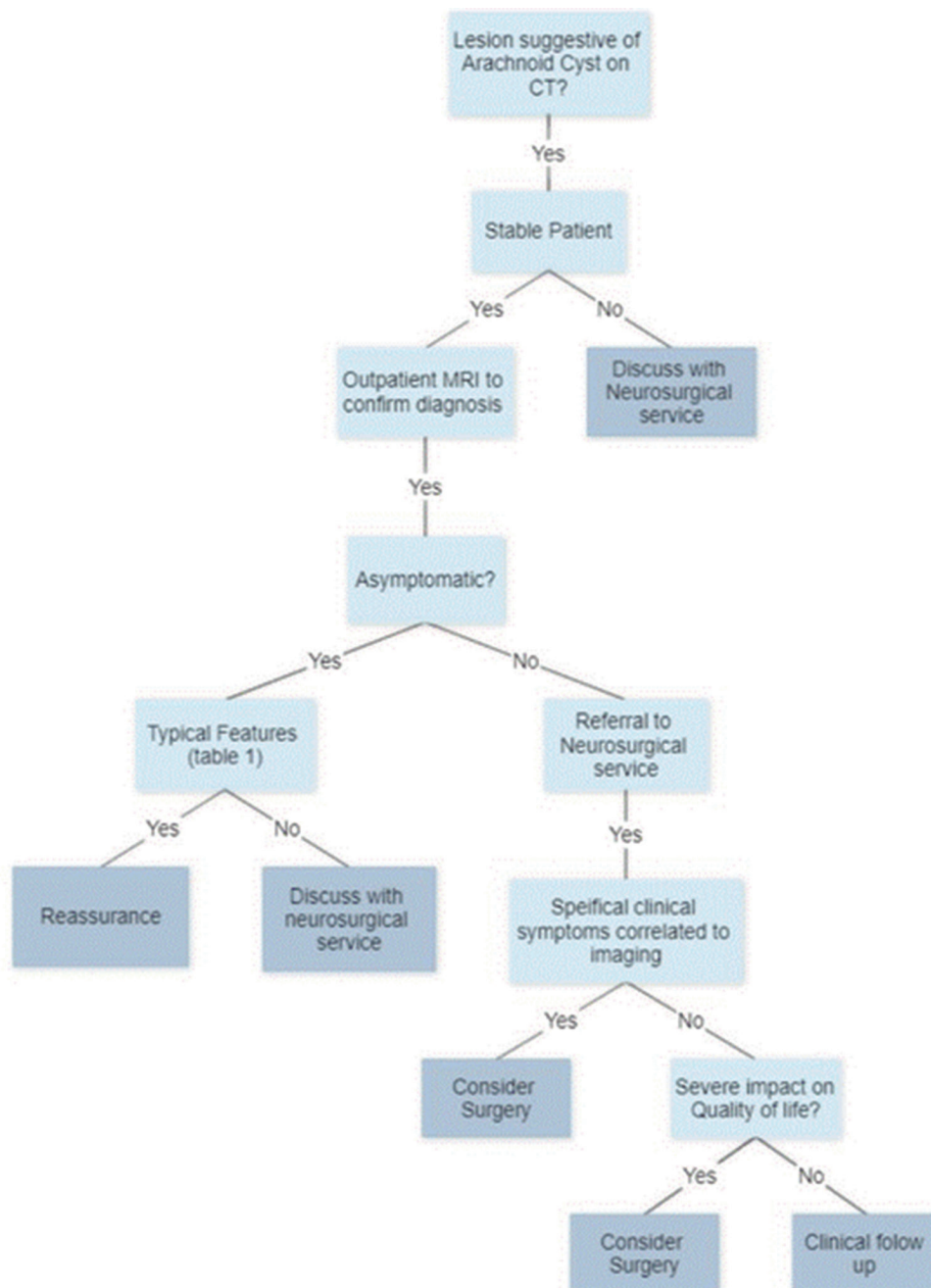
Correlating an arachnoid cyst with clinical presentation is a subjective assessment, with no objective test available to the surgeon. Symptom severity, cyst size, and correlating location with the presenting complaint are the best tools available to the present practitioners.

**Table 1:** Specific and non-specific symptoms associated with arachnoid cyst.

Specific symptoms or focal neurological deficits	Non-specific symptoms
Localized seizures	Headache
Visual changes	Nausea/vomiting
Nystagmus	Dizziness
Hearing loss	Vertigo
Speech abnormalities	Ataxia/gait imbalance
Cervical myelopathy	Non-localized seizure
Facial palsy	Cognitive deficits

**Table 2:** Imaging features of typical and atypical arachnoid cyst.

Imaging characteristics	Features of a typical cyst	Features of an atypical cyst
Number	Singular and well-circumscribed	Multiple cysts
Classification	Extra-axial	Intra-axial
Location	Middle fossa, retrocerebellar, and convexity	Cerebellopontine angle and subarachnoid cisterns
Single dimension	<2.5 cm	>2.5 cm
Intensity/density on imaging	Follows CSF on all modalities	Component non-congruent with CSF
Wall size	Thin/imperceptible	Thick/irregular
Hemorrhage	Without	Possible
Mass effect	No	Possible



**Figure 1:** Treatment algorithm for patients presenting with an arachnoid cyst.

## Surgical treatment

The aim of intervention is to achieve decompression of the cyst and establish communication between the normal and pathological CSF spaces. In general, the present evidence suggests that the treatment of symptomatic arachnoid cysts with surgical intervention does appear effective. A recent meta-analysis by Hayes *et al.* conducted by a literature search of existing studies concluded the treatment effect was 0.667 ( $P < 0.01$ ) for all surgical intervention in improving patient outcomes.<sup>[11]</sup> Cyst volume postoperatively does not correlate with patient outcomes<sup>[1,4,11,16]</sup> and thus should not be used to evaluate success. The previous meta-analysis comparing surgical methods found partial symptom improvement in 90% of surgical patients ( $P < 0.01$ ).<sup>[4]</sup> Both studies mention poor quality of evidence.<sup>[5]</sup> One retrospective study showed 86% of symptomatic patients who declined surgery improved clinically without intervention. Imaging characteristics were identical; however, those who refused surgery had a statistically significant lower prevalence of headache.<sup>[16]</sup> The first long-term prospective study of craniotomy with fenestration at short- and long-term follow-ups found 73.4% and 82%, headache symptoms improved using standardized scoring algorithms.<sup>[14]</sup>

### Is there a best treatment?

Two primary interventions are available for treating arachnoid cysts surgically, open craniotomy or endoscopic fenestration. The technique chosen is generally determined by surgeon experience and cyst location. There is no consensus for which method is best. Meta-analysis of retrospectively analyzed surgical methods shows similar rates of positive treatment effect between all practices.<sup>[4,11]</sup>

Craniotomy theoretically favors cysts in which the surrounding arachnoid is compressed,<sup>[6]</sup> where external decompression is achieved before restoring natural drainage pathways. Cysts in the convexities, which make up the majority of presentations, have preliminary evidence for favoring craniotomy.<sup>[7]</sup> Fenestration of the cyst allows for communication into the normal CSF pathways. In general, endoscopic procedures<sup>[7]</sup> are associated with fewer postoperative complications, and shorter hospital stays compared to craniotomy.<sup>[19]</sup> Suprasellar cysts are good candidates for endoscopy due to lying near sensitive structures such as the pituitary gland, hypothalamus, and optic nerve.<sup>[6]</sup> Similarly, cysts in the quadrigeminal cistern are favorable to endoscopic treatment due to the surrounding veins.<sup>[5]</sup>

## CONCLUSION

This review concludes that asymptomatic patients with typical cysts have a low risk of cyst growth and development of new symptomatology, thus do not require surveillance or

intervention. Greater than 94%<sup>[1]</sup> of patients are asymptomatic; practitioners can be confident in reassuring patients of the benign nature of a potentially worrying finding. Recognizing the small number of symptomatic patients and those with cysts in areas sensitive to causing hydrocephalus is where a GPs decision making in conjunction with specialty input is of highest yield. The minority of symptomatic patients or those with cysts in sensitive areas may require referral to a neurosurgeon for clinical follow-up or intervention.

## KEY POINTS

- Majority of arachnoid cysts are asymptomatic and are unlikely to become symptomatic.
- Surveillance imaging is not required as they are unlikely to change size.
- Cysts in sensitive areas or symptomatic patients should be discussed with a neurosurgical service.
- Atypical cysts should be discussed with a neurosurgical service.
- Surgery appears to have a role in patients whose symptoms can be clinically ascribed to a symptomatic cyst.

### Declaration of patient consent

Patient's consent not required as there are no patients in this study.

### Financial support and sponsorship

Nil.

### Conflicts of interest

There are no conflicts of interest.

## REFERENCES

1. Al-Holou WN, Terman S, Kilburg C, Garton HJ, Muraszko KM, Maher CO. Prevalence and natural history of arachnoid cysts in adults. *J Neurosurg* 2013;118:222-31.
2. Basaldella L, Orvieto E, Dei Tos AP, Della Barbera M, Valente M, Longatti P. Causes of arachnoid cyst development and expansion. *Neurosurg Focus* 2007;22:E4.
3. Berle M, Wester KG, Ulvik RJ, Kroksveen AC, Haaland OA, Amiry-Moghaddam M, *et al.* Arachnoid cysts do not contain cerebrospinal fluid: A comparative chemical analysis of arachnoid cyst fluid and cerebrospinal fluid in adults. *Cerebrospinal Fluid Res* 2010;7:8.
4. Chen Y, Fang HJ, Li ZF, Yu SY, Li CZ, Wu ZB, *et al.* Treatment of middle cranial fossa arachnoid cysts: A systematic review and meta-analysis. *World Neurosurg* 2016;92:480-90.e2.
5. Cinalli G, Spennato P, Columbano L, Ruggiero C, Aliberti F, Trischitta V, *et al.* Neuroendoscopic treatment of arachnoid cysts of the quadrigeminal cistern: A series of 14 cases.

- J Neurosurg Pediatr 2010;6:489-97.
6. Gangemi M, Colella G, Magro F, Maiuri F. Suprasellar arachnoid cysts: Endoscopy versus microsurgical cyst excision and shunting. *Br J Neurosurg* 2007;21:276-80.
  7. Gangemi M, Seneca V, Colella G, Cioffi V, Imperato A, Maiuri F. Endoscopy versus microsurgical cyst excision and shunting for treating intracranial arachnoid cysts. *J Neurosurg Pediatr* 2011;8:158-64.
  8. Gui S, Bai J, Wang X, Zong X, Li C, Cao L, *et al.* Assessment of endoscopic treatment for quadrigeminal cistern arachnoid cysts: A 7-year experience with 28 cases. *Childs Nerv Syst* 2016;32:647-54.
  9. Hall A, White MA, Myles L. Spontaneous subdural haemorrhage from an arachnoid cyst: A case report and literature review. *Br J Neurosurg* 2017;31:607-10.
  10. Hall S, Smedley A, Sparrow O, Mathad N, Waters R, Chakraborty A, *et al.* Natural history of intracranial arachnoid cysts. *World Neurosurg* 2019;126:e1315-20.
  11. Hayes MJ, TerMaath SC, Crook TR, Killeffer JA. A review on the effectiveness of surgical intervention for symptomatic intracranial arachnoid cysts in adults. *World Neurosurg* 2019;123:e259-72.
  12. Heier LA, Zimmerman RD, Amster JL, Gandy SE, Deck MD. Magnetic resonance imaging of arachnoid cysts. *Clin Imaging* 1989;13:281-91.
  13. Helland CA, Wester K. Intracystic pressure in patients with temporal arachnoid cysts: A prospective study of preoperative complaints and postoperative outcome. *J Neurol Neurosurg Psychiatry* 2007;78:620-3.
  14. Moss T, Helland CA, Mørkve SH, Wester K. Surgical decompression of arachnoid cysts leads to improved quality of life: A prospective study-long-term follow-up. *Acta Neurochir (Wien)* 2019;161:2253-63.
  15. Osborn AG, Preece MT. Intracranial cysts: Radiologic-pathologic correlation and imaging approach. *Radiology* 2006;239:650-64.
  16. Rabiei K, Hellström P, Högfeltdt-Johansson M, Tisell M. Does subjective improvement in adults with intracranial arachnoid cysts justify surgical treatment? *J Neurosurg* 2018;128:250-7.
  17. Rengachary SS, Watanabe I. Ultrastructure and pathogenesis of intracranial arachnoid cysts. *J Neuropathol Exp Neurol* 1981;40:61-83.
  18. Robinson RG. Congenital cysts of the brain: Arachnoid malformations. *Prog Neurol Surg* 1971;4:133-74.
  19. Shim KW, Lee YH, Park EK, Park YS, Choi JU, Kim DS. Treatment option for arachnoid cysts. *Childs Nerv Syst* 2009;25:1459-66.

**How to cite this article:** Carbone J, Sadasivan AP. Intracranial arachnoid cysts: Review of natural history and proposed treatment algorithm. *Surg Neurol Int* 2021;12:621.