



Successful Interventional Management of Common Carotid Artery Rupture during Recurrent Parathyroid Cancer Surgery: A Case Report

재발한 부갑상선암 수술 중 발생한 총경동맥 파열의 성공적인 인터벤션 치료: 증례 보고

Ye Rin Hwang, MD , Seung Yeon Noh, MD ,
Se Hwan Kwon, MD* , Joo Hyeong Oh, MD

Department of Radiology, College of Medicine, Kyung Hee University, Kyung Hee University Hospital, Seoul, Korea

ORCID iDs

Ye Rin Hwang <https://orcid.org/0000-0002-2329-6399>
Seung Yeon Noh <https://orcid.org/0000-0001-7532-5211>
Se Hwan Kwon <https://orcid.org/0000-0002-7777-8422>
Joo Hyeong Oh <https://orcid.org/0000-0002-8558-2112>

Common carotid artery (CCA) rupture during parathyroid cancer surgery is extremely rare and is generally life-threatening. We present a case of successful management of a ruptured CCA following the emergency placement of stent-graft in a 59-year-old male diagnosed with recurrent parathyroid cancer. During recurrent parathyroid cancer surgery, his right CCA ruptured unexpectedly, and his vital signs deteriorated rapidly despite surgical management. After stent replacement, his unstable vital signs improved and, thereafter, he was discharged without any complications.

Index terms Carotid Artery Injuries; Endovascular Procedures; Stents; Emergencies; Parathyroidectomy

INTRODUCTION

The management of carotid artery injury has traditionally required surgical treatment (1, 2). However, the surgical approach of carotid artery repair yields unsatisfactory results, including cerebral ischemia and associated neurologic morbidity and mortality (3). Recently,

Received September 11, 2021
Revised December 6, 2021
Accepted December 9, 2021

*Corresponding author

Se Hwan Kwon, MD
Department of Radiology,
College of Medicine,
Kyung Hee University,
Kyung Hee University Hospital,
23 Kyunghedae-ro, Dongdaemun-
gu,
Seoul 02447, Korea.

Tel 82-2-958-8622
Fax 82-2-960-0787
E-mail kwon98@khu.ac.kr

This is an Open Access article distributed under the terms of the Creative Commons Attribution Non-Commercial License (<https://creativecommons.org/licenses/by-nc/4.0>) which permits unrestricted non-commercial use, distribution, and reproduction in any medium, provided the original work is properly cited.

the emergence of interventional treatment methods offers an alternative to traditional surgical methods for carotid lesions such as carotid pseudoaneurysm, dissection, fistulas, laceration associated with neurosurgery, and blowout syndrome caused by malignancy. Here, we report a case of successful interventional management of common carotid artery (CCA) rupture during parathyroid cancer surgery.

CASE REPORT

A 59-year-old male patient was admitted to our hospital for surgery related to the recurrent malignancy of the right parathyroid gland. He underwent right thyroidectomy/parathyroidectomy and two mass removal surgeries due to the recurrence of right parathyroid cancer in the past 10 years. His history included hypertension that was diagnosed 15 years earlier, for which he had been taking antihypertensive drugs. There was no history of trauma, diabetes, or other congenital diseases. The patient had no connective tissue disorders or other systemic anomalies, and there was no significant family history of disease.

At the last follow-up, axial neck CT showed a small soft tissue nodule at right thyroid bed, posteromedial to the right CCA (Fig. 1A). Because the size of the lesion increased compared to the previous CT scan (about 0.6 cm to 1.6 cm), parathyroid scintigraphy (Tc-99m sestamibi 15mCi scan) was planned. Early scan was performed at 20 minutes after intravenous radiopharmaceutical injection and delayed scan was performed at 150 minutes after injection. There were multiple nodular uptake foci in the right upper paratracheal area and right operation bed (Fig. 1B). The patient was also examined for increased blood calcium (hypercalcemia, 15.9 mg/dL). A diagnosis of recurrent parathyroid cancer was made, and surgical removal was planned.

During the operation, his right CCA was accidentally ruptured, resulting in abrupt massive bleeding. The surgeon compressed the ruptured portion manually and attempted surgical repair. However, surgical repair was difficult and failed because the location of the rupture site was very deep with continuous massive bleeding. Furthermore, his vital signs deteriorated rapidly despite manual compression.

He was referred to the interventional radiology department for the management of the ruptured right CCA, and we decided to perform emergent stent grafting for the ruptured lesion. In the angiography suite, an 8 French (Fr) femoral sheath was inserted via the right common femoral artery by Seldinger method. Right brachiocephalic artery was selected using 0.035 inch guidewire and 5 French diagnostic catheter. The angiography showed focal rupture and active bleeding from the proximal right CCA (Fig. 1C). Fortunately, the rupture portion had a sufficient proximal safety margin from the brachiocephalic artery for the stent-graft placement. So, we replaced an 8 French long guiding-sheath catheter at the right proximal CCA, and then, a self-expandable peripheral stent graft (10 mm × 60 mm; SnG Biotech, Yongin, Korea) was successfully placed. A final angiogram showed the successful sealing of CCA rupture without any contrast leakage. His right CCA and subclavian artery flow was preserved (Fig. 1D). The patient had no neurologic complications after the procedure. He was discharged 12 days after the procedure without major complications. After the procedure, the surgeon completed the removal surgery of recurrent parathyroid cancer.

The follow-up CT scan 6 months after the treatment showed a properly located stent graft

Fig. 1. Successful stent-graft placement of common carotid artery rupture during recurrent parathyroid cancer surgery in a 59-year-old male.

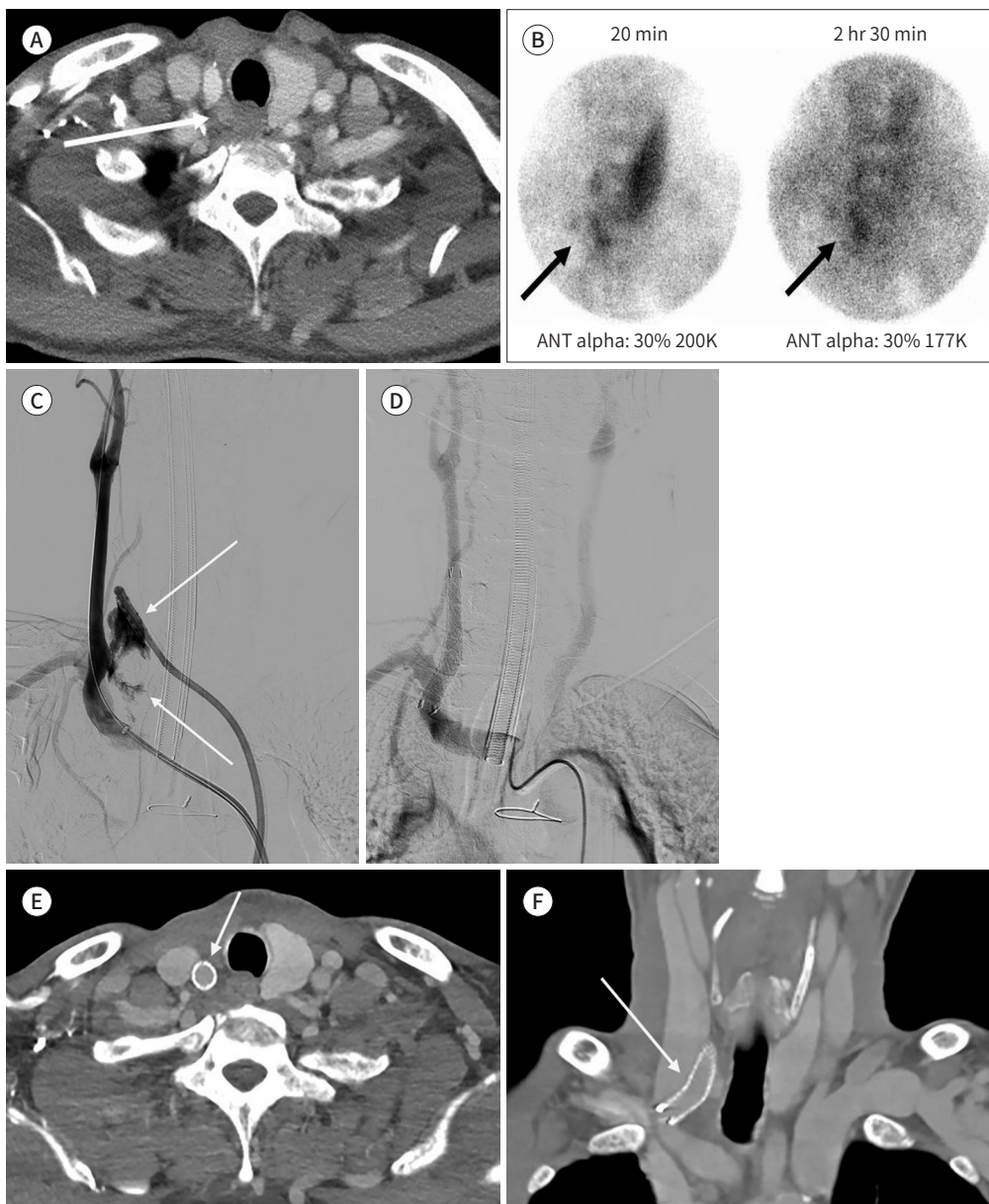
A. Axial neck CT shows a small soft tissue nodule at the right thyroid bed, posteromedial to the right common carotid artery (arrow).

B. Parathyroid scintigraphy (Tc-99m sestamibi 15mCi scan, 20 minutes and 2 hours 30 minutes scans) shows multifocal nodular uptake in right upper paratracheal area and right thyroid bed (arrows), suggesting parathyroid carcinoma.

C. Right common carotid angiography shows arterial rupture and active extravasation of the contrast media (arrows).

D. Post-procedural angiography shows the successful sealing of the rupture without blood leakage. The right common carotid and subclavian artery flow are preserved.

E, F. Follow-up axial (**E**) and coronal (**F**) CT 5 months after stent-graft placement show well-located stent-graft with good patency (arrows).



with excellent patency (Fig. 1E, F). The patient has been monitored for 1 year and is in good physical condition thus far.

This case report followed the 1975 Helsinki Declaration's ethical guidelines. And we received written informed consent from the patient for the study.

DISCUSSION

The terms "carotid blowout" and "carotid artery rupture" are used synonymously in the literature. The modern definition of "carotid blowout" is a syndrome with three distinct subtypes including threatened (Grade I—radiological or clinical evidence to suspect future hemorrhage, such as an exposed carotid artery), imminent (Grade II—transcervical or transoral short-term hemorrhage, which usually resolves spontaneously or with surgical packing), and acute (Grade III—abundant hemorrhage, which is neither self-limiting nor controlled with surgical packing) (4, 5).

Carotid artery injury can be caused by trauma (blunt, penetrating, and iatrogenic), cancer or cancer treatment, and spontaneous dissection (1, 2, 6). Although the incidence of carotid artery injury is unclear, approximately 6% of all cases of penetrating trauma to the neck and less than 1% of blunt neck injuries involve carotid artery injury (2).

Iatrogenic carotid artery rupture has been reported to occur in 3%–5% of patients who undergo major head and neck surgery (6). In addition, it can occur during transsphenoidal surgery. According to the response of 958 neurosurgeons, 12% reported that they had encountered carotid artery injury during transsphenoidal surgery (1, 7). Carotid artery injury or rupture is not common in clinical practice; however, if it does occur, the mortality rate can reach 17%–40%, and the incidence of serious central nervous system complications has been reported as 40%–80% among survivors (7, 8).

The right CCA originates at the bifurcation of the brachiocephalic trunk behind the sternoclavicular joint and courses cephalad, terminating at the level of the thyroid cartilage (C4 vertebral body), where it bifurcates into internal and external carotid artery (9). Therefore, it is a risk for the injury during thyroidectomy or parathyroidectomy. These injuries could be devastating because of cerebrovascular ischemia and airway compression. Iatrogenic carotid artery injuries by surgical trauma were accompanied by 19.3% (11/57) incidence of stroke and 10.5% (6/57) mortality. Even more, a median sternotomy would be required to achieve proper control of the injured carotid artery behind the sterno-clavicular joint (proximal carotid artery).

Cawich et al. (9) reported a rare case where they were required to repair a complete transection of the carotid artery with segmental loss which occurred as an iatrogenic complication during thyroidectomy. They performed segmental resection of the injured carotid artery and ligation of both carotid ends in an emergency. Jamaan et al. (10) reported a septic bleeding of the CCA following total thyroidectomy. They performed resection of the faulty artery segment and surgical autograft procedure using great saphenous vein. In our case, the right CCA rupture occurred during recurrent parathyroid cancer surgery. Of course, since it was a rupture during surgery, it would be ideal if immediate surgical access was possible. Unfortunately, surgical management was failed due to the massive hemorrhage. Fortunately, interventional stent-graft placement was successful in this patient because the rupture portion had a suffi-

cient proximal safety margin from the brachiocephalic artery for the stent-graft placement.

The treatment of carotid artery injury has traditionally required surgical management (1). However, the surgical approach for carotid artery injury is technically difficult, and it is often impossible to identify the exact source of bleeding due to the deep-seated location and massive bleeding. Therefore, the yields of the surgical repair has been unsatisfactory results including cerebral ischemia, and it is associated with neurologic morbidity and mortality (1, 2). Recently, the emergence of interventional treatment methods offers an alternative to traditional surgical method, and it is considered the gold standard for some patients. There are several options for the endovascular management of carotid artery injuries, such as selective embolization using various embolic materials and stent-graft placement, which allows continued cerebral blood flow (4-6). The stent-graft placement can be used alone or in combination with embolization.

In conclusion, CCA rupture during parathyroid cancer surgery is a serious and life-threatening complication. When a large amount of bleeding occurs or vital signs are unstable, carotid arterial rupture should be suspected. Fortunately, the frequency of carotid rupture during surgery is further decreasing with the development of surgical techniques, but difficult surgical access is a problem that is directly related to patient's life. A rapid transition to endovascular approach could save patients and prevent complications from vascular injury.

Author Contributions

Conceptualization, K.S.H.; investigation, H.Y.R., K.S.H., N.S.Y.; projection administration, K.S.H.; supervision, K.S.H.; writing—original draft, H.Y.R., K.S.H.; and writing—review and editing, all authors.

Conflicts of Interest

The authors have no potential conflicts of interest to disclose.

Funding

None

REFERENCES

1. Lee CH, Park JS, Hwang KW, Lee SW, Park SW, Park SJ. Procedure-induced acute common carotid artery perforation presenting with airway obstruction and successful treatment by endovascular stent graft. *Korean Circ J* 2011;41:405-408
2. Martin RF, Eldrup-Jorgensen J, Clark DE, Bredenberg CE. Blunt trauma to the carotid arteries. *J Vasc Surg* 1991;14:789-793; discussion 793-795
3. DuBose J, Recinos G, Teixeira PG, Inaba K, Demetriades D. Endovascular stenting for the treatment of traumatic internal carotid injuries: expanding experience. *J Trauma* 2008;65:1561-1566
4. Broomfield S, Bruce I, Birzgalis A, Herwadkar A. The expanding role of interventional radiology in head and neck surgery. *J R Soc Med* 2009;102:228-234
5. Dequanter D, Shahla M, Paulus P, Aubert C, Lothaire P. Transarterial endovascular treatment in the management of life-threatening carotid blowout syndrome in head and neck cancer patients: review of the literature. *J Mal Vasc* 2013;38:341-344
6. Upile T, Triaridis S, Kirkland P, Archer D, Searle A, Irving C, et al. The management of carotid artery rupture. *Eur Arch Otorhinolaryngol* 2005;262:555-560
7. Ciric I, Ragin A, Baumgartner C, Pierce D. Complications of transsphenoidal surgery: results of a national survey, review of the literature, and personal experience. *Neurosurgery* 1997;40:225-236; discussion 236-237
8. Asensio JA, Valenziano CP, Falcone RE, Grosh JD. Management of penetrating neck injuries. The controversy surrounding zone II injuries. *Surg Clin North Am* 1991;71:267-296

9. Cawich SO, Dwarika W, Mohammed F, Ramdass MJ, Ragoonanan V, Augustus M, et al. Lessons learned after iatrogenic complete transection of the right common carotid artery with segmental vessel loss. *Case Rep Vasc Med* 2021;2021:8812870
10. Jamaan T, Raedecke J, Kayser C, Rueckauer KD, Thomusch O. Septic bleeding of the common carotid artery following total thyroidectomy: an atypical complication. *Case Rep Med* 2010;2010:953282

재발한 부갑상선암 수술 중 발생한 총경동맥 파열의 성공적인 인터벤션 치료: 증례 보고

황예린 · 노승연 · 권세환* · 오주형

부갑상선암 수술 중 발생하는 총경동맥 파열은 매우 드물고 생명을 위협하는 질환이다. 저자들은 재발한 부갑상선암을 가진 59세 남자 환자에서 파열된 총경동맥을 응급 피복형 스텐트 삽입을 통해 성공적으로 치료한 증례를 보고한다. 수술 도중 환자의 우측 총경동맥은 갑자기 파열되었고 수술적 대처에도 활력징후가 급속하게 악화되었으나 스텐트 삽입 후 호전되었고 합병증 없이 퇴원하였다.

경희대학교 의과대학 경희대학교병원 영상의학과