

Serum ProGRP and NSE levels predicting small cell lung cancer transformation in a patient with *ALK* rearrangement-positive non-small cell lung cancer: A case report

YUKO OYA¹, TATSUYA YOSHIDA¹, TAKEHIRO UEMURA¹,
YOSHIKO MURAKAMI², YOSHITAKA INABA³ and TOYOAKI HIDA¹

Departments of ¹Thoracic Oncology, ²Pathology and Molecular Diagnostics, and
³Diagnostic and Interventional Radiology, Aichi Cancer Center Hospital, Nagoya, Aichi 464-8681, Japan

Received December 23, 2017; Accepted May 22, 2018

DOI: 10.3892/ol.2018.9158

Abstract. The resistance mechanisms to anaplastic lymphoma kinase (*ALK*) inhibitors comprise *ALK* gene variations, such as *ALK* point mutations and copy-number gains, the activation of bypass signaling through the activation of other oncogenes and small cell lung cancer (SCLC) transformation. To date, few studies have investigated whether tumor markers for SCLC correlate with the SCLC transformation in *EGFR*-mutant NSCLC and *ALK*-positive non-SCLC (NSCLC). The present case study reported a patient with SCLC transformation after alectinib treatment. The patient exhibited elevation of pro-gastrin-releasing peptide precursor and neuron-specific enolase levels, which may be predictive of SCLC transformation during the resistance to *ALK*-tyrosine kinase inhibitors.

Introduction

Anaplastic lymphoma kinase (*ALK*) gene rearrangements are present in 3-5% of patients with non-small cell lung cancer (NSCLC). Research has revealed the promising clinical activity of *ALK*-tyrosine kinase inhibitors (TKIs) in the treatment of patients with NSCLC who contain *ALK* rearrangements. Crizotinib was the first *ALK*-TKI approved for patients with *ALK* rearrangement-positive NSCLC. Recently, two second-generation *ALK*-TKIs (alectinib and ceritinib) have been approved for the treatment of *ALK* rearrangement-positive NSCLC in Japan. Although these inhibitors exhibited significant clinical responses, almost all patients treated with them developed resistance. Some studies have reported that the resistance mechanisms in patients with

ALK rearrangement-positive NSCLC comprised *ALK* gene alterations, such as *ALK* point mutations and copy-number gains (1,2), bypass signaling activation through the activation of other oncogenes (3,4), and SCLC transformation (5,6). However, to date, no study has reported a correlation between tumor markers and SCLC transformation in both *EGFR*-mutant and *ALK* rearrangement-positive NSCLC. Here, we report a case of a patient with SCLC transformation after alectinib treatment who exhibited an elevation of pro-gastrin-releasing peptide precursor (ProGRP) and neuron-specific enolase (NSE) levels, suggesting these to be predictive of SCLC transformation during the development of resistance to *ALK*-TKIs.

Case report

A 62-year-old former smoker male (38 pack-year history) with contralateral lung metastases presented with lung adenocarcinoma in clinical stage T1aN3M1a. The patient provided informed consent. He underwent biopsy of the left supraclavicular lymph node, and both immunohistochemistry (IHC) and fluorescence *in situ* hybridization (FISH) revealed adenocarcinoma with *ALK* rearrangement. Accordingly, he received cytotoxic chemotherapy (carboplatin, pemetrexed, and bevacizumab), to which his best response was a stable disease. After 4 months of the treatment initiation, his drug regimen was changed to 300 mg alectinib two times daily, which is the approved dosage in Japan, due to the disease progression. Eventually, he attained complete radiological remission. After 1 year of alectinib treatment, brain magnetic resonance imaging revealed a new central nervous system (CNS) metastasis. Accordingly, he underwent stereotactic radiotherapy (SRT) for the isolated CNS lesion and continued receiving alectinib beyond the CNS progression. After 2 years of the alectinib initiation, computed tomography (CT) revealed a new mass (55x60 mm) in the left lobe of the liver (Fig. 1A). The pathological finding corroborated SCLC transformation (Fig. 2A). In addition, the detection of the *ALK* overexpression and rearrangement with IHC and FISH confirmed SCLC transformation in this specimen (Fig. 2B and C). During rebiopsy, serum ProGRP, NSE, and carcinoembryonic antigen (CEA) levels were 275.5 pg/ml, 21.8 ng/ml and

Correspondence to: Dr Tatsuya Yoshida, Department of Thoracic Oncology, Aichi Cancer Center Hospital, 1-1 Kanokoden, Chikusa-ku, Nagoya, Aichi 464-8681, Japan
E-mail: t.yoshida@aichi-cc.jp

Key words: non-small cell lung cancer, small cell lung cancer transformation, anaplastic lymphoma kinase gene rearrangements

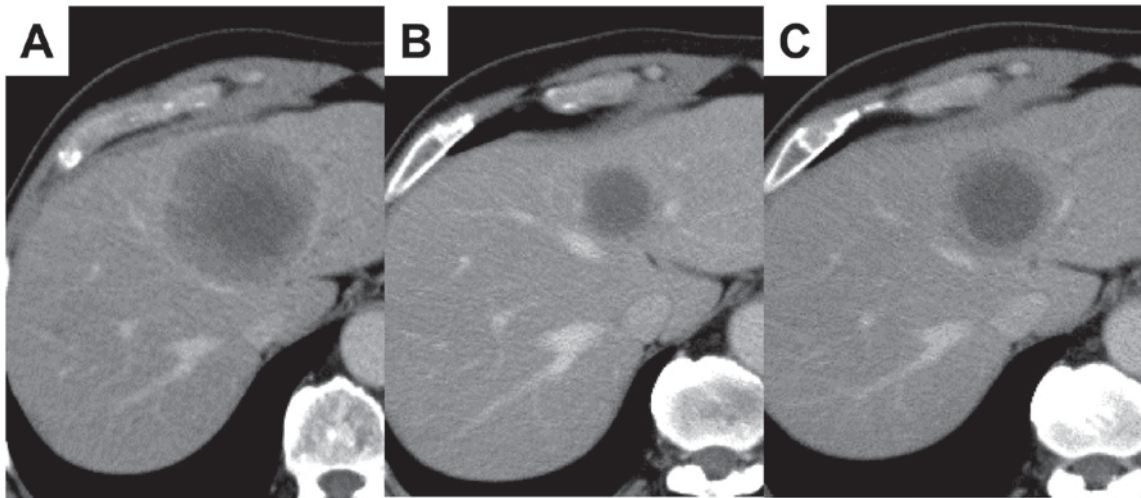


Figure 1. CT scans of liver metastasis. CT scans (A) just before the initiation of CDDP and ETP; (B) after four cycles of CDDP and ETP; and (C) just before the initiation of AMR. CT, computed tomography; CDDP, cisplatin; ETP, etoposide; AMR, amrubicin.

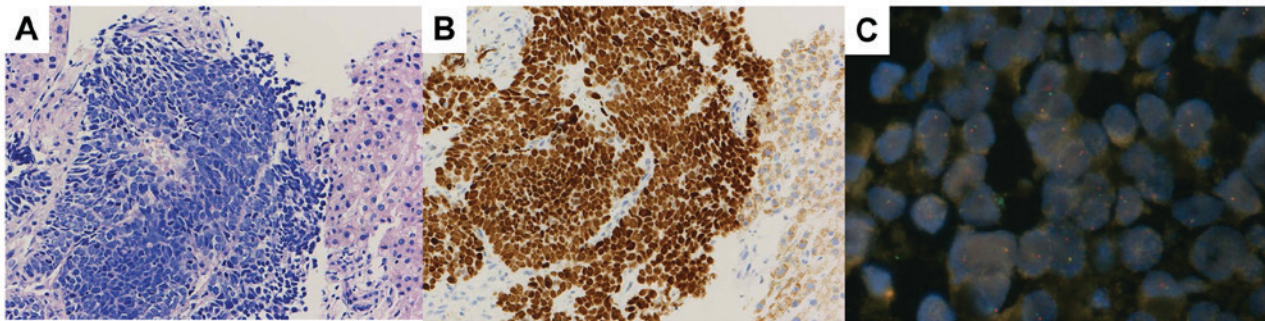


Figure 2. Histopathological analysis of liver metastasis after alectinib treatment. (A) Hematoxylin and eosin staining indicated small round cell proliferation, which is consistent with the diagnosis of SCLC (original magnification, x100). (B) Tumor cells were positive for ALK immunohistochemistry (original magnification, x100) and (C) break-apart signals were observed in ALK FISH. SCLC, small cell lung cancer; ALK, anaplastic lymphoma kinase; FISH, fluorescence *in situ* hybridization.

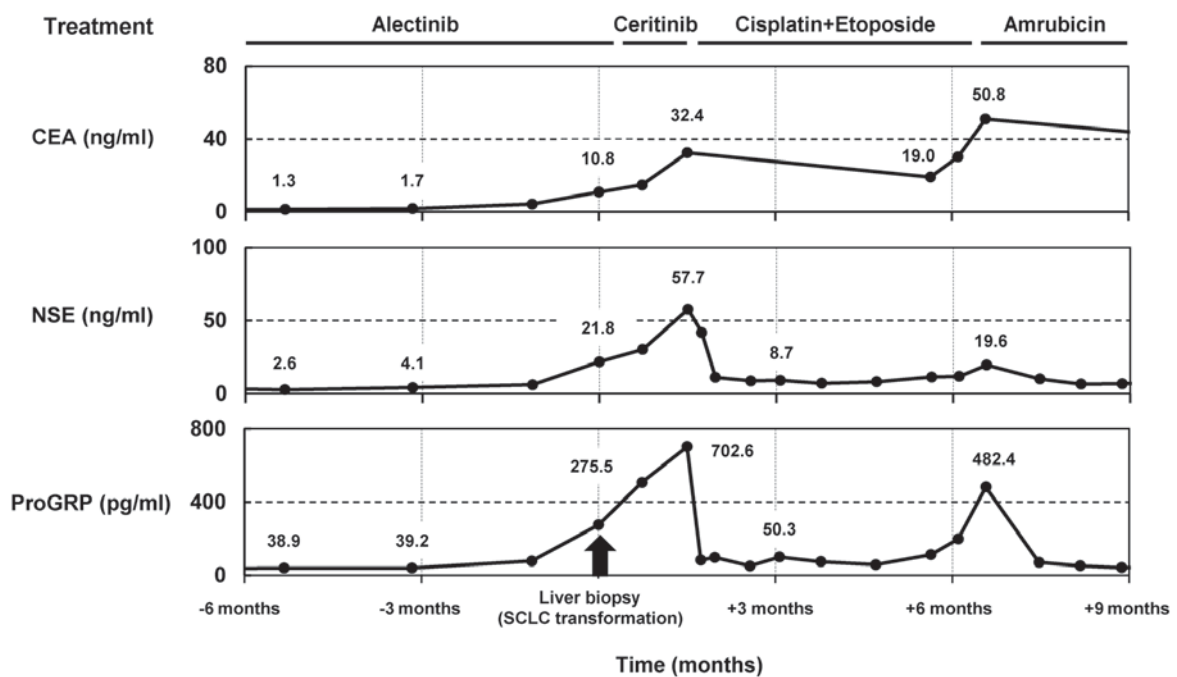


Figure 3. Time course of serum CEA, NSE and ProGRP levels before and after rebiopsy for SCLC transformation. CEA, carcinoembryonic antigen; NSE, neuron-specific enolase; ProGRP, pro-gastrin-releasing peptide precursor; SCLC, small cell lung cancer.

10.8 ng/ml, respectively (serum ProGRP and CEA levels upon *ALK* rearrangement-positive NSCLC diagnosis were 56.3 pg/ml and 4.2 ng/ml, respectively). Accordingly, he temporally received ceritinib after alectinib treatment; however, serum ProGRP, NSE, and the size of liver metastasis continued to increase. Thus, we switched to cisplatin and etoposide. After four cycles, CT revealed a partial response of the liver lesion to the treatment (Fig. 1B). After 3 months, liver metastasis progressed (Fig. 1C). Hence, we treated the patient with three more regimens [amrubicin (AMR), nivolumab, and irinotecan], but the tumor progressed. After 4 years of the treatment initiation, the patient died due to disease progression.

Discussion

This case report retrospectively analyzed the serial tumor markers CEA, NES, and ProGRP because the diagnosis of *ALK* rearrangement-positive NSCLC in a patient (Fig. 3). Three months before SCLC transformation was confirmed by a liver biopsy, serum CEA, NES, and ProGRP levels were within normal limits. However, after SCLC transformation, serum ProGRP and NSE levels correlated with tumor response to chemotherapy for SCLC and were significantly beneficial for monitoring tumor progression. Thus, this study revealed that tumor markers, such as ProGRP and NSE, can predict SCLC transformation at the time of developing resistance to ALK-TKIs.

Apparently, ProGRP and NSE are two of the tumor markers of SCLC that are preferentially used to diagnose diseases. Typically, the diagnostic specificity of NSE is rather limited owing to a relatively high false-positive rate. Conversely, the diagnostic sensitivity and specificity of ProGRP in SCLC are higher compared to those in NSE (7). To date, no study has investigated whether tumor markers for SCLC could be predictive markers for SCLC transformation in not only *EGFR*-mutant NSCLC but also *ALK* rearrangement-positive NSCLC. To the best of our knowledge, only one case study of SCLC transformation in *EGFR*-mutant NSCLC reported the elevation of serum ProGRP and NSE levels. However, whether tumor markers could be predictive for the diagnosis of SCLC transformation, due to the confirmed pathological diagnosis at autopsy, remains unclear. Hence, our case is the first to report that both ProGRP and NSE could be useful predictive markers for SCLC transformation.

Research has identified several ALK-TKI resistance mechanisms in patients with *ALK* rearrangement-positive NSCLC, and each resistance mechanism exhibits a different sensitivity to other ALK inhibitors in *ALK* rearrangement-positive NSCLC (8). Thus, identifying the resistance mechanism that remains sensitive to other ALK inhibitors could be essential in selecting appropriate ALK inhibitors as subsequent ALK-TKIs. In addition, non-invasive liquid biopsies and cell-free DNA (cfDNA) genotyping have been developed to detect these resistance mechanisms efficiently because multiple tumor biopsies are related to both risks and discomfort (6,9-12). However, liquid biopsies are limited in the diagnosis of histological transformation. Hence, we anticipate that combining ProGRP and specific cfDNA for the detection of ALK resistance mutation could be more useful. Indeed, in our case, both ProGRP and NSE levels were elevated at the time of developing resistance to alectinib, suggesting that we could predict SCLC transformation before rebiopsy. Further investigation of the correlation between

tumor markers ProGRP and NSE and SCLC transformation is warranted.

Acknowledgements

Not applicable.

Funding

No funding was received.

Availability of data and materials

The datasets used and/or analyzed during the current study are available from the corresponding author on reasonable request.

Authors' contributions

YO, TY and TH collaborated in the conception and design of the study. YO, TY, TU, YI and TH acquired the data. YO, TY, TU, YI and TH performed data analysis. All authors were involved in writing the manuscript. All authors read and approved the final manuscript.

Ethics approval and consent to participate

Not applicable.

Consent for publication

The patient was informed that the data from his case would be submitted for publication and provided consent.

Competing interests

Dr Hida obtained research grants from Ono Pharmaceutical, Novartis Pharma, Chugai Pharmaceutical, Eli Lilly, Taiho Pharmaceutical, AstraZeneca, Nippon Boehringer Ingelheim, Pfizer, Bristol-Meyers Squibb, Clovis Oncology, Eisai, Takeda Bio, Dainippon Sumitomo Pharma, Abbvie, MSD, Merck Serono, Kyowa Hakko Kirin, Daiichi Sankyo, Servier, Kissei, Ignyta, and Astellas. He has received personal fees from Ono Pharmaceutical, Novartis Pharma, Chugai Pharmaceutical, Eli Lilly, Taiho Pharmaceutical, AstraZeneca, Nippon Boehringer Ingelheim, Pfizer, MSD, Kissei, Clovis Oncology, and Bristol-Meyers Squibb. All other authors have no competing interests.

References

1. Katayama R, Khan TM, Benes C, Lifshits E, Ebi H, Rivera VM, Shakespeare WC, Iafrate AJ, Engelman JA and Shaw AT: Therapeutic strategies to overcome crizotinib resistance in non-small cell lung cancers harboring the fusion oncogene EML4-ALK. *Proc Natl Acad Sci USA* 108: 7535-7540, 2011.
2. Katayama R, Shaw AT, Khan TM, Mino-Kenudson M, Solomon BJ, Halmos B, Jessop NA, Wain JC, Yeo AT, Benes C, *et al*: Mechanisms of acquired crizotinib resistance in ALK-rearranged lung cancers. *Sci Transl Med* 4: 120ra17, 2012.
3. Sasaki T, Koivunen J, Ogino A, Yanagita M, Nikiforov S, Zheng W, Lathan C, Marcoux JP, Du J, Okuda K, *et al*: A novel ALK secondary mutation and EGFR signaling cause resistance to ALK kinase inhibitors. *Cancer Res* 71: 6051-6060, 2011.

4. Lovly CM, McDonald NT, Chen H, Ortiz-Cuaran S, Heukamp LC, Yan Y, Florin A, Ozretić L, Lim D, Wang L, *et al*: Rationale for co-targeting IGF-1R and ALK in ALK fusion-positive lung cancer. *Nat Med* 20: 1027-1034, 2014.
5. Fujita S, Masago K, Katakami N and Yatabe Y: Transformation to SCLC after treatment with the ALK inhibitor alectinib. *J Thorac Oncol* 11: e67-e72, 2016.
6. Ou SI, Lee TK, Young L, Fernandez-Rocha MY, Pavlick D, Schrock AB, Zhu VW, Milliken J, Ali SM and Gitlitz BJ: Dual occurrence of ALK G1202R solvent front mutation and small cell lung cancer transformation as resistance mechanisms to second generation ALK inhibitors without prior exposure to crizotinib. Pitfall of solely relying on liquid re-biopsy? *Lung Cancer* 106: 110-114, 2017.
7. Stieber P, Dienemann H, Schalhorn A, Schmitt UM, Reinmiedl J, Hofmann K and Yamaguchi K: Pro-gastrin-releasing peptide (ProGRP)-a useful marker in small cell lung carcinomas. *Anticancer Res* 19: 2673-2678, 1999.
8. Gainor JF, Dardaei L, Yoda S, Friboulet L, Leshchiner I, Katayama R, Dagogo-Jack I, Gadgeel S, Schultz K, Singh M, *et al*: Molecular mechanisms of resistance to first- and second-generation ALK inhibitors in ALK-rearranged lung cancer. *Cancer Discov* 6: 1118-1133, 2016.
9. Paweletz CP, Sacher AG, Raymond CK, Alden RS, O'Connell A, Mach SL, Kuang Y, Gandhi L, Kirschmeier P, English JM, *et al*: Bias-corrected targeted next-generation sequencing for rapid, multiplexed detection of actionable alterations in cell-free DNA from advanced lung cancer patients. *Clin Cancer Res* 22: 915-922, 2016.
10. Lodrini M, Sprüssel A, Astrahantseff K, Tiburtius D, Korschak R, Lode HN, Fischer M, Keilholz U, Eggert A and Deubzer HE: Using droplet digital PCR to analyze MYCN and ALK copy number in plasma from patients with neuroblastoma. *Oncotarget* 8: 85234-85251, 2017.
11. Johnson AC, Dô P, Richard N, Dubos C, Michels JJ, Bonneau J and Gervais R: Identification of I1171N resistance mutation in ALK-positive non-small-cell lung cancer tumor sample and circulating tumor DNA. *Lung Cancer* 99: 38-40, 2016.
12. Bordi P, Tiseo M, Rofi E, Petrini I, Restante G, Danesi R and Del Re M: Detection of ALK and KRAS mutations in circulating tumor DNA of patients with advanced ALK-positive NSCLC with disease progression during crizotinib treatment. *Clin Lung Cancer* 18: 692-697, 2017.



This work is licensed under a Creative Commons Attribution-NonCommercial-NoDerivatives 4.0 International (CC BY-NC-ND 4.0) License.