

# Cutaneous vasculitis in a patient with ankylosing spondylitis

## A case report

Chao Ye, PhD\*, Wenyuan Li, MD

### Abstract

**Rationale:** Cutaneous vasculitis is usually found in patients with rheumatoid arthritis (RA) as an extra-articular manifestation, but rare in patients with ankylosing spondylitis (AS). In this case, we describe an AS patient who developed large skin lesions, of which the histological findings were consistent with cutaneous vasculitis.

**Patient concerns:** A 22-year-old male who was diagnosed as HLA-27 positive AS for 5 years. However, in the last year, he suffered a recurrent skin lesion in both lower extremities especially the dorsum of feet, accompanying with intense pruritus.

**Diagnosis:** The originally diagnosis of the skin lessons was dermatitis, and then a skin biopsy pathology showed it was consistent with cutaneous vasculitis.

**Intervention:** At first he was treated with gentamycin and ethacridine for nearly 2 weeks, the symptoms were relieved. But then he suffered severe cutaneous lesions with swell at the ulcerous margin in his dorsum of right foot. The patient was treated with dexamethasone 10mg intravenous drip daily for 2 weeks, and followed by methylprednisolone 160mg oral administration daily after discharge. The skin lesions were gradually healed in several months

**Outcomes:** This patient was followed up at 1-month, 5-month, and 10-month after discharged, the skin lessons was gradually healed and never occurred.

**Lessons:** This case indicated that cutaneous vasculitis might be an extra-articular manifestation of AS in which IgA may plays a pathogenic part. All this may be associated with the damage of cytokines and autoantibodies to vascular endothelial wall caused by active inflammatory phase.

**Abbreviations:** AS = ankylosing spondylitis, HSP = Henoch-Schonlein purpura, LCV = leucocytoclastic vasculitis, MTX = methotrexate, TNFi = tumor necrosis factor  $\alpha$  inhibitor, TTP = thrombotic thrombocytopenic purpura.

**Keywords:** ankylosing spondylitis, cutaneous vasculitis, skin lesions

## 1. Introduction

Ankylosing spondylitis (AS) is a type of arthritis with long-term inflammation in the joints of spine. Since, AS is a systemic disease, the symptoms may not be limited to the joints. AS patient may also have fever, fatigue, loss of appetite, and other symptoms. For example, some AS patients have eye inflammation with symptoms of eye pain, redness, floaters, and sensitivity to light. Besides, some patients may have heart and lung symptoms.<sup>[1]</sup>

However, cutaneous lesions in AS is especially rare. Here we report a Chinese AS patient who developed large-area of cutaneous lesions in both lower extremities, especially in the skin of dorsum of feet.

This research project has been approved by the Ethics Committee of The First Affiliated Hospital of USTC with the approval number: P-002 and the consent were obtained from the patient for publication of this case report and accompanying images.

## 2. Case report

A 22 years old male was diagnosed with HLA-B27 positive AS in 2013. Pain and stiffness subsequently affected his thoracic and lumbar spine. The involvement of lumbar spine, sacroiliac, and hip joints were confirmed by X-ray and hips MRI. There was no bowel disease or psoriasis. The initially treatment was thalidomide and sulfasalazine. The pain of various joints could be alleviated by non-steroidal anti-inflammatory drugs (NSAIDs) including lornoxicam or celecoxib. Then he took etanercept, a tumor necrosis factor  $\alpha$  inhibitor (TNFi), 50mg weekly for 3 months. His regular medication was thalidomide 50mg daily, sulfasalazine 0.75g 3 times a day, celecoxib 0.2g twice a day. Stiffness and pain were controlled well. Last years, the patient suffered reversal skin ulceration in both lower extremities, especially in dorsum of feet, accompanying with intense pruritus. At first, the skin lessons diagnosed as dermatitis, after treated

Editor: N/A.

The authors have no conflicts of interest to disclose.

The First Affiliated Hospital of USTC, Division of Life Science and Medicine, University of Science and Technology of China, Hefei, Anhui, P.R. China.

\* Correspondence: Chao Ye, The First Affiliated Hospital of USTC, Division of Life Science and Medicine, University of Science and Technology of China, 17# Lujiang Road, Hefei, Anhui, 230001, R.P. China (e-mail: yechao850606@163.com).

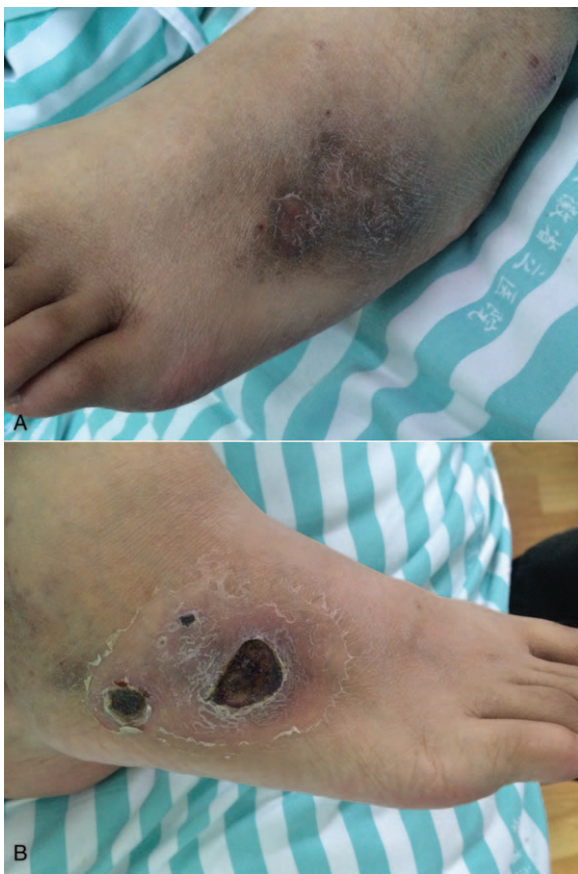Copyright © 2019 the Author(s). Published by Wolters Kluwer Health, Inc. This is an open access article distributed under the terms of the Creative Commons Attribution-Non Commercial-No Derivatives License 4.0 (CCBY-NC-ND), where it is permissible to download and share the work provided it is properly cited. The work cannot be changed in any way or used commercially without permission from the journal.

Medicine (2019) 98:3(e14121)

Received: 23 August 2018 / Received in final form: 9 December 2018 /

Accepted: 17 December 2018

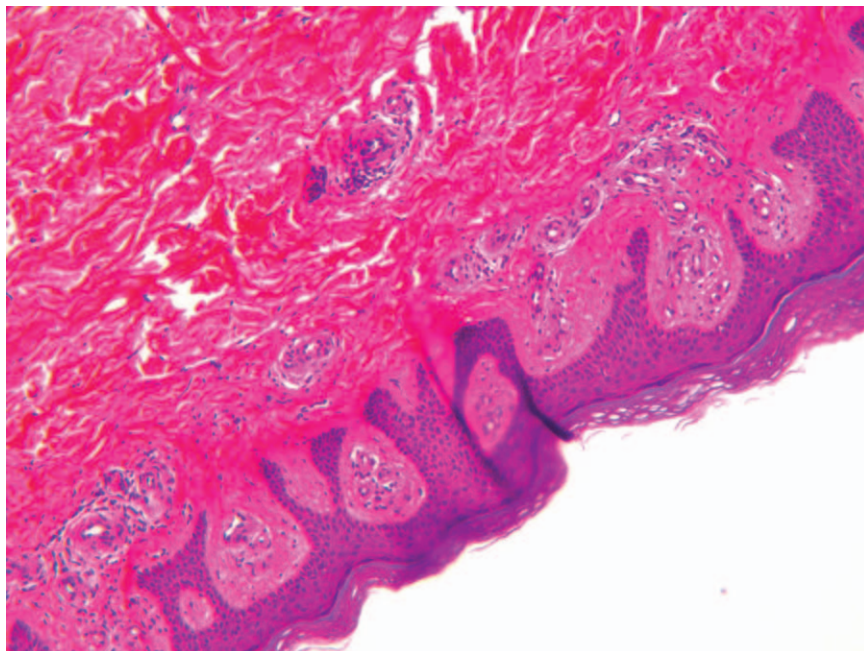
<http://dx.doi.org/10.1097/MD.00000000000014121>



**Figure 1.** A. Old healed lesions in the left dorsum foot; B. New-onset skin lesions located on the right dorsum foot.

with gentamycin and ethacridine, all those symptoms were relieved (Fig. 1A). However, nearly half a month later, severe cutaneous lesions relapsed in the dorsum of his right foot, which has a large area of skin ulceration with swelling at the ulcerous margin. He was hospitalized for these hard healing skin lesions (Fig. 1B). The upper limbs, trunk and face membranes were free of lesions, with no other complains in this patient. He once suffered from Henoch-Schonlein purpura (HSP) 13 years ago when he was 9. A daily 25 mg predison was used to treat him for couple of weeks. Then he recovered well and no clear anaphylactogen was found at that time.

Laboratory studies revealed a normal blood routine (leucocyte:  $3.96 \times 10^9/L$ , erythrocyte:  $5.21 \times 10^{12}/L$ , hemoglobin: 128 g/L, platelet:  $286 \times 10^9/L$ ) and liver and renal function (glutamic pyruvic transaminase: 18 IU/L, glutamic oxalacetic transaminase: 24 IU/L, serum urea nitrogen: 3.50 mmol/L, creatinine:  $49 \mu\text{mol}/L$ , Uric acid:  $417 \mu\text{mol}/L$ ). Streptolysin "O", rheumatoid factor, myeloperoxidase, and antinuclear antibodies were negative; Polyangiitis-antineutrophil cytoplasmic antibodies were weakly positive. The HLA-B27 antigen was present. The urine occult blood showed positive. The erythrocyte sedimentation rate was 21 mm/hour, C-reactive protein was 25.8 mg/L, procalcitonin  $<0.1$  ng/mol. The serum IgA level was 4.83 g/L, IgG level was 22.23 g/L. IgM, C3 and C4 serum levels were within normal ranges. Serological tests for hepatitis B, hepatitis C, and HIV also gave negative results. A skin biopsy pathology showed mild hyperplasia and hyperkeratosis of squamous epithelium, dermis with hyaline degeneration, local tiny vascular wall fibrous necrosis with focal neutrophils infiltrate, interstitial exudation of red blood cells, which are conforming to vasculitis (Fig. 2). The patient was treated with dexamethasone 10 mg intravenous drip daily for 2 weeks and followed by methylprednisolone 160 mg oral administration daily after discharge. Glucocorticoid was reduced gradually. We followed-up the patient at 1-month, 5-month, and 10-month after the discharge. One month later, the serum IgA level of the



**Figure 2.** Mild hyperplasia and hyperkeratosis of squamous epithelium, dermis with hyaline degeneration, local tiny vascular wall fibrous necrosis with focal neutrophils infiltrate, interstitial exudation of red blood cells, and pathological change conforming to vasculitis. (H&E stain).

patient was reduced to 3.75 g/L, C-reactive protein and erythrocyte sedimentation rate were within normal ranges, we stopped the glucocorticoid treatment, thalidomide, sulfasalazine, and celecoxib were ongoing used. Then we followed-up him at 5-month and 10-month after discharged, the skin lesions persisted for months then eventually healed, the serum IgA level, C-reactive protein, and erythrocyte sedimentation rate were all within normal ranges. The stiffness and pain were controlled well, and the cutaneous vasculitis was never recrudesced.

### 3. Discussion and conclusions

There were case reports of systemic vasculitis or arteritis in the literature of AS,<sup>[2,3]</sup> but cutaneous vasculitis of AS patients are rare in clinic. Most previous literatures were just reports of cases concerning AS with skin lesions like peliosis. Schlaifer reported immunologic thrombocytopenic purpura (ITP) in AS in 1990.<sup>[4]</sup> Pallot-Prade reported a case of thrombotic thrombocytopenic purpura (TTP) which revealed AS in 1993.<sup>[5]</sup> After 4-year follow-up, the spondylitis was still progressing in that patient, and TTP has not relapsed. The author argued that the relationship between AS and TTP is not clear. HSP in patients with AS is rare, only 2 cases of spontaneous occurrence were reported in 2 AS patients with IgA nephropathy and leucocytoclastic cutaneous vasculitis.<sup>[6]</sup> Since IgA was found in the skin by immunofluorescence in one of these patients, it is likely that IgA contributes to both skin and kidney lesions. Abnormal IgA was secreted in AS, perhaps through microbial antigenic stimulation of the digestive mucosa. In another case report, patients with spondylitis were associated with inflammatory bowel disease, the coincidence of IgA cutaneous vasculitis has also been described.<sup>[7]</sup> In our case, the patient had a medical history of HSP 13 years ago and then AS 5 years ago. HSP did not recur all these years, while the skin rash just happened last years. Whether there is any relationship between HSP and AS, and even the cutaneous vasculitis this time needs more investigation. Moreover, the patient also has a high serum level of IgA. It is reported that IgA levels are high during the active inflammatory phases of spondylitis,<sup>[8]</sup> and circulating IgA containing immune complexes may also be found in spondyloarthropathies.<sup>[9]</sup> In our case, the cutaneous vasculitis may also have a close relationship with IgA during pathogenic process.

With application of biologic agent and immunodepressive drug these years, there are researches about the skin lesions in AS induced by some biologic agents or immunodepressive drugs. In 2000, Borman<sup>[10]</sup> reported a case about low-dose methotrexate (MTX) induced vasculitis on patients with AS. The patient developed large atypical erythematous-purpuric cutaneous lesions which histologically proven vasculitis after the second oral dose of 7.5mg MTX therapy. After discontinuation of MTX treatment, the skin rash significantly regressed. Rolfe<sup>[11]</sup> described a patient with severe longstanding AS, who developed HSP after commencing therapy with etanercept. TNFi induced HSP was the most widely described in patients with rheumatoid arthritis (RA),<sup>[12]</sup> but was extremely rare in AS patients. TNFi may trigger the development of HSP by provoking immune dysregulation, especially the role of T regulatory cells which has been explored playing important role in the pathogenesis of HSP.<sup>[13]</sup> One report described a case of leucocytoclastic vasculitis (LCV) in the lower extremities after the treatment of golimumab.<sup>[14]</sup> The patient successively administrated with adalimumab 40mg/14days for 5 months and etanercept 50mg/week for 18 months and treated with golimumab 50mg/month 10 months

later due to lack of response. After the second dose, the patient developed skin lesions compatible with lower limb palpable purpura which confirming LCV by skin biopsy, and the skin lesion was resolved with golimumab discontinuation. A possible pathogenic mechanism of TNFi induced LCV has been postulated to be the direct drug toxicity to the vessel wall, and reactions mediated by cytokines which are associated with INF- $\gamma$  or IL-6 on vascular endothelial wall or induction of autoantibodies reactive with the endothelium.<sup>[15,16]</sup> In our case, the patient was treated with etanercept for 3 months, but the skin lesions arose 4 years later after discontinuation. So it seems that etanercept does no influence on the development of cutaneous vasculitis in this patient with AS.

Cutaneous lesions in AS is extremely rare, whether it is an extra-articular manifestation of AS has not been definitely concluded yet. In our case, the patient suffered from HSP when he was very young, but the performance of skin rash is not consistent with HSP. He was treated with etanercept before, but there seems no relationship between etanercept and vasculitis this time. To our knowledge, this is the first case to report such large area cutaneous lesions histologically proven vasculitis in patient with AS. Perhaps IgA may play a pathogenic part of vasculitis in patient with AS, and the skin lesion might also be associated with the damage of vascular endothelial wall by cytokines and autoantibodies caused by active inflammatory phase in AS patient. Cutaneous lesions may be an extra-articular manifestation of AS, while more cases and deeper investigations are needed.

### Acknowledgment

We are grateful to Professor Jinhui Tao and Zhi Yao for their assistance in disease treatment and pathological diagnosis. And genuinely appreciate Professor Wanyin Tao for his language supports on this manuscript.

### Author contributions

**Data curation:** Chao Ye.

**Methodology:** Chao Ye

**Supervision:** Wenyuan Li.

**Writing – original draft:** Wenyuan Li, Chao Ye

**Writing – review & editing:** Wenyuan Li, Chao Ye

Chao Ye orcid: 0000-0003-0740-7850.

### References

- [1] Sieper J, Braun J, Rudwaleit M, et al. Ankylosing spondylitis: an overview. *Ann Rheum Dis* 2002;61(suppl 3):iii8–18.
- [2] Ball GV, Hathaway B. Ankylosing spondylitis with widespread arteritis. *Arthritis Rheum* 1966;9:737–45.
- [3] Ferreiro Seoane JL, Gomez Rodriguez N, Formigo Rodriguez E, et al. The coexistence of rheumatoid arthritis, ankylosing spondylitis and intestinal necrotizing vasculitis. *An Med Interna* 1993;10:452–4.
- [4] Schlaifer D, Arlet P, Ollier S, et al. Immunologic thrombocytopenic purpura in ankylosing spondylitis. *Presse Med* 1990;19:525.
- [5] Pallot-Prades B, Benvenuto V, Riffat G, et al. Thrombotic thrombocytopenic purpura and ankylosing spondylarthritis. *Apropos of a case. Revue Med Interne* 1993;14:115–6.
- [6] Beauvais C, Kaplan G, Mougnot B, et al. Cutaneous vasculitis and IgA glomerulonephritis in ankylosing spondylitis. *Ann Rheum Dis* 1993;52:61–2.
- [7] Peeters AJ, van den Wall Bake AW, Daha MR, et al. Inflammatory bowel disease and ankylosing spondylitis associated with cutaneous vasculitis, glomerulonephritis, and circulating IgA immune complexes. *Ann Rheum Dis* 1990;49:638–40.
- [8] Cowling P, Ebringer R, Ebringer A. Association of inflammation with raised serum IgA in ankylosing spondylitis. *Ann Rheum Dis* 1980;39:545–9.

- [9] Deicher H, Ebringer A, Hildebrand S, et al. Circulating immune complexes in ankylosing spondylitis. *Br J Rheumatol* 1983;22(suppl 2):122–7.
- [10] Borman P, Bodur H, Gulec AT, et al. Atypical methotrexate dermatitis and vasculitis in a patient with ankylosing spondylitis. *Rheumatol Int* 2000;19:191–3.
- [11] Rolle AS, Zimmermann B, Poon SH. Etanercept-induced Henoch-Schonlein purpura in a patient with ankylosing spondylitis. *J Clin Rheumatol Pract Rep Rheum Musculoskeletal Dis* 2013;19:90–3.
- [12] Asahina A, Ohshima N, Nakayama H, et al. Henoch-Schonlein purpura in a patient with rheumatoid arthritis receiving etanercept. *Eur J Dermatol: EJD* 2010;20:521–2.
- [13] Li YY, Li CR, Wang GB, et al. Investigation of the change in CD4(+) T cell subset in children with Henoch-Schonlein purpura. *Rheumatol Int* 2012;32:3785–92.
- [14] Pamies A, Castro S, Poveda MJ, et al. Leucocytoclastic vasculitis associated with golimumab. *Rheumatology* 2013;52:1921–3.
- [15] Mohan N, Edwards ET, Cupps TR, et al. Leukocytoclastic vasculitis associated with tumor necrosis factor-alpha blocking agents. *J Rheumatol* 2004;31:1955–8.
- [16] Guillevin L, Mouthon L. Tumor necrosis factor-alpha blockade and the risk of vasculitis. *J Rheumatol* 2004;31:1885–7.