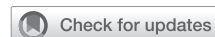

# Percutaneous dilatational tracheostomy guided by rigid bronchoscopy in patients with cervical mass



Alfonso Fiorelli, MD, PhD,<sup>a</sup> Beatrice Leonardi, MD,<sup>a</sup> Fausto Ferraro, MD,<sup>b</sup> Giovanni Liguori, MD,<sup>c</sup> Massimo Ciaravola, MD,<sup>b</sup> Giuseppe Vicario, MD,<sup>a</sup> and Giovanni Natale, MD,<sup>a</sup> Naples, Italy

From the <sup>a</sup>Department of Translational Medicine, Thoracic Surgery Unit and <sup>b</sup>Department of Women, Child, and General and Specialized Surgery, Anesthesiology and Intensive Care Unit, University of Campania Luigi Vanvitelli, Naples, Italy; and <sup>c</sup>Department of Emergency, Anesthesiology and Intensive Care Unit, Cardarelli Hospital, Naples, Italy.

Received for publication Jan 1, 2024; revisions received Jan 23, 2024; accepted for publication Jan 24, 2024; available ahead of print Feb 17, 2024.

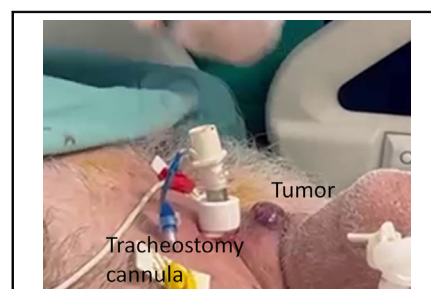
Address for reprints: Alfonso Fiorelli, MD, PhD, Thoracic Surgery Unit, Università della Campania Luigi Vanvitelli, Piazza Miraglia, 2, Naples, I-80138, Italy (E-mail: [alfonso.fiorelli@unicampania.it](mailto:alfonso.fiorelli@unicampania.it)).

JTCVS Techniques 2024;24:222-4

2666-2507

Copyright © 2024 The Author(s). Published by Elsevier Inc. on behalf of The American Association for Thoracic Surgery. This is an open access article under the CC BY-NC-ND license (<http://creativecommons.org/licenses/by-nc-nd/4.0/>).

<https://doi.org/10.1016/j.jtc.2024.01.027>



Tracheostomy cannula and tumor.

## CENTRAL MESSAGE

In intubated patients with airway obstruction caused by cervical mass, the use of RB rather than FB could facilitate the execution of PDT due to better visibility and higher suction capacity.

▶ Video clip is available online.

Percutaneous dilatational tracheostomy (PDT) guided by a flexible bronchoscope (FB) is the procedure of choice for performing elective tracheostomy in critically ill patients.<sup>1</sup> However, this procedure may be challenging in patients with difficult airway. Herein, we report the use of a rigid bronchoscope (RB) for performing PDT in intubated patients with tracheal stenosis due to a cervical mass.

## TECHNIQUE

The procedure was performed in the operating room under general anesthesia. An 8.5-mm outer diameter RB was introduced and advanced through the vocal cords (Figure 1, A) into the larynx (Figure 1, B) alongside the indwelling endotracheal tube. The balloon cuff of the endotracheal tube was deflated under endoscopic vision (Figure 1, C), the tube was removed as the RB was carefully advanced into the trachea (Figure 1, D). Jet ventilation through the RB provided ventilation. The RB forced the stenosis and reopened the airway; then, the tip of the RB was positioned proximally to the stenosis and guided the PDT. The trachea was accessed with a 17-gauge needle (Figure 2, A) and then a guide wire was inserted. The punch dilator introduced over the guide wire dilated the tracheal stoma (Figure 1, B) and then the tracheostomy tube was introduced after the dilation (Figure 1, C). Finally, an FB was introduced through the tracheostomy and adjusted the length of the tracheostomy to

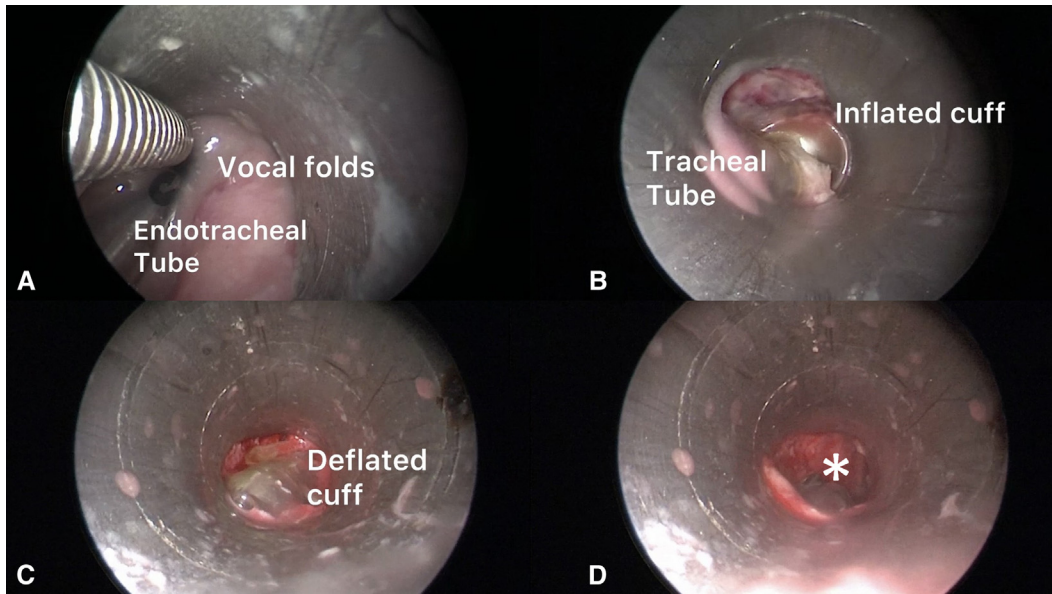
compensate for the size of the tumor. The patient was ventilated through the tracheostomy tube and the RB was withdrawn (Figure 1, D). Video 1 summarizes the procedure.

## PATIENTS

This procedure was performed in 3 consecutive patients with airway stenosis due to cervical mass. In 2 cases, the mass was malignant and involved the local structure of the neck, including the skin. All patients underwent emergency intubation due to acute respiratory distress and elective tracheostomy was indicated to facilitate weaning from the ventilator. No complications occurred during the PDT procedure. The patients' informed written consent for the publication of the study data was obtained; institutional review board approval was not required.

## DISCUSSION

In our cases, tracheostomy was indicated to facilitate the weaning from the ventilator and to ensure ventilation. The presence of cervical mass discouraged us to perform an open tracheostomy because it could result in more blood loss than PDT. Furthermore, the presence of a distorted airway let us use an RB instead of an FB for guiding

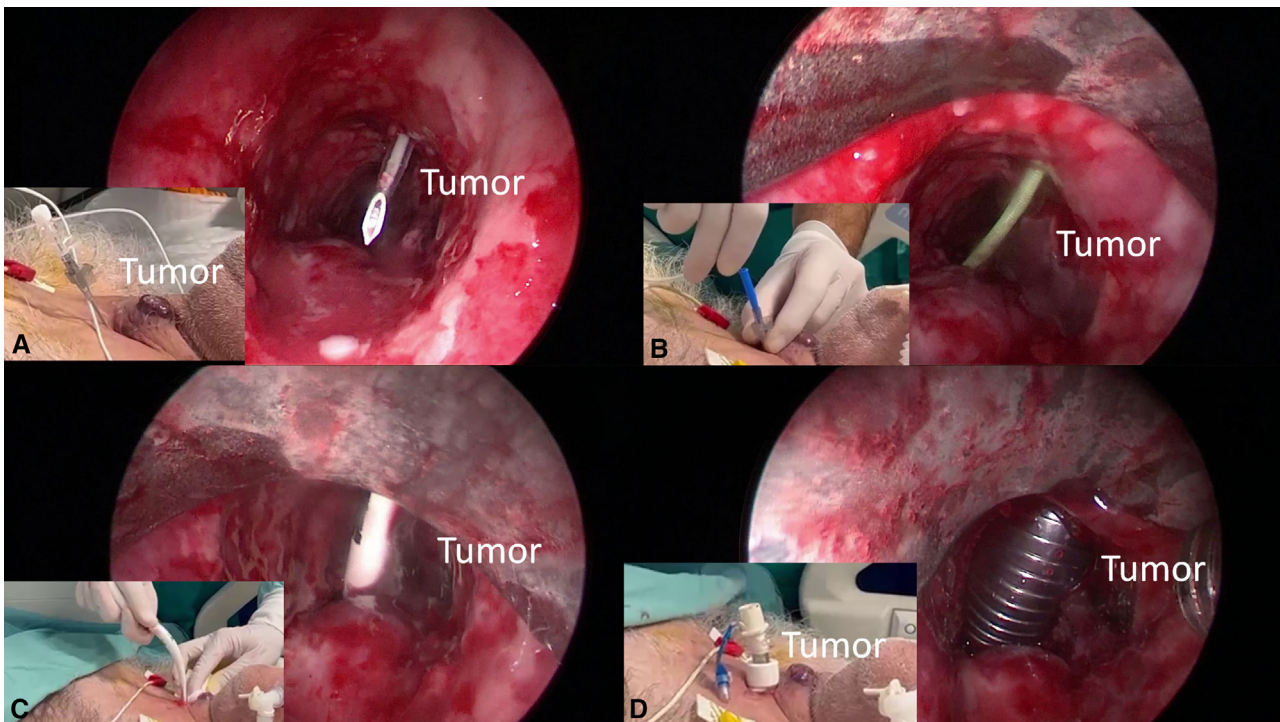


**FIGURE 1.** The picture showed the insertion of rigid bronchoscope (RB) alongside the endotracheal tube through the vocal cords (A); the place of RB within subglottic area (B); the deflation of the cuff of the endotracheal tube (C); and the withdrawal of the endotracheal tube (D).

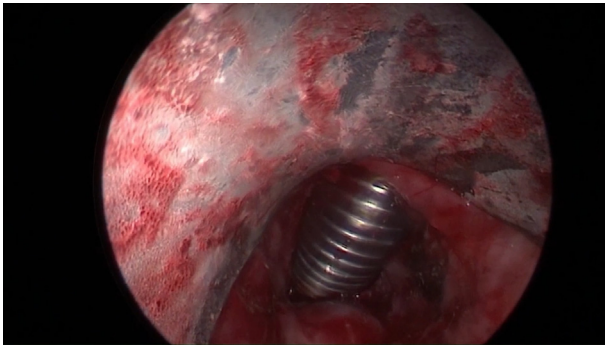
PDT. Several authors<sup>1-5</sup> have performed PDT guided by an RB in patients with difficult airway due to obesity, previous tracheostomy, and/or radiotherapy, and existing tracheal stents and/or in those with high risk of bleeding for coagulopathy, but airway stenosis due to cervical

mass was still considered a criterion of exclusion for PDT so far.

RB could offer many advantages over FB. First, the better visibility and higher suction capacity allowed an effective control of intratracheal bleeding in case of tumor lesion.



**FIGURE 2.** The pictures and the inserts summarized the main manoeuvres of percutaneous dilatational tracheostomy (PDT) guided by rigid bronchoscope as the insertion of needle (A), of guidewire (B); of dilator (C), and of tracheostomy cannula (D).



**VIDEO 1.** The video edited the main steps of the percutaneous dilatational tracheostomy (PDT) guided by rigid bronchoscopy as the removal of the orotracheal tube and the insertion of rigid bronchoscope and the PDT guided by rigid bronchoscopy. Video available at: [https://www.jtcvs.org/article/S2666-2507\(24\)00059-2/fulltext](https://www.jtcvs.org/article/S2666-2507(24)00059-2/fulltext).

During PDT, the tip of the RB lifted the trachea anteriorly and provided a natural abutment to the pressure from the dilatation, avoiding the downward force necessary for dilatation that could damage the tumor. In case of acute hypoxia, the progression of the RB toward the carina forced the stenosis, reopened the airway, and ensured ventilation. Endoscopic forceps can overcome some troubles of the procedure, such as kinking of the guide wire due to the distorted airway.

The main limitation of this procedure was the removal of a secure airway to place the RB, which could result in loss of airway. To avoid this critical situation, we suggest using an RB of small size that can pass alongside the tracheal tube

through the vocal folds. The patient was not extubated until the RB was in the laryngeal inlet.

Obviously, this technique should be considered as an adjunct to the standard strategies for performing tracheostomy and indicated in very selected patients who are considered at high risk for standard PDT procedure. Considering the small number of patients, the feasibility of our approach should be corroborated by other, and larger, experiences.

### Conflict of Interest Statement

The authors reported no conflicts of interest.

The *Journal* policy requires editors and reviewers to disclose conflicts of interest and to decline handling manuscripts for which they may have a conflict of interest. The editors and reviewers of this article have no conflicts of interest.

### References

1. Grigo AS, Hall ND, Crerar-Gilbert AJ, Madden BP. Rigid bronchoscopy-guided percutaneous tracheostomy. *Br J Anaesth.* 2005;95(3):417-419.
2. Majid A, Cheng GZ, Kent MS, Gangadharan SP, Whyte R, Folch E. Evaluation of rigid bronchoscopy-guided percutaneous dilatational tracheostomy. A pilot study. *Ann Am Thorac Soc.* 2014;11(5):789-794.
3. Moulin M, Aboussouan MP, Castellanos PF, Atallah I. Evaluation of percutaneous dilatational tracheostomy under laryngosuspension. *Eur Arch Otorhinolaryngol.* 2020;277(12):3391-3396.
4. Nowak A, Kern P, Koscielny S, et al. Feasibility and safety of dilatational tracheostomy using the rigid endoscope: a multicenter study. *BMC Anesthesiol.* 2017; 17(1):7.
5. Fiorelli A, Messina G, Santini M, Ferraro F. Percutaneous dilation tracheostomy in a patient with tracheal stent. *Interact Cardiovasc Thorac Surg.* 2021;33(4): 654-656.