

# New autopsy technique in COVID-19 positive dead bodies: opening the thoracic cavity with an outlook to reduce aerosol spread

Somnath Das ,<sup>1</sup> Anshuman Roy,<sup>2</sup> Rina Das<sup>3</sup>

► Additional supplemental material is published online only. To view, please visit the journal online (<http://dx.doi.org/10.1136/jclinpath-2022-208173>).

<sup>1</sup>Forensic Medicine and Toxicology, RG Kar Medical College, Kolkata, West Bengal, India

<sup>2</sup>Anatomy, Raiganj Government Medical College, Raiganj, West Bengal, India

<sup>3</sup>Forensic Medicine and Toxicology, NRS Medical College, Kolkata, West Bengal, India

## Correspondence to

Dr Somnath Das, Forensic Medicine and Toxicology, RG Kar Medical College, Kolkata, WB 700004, India; [somnath1976@rediffmail.com](mailto:somnath1976@rediffmail.com)

Received 20 January 2022

Accepted 20 May 2022

## ABSTRACT

**Aims** After the advent of the COVID-19 pandemic, most countries have modified some of their health-related regulations. However, this has not been in the case of the postmortem of deceased because it has a legal aspect. Thus, the healthcare providers knowingly or unknowingly faced the threat of COVID-19 exposure from those dead bodies. To introduce an autopsy technique that reduces the droplet spreads, especially in those mortuaries where the biosafety mechanism is not highly equipped.

**Methods** The validity of the new incision was achieved through the calculation of the Scale Content Validity Index (SCVI) taking inputs from 17 forensic specialists. The subjects for the new technique were selected from the patients who were RTPCR positive for COVID-19 or clinically or radiologically showing features of COVID-19.

**Results** The dissection procedure was finalised by achieving the SCVI at 0.92. The chest cavity was approached through the abdominal cavity by opening the diaphragm and dissecting out the contents of the chest using a long blade knife.

**Conclusions** The advantage of this approach is that the autopsy surgeon and pathologists do not have to open the chest cavity by dissecting the Sternum, and hence the chance of droplet infection becomes almost nil. This technique is complete, simple, less time-consuming and conducive for sample collection, and even reduces the possibility of body fluid seepage following a postmortem examination

## INTRODUCTION

The new coronavirus SARS-CoV-2, an agent of the severe acute respiratory syndrome pandemic, a combination of the acute respiratory syndrome and multiorgan syndrome, after its appearance in Wuhan in China at the end of 2019, caused more than five million deaths worldwide to date.<sup>1,2</sup> In January 2020, WHO reported this outbreak, and the virus was later named as 2019 novel coronavirus or COVID-19.<sup>3</sup> It is a successor of SARS-CoV-1 of 2002–2004.<sup>4</sup> Corona virus is classified in the orthocoronaviridae subfamily and is present in humans and many animals. It is a single-stranded RNA virus with positive polarity. The first coronavirus was isolated from chicken embryos in 1937 called the infectious bronchitis virus. SARS-CoV-2 is believed to have zoonotic origins and has a close similarity to bat coronaviruses.<sup>5,6</sup>

Since the beginning of the pandemic SARS-CoV-2 has been accepted as a pathogen classified among the hazard group 3 representing a significant

## WHAT IS ALREADY KNOWN ON THIS TOPIC

- ⇒ Pathological or Medico-legal autopsies have been the cornerstone for the determination of pathogenesis of unknown diseases.
- ⇒ Asymptomatic cases in COVID-19 posed a threat for the forensic and clinical pathologists throughout the world for aerosol infections especially in those mortuaries which are not highly equipped.

## WHAT THIS STUDY ADDS

- ⇒ The study describes a new method of dissecting the organs of the chest cavity approached through the abdominal cavity by opening the diaphragm during the Autopsy of COVID-19 positive cases validated by Scale Content Validity Index.

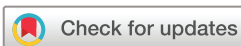## HOW THIS STUDY MIGHT AFFECT RESEARCH, PRACTICE AND/OR POLICY

- ⇒ The abdominal approach of thoracic organ dissection can be an essential autopsy technique for all bodies with a suspected lung infection to reduce droplet spread.

risk for those who come into contact with it and have a high propensity for man to man transmission.<sup>7</sup> Throughout this time, there is no authenticated evidence that the COVID-19 virus does not spread through these dead bodies, and hence people coming in contact with COVID-19 positive corpses are expected to adhere to strict biosafety measures.<sup>8</sup>

The pathophysiology of this disease is still not known entirely; the spread of the virus usually occurs through coughing and sneezing and has its maximum concentration in the entire respiratory tract, to be more specific, in the lungs.<sup>9</sup> The rapid spread of this virus created an alarm throughout the countries. The case fatality also increased at the same rate. A whole lot of these patients were brought dead in hospital emergencies.<sup>10</sup> As per the regulations in most countries, these cases were treated as unnatural deaths and had to undergo postmortem examination.<sup>11</sup> The natural history of COVID-19 virus infection shows that majority of the cases are asymptomatic. So, those cases which were unrelated to any disease process but died due to any other unnatural cause like hanging, drowning, strangulation, etc, were incidentally also found to be COVID-19 positive.

Hence health professionals, mortuary personnel, coroners and pathologists who work in autopsy



© Author(s) (or their employer(s)) 2022. No commercial re-use. See rights and permissions. Published by BMJ.

**To cite:** Das S, Roy A, Das R. *J Clin Pathol* Epub ahead of print: [please include Day Month Year]. doi:10.1136/jclinpath-2022-208173

rooms face daily challenges while approaching probable, suspected or confirmed death cases of SARS-CoV-2 infection.<sup>11</sup>

It is a fact that most low-income and middle-income countries that were not having highly equipped mortuaries for the dissection of these infected dead bodies found it challenging to deal with these cases.<sup>12</sup> Though almost all the health regulatory organisations have issued guidelines for the procedure and selecting cases for autopsy,<sup>13–15</sup> it was almost impossible to differentiate between the asymptomatic and asymptomatic cases in the autopsy room.

To protect the mortuary staff and avoid risky procedures such as dissection, clinical and forensic autopsies around the world have been significantly reduced or not performed at all. In fact, to date little is known about the behaviour of the COVID-19 virus after the death of the human host and it is not known with certainty how long it can be detected in body fluids.

Naturally, the best possible way to deal with these dead bodies was to find out a method of dissection where the droplet spread is at a minimum.

### The conventional methods of doing a postmortem

Conventionally, there are three basic types of incisions for opening the neck, thorax and abdomen of an individual.<sup>16–21</sup>

The 'I' incision—Starts from symphysis menti and moves down to symphysis pubis encircling the umbilicus.

The 'Y' incision—Starts from the tip of the acromion process of either side, extending downward up to the xiphoid process encircling the lower border of the breast. It then extends below up to the symphysis pubis.

The modified 'Y' incision—Starts from the mastoid process of either side, extends up to the midpoint of the clavicle, then from there, moves almost horizontally up to the sternal notch. The incision then travels vertically downward up to symphysis pubis.

The skin and subcutaneous tissues are reflected, following which the chest and abdominal cavities are opened in all these cases. The conventional method of opening the chest cavity is to cut through the costochondral junction from the second intercostal space and remove the anterior chest shield by cutting through the sternoclavicular joint of either side.<sup>16–19</sup> Rib shears or saws are used to cut through these junctions, especially among the olds where the costochondral junction has been ossified. The ribs or costal cartilages can also be incised using a long-bladed serrated knife (breadknife) or with an oscillating saw. These methods all have advantages and disadvantages. Rib shears may leave splintered edges to the ribs, creating a sharps hazard. Using a breadknife produces smooth edges, but risks incising the underlying lung/liver. An oscillating saw (with a fantail blade) also produces smooth edges, but risks aerosolising underlying pleural fluid.

This process of dissection of the lungs and large airways by opening the thoracic cavity is an area of extreme concern while dealing with death cases due to respiratory viruses like COVID-19. Eventually, the forensic medicine experts and the entire mortuary staff become susceptible to these aerosols.<sup>22 23</sup> Opening the skull bone also results in the spread of infection. However, using a vacuum saw can somewhat reduce the chance of aerosol spread but only to a certain extent.<sup>23</sup>

The standard method for detecting COVID-19 infection is the RT-PCR test or rapid antigen test, both of which have their limitations in detecting the COVID-19 positive cases.<sup>24</sup> Hence, not only among the asymptomatic cases but also in those cases where the test is negative, infection spread is possible even in a well-protected and well-performed postmortem examination.

Using a personal protective equipment (PPE) kit for all these cases is ideal but not foolproof.<sup>25</sup>

So it became essential to find a new method of dissection of dead bodies, especially the approach to the thoracic part, which will reduce the aerosol spread to the minimum. To do so, the author, with his team members, made some modifications to the existing incisions while performing a complete post-mortem on these infected bodies.

### MATERIAL AND METHOD: VALIDATION AND FORMULATION OF A NEW INCISION FOR AUTOPSY ON COVID-19 POSITIVE DEAD BODIES

The validity of the method of dissection was made based on the item Content Validity Index (CVI). Content validity is defined as the degree to which elements of an assessment instrument are relevant to and representative of the targeted construct for a particular assessment purpose.<sup>26</sup> The steps of content validation include preparation of a form, selection of a panel of experts, conducting the content validation, reviewing the items, providing a score on each item, and finally calculating the CVI.<sup>26</sup> The Scale CVI (SCVI) was computed on the method of averages of the item-level CVIs.<sup>26</sup>

A group of 17 forensic medicine specialists was chosen and requested to judge the content validity index twice for each item. They were given a structured format containing different Items of dissection (online supplemental table 1). Label—Items of Validation with scoring) with full elaboration in a separate sheet, which has to be marked on a scale of 1–4.

1. Not appropriate.
2. Somewhat appropriate (items require major revision).
3. Almost appropriate (items required minor modification).
4. Appropriate.

All rounds of correspondence were made via email or in person.

Those items which required revisions were modified accordingly (online supplemental table 2, label-details of the modifications done following the recommendation of the expert group in final round) following discussion with the panellists.

### RESULTS

After the first round, 4 out of 10 items (whose ICV score was less than 0.8) were modified. Among them, items 3, 5, 8 and 10 were rewritten and sent for the second round of review.

In the second round, the panellists again were requested to judge the items by scoring 1–4 on their appropriateness. After calculation, the CVI of each item was achieved between 0.8 and 1. The SCVI (proportion of items on the instrument that achieved a rating of 3 or 4 by the experts) was found to be at 0.92.

### The new incision for autopsy on COVID-19 positive dead bodies

The entire process of the dissection method was formulated in three stages. In the first stage, 13 autopsies were conducted to outline the steps of dissection to be put forward to the 17 forensic experts for the first round of evaluation. Next, another 12 autopsies were performed according to the recommendations made by the panellists' experts. In both these cases, the dead bodies were chosen from the patients who had no symptoms of COVID-19 infection. Finally, when the steps were validated by the experts, 25 postmortems were performed on the dead bodies that either were positive for COVID-19 infection (by RTPCR test) or had symptoms likely to be of COVID-19 (not positive at the time of postmortem, but were diagnosed to be positive form

the samples collected during autopsy). Those cases that showed negative RTPCR reports were excluded from the study. The sample sizes of 25 cases were selected considering the fatality rate in COVID-19 in India to be 1.5 using online sample size calculators with an additional 10% more, considering the probability of non-responsiveness. The period of the study was from the last quarter of 2020 to the first quarter of 2021. Contributing diagnosis was obtained from death certificates, RT-PCR reports and CT scan reports. Informed consent was taken from the next of kin for all these cases.

## Preparatory phase

### Personnel

A minimum number of people were engaged in the autopsy team. In addition, a record of the names and activities of all members participating in the procedure was maintained.

### Workstation

The body was placed on a well-disinfected dissection table with proper waste containment and drainage features to minimise body fluids and wastewater spills. All cutting edges in the working area were identified beforehand to reduce the risk of injury to the members. Hand hygiene facilities were readily available at the point of use and next to the PPE donning and doffing area.

### Precaution

Every member donned complete personal protective equipment, N95 respirator and eye-protecting goggles for COVID-19 autopsies, and work hygiene was maintained according to the prescribed protocols to avoid contamination and the spread of the virus.

#### Instruments

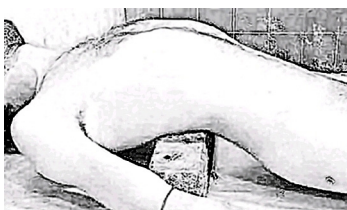- ▶ Scalpel: Detachable handle (No 4) and blade (No 20).
- ▶ Plain non-toothed forceps.
- ▶ Scissors.
- ▶ Long blade knife (brain knife).
- ▶ Retractor (if required).
- ▶ Large surgical mops or surgical gauze.

Round-ended scissors and blades with blunt tips were used to reduce the risk of prick injuries. All needles, syringes and other contaminated sharp edges were handled cautiously and disposed of in appropriate puncture-proof labelled containers. All aerosol generating procedures for confirmed or suspected COVID-19 cases were avoided. The use of water was minimised to avoid any aerosol formation during an autopsy. New scissors and fresh scalpels were used wherever necessary to avoid cross-contamination.

## Approach to dissection and autopsy technique

### Cadaveric inspection and position

The body was placed on top of the dissecting table in a supine position with a wooden block placed under the Lumbar vertebra so that the thoracic part is extended backward, making the



**Figure 1** Positioning of the body.

xiphoid process more prominent (figure 1). During preparation, the body was inspected for scars/deformities of the chest/abdominal wall. Abnormalities reported under extrapulmonary manifestations of COVID-19, such as signs of conjunctival congestion, oedema, and conjunctivitis, and dermatological manifestations, like maculopapular/erythematous/exanthematous rashes, vesicular lesions, petechiae vesicles, and/or necrotic lesions in varying severity of the disease were noted.

### Identification of anatomical landmarks

The following anatomical landmarks were identified for delineation of incision lines.

1. Xiphisternal joint.
2. Lower costal margin.
3. Umbilicus.
4. Linea alba.
5. Linea semilunaris.
6. Symphysis pubis.

### Incision

The extent of the incision was planned so that a singular approach presents an adequate exposure with flexibility.

The autopsy technique was initiated by an upper midline scalpel incision of the skin along the axis of the linea alba. The incision line started from the xiphoid process and was continued inferiorly in the midline encircling the umbilicus. Abdominal exposure was facilitated by extending the incision up to the symphysis pubis (figure 2). The umbilicus may be retracted away from the midline using a clamp to keep the incision vertically straight in certain instances.

The incision was deepened through the subcutaneous tissue and superficial fascial layers (figure 3) and dissected through the aponeurotic components of the rectus sheath exclusive of any muscular intervention (figure 4). Sometimes part of the rectus abdominis and medial part of internal oblique muscles can be incised to get better exposure.

Neck structures were dissected by reflecting the skin using the conventional modified 'Y' incision extending up to the suprasternal notch.

### Approach to the abdominal cavity

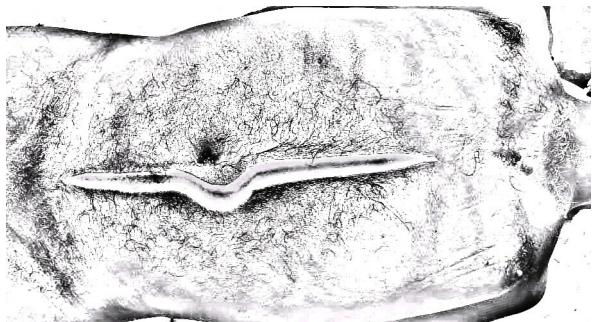The skin and tissue flaps were reflected, and the remnants of the anterior abdominal wall were turned down to identify the peritoneum. The peritoneal cavity was opened with an incision similar to the skin incision and reflected with the anterior abdominal wall, taking care to avoid damage to the peritoneum or the structures covered by it.

The fold of the peritoneum from the median part of the supra-umbilical anterior abdominal wall to the liver was cut. The peritoneum was also uncovered from the posterior surface of the infraumbilical abdominal wall.

Inspection of the peritoneal cavity and the abdominal organs were performed *in situ* before proceeding further (figure 5). All the abdominal organs were examined for evidence of infection, inflammation, congestion, haemorrhages, patchy necrotic areas or other conditions. The presence of blood, bile or other fluids surrounding the abdominal organs was also noted. If required, large surgical mops or surgical gauze mops can be used to keep the intestine away from the dissection field.

After inspection of the abdominal cavity, a hand was passed upwards over the anterior surface of the stomach to identify the fundus and the oesophagus. Next, the liver was pulled superiorly, and the inferior margin tilted upwards to expose the lesser





**Figure 2** Skin incision from the xiphoid process to the symphysis pubis encircling the umbilicus.

omentum and trace the lesser curvature of the stomach downwards. Next, the stomach and the vascular attachments were cut and turned to the left to expose the lesser sac. Finally, the peritoneum was removed as far inferiorly as the attachment of the greater omentum. All other abdominal organs were dissected as per the conventional method.<sup>16-20</sup>

Next, the anterior layers of the coronary and left triangular ligaments, the hepatic veins entering the inferior vena cava and the remaining peritoneal connections of the liver to the diaphragm were separated to disengage the liver downwards from the inferior vena cava.

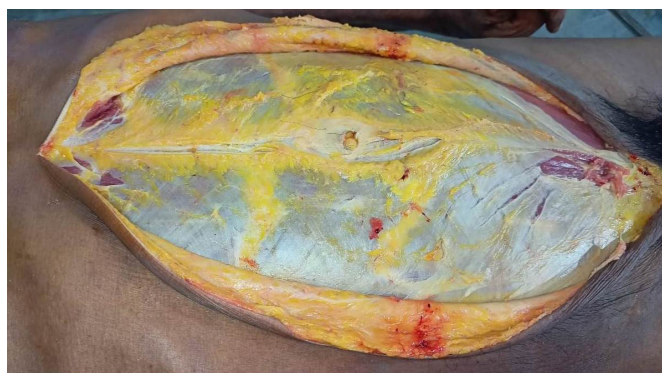#### Approach to the thoracic cavity

The inferior part of the sternal plate was gently elevated and upturned with the costal cartilages and anterior parts of the ribs. If required, the sternum and ribcage can be retracted by manual traction with retractors (figure 6).

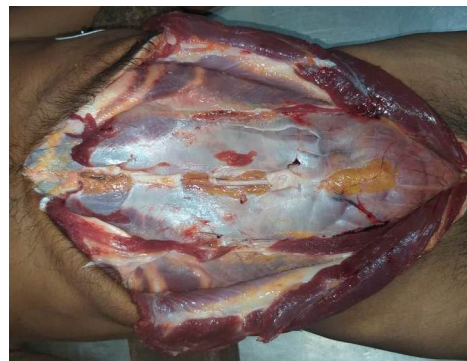As the sternum was lifted, the membranous attachments were cut close to the midline, along the line of pleural reflection from the sternum onto the mediastinum. The pleura and fascia were removed from the back of the sternum and the superior surface of the exposed part of the diaphragm. The attachments of the diaphragm to the xiphoid process and costal cartilages were noted and divided as necessary.

The slips of origin of the diaphragm were cut through from the internal surface of the lower six costal cartilages in front of the mid-axillary line. The diaphragm was made free from its lateral and posterior attachments as far as possible to expose the thoracic cavity.

Once access was gained into the thoracic cavity, the heart and lungs were separated from the remaining parts of the mediastinum. The lung was pulled laterally from the mediastinum to



**Figure 3** Skin incision deep through the subcutaneous tissue and fascial layers.



**Figure 4** After removal of rectus abdominis, peritoneum intact.

expose and cut through the root and pulmonary ligament from above downwards close to the lung using a long blade knife. The lung was removed on each side and stored in a plastic bag to prevent it from drying. The heart was grossly examined for pathological changes, particularly for the pericardium and dilatation changes, and was finally removed.

#### Collection of samples

While collecting samples of pleural fluid or pericardial fluid, the wooden block can be shifted between the intra scapular space, and a long needle syringe can be used to collect pleural fluid from the costophrenic recess piercing the lateral aspect of the diaphragm.

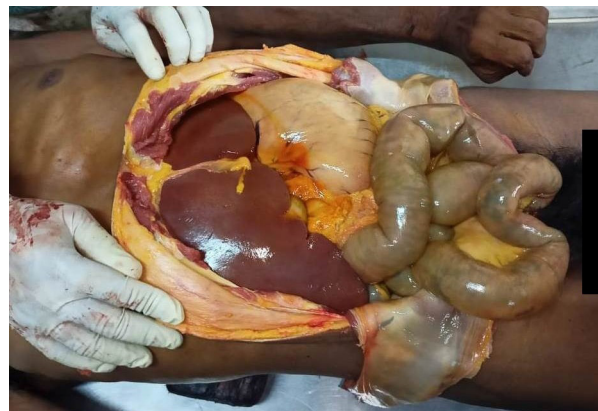
Pericardial fluid can be collected easily before or after the removal of the diaphragm.

#### Closure

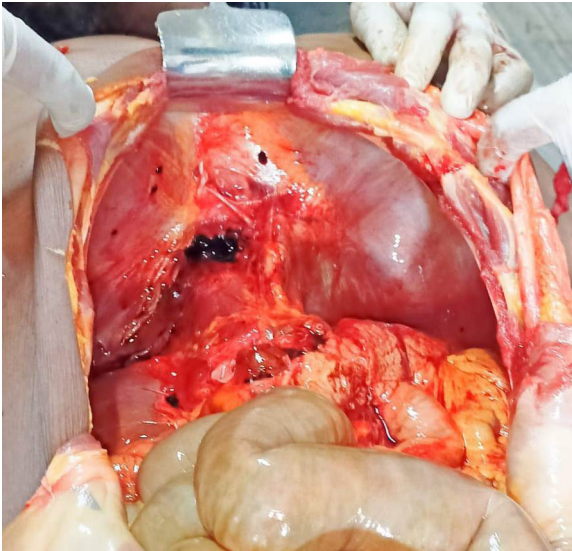
On completing the procedure, the abdominal wall layers were sutured in reverse order, and the skin incision was stitched closed.

Specimens were secured adequately according to prescribed guidelines and placed in an appropriately labelled leak-proof specimen bag with proper disinfection. Samples for histopathological examination were fixed in 4% buffered formalin/10% natural buffered formalin.

The PPE was discarded in the appropriate waste laundry. Reusable goggles and shields were cleaned and disinfected according to recommendations. Following that, hands were cleaned with soap and water before using alcohol-based hand sanitiser. Finally, the table, the instruments and the skin of the corpse were appropriately disinfected.



**Figure 5** Abdominal organs after removal of peritoneum.



**Figure 6** Inferior surface of the diaphragm after removal of subdiaphragmatic organs.

## DISCUSSION

It is unknown whether the COVID-19 virus remains active after the human host has died. It has been found that the SARS virus can be detected in the lungs and small intestine of the dead individual until 90–175 hours after death.<sup>27</sup> Post mortem study on COVID-19 through a nasopharyngeal and oropharyngeal swab shows that virus could still be detected 27 hours after death. Whether the bodily fluids pose an infection risk when the virus can be detected, is unknown.<sup>28</sup>

There are many guidelines on the handling of subjects who died due to COVID-19. Most of them are a replication of WHO guidelines on the safe handling of dead bodies, whereas others believe that dead bodies are to be handled as per the guidelines based on SARS/MERS.<sup>29</sup> Hence the recommended procedures for COVID-19 autopsy are diverse. As the BSL-3 autopsy facility is not available in middle and low-resource settings, in the practical field, whenever there is a community spread of the virus, a suspected positive COVID-19 corpse should be handled the same way as a positive COVID-19 case.<sup>29</sup>

Postmortem investigation rates remain scarce worldwide as do scientific contributions and, in this regard, reluctance to perform autopsies based on fear of disease transmission, lack of adequate facilities and strict procedures and regulations imposed by governments have been defined by the scientific community as the ‘lockdown of science’. Cultural barriers and the reluctance of families to provide informed consent are additional factors contributing to the decline in autopsy numbers.<sup>30</sup>

At the same time, several countries have modified their initial recommendations, recognising the gold standard of a complete autopsy—both macroscopic and microscopic—in controlling the COVID-19 pandemic, although having their own rules regarding the health emergency. However, to date, several important concerns have not been clarified to encourage the continued use of autopsies, and consequently post mortem examinations when performed, have become minimally invasive sampling of lung microfragments only, performing needle biopsies of different organs—lung, liver, kidney and heart.

Due to the COVID-19 pandemic, some countries have decided not to allow complete autopsies, as a complete autopsy is frequently not feasible in highly transmissible diseases due to biohazard challenges.<sup>31</sup> Thus, the minimally invasive autopsy

(MIA) has emerged as a validated and safe innovative, and alternative method to conventional autopsy for use in low-income settings, where the lack of infrastructure and human resources persists.

MIA, also known as minimally invasive tissue sampling, is a simple, systematic and standardised needle-based postmortem examination. It has easy technical applicability even with any supplementary sophisticated image-based technique to guide the sampling,<sup>32</sup> aimed at collecting fluids (blood, cerebrospinal fluid, effusions) and cores of tissue from the key, highly informative organs such as the lungs, liver, brain and heart.<sup>31 32</sup> Several other organs viz. kidney, spleen, bone marrow, liver, pancreas, stomach, intestine, thyroid and skin have also been studied.<sup>33</sup> These samples are analysed through histopathological and microbiological methods, and apart from the evidence on the pathological lesions and the infectious agents responsible, they have also successfully determined the progressive events leading to death in most cases.<sup>32</sup>

Ultrasound-guided<sup>34–36</sup> and CT-guided<sup>37</sup> autopsies have also been performed along with postmortem needle.<sup>38 39</sup> MIA for the study of pulmonary and systemic involvement of COVID-19 in certain facilities in Brazil,<sup>36</sup> Spain,<sup>31</sup> Belgium<sup>39</sup> and China.<sup>31 33 34 38 40</sup> Maximum involvement was seen in the lung, followed by other organs.

In an observational study in Spain, a complete autopsy was also conducted immediately after the MIA and all the thoracoabdominal organs were eviscerated and dissected for detailed gross examination. Samples were obtained from the main organs (both lungs, liver, heart, kidneys, spleen, bone marrow) for histological and microbiological analyses.<sup>31</sup>

Almost all the literature review mentioned above on this aspect of autopsies on COVID-19 dead body reveals that ‘complete autopsy’ was essentially lacking. But as per norms of most countries, medicolegal autopsies without thorough inspection and dissection of the internal organs may produce omission of valuable clues to determine the cause of death. Moreover, a disease where a majority of the cases are asymptomatic inadvertently exposes forensic pathologists to the threat of infection. There are many countries with inadequate infrastructure and logistics makes them more vulnerable.

In the conventional method of dissection, while cutting the costochondral junction, reflecting the sternum and opening the chest cavity, the maximum aerosol spread is possible.<sup>41</sup> The chances increase with the type of instrument used. At the same time, in dealing with the dead bodies of respiratory pathogens like COVID-19 positive patients, such aerosol spread must be restricted to a minimum.

As the abdominal organ has no bony part in its anterior wall, opening through this site reduces the chances of microbe spreading almost to zero.

Approaching the thoracic cavity through the diaphragm has another advantage. The plural fluid and pericardial fluid can easily be drawn through long needle syringes even before opening the thoracic cavity, which is the most ideal. This is also advantageous over the blind pleural fluid taps commonly done during the Autopsy from the intercostal spaces through the surface, where the chance of contamination with ascitic fluid is always there.

Another advantage of this minimum dissection autopsy is that it reduces the chance of spreading dead body discharges by omitting the chest wall opening by the conventional method, which can be a source of infection. In addition, the double-layer stitch (one at the level of the rectus muscle and another one at the skin) that is only possible over the abdominal region



and not on the thoracic incision makes it more secure for the purpose.

The entire process is less time-consuming as the procedure of chest cavity opening by dissection of the ribs and sternum done in the standard procedure<sup>19–21</sup> and closure of the same were absent, and hence the exposure in mortuary rooms can also be reduced. Thus, this dissection method can be applied to all autopsies with suspected infection of the lungs or if one chooses to in the near future.

The only disadvantage of this method is that this approach may be unsuccessful in circumstances of inadequate exposure due to tapered/restricted thoracic outlet or thoracic abnormalities. In such cases, a hand saw and rib shears can be considered an alternative cutting tool to an oscillating bone saw. If an oscillating saw is deemed essential, a vacuum cover should be attached to contain the aerosols.

## CONCLUSION

The abdominal approach of thoracic organ dissection can be an essential autopsy technique for all bodies with suspected lungs infection by respiratory pathogens of high virulence. This technique is simple, quick and affordable to all and fulfils all the aspects of a complete autopsy.

**Handling editor** Runjan Chetty.

**Twitter** Somnath Das @DrSomnathDas2

**Acknowledgements** All the dead bodies who were the subjects in this research, Dr. Chakrabarty Pinaki, Dr. Kar Abir and Mr. Sambhu Mallick, the mortuary attendant of our institution.

**Contributors** All the authors have contributed almost equally in the procedure, drafting and finalising the manuscript. SD is responsible for the overall content as guarantor.

**Funding** The authors have not declared a specific grant for this research from any funding agency in the public, commercial or not-for-profit sectors.

**Competing interests** None declared.

**Patient consent for publication** Not applicable.

**Ethics approval** The details of the ethics committee are as follows: R G Kar Medical College, IECID ECR/322/Inst/WB/2013/RR-20. Participants gave informed consent to participate in the study before taking part.

**Provenance and peer review** Not commissioned; externally peer reviewed.

**Data availability statement** Data sharing not applicable as no datasets generated and/or analysed for this study.

**Supplemental material** This content has been supplied by the author(s). It has not been vetted by BMJ Publishing Group Limited (BMJ) and may not have been peer-reviewed. Any opinions or recommendations discussed are solely those of the author(s) and are not endorsed by BMJ. BMJ disclaims all liability and responsibility arising from any reliance placed on the content. Where the content includes any translated material, BMJ does not warrant the accuracy and reliability of the translations (including but not limited to local regulations, clinical guidelines, terminology, drug names and drug dosages), and is not responsible for any error and/or omissions arising from translation and adaptation or otherwise.

This article is made freely available for personal use in accordance with BMJ's website terms and conditions for the duration of the covid-19 pandemic or until otherwise determined by BMJ. You may download and print the article for any lawful, non-commercial purpose (including text and data mining) provided that all copyright notices and trade marks are retained.

## ORCID iD

Somnath Das <http://orcid.org/0000-0002-7805-6114>

## REFERENCES

- Zheng J. SARS-CoV-2: an emerging coronavirus that causes a global threat. *Int J Biol Sci* 2020;16:1678–85.
- WHO. Coronavirus disease (COVID-2019) situation dashboard. Available: <https://covid19.who.int/>
- WHO. Report of the WHO-China joint mission on coronavirus disease 2019 (COVID-19), 2020. Available: <https://www.who.int/docs/default-source/coronaviruse/who-china-joint-mission-on-covid-19-final-report.pdf>
- Coronaviridae Study Group of the International Committee on Taxonomy of Viruses. The species severe acute respiratory syndrome-related coronavirus: classifying 2019-nCoV and naming it SARS-CoV-2. *Nat Microbiol* 2020;5:536–44.
- Andersen KG, Rambaut A, Lipkin WI, et al. The proximal origin of SARS-CoV-2. *Nat Med* 2020;26:450–2.
- Ludwig S, Zarbock A. Coronaviruses and SARS-CoV-2: a brief overview. *Anesth Analg* 2020;131:93–6.
- Kaufer AM, Theis T, Lau KA, et al. Laboratory biosafety measures involving SARS-CoV-2 and the classification as a risk group 3 biological agent. *Pathology* 2020;52:790–5.
- Sapino A, Facchetti F, Bonoldi E. Societ Italiana di Anatomia Patologica e Citologia - SIAPEC. The autopsy debate during the COVID-19 emergency: the Italian experience. *Virchows Arch* 2020;476:821–3.
- Wölfel R, Corman VM, Guggemos W, et al. Virological assessment of hospitalized patients with COVID-2019. *Nature* 2020;581:465–9.
- Patel SK, Singh J, Singh HP, et al. Brought dead cases in tertiary care hospital in central India. *Indian J Crit Care Med* 2017;21:62–3.
- Lacy JM, Brooks EG, Akers J, et al. COVID-19: postmortem diagnostic and biosafety considerations. *Am J Forensic Med Pathol* 2020;41:143–51.
- Kumar A, Nayar KR. COVID-19 and mass fatality management: a public health challenge. *Disaster Med Public Health Prep* 2020;14:e38–9.
- World Health Organization (WHO). Infection prevention and control for the safe management of a dead body in the context of COVID-19, 2020. Available: [https://apps.who.int/iris/bitstream/handle/10665/331538/WHO-COVID-19-IPC\\_DBMgmt-2020.1-eng.pdf](https://apps.who.int/iris/bitstream/handle/10665/331538/WHO-COVID-19-IPC_DBMgmt-2020.1-eng.pdf)
- Centers for Disease Control and Prevention. Collection and submission of postmortem specimens from deceased persons with confirmed or suspected COVID-19. Available: <https://www.cdc.gov/coronavirus/2019-ncov/hcp/guidance-postmortem-specimens.html>
- The Royal College of Pathologists Briefing on COVID-19. Autopsy practice relating to possible cases of COVID-19 (2019-nCoV, novel coronavirus from China 2019/2020). Available: <https://www.rcpath.org/uploads/assets/d5e28baf-5789-4b0f-acecfe370eee6223/fe8fa85a-f004-4a0c-81ee4b2b9c12cbf/Briefing-on-COVID-19-autopsy-Feb-2020.pdf>
- VijKrishan. *Textbook of forensic medicine and toxicology*. 5th edn. New Delhi: Elsevier, 2014: 15–25.
- Camps Francis EBombay KM, ed. *Gradwohl legal medicine*. 3rd edn. Varghese company, 1976: 356–60.
- Laaksonen H, Parikh CK. *Dissection of neck in medico-legal postmortems in India*. 1st edn. Bombay: Dr. CK Parikh medical publication, 1985: 42–3.
- Parikh CK. *Parikh's text book of medical jurisprudence and toxicology*. Bombay Medical centre, 1990: 93–104.
- Reddy KSN. *The essentials of forensic medicine and toxicology*. 34th edn. New Delhi: Jaypee, 2017: 98–127.
- Knight B. *Forensic pathology*. 3rd edn. London: Arnold, 1996: 312–24.
- Pluim JME, Loeve AJ, Gerretsen RRR. Minimizing aerosol bone dust during autopsies. *Forensic Sci Med Pathol* 2019;15:404–7.
- Loibner M, Langner C, Regitnig P, et al. Biosafety requirements for autopsies of patients with COVID-19: example of a BSL-3 autopsy facility designed for highly pathogenic agents. *Pathobiology* 2021;88:37–45.
- Tahamtan A, Ardebili A. Real-time RT-PCR in COVID-19 detection: issues affecting the results. *Expert Rev Mol Diagn* 2020;20:453–4.
- Sharma N, Hasan Z, Velayudhan A, et al. Personal protective equipment: challenges and strategies to combat COVID-19 in India: a narrative review. *J Health Manag* 2020;22:157–68.
- Yusoff MSB, Yusoff MSB. ABC of content validation and content validity index calculation. *Education in Medicine Journal* 2019;11:49–54.
- Tang JW, To K-F, Lo AWI, et al. Quantitative temporal-spatial distribution of severe acute respiratory syndrome-associated coronavirus (SARS-CoV) in post-mortem tissues. *J Med Virol* 2007;79:1245–53.
- Rivm.nl. Handig die LCI-richtlijn van het RIVM [Internet]. Available: <https://lci.rivm.nl/richtlijnen/covid-19> [Accessed 06 Dec 2021].
- Dijkhuizen LGM, Gelderman HT, Duijst WJLM. Review: the safe handling of a corpse (suspected) with COVID-19. *J Forensic Leg Med* 2020;73:101999.
- Melo DN, Mara Coelho T, RolimPinheiro Lima G, et al. Aparecida de Almeida Monteiro R, Ordi J, Hilário do NascimentoSaldiva P, Pamplona de GóesCavalcanti L. use of minimally invasive autopsy during the COVID-19 pandemic and its possibilities in the context of developing countries. *PLoS Negl Trop Dis* 2021;15:e0009629.
- Rakislova N, Marimon L, Ismail MR, et al. Minimally invasive autopsy practice in COVID-19 cases: biosafety and findings. *Pathogens* 2021;10:412.
- Rakislova N, Marimon L, Ismail MR, et al. Minimally invasive autopsy practice in COVID-19 cases: biosafety and findings. *Pathogens* 2021;10:412.
- Yao XH, TY L, ZC H. A pathological report of three COVID-19 cases by minimally invasive autopsies. *Zhonghua Bing Li XueZaZhi* 2020;49:411–7.

- 34 JH W, Li X, Huang B. [Pathological changes of fatal coronavirus disease 2019 (COVID-19) in the lungs: report of 10 cases by postmortem needle autopsy]. *Zhonghua Bing Li Xue Za Zhi* 2020;49:568–75.
- 35 Brook OR, Piper KG, Mercado NB, *et al.* Feasibility and safety of ultrasound-guided minimally invasive autopsy in COVID-19 patients. *Abdom Radiol* 2021;46:1263–71.
- 36 Monteiro RAdeA, Duarte-Neto AN, Silva LFFda, *et al.* Ultrasound-guided minimally invasive autopsies: a protocol for the study of pulmonary and systemic involvement of COVID-19. *Clinics* 2020;75:e1972.
- 37 D'Onofrio V, Donders E, Vanden Abeele M-E, *et al.* The clinical value of minimal invasive autopsy in COVID-19 patients. *PLoS One* 2020;15:e0242300.
- 38 Xu X, Chang XN, Pan HX, *et al.* [Pathological changes of the spleen in ten patients with coronavirus disease 2019(COVID-19) by postmortem needle autopsy]. *Zhonghua Bing Li Xue Za Zhi* 2020;49:576–82.
- 39 Tian S, Xiong Y, Liu H, *et al.* Pathological study of the 2019 novel coronavirus disease (COVID-19) through postmortem core biopsies. *Mod Pathol* 2020;33:1007–14.
- 40 Li Y, Wu J, Wang S, *et al.* Progression to fibrosing diffuse alveolar damage in a series of 30 minimally invasive autopsies with COVID-19 pneumonia in Wuhan, China. *Histopathology* 2021;78:542–55.
- 41 Wenner L, Pauli U, Summermatter K, *et al.* Aerosol generation during Bone-Sawing procedures in veterinary autopsies. *Vet Pathol* 2017;54:425–36.