

CASE REPORT

Point-of-care ultrasound diagnosis of flexor tenosynovitis caused by an unusual pathogen

Margaret C. Yates¹, Katherine F. Chiasson², Zachary S. Pacheco¹, John P. Gullett¹, Brad D. Denney² and David C. Pigott^{1,*},[†]

¹Department of Emergency Medicine, The University of Alabama at Birmingham, Birmingham, AL, USA,

²Division of Plastic Surgery, Department of Surgery, The University of Alabama at Birmingham, Birmingham, AL, USA

*Correspondence address. Department of Emergency Medicine, The University of Alabama at Birmingham, 619 S 19th St., OHB 251, Birmingham, AL 35249-7013, USA. Tel: 205-821-0538; E-mail: dpigott@uabmc.edu

Abstract

Skin and soft tissue infections are commonly encountered in the emergency department and are typically caused by common gram-positive bacteria. In the immunocompromised patient, however, infections from unusual pathogens should also be considered. We describe the case of a 66-year-old male with a history of renal transplant who was diagnosed with flexor tenosynovitis by point-of-care ultrasound. Although initial wound cultures were negative, subsequent microbiological testing led to the underlying cause, a nontuberculous mycobacterial infection.

INTRODUCTION

Among patients presenting with evidence of forearm or hand infection, infectious flexor tenosynovitis (FTS) is an important diagnosis to consider, as failure to detect this condition may lead to severe morbidity and loss of hand function. The most common causes include *Streptococcus* and *Staphylococcus* species, including methicillin-resistant *Staph. aureus* (MRSA), which may be introduced via a number of routes, including local trauma, contiguous spread or hematogenous spread [1]. Diagnosis of FTS has typically been based on physical examination, including the use of Kanavel's signs (tenderness of the flexor tendon sheath, affected finger held in flexion, the presence of fusiform swelling and pain on passive extension) [2]. More recently, however, point-of-care ultrasound (POCUS) has also been shown to be a rapid, effective adjunct for the diagnosis of FTS [3]. We present an

atypical case of FTS in an immunocompromised patient diagnosed with the aid of POCUS, complicated by the presence of a nontuberculous mycobacterial infection.

CASE REPORT

A 66-year-old male with history of hypertension, diabetes mellitus and renal transplant presented to the emergency department with several months of left hand swelling and pain. He denied any recent trauma or animal bites to his hand or arm.

On physical examination, he was afebrile with normal vital signs. The fingers of his left hand were held in moderate flexion. He had swelling and tenderness of the volar distal forearm, hand and fingers, with pain on active and passive finger extension. No erythema and warmth were present. Sensation was intact with

[†]David C. Pigott, <http://orcid.org/0000-0002-9699-9327>

First author: Margaret C. Yates, 619 S 19th St., OHB 251, Department of Emergency Medicine, The University of Alabama at Birmingham. mcompton@uabmc.edu; 251-282-0019

Received: July 9, 2020; Revised: October 2, 2020; Accepted: October 17, 2020

© The Author(s) 2020. Published by Oxford University Press. All rights reserved. For Permissions, please email: journals.permissions@oup.com

This is an Open Access article distributed under the terms of the Creative Commons Attribution Non-Commercial License (<http://creativecommons.org/licenses/by-nc/4.0/>), which permits non-commercial re-use, distribution, and reproduction in any medium, provided the original work is properly cited. For commercial re-use, please contact journals.permissions@oup.com

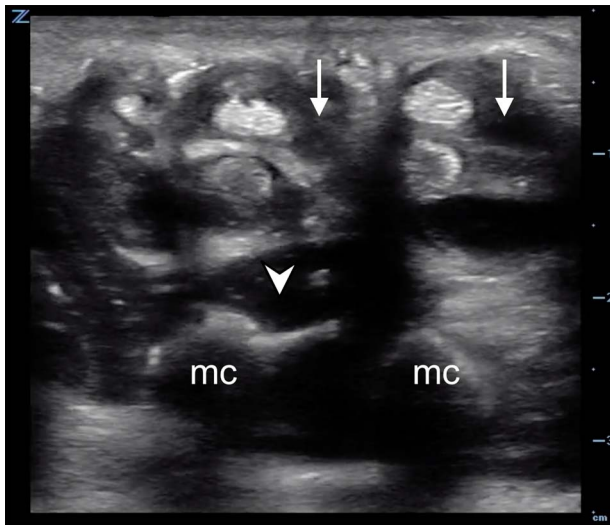


Figure 1: In this transverse ultrasound view of the patient's left palm, complex fluid (white arrows) is seen within the synovial sheath surrounding the paired flexor tendons. Also note the hypochoic fluid in the midpalmar space (arrowhead) superficial to the metacarpals (mc).

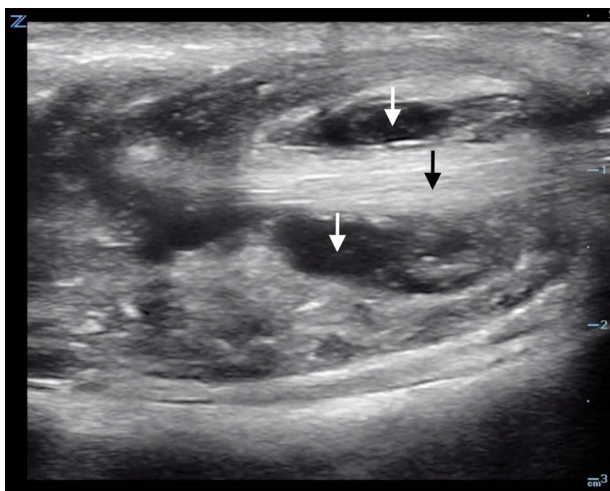


Figure 2: In this longitudinal ultrasound image, complex fluid (white arrows) is seen both superficial and deep to the flexors of the patient's index finger. Note the ragged appearance of the flexor tendon (black arrow).

the exception of paresthesias of the distal fifth finger. Radial and ulnar pulses were intact.

Laboratory evaluation was notable for the absence of leukocytosis (white blood cell count $5.5 \times 10^9/L$) although C-reactive protein was elevated at 14.5 mg/L. Hand radiographs were unremarkable. A POCUS was performed using a high-frequency linear-array transducer on a Zonare ultrasound system (Zonare Medical Systems, Inc., Mountain View, CA) which demonstrated a large complex fluid collection surrounding the flexor tendons of the left mid-forearm extending to the volar aspect of the left hand (Fig. 1). Fluid was also noted surrounding the flexor tendons of the left index finger (Fig. 2).

Following plastic surgery consultation, the patient was taken to the operating room for exploration, drainage and release of the left carpal tunnel. Operative findings included an extensive cavity of tenacious yellow/clear fluid with solid components

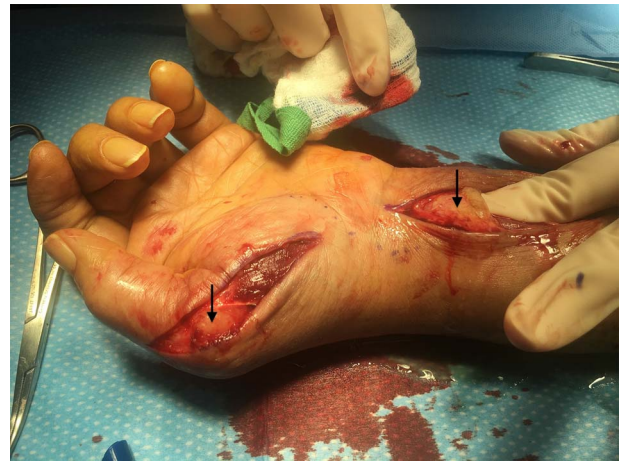


Figure 3: Intraoperative photo of the patient's volar wrist and hand. Note the thick yellowish material adjacent to the surgeon's finger as well as in the thenar eminence (arrows).

extending from the left volar forearm through the carpal tunnel to the palm and volar thumb (Fig. 3).

Blood, fluid and tissue cultures were sent, including gram-positive, gram-negative, acid-fast bacilli (AFB) and fungal assays. The patient was empirically started on IV vancomycin, cefepime and fluconazole.

All initial cultures were negative, and preliminary AFB smear was negative. Three weeks later, wound culture results were positive for *Mycobacterium avium* complex (MAC). Further patient evaluation revealed the presence of a peripheral lung nodule with nodularity and cavitory changes concerning for atypical mycobacterial infection. The patient's clinical course was complicated by the need for further operative debridement for residual MAC disease 5 months later. He was discharged on a 6- to 12-month course of azithromycin, rifabutin and ethambutol, as well as hand therapy.

DISCUSSION

FTS is defined as inflammation of the tendon and synovial sheath and most frequently occurs in the upper extremities. Potential complications may include carpal tunnel syndrome, compartment syndrome, and even tissue necrosis requiring amputation [4]. FTS in immunocompromised patients may be caused by common skin flora or, as in our case, by more unusual pathogens. The broader differential diagnosis in patients with suspected infectious tenosynovitis should include infectious causes such as staphylococcus, streptococcus and mycobacterial infection as well as noninfectious causes such as injury, autoimmune or inflammatory tenosynovitis.

Soft tissue infections involving the wrist and palm may spread through the synovial sheaths that surround the flexor tendons of the hand. The common flexor sheath (also known as the ulnar bursa) contains the superficial and deep flexor tendons of the fingers, except for flexor pollicis longus, which is contained within a separate synovial sheath, the radial bursa. The ulnar and radial bursa communicate in 50–85% of patients [5], which may facilitate the progression of FTS to involve not only the palmar flexors but also the thumb, as in this case, requiring a separate thumb incision and debridement.

Ultrasonography has increasingly been recognized as a valuable imaging modality in the evaluation of patients with suspected FTS [6]. On ultrasound examination, complex hypoechoic or anechoic fluid may be seen surrounding the flexor tendons within the fingers as well as in the hand and wrist, as in our case. After FTS is identified, urgent surgical consultation should be obtained and empiric antimicrobial and antifungal treatment initiated [7].

MAC is an indolent mycobacterial infection that is generally encountered in immunocompromised patients and most often presents with pulmonary involvement. Diagnosis is made through blood or body fluid cultures, such as sputum samples. Treatment may be prolonged and involves a three-drug regimen that is often at least 12 months in duration [8].

A recent review of nontuberculous mycobacterial infections of the hand demonstrated several common characteristics, including need for surgical debridement, delay in microbiologic diagnosis (mean 4.9 weeks after surgery) followed by a prolonged course of antimycobacterial therapy. Recurrence was rare although ~20% of patients had long-term sequelae including pain, stiffness and swelling [9].

CONCLUSION

In this case, POCUS played an important role in the diagnosis of FTS in a patient with minimal physical exam findings, expediting the initiation of appropriate therapy and operative intervention. A comprehensive approach to confirming the patient's microbiologic diagnosis, including bacterial, fungal and mycobacterial assays, ensured that this unusual pathogen, and its atypical presentation, would not go undetected.

SUPPLEMENTARY MATERIAL

Supplementary material is available at the *Journal of Surgical Case Reports* online.

ACKNOWLEDGEMENTS

None.

CONFLICT OF INTEREST STATEMENT

No conflicts of interest are reported.

FUNDING

None.

ETHICAL APPROVAL

No approval is required for this case report.

CONSENT

A signed patient consent form was obtained and is available on request.

GUARANTOR

David C. Pigott will serve as the Guarantor for this publication submission.

REFERENCES

- Hyatt BT, Bagg MR. Flexor tenosynovitis. *Orthop Clin North Am* 2017;**48**:217–27. doi: [10.1016/j.ocl.2016.12.010](https://doi.org/10.1016/j.ocl.2016.12.010).
- Kanavel AB. *Infections of the hand: a guide to surgical treatment of acute and chronic suppurative processes of the fingers, hand, and forearm*. Philadelphia: Lea and Febiger, 1912.
- Padrez K, Bress J, Johnson B, Nagdev A. Bedside ultrasound identification of infectious flexor tenosynovitis in the emergency department. *West J Emerg Med* 2015;**16**:260–2. doi: [10.5811/westjem.2015.1.24474](https://doi.org/10.5811/westjem.2015.1.24474).
- Kour AK, Looi KP, Phone MH, Pho RW. Hand infections in patients with diabetes. *Clin Orthop Relat Res* 1996;**331**:238–44. doi: [10.1097/00003086-199610000-00034](https://doi.org/10.1097/00003086-199610000-00034).
- Aguiar RO, Gasparetto EL, Escuissato DL, Marchiori E, Trudell DJ, Haghighi P et al. Radial and ulnar bursae of the wrist: cadaveric investigation of regional anatomy with ultrasonographic-guided tenography and MR imaging. *Skeletal Radiol* 2006;**35**:828–32. doi: [10.1007/s00256-006-0143-z](https://doi.org/10.1007/s00256-006-0143-z).
- Jardin E, Delord M, Aubry S, Loisel F, Obert L. Usefulness of ultrasound for the diagnosis of pyogenic flexor tenosynovitis: a prospective single-center study of 57 cases. *Hand Surg Rehabil* 2018;**37**:95–8. doi: [10.1016/j.hansur.2017.12.004](https://doi.org/10.1016/j.hansur.2017.12.004).
- Giladi AM, Malay S, Chung KC. A systematic review of the management of acute pyogenic flexor tenosynovitis. *J Hand Surg Eur Vol* 2015;**40**:720–8. doi: [10.1177/1753193415570248](https://doi.org/10.1177/1753193415570248).
- Daley CL. Mycobacterium avium complex disease. *Microbiol Spectr* 2017;**5**. doi: [10.1128/microbiolspec.TNMI7-0045-2017](https://doi.org/10.1128/microbiolspec.TNMI7-0045-2017).
- Balagué N, Uçkay I, Vostrel P, Hinrikson H, Van Aaken I, Beaulieu JY. Non-tuberculous mycobacterial infections of the hand. *Chir Main* 2015;**34**:18–23. doi: [10.1016/j.main.2014.12.004](https://doi.org/10.1016/j.main.2014.12.004).