

Root Canal Morphology of Mandibular First Premolar in a Gujarati Population - an In Vitro Study

Atul Jain¹, Rachana Bahuguna²

ABSTRACT

Background: Knowledge about root canal morphology and its frequent variations can exert considerable influence on the success of endodontic treatment. The aim of this study was to survey the root canal morphology of mandibular first premolar teeth in a Gujarati population by decalcification and clearing technique.

Methods: One hundred thirty eight extracted mandibular first premolar teeth were collected from a Gujarati population. After decalcifying and clearing, the teeth were examined for tooth length, number of cusps and roots, number and shape of canal orifices and canal types.

Results: The average length of mandibular first premolar teeth was 21.2 mm. All the teeth had 2 cusps. One hundred thirty four teeth (97.1%) had one root, and just 4 teeth (2.89%) had two roots. Mesial invagination of root was found in 21 teeth (15.21%). One canal orifice was found in 122 teeth (88.4%) and two canal orifices in 16 teeth (11.59%). Shape of orifices was found to be round in 46 teeth (33.33%), oval in 72 teeth (52.17%) and flattened ribbon in 20 teeth (14.49%). According to Vertucci's classification, Type I canal system was found in 93 teeth (67.39%), Types II,III,IV,V, and VI in 11 teeth (7.97%), 5 teeth (3.62%), 4 teeth (2.89%), 24 teeth (17.39%), and 1 tooth (0.72%) respectively.

Conclusion: Mandibular first premolar teeth were mostly found to have one root and Type I canal system.

Keywords: Canal orifice, Decalcification, Length of tooth, Mandibular first premolar, Root canal system.

Received: November 2010

Accepted: March 2011

Dent Res J 2011; 8(3): 118-122

Introduction

Over the years it has been established that successful endodontic treatment can be achievable with accurate diagnosis & treatment planning, along with having the knowledge of root canal morphology and its frequent variations. Peter et al.¹ reported that the original geometry of canal, before shaping and cleaning procedures, had more influence on the changes, that occurred during preparation, than the instrumentation technique itself. Thus, they emphasized on the importance of root canal anatomy.

The wide range of studies conducted on root canal anatomy, from the early work of Hess and Zurcher,² to more recent, demonstrating anatomic complexities of the root canal systems, have all

emphasized on the fact that a root with tapering canal and a single foramen is an exception rather than a rule.

The root canal system is complex and canal may branch, divide and rejoin taking various pathways to the apex. Weine³ categorized the root canal system into four basic types. Vertucci⁴ found numerous complex canal systems and identified eight pulp canal configurations.

All races and ethnic groups have some degree of dental anatomic variations. Asian populations present one of the widest variations in coronal shape, external root form and internal canal space morphology.

Amongst all the teeth, mandibular first premo-

¹ Professor, Department of Conservative Dentistry and Endodontics, K. M. Shah Dental College & Hospital, Gujarat, India.

² Professor, Department of Pedodontics and Preventive Dentistry, K. M. Shah Dental College & Hospital, Gujarat, India.

Correspondence to: Atul Jain, Email: jaindratul@yahoo.co.in

lar is quite difficult to treat, and has high flare up and failure rates, the major contributory factor is attributed to the Variations in root canal anatomy.^{5,6} Though a few studies on these teeth have been carried out in India, no study on the variations in root canal anatomy of Mandibular first premolar has been carried out in the central region of Gujarat, India, where the failure rate of endodontic treatment of these teeth is quite high.

Materials and Methods

For this in-vitro study 138 permanent extracted mandibular first premolar teeth were collected from the Out Patient Department of K M Shah Dental College and Hospital, Sumandeep Vidyapeeth, Vadodara, India, of the local population. Teeth were collected irrespective of age and sex of the patients.

The inclusion criteria were intact teeth extracted for (i) Orthodontic treatment, (ii) Periodontal diseases, (iii) Periapical diseases, (iv) Extreme mobility.

The exclusion criteria were (i) Grossly decayed or carious teeth, (ii) Fractured teeth (iii), Teeth with crazy shapes, (iv) Root canal treated teeth, (v) Teeth with full coverage restoration.

Teeth were cleaned from all debris, attached tissue and calculus using an Ultrasonic Scaler and were preserved in 10% of formalin solution. Teeth were measured for length, using Electronic Vernier Caliper (MEKA Electronic Vernier Caliper 150 mm, Model no. 06912, Hangzhou Meka Tools Co. Ltd., Zhejiang, China), from the tip of the crown to the apex of the root. For curved roots, tangents were drawn to the curved portion of the tooth and end length was measured by connecting the points of tangency.

Access cavities were prepared using No. 2 Round diamond point (Mani, Japan) in a High Speed Air Rotor Handpiece (NSK Standard, NSK Company, Japan) with air-water spray. Oval shaped access cavity was prepared which extended buccally up to the tip of buccal cusp, lingually up to lingual cusp inclination, walls were diverged oc-

clusally with No. 2 Endo Access bur (Maillefer, Dentsply, Switzerland) for better visualization of the orifices. Shape and number of the canal orifices were observed under a Dental Operating Microscope (Seiler i Q 100-180, Seiler Precision Microscopes, St. Louis, U.S.A.) at 12X magnification. Then teeth were placed in 5.2% of sodium hypochlorite solution (Merck Limited, Mumbai, India) for 24 hours. Teeth were then decalcified and were made transparent by technique reported by Robertson et al.⁷

Following the placement in Sodium hypochlorite solution, teeth were washed with running water for 2 hours, then placed in 5% of Nitric Acid solution (SDFCL, Mumbai, India) for 72 hours. Nitric Acid solution was renewed every 24 hours.

Teeth were then washed with running water and placed in ascending grades of Isopropyl alcohol (SDFCL, Mumbai, India) i.e. 70%, 80%, 90% and 100% successively for 12 hours each, for a total duration of 48 hours for dehydration.

Teeth were rendered transparent by placing in Methyl Salicylate (SDFCL, Mumbai, Maharashtra, India). Methylene Blue Dye (SDFCL, Mumbai, India) was injected into these decalcified and transparent teeth through the access opening till the dye exited through the apical foramen; thus the entire pulp space were colored. These teeth were then observed under Dental Operating Microscope at 12X magnification and root canal systems were identified according to Vertucci's Classification.⁴

Results

Tooth length: In this study the average length of the mandibular first premolars was found to be 21.2 mm with the longest tooth having a length of 26 mm and shortest 17 mm.

Number of Cusps & Roots: Two cusps were found in all the 138 teeth. One hundred thirty four teeth (97.10%) had one root and two roots were found in 4 teeth had two roots [2.89%]. Mesial invagination of root was found in 21 teeth (15.21%) (Table 1 and Figure 1).

Table 1. Number of roots in mandibular first premolar

Teeth	One Rooted	Two Rooted	Mesial Invagination of Root
Number	134	4	21
Percent	97.10	2.89	15.21

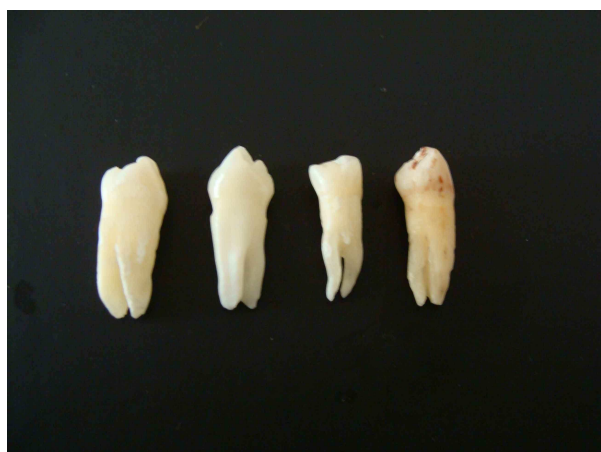

Figure 1. Two rooted mandibular first premolar teeth.

Canal Orifice: In the mandibular first premolar teeth one canal orifice was found in 122 teeth (88.40%) and two canal orifices were found in 16 teeth (11.59%)

The shape of the canal orifice was found to be round in 46 teeth (33.33%), oval in 72 teeth (52.17%) and flattened ribbon in 20 teeth (14.40%) (Table 2).

Canal Type: According to Vertucci’s classification of canal types, Type I canal system was found in 93 teeth (67.39%), Type II in 11 teeth (7.97%), Type III in 5 teeth (3.62%) and Type IV in 4 teeth (2.89%), Type V in 24 teeth (17.39%), and Type VI in 1 tooth (0.76%) (Table 3 and Figure 2).

Table 2. Number and shape of orifice in mandibular first premolar

Teeth	One Orifice	Two Orifice	Round Orifice	Oval Orifice	Flattened Ribbon
Number	122	16	46	72	20
Percent	88.40	11.59	33.30	52.17	14.49

Table 3. Canal system types according to Vertucci’s classification

Type of Canal	Canal Pattern	% of Occurrence (n = 138)	Number of teeth (n = 138)
Type I	1	67.39	93
Type II	2-1	7.97	11
Type III	1-2-1	3.62	5
Type IV	2-2	2.89	4
Type V	1-2	17.39	24
Type VI	2-1-2	0.72	1
Type VII	1-2-1-2	0	0
Type VIII	3-3	0	0




Figure 2. Canal type and canal pattern according to vertucci’s classification (A) TypeI, (B) TypeII, (C) Type III, (D) Type IV, (E) Type V, (F) Type VI.

Discussion

One of the predominant causes of the failure of root canal treatment in mandibular first premolar is due to the variations in root canal anatomy. In the Central Gujarat Region of India the failure rate of mandibular first premolar has been quite high with the variations in root canal anatomy being one of the attributable causes. Since no previous study on the root canal morphology of these teeth had been conducted, this study was taken up.

Although many studies on root canal anatomy have been carried out using macroscopic section,⁸ radiography,⁹ direct observation with microscope,¹⁰ decalcification and clearing,^{11,12} 3D reconstruction,¹³ computed tomography,^{14,15} decalcification and clearing technique has provided the most detailed information along with being simple and inexpensive. In this study the average length of mandibular first premolar teeth was found to be 21.2 mm whereas Cohen & Hargreaves⁶ and Velumurgan & Sandhya¹⁶ reported the average length of the teeth as 21.6 mm.

All the mandibular first premolar teeth examined in this study were found to have 2 cusps which is in keeping with the established external morphology of this tooth.^{17, 18} Evagination manifested as an extra cusp or enamel pearl, although commonly reported in mandibular premolars in people of Asian descent was not found.

In this study 97.10% of the mandibular first premolar teeth were found to have one root (134 teeth) whereas 2.89% teeth were found to have two roots (4 teeth) which is similar to the finding of Zillich & Dawson,¹⁹ Vertucci,⁴ Rahimi et al.²⁰ and Velumurgan & Sandhya.¹⁶

Mesial invagination of the root that arises as a result of invagination of Hertwig's epithelial root sheath and manifested as accentuation of the normal longitudinal root groove was found in 21teeth (15.21%) which was consistent with the finding of Robinson et al.¹⁴, who found invagination in 15% mandibular first premolars using spiral computed tomography and that of Velumurgan & Sandhya¹⁶ who reported 14% of mandibular first premolars with mesial invagination of the root.

According to Vertucci's classification,⁴ Root canal system of mandibular first premolars was found to be predominantly (67.39%) Type I (Single canal extends from pulp chamber to apex). Vertucci's reported Type I canal system in 70%, Velumurgan & Sandhya¹⁶ in 72%, while Zillich & Dawn-

son¹⁹ reported an incidence ranging from 67.2% to 86.3%. Type II canal system (Two separate canals leave pulp chamber and join short of apex to form one canal) was found in 7.97% teeth whereas Vertucci⁴ reported 0%, Velumurgan & Sandhya¹⁶ 6% and Rahimi et al.²⁰ 5.6 %. Type III Canal system (One canal leaves pulp chamber and divides into two canals in the root, and finally merge into one and exit) was found in 3.62% teeth which was similar to 4% in the findings of Vertucci⁴ and 3% of Velumurgan & Sandhya.¹⁶ Type IV canal system (Two separate canals extend from pulp chamber to apex) was found in 2.89% mandibular first premolars, Vertucci⁴ reported this system in 1.5% teeth, Velumurgan & Sandhya¹⁶ in 10% and Rahimi et al.²⁰ in 22 %. Type V Canal system (One canal leaves pulp chamber, divides short of apex into two) was found in 17.39% teeth, Vertucci⁴ found this system in 24% teeth while Velumurgan & Sandhya¹⁶ reported an incidence of 8%. Type VI canal system (Two canals leave pulp chamber merge in the root and divide again short of apex to exit as two distinct canals) was found in 0.72% teeth. Types VII (One canal leaves pulp chamber, divides and then rejoin in root and finally divides into two canals short of the apex) and VIII (Three separate canals extend from pulp chamber to the apex) were not identified in any of the teeth.

The difference in the incidence of I, II, III, IV, V, canal system in the present study and those reported by Vertucci⁴, Velumurgan & Sandhya¹⁶ and Rahimi et al.²⁰ could be attributed to racial difference since this study was carried out on a Gujarati Indian population whereas Vertucci⁴ carried out study on Caucasian population, Rahimi et al.²⁰ in Iranian population and Velumurgan & Sandhya¹⁶ on South Indian population.

Conclusion

It can be concluded from the results of this study that mandibular first premolar teeth present a wide variety of radicular features, with one root and one canal being found in majority of cases. Presence of two roots, two canals, mesial invagination of root is also found in a number of cases, which complicates the endodontic treatment.

References

1. Peters OA, Schönenberger K, Laib A. Effects of four Ni-Ti preparation techniques on root canal geometry assessed by micro computed tomography. *Int Endod*

- J 2001; 34(3):221-30.
2. Hess W, Zurcher E. The anatomy of root canals of the teeth of the Permanent & Deciduous Dentition. New York: William Wood & Co. 1925.
 3. Weine FS. Endodontic Therapy, 5th edn. St. Louis: Mosby– Yearbook Inc. 1996: 243
 4. Vertucci FJ. Root canal anatomy of the human permanent teeth. Oral Surg Oral Med Oral Pathol. 1984; 58: 589-99.
 5. Ingle JI, Taintor JF. Endodontic, 3rd ed. Philadelphia: Lea & Fibiger; 1985, 27-52.
 6. Cohen S, Hargreaves KM. Pathways of the Pulp. 9thed. St. Louis. Mosby. Elsevier. 2006: 216.
 7. Robertson D, Leeb J, Mckee M, Brewer E. A clearing technique for the study of root canal systems. J Endod.1980; 6(1): 421-4.
 8. Baisden MK, Kulild JC, Weller RN: Root canal configuration of the mandibular first premolar. J Endod. 1992; 18(10): 505-8.
 9. Pineda F, Kuttler Y. Mesiodistal and Buccolingual roentgenographic investigation of 7,275 root canals. Oral Surg Oral Med Oral Pathol. 1972; 33(1): 101-10.
 10. Sempira HN, Hartwell GR. Frequency of second mesiobuccal canals in maxillary molars as determined by use of an operating microscope: a clinical study. J Endod. 2000; 26(11): 673-4.
 11. Caliskan MK, Pehlivan Y, Sepetcioglu F, Turkun M, Tuncer SS. Root canal morphology of human permanent teeth in a Turkish population. J Endod. 1995; 21(4): 200-4.
 12. Rwenyonyi CM, Kutesa AM, Muwazi LM, Buwembo W. Root and canal morphology of maxillary first and second permanent molar teeth in a Ugandan population. Int Endod J. 2007; 40(9): 679-83.
 13. Mikrogeorgis G, Lyroutdia KL, Nikopoulos N, Pitas I, Molyvdas I, Lambrianidis TH. 3D computer-aided reconstruction of six teeth with morphological abnormalities. Int Endod J. 1999; 32(2): 88-93.
 14. Robinson S, Czerny C, Gahleitner A, Bernhart T, Kainberger FM. Dental CT evaluation of mandibular first premolar root configurations and canal variations. Oral Surg Oral Med Oral Pathol Oral Radio Endo. 2002; 93(3): 328-32.
 15. Reuben J, Velmurugan N, Kandaswamy D. The evaluation of root canal morphology of the mandibular first molar in an Indian population using spiral computed tomography scan: an in vitro study. J Endod. 2008; 34(2): 212-5.
 16. Velmurugan N, Sandhya R. Root canal morphology of mandibular first premolar in an Indian population: a laboratory study. Int Endo J. 2009; 42(1): 54-58.
 17. Ash M, Nelson S. Wheeler's Dental Anatomy, Physiology and Occlusion. 8th Ed Philadelphia: Saunders. 2003.
 18. Fuller J, Denely G. Concise Dental Anatomy & Morphology. 2nd ed Chicago: Year Book Medical Publishers Inc. 1984.
 19. Zillich R, Dowson J. Root canal morphology of mandibular first & second premolars. Oral Surg Oral Med Oral Pathol .1973; 36(5): 738-44.
 20. Rahimi S, Shahi S, Yavari H, Manafi H, Eskandarzadeh N. Root canal configuration of mandibular first & second premolars in an Iranian population. Journal of Dental Research, Dental Clinics, Dental Prospects. 2007; 1 (2): 59-64.