

The Review of Ophthalmic Symptoms in COVID-19

Aleksander Robert Stawowski¹, Joanna Konopińska², Sylwester Szymon Stawowski³, Justyna Adamczuk⁴, Monika Groth⁵, Anna Moniuszko-Malinowska⁴, Piotr Czupryna⁴

¹Department of Ophthalmology, University Clinical Hospital in Białystok, Białystok, Poland; ²Department of Ophthalmology, Medical University of Białystok, Białystok, Poland; ³Non-Public Health Care Facility MEDIX, Białystok, Poland; ⁴Department of Infectious Diseases and Neuroinfectious, Medical University of Białystok, Białystok, Poland; ⁵Department of Allergology and Internal Diseases, University Clinical Hospital in Białystok, Białystok, Poland

Correspondence: Aleksander Robert Stawowski, Department of Ophthalmology, University Clinical Hospital in Białystok, Białystok, Poland, Tel +48-668101778, Email aleksanderstawowski@wp.pl

Abstract: The COVID-19 pandemic caused by SARS-CoV-2 had a significant impact on the health of the global human population, affecting almost every human organ, including the organ of vision. Research focus on understanding the pathophysiology, identifying symptoms and complications of the disease. Eye-related pathologies are important foci of research due to the potential for direct impact of the virus. Ophthalmologists around the world are reporting various symptoms of eye infections and ocular pathologies associated with SARS-CoV-2. The review of ophthalmic symptoms was conducted to help physicians of various specialties recognize possible ophthalmic manifestations of this viral disease. A literature review was conducted from January 2020 to July 2023 in the PubMed, MEDLINE, Science Direct, Scopus, Scielo and Google Scholar databases. The review of the literature showed that conjunctivitis is the most common ophthalmic symptom observed during the course of COVID-19 and can occur at any stage of the disease. Changes in the eye may result from the direct effect of the virus, immune response, prothrombotic states, comorbidities, and medications used. Symptoms related to the organ of vision can be divided into: changes affecting the protective apparatus of the eye, the anterior eye segment, the posterior eye segment, neuro-ophthalmic, and orbital changes. Ocular symptoms may suggest COVID-19 infection or appear several weeks after recovery. Following COVID-19 vaccinations, a diverse range of ophthalmic symptoms was observed in various locations and at different times, mirroring the ocular symptoms experienced throughout the course of the COVID-19 illness. It is important for physicians of all specialties to be aware of possible potential connections between eye diseases and SARS-CoV-2, in order to effectively diagnose and treat patients.

Keywords: COVID-19, SARS-CoV-2, ocular symptoms

Introduction

In March 2020, the World Health Organization (WHO) announced a pandemic of a new, rapidly spreading viral infection with a high mortality rate and high infectivity called COVID-19 (coronavirus disease 2019).^{1,2} The first identification of a respiratory infection caused by SARS-CoV-2 occurred in December 2019 in Wuhan, China.³ By July 2023, over 767 million cases and almost 7 million deaths have been confirmed worldwide.⁴ The SARS-CoV-2 virus mainly attacks the respiratory system and manifests itself with cough, difficulty breathing, pneumonia and acute respiratory distress syndrome (ARDS). However, the respiratory system is not the only organ/system affected by the disease. COVID-19 has a wide spectrum of symptoms and complications and can affect almost every human system and organ.⁵⁻¹³

Since the early stages of the pandemic, attention was drawn to the fact that the eye plays a crucial role in the course of COVID-19, serving as a gateway for infection through hand-to-eye contact or aerosol contact with the conjunctiva. This observation highlights the importance of eye protection during the pandemic and the awareness that ocular symptoms may be the first or even the only manifestation of COVID-19. It should be remembered that ocular symptoms can be observed at any stage of the disease and even after recovery.¹⁴⁻¹⁷ In January 2020, in Italy, a 65-year-old woman returning from China, presented with general symptoms typical of a viral infection and conjunctivitis, as evidenced by the presence of coronavirus RNA in a swab taken from her eye.^{18,19} Since the SARS-CoV-2 virus is constantly evolving, resulting in different subtypes that may have different symptoms, it is necessary to constantly update knowledge about the COVID-19 disease, including

possible new symptoms and to be particularly vigilant in the evaluation of patients during and after the disease.^{20,21} Ophthalmic pathologies resulting from SARS-CoV2 virus may affect all structures of the eye and manifest as ophthalmological symptoms due to the pathological effect of the virus on distant structures and tissues.

A review of the scientific literature on ophthalmological symptoms in the course of COVID-19 was conducted in databases such as PubMed, MEDLINE, Science Direct, Scopus, Scielo and Google Scholar, using the keywords: “COVID-19”, “SARS-CoV-2”, “eye” and “ophthalmology”. Due to the extensive literature, we focused on the most relevant publications in the English language from January 2020 to July 2023. These were primarily original works and reviews, but we also analyzed case reports.

Ophthalmological Symptoms in the Course of COVID-19

The latest studies and meta-analyses have confirmed a more frequent occurrence of ophthalmological symptoms in COVID-19 patients, ranging from 2 to 32%.²² The most common ophthalmological symptoms reported by patients were conjunctivitis, eye pain, swelling and redness. Often, the first visible ophthalmological symptom of COVID-19 infection was conjunctivitis.²³ In a 2020 study of 2347 patients with confirmed infection, 11.64% had ophthalmological symptoms related to the ocular surface, including eye pain and redness with discharge. The majority of patients (31.2%) reported eye pain.²³ In another study from 2021, the analysis of 7300 patients revealed the occurrence of ocular symptoms during COVID-19 infection in 11.03% of patients, including symptoms such as: dry eye or foreign body sensation (16%), redness (13.3%), tearing (12.8%), itching (12.6%), eye pain (9.6%) and discharge (8.8%). Conjunctivitis was the most frequently reported ophthalmological complaint in COVID-19 patients and occurred in 88.8% of respondents. Much less common ophthalmic pathologies have also been described, such as keratoconjunctivitis (2.2%), episcleritis (2.2%), scleritis (2.2%), posterior ischemic optic neuropathy and neuropathy (1.1%) (Figure 1).²⁴

The SERPICO-19 study published in 2020 revealed changes in the retina in the form of: retinal hemorrhages (9.25%), cotton wool foci (7.4%), dilated veins (27.7%), tortuous vessels (12.9%) (Figure 2).²⁵

In another study of 117 patients in a critical general condition, optic disc edema was observed in 11.1% of patients, cotton wool foci in 10.3% of patients, retinal hemorrhages in 4.3%, retinal edema in 4.3%, macular whitening in 4.3%, vascular tortuosity in 3.4%, optic disc inflammation in 2.6%, central retinal vein occlusion in 0.9%, and central retinal vein branch occlusion in 0.9%.^{26,27}

The literature on COVID-19 describes neuro-ophthalmological symptoms accompanying the infection, such as optic neuritis, optic disc edema, visual disturbances associated with posterior reversible encephalopathy syndrome, loss of vision due to stroke, cranial neuropathies, Miller Fisher syndrome, Adie’s pupils, myasthenia gravis, nystagmus, and eye movement disorders.^{28,29} The described symptoms of COVID-19 may vary in severity, from minor pain around the eye socket to a life-threatening fungal infection. Retrobulbar neuritis, inflammation of the lacrimal glands and ducts, and inflammation of the orbital tissues have been reported in the literature.^{30–32} In the latter part of this paper, we will present more detailed ophthalmological pathologies depending on the location in the eye in patients with confirmed COVID-19.

Table 1 shows the most significant ophthalmic pathologies associated with COVID-19, categorized according to their location.

Ophthalmological Symptoms in the Protective Apparatus of the Eye

Eyelids

COVID-19 symptoms affecting eyelids usually concern the edge of the eyelids and occur in the form of inflammation of the skin, the orifices of the meibomian glands, telangiectasia of the free edge of the eyelids, and secretion around the eyelashes.^{12,24,33} There are case reports of eyelash loss, eyelid dermatitis, and eyelid edema as symptoms of COVID-19.³⁴

Ophthalmological Symptoms in the Anterior Section of the Eyeball

Conjunctivitis

Papillary conjunctivitis is the most common ophthalmological symptom in the course of COVID-19 infection, observed at various stages of the disease and may be unilateral or bilateral.^{35,36} Prospective studies have shown the incidence of this type of inflammation in approximately 6% of patients with COVID-19, while retrospective studies have found

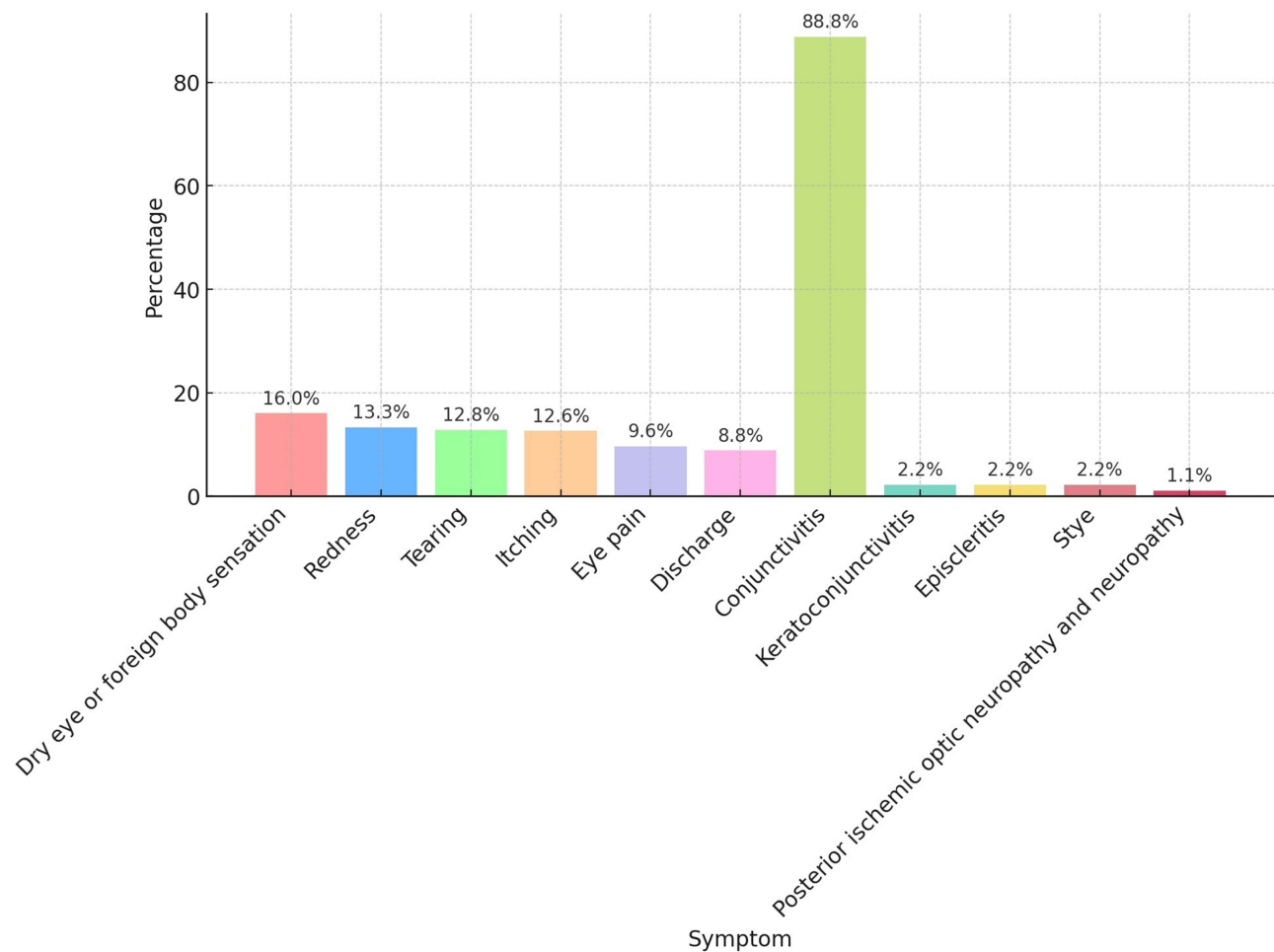


Figure 1 The frequency of occurrence of individual ophthalmological symptoms in COVID-19 patients who developed ophthalmological symptoms, based on a 2021 study of 7300 individuals, representing 11.03% of these patients.²⁴

a lower incidence of less than 1%.³⁷ In a study of 535 patients, conjunctival hyperemia was reported in 5% of patients, with 4% experiencing it as a symptom of disease onset.³⁶ In a meta-analysis published in 2021, of 19 cross-sectional studies covering 7300 individuals, 11.03% experienced ophthalmic symptoms. The most prevalent eye disease associated with COVID-19 was conjunctivitis, which occurred in 88.8% of patients with ocular symptoms.²⁴ The high rate of conjunctival pathology results not only from direct exposure of the conjunctiva to the pathogen, but also from the connection of the mucous membranes of the upper respiratory tract and the conjunctiva via the nasolacrimal duct.³⁸ In children, conjunctivitis associated with COVID-19 is usually the initial symptom of infection, has a mild course and is characterized by a rapid recovery. The main symptom of the disease is hyperemia with scant conjunctival secretion and rubbing of the eyes.¹⁹ Noteworthy, eye symptoms may be the first and only symptom of COVID-19 infection in children at any stage of the disease. Ophthalmic symptoms are more often observed in children with severe systemic disease. The literature describes myopia as a long-term and indirect consequence of COVID-19 in children.³⁹ There have also been reports of hemorrhagic and pseudomembranous conjunctivitis in severe cases of COVID-19 infection.⁴⁰

Few cases of keratitis coexisting with conjunctivitis and other symptoms are described in the literature. They are characterized as visible defects in the corneal epithelium and subepithelial infiltrates preceding the onset of respiratory symptoms. The mechanism of the corneal epithelium damage is not fully understood. Two opposing theories explain the pathomechanism of these changes. The first theory suggests direct damage to the corneal epithelium as a result of the virus's entry, while the second indicates the damaging effect of cytokines on the corneal epithelium.^{41–44}

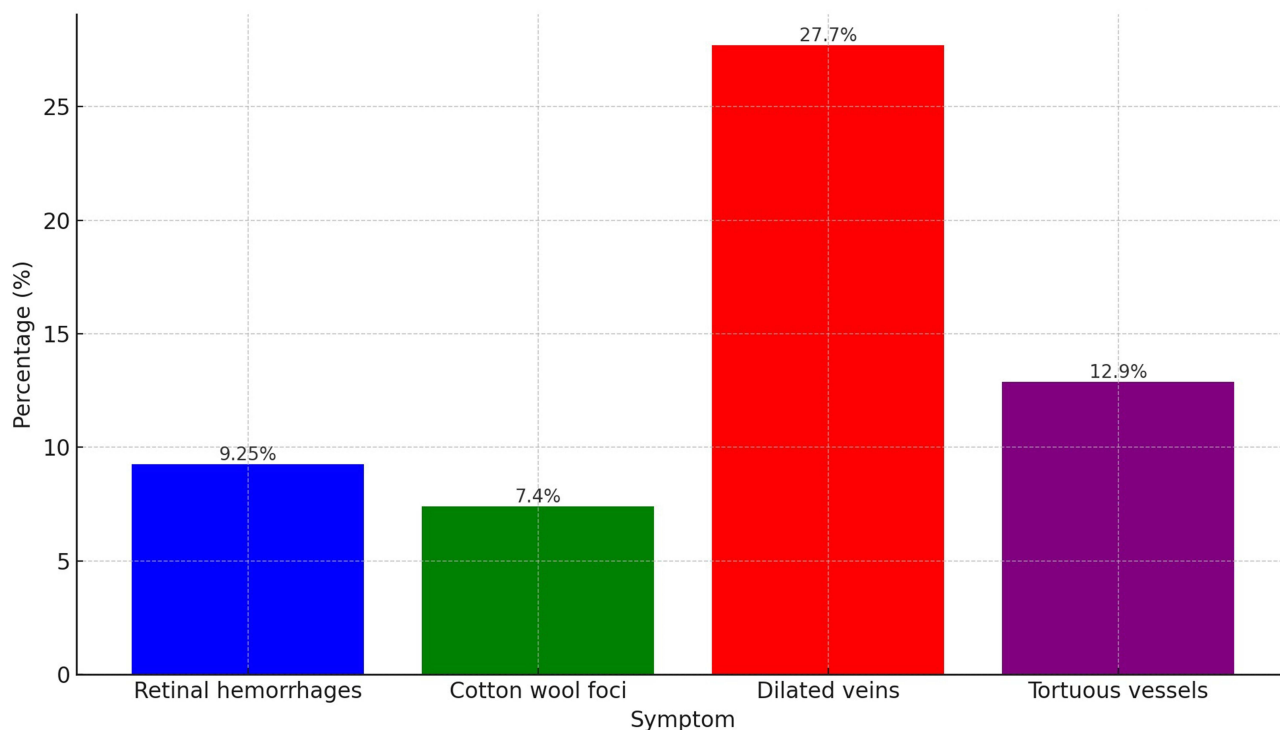


Figure 2 Changes observed in the retina based on the SERPICO-19 study published in 2020.²⁵

Scleritis and Episcleritis

Scleritis and episcleritis are described as rare symptoms of COVID-19, often preceding or co-occurring with other ophthalmological symptoms, and even as the first symptom of COVID-19 preceding the onset of systemic symptoms such as headache, shortness of breath, cough, and fever.⁴⁵⁻⁴⁸ Case reports of nodular scleritis and necrotizing episcleritis in the course of COVID-19 are available.^{48,49} Severe binocular scleritis has also been reported as the main symptom or one of the main symptoms in children suffering from multisystem inflammatory syndrome in children associated with COVID-19 (MIS-C).^{50,51}

Table 1 Type of Ophthalmic Pathology in COVID-19 Disease Depending on the Location

Location of Ophthalmic Symptoms	Type of Pathology
Ophthalmological symptoms in the protective apparatus of the eye (Eyelids)	Inflammation of the skin Inflammation of the orifices of the Meibomian glands Telangiectasia of the free edge of the eyelids Secretion around the eyelashes. Eyelash loss Eyelid dermatitis Eyelid edema
Ophthalmological symptoms in the anterior section of the eyeball	Conjunctivitis Scleritis and episcleritis
Ophthalmological symptoms in the posterior section of the eyeball	Central retinal vein occlusion Central retinal artery occlusion Acute macular neuroretinopathy (AMN) Acute central medial maculopathy (PAMM) Retinitis, acute retinal necrosis (ARN) Choroiditis and other retinal changes

(Continued)

Table 1 (Continued).

Location of Ophthalmic Symptoms	Type of Pathology
Neuro-ophthalmological symptoms	Optic neuritis and other optic nerve disorders Pupil abnormalities Visual field defects and visual disturbances of central origin Cranial nerve palsy Nystagmus and abnormal eye movement
Orbital symptoms	Mucormycosis Post-orbital pain Inflammation of the orbital tissues Inflammation of the lacrimal gland

Ophthalmological Symptoms in the Posterior Section of the Eyeball

Ophthalmological symptoms related to the posterior segment of the eye are not pathognomonic for COVID-19. The SARS-CoV-2 virus, like other viruses, can cause inflammatory, vascular and neuronal changes in the posterior segment of the eye.¹² To assess the symptoms occurring in the posterior segment of the eye during COVID-19, the most useful methods are optical coherence tomography (OCT) and fluorescein angiography (AF), which allow the detection of changes and their degree of advancement, including cotton wool foci, retinal hemorrhages, central serous retinopathy, phlebitis, optic discitis, uveitis, multifocal retinitis, necrotizing retinitis, central retinal artery and vein occlusion, and Purtscher retinopathy.⁵²

Central Retinal Vein Occlusion

Ophthalmic imaging such as fluorescein angiography (AF) and optical coherence tomography (OCT) used to visualize the fundus of the eye in the case of central retinal vein occlusion in the course of COVID-19 did not show any differences in the image compared to retinal vein occlusion caused by other factors (Figure 3). Patients with COVID-19, regardless of the severity of the disease, duration, or systemic symptoms, often have hypercoagulability and increased inflammatory markers such as D-dimer, interleukin-6, prothrombin time (PT), activated partial thromboplastin time (APTT), fibrinogen and cytokines. Moreover, the hypoxia-induced coagulation cascade in pneumonia is enhanced by endothelial cell activation and tissue factor secretion as a result of hypoxia.^{53–56} Blood hypercoagulability as a result of COVID-19 disease is one of the main elements of pathology in the eyeballs of patients in the course of SARS-CoV-2 virus infection and is independent of standard risk factors for central retinal vein thrombosis, such as hypertension, diabetes, and obesity.^{54,57,58} It is noted in the literature that the cause of hypercoagulable state is unclear, whether the coagulation

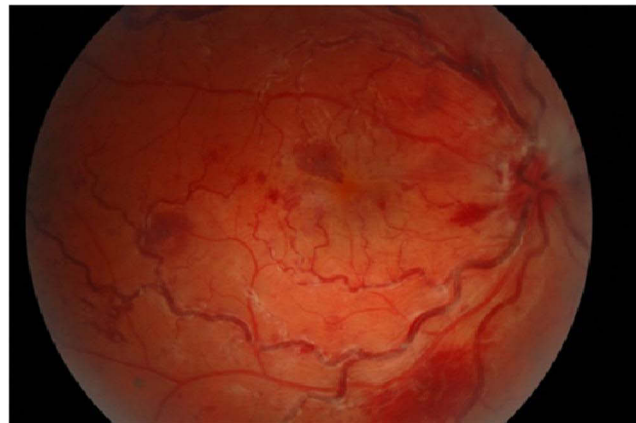


Figure 3 Central retinal vein occlusion in a 26-year-old female patient with Covid-19 infection and no other risk factors (Picture from the collection of the Ophthalmology Department, Medical University of Białystok).

cascade is directly activated by the virus or may result from local or systemic inflammation. The mechanism is not fully understood and explained.⁵⁹

Central Retinal Artery Occlusion, Acute Macular Neuroretinopathy (AMN), Acute Central Medial Maculopathy (PAMM)

There are reports of sudden painless loss of vision or significant deterioration of visual acuity and central and paracentral scotomas appearing in the visual field in patients suffering from COVID-19. It is associated with occlusion of the central retinal artery, acute macular neuroretinopathy (AMN), paracentral acute middle maculopathy (PAMM) or the simultaneous occurrence of these pathologies. The available literature describes cases in which it is indicated that the etiology of these symptoms is caused by an ischemic mechanism affecting the entire retina or limited to sectors vascularized by one of the branches of the central retinal artery.^{60,61} It may also affect the posterior pole in an isolated manner and is related to the mechanism of ischemia of the deep capillary plexuses supplied exclusively by the ciliary system.^{62,63}

Ophthalmological symptoms of COVID-19 at the fundus of the eye, occurring in central retinal artery occlusion, AMN, PAMM (Figure 4), such as retinal hemorrhages in all quadrants with Roth spots, retinal edema, swelling and blurring of the disc border of optic nerve and the cherry sign are not characteristic of COVID-19 and may occur in other diseases.^{63–65} In most cases reported in the literature, the ischemic mechanism is explained by hypercoagulability resulting from the hyperinflammatory reaction induced by the SARS-CoV2 virus.^{66,67} However, obstruction without a hypercoagulable state and additional risk factors has also been reported.⁶⁸ Therefore, we cannot clearly determine what induces the hypercoagulable state and whether the coagulation cascade is directly activated by the virus or perhaps it is the result of local or systemic inflammation.⁵⁹

Retinitis, Acute Retinal Necrosis (ARN), Choroiditis and Other Retinal Changes

Changes affecting the choroid and retina in the course of infectious and inflammatory diseases are common, especially in patients whose immunity has been impaired for various reasons. Infectious diseases often involve inflammation of the uvea and retina. These conditions are caused by either systemic disease or local inflammation. COVID-19 has also been associated with retinal and choroid pathologies. There are few descriptions and reports of uveitis during COVID-19.^{69,70} It is believed that the SARS-CoV2 virus is responsible for the inflammatory mechanism of highly vascularized tissue and may cause chorioretinitis.⁷¹ A case of anterior uveal involvement associated with tubulointerstitial nephritis and uveitis (TINU) syndrome following COVID-19 infection has been described in a pediatric patient. The authors of the report suggest an autoimmune etiology of uveitis, with the SARS-Cov2 virus as the initiating mechanism for the infection.⁷² Figure 5 demonstrates uveitis in a 48-year-old patient.

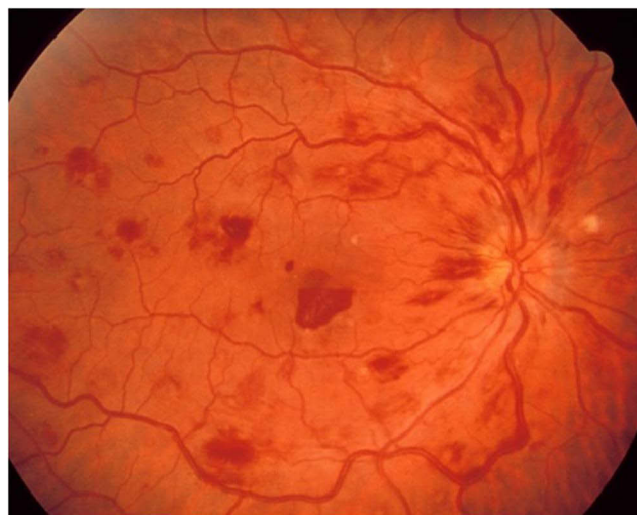

Figure 4 Paracentral acute middle maculopathy in a 56-year-old male patient with Covid-19 infection (Picture from the collection of the Ophthalmology Department, Medical University of Białystok).

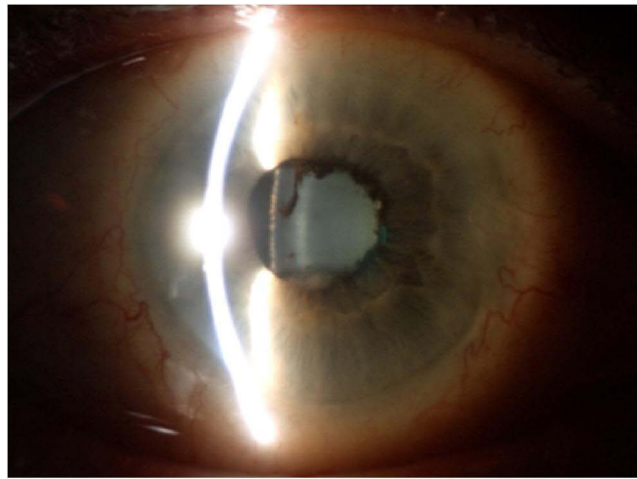


Figure 5 Uveitis during COVID-19 in a 48-year-old female patient (Picture from the collection of the Ophthalmology Department, Medical University of Białystok).

Acute retinal necrosis manifests itself in the fundus of the eyes with yellow-white infiltrates with clear boundaries; retinal hemorrhages may also occur and ultimately lead to tractional retinal detachment. Pathology may also involve vessels. Arteritis may lead to preretinal neovascularization and, consequently, to vitreous hemorrhages. Other ophthalmological symptoms, such as peripheral retinal hemorrhages, macular discoloration, sectoral retinal pallor, flame-shaped hemorrhages, hard exudates, cotton wool foci, vasoconstriction, and vascular tortuosity, cannot be clearly attributed to the action of the SARS-CoV-2 virus due to the effect of other factors such as medications and chronic diseases of the patient.^{25,73,74}

Acute retinal necrosis (ARN) is a rare disease, most common in patients whose immunity has been compromised for various reasons. Cases of acute retinal necrosis (ARN) have been reported in the literature due to SARS-CoV2 virus infection or COVID-19 disease.⁷⁵

Neuro-Ophthalmological Symptoms

It is estimated that approximately one third of people with COVID-19 experience neurological complications, especially in more severe infections.⁷⁶ The most common serious neurological symptoms of COVID-19 are acute cerebrovascular disorders and fluctuating states of consciousness.⁷⁷ In a retrospective study conducted in Wuhan, neurological symptoms were observed in 36.4% of hospitalized patients.⁷⁸ Most often, these symptoms are associated with more severe cases of COVID-19.^{78,79} Long-term hospitalizations and deaths resulted from ischemic strokes in COVID-19 and often affected the visual pathways.^{80,81} The conclusions and suggestions resulting from these observations are that ischemic strokes in patients with COVID-19 are more serious and more likely to lead to disability than strokes in people not infected with SARS-CoV2.⁸² In the case of isolated cranial neuropathies affecting the eyes, they are usually observed in mild to moderate COVID-19 cases that resolve spontaneously or with standard treatment.^{83,84}

Various mechanisms of the probable action of the SARS-CoV-2 virus are described in the literature. It is believed that the SARS-CoV2 virus can act directly on nervous tissue through hypoxia, causing hypercoagulability, inflammation and cytokine storm. An ascending route of infection through the olfactory nerve is also considered. Direct entry of the virus occurs by binding to the ACE-2 receptor, found on alveolar epithelial cells, neurons and glial cells.⁸⁵ These mechanisms may be responsible for the neuro-ophthalmic symptoms of COVID-19.^{28,79}

The SARS-COV-2 virus can affect brain tissue, leading to pathologies in the visual pathways. It can cause various CNS conditions such as seizures, anosmia, dysgeusia, posterior reversible encephalopathy syndrome (PRES), neuro-myelitis optica (NMO), myelin oligodendrocyte glycoprotein (MOG)-related disease, acute disseminated encephalomyelitis (ADEM), cerebral venous sinus thrombosis (CVST), and cerebral strokes.^{28,80–82} Additionally, it may affect the peripheral nervous system, causing Guillain-Barré syndrome, Miller Fisher syndrome, cranial polyneuritis, and myasthenia gravis.^{86–90}

Optic Neuritis and Other Optic Nerve Disorders

There are publications in the literature describing cases of optic neuritis associated with COVID-19 disease, where no cause other than SARS-CoV-2 virus infection could be identified (Figure 6A and B).^{79,91,92} COVID-19 has been observed to precede the onset of optic neuritis in NMO disorders^{77,93} and MOG-related disorders.^{76,92,94–96} Cases of optic neuritis have also been reported in children in association with COVID-19 disease.⁹⁷ A case of a 13-year-old child with optic neuritis in the course of multisystem inflammatory syndrome in children (MIS-C) has been described in literature.⁹⁸

Furthermore, a case has been reported in which COVID-19 caused optic neuritis in association with uveitis, leading to optic nerve atrophy despite the use of corticosteroid therapy. However, the patient only received oral prednisone, without intravenous steroid pulses. The authors of this case suggest that the optic nerve atrophy may have been caused by an

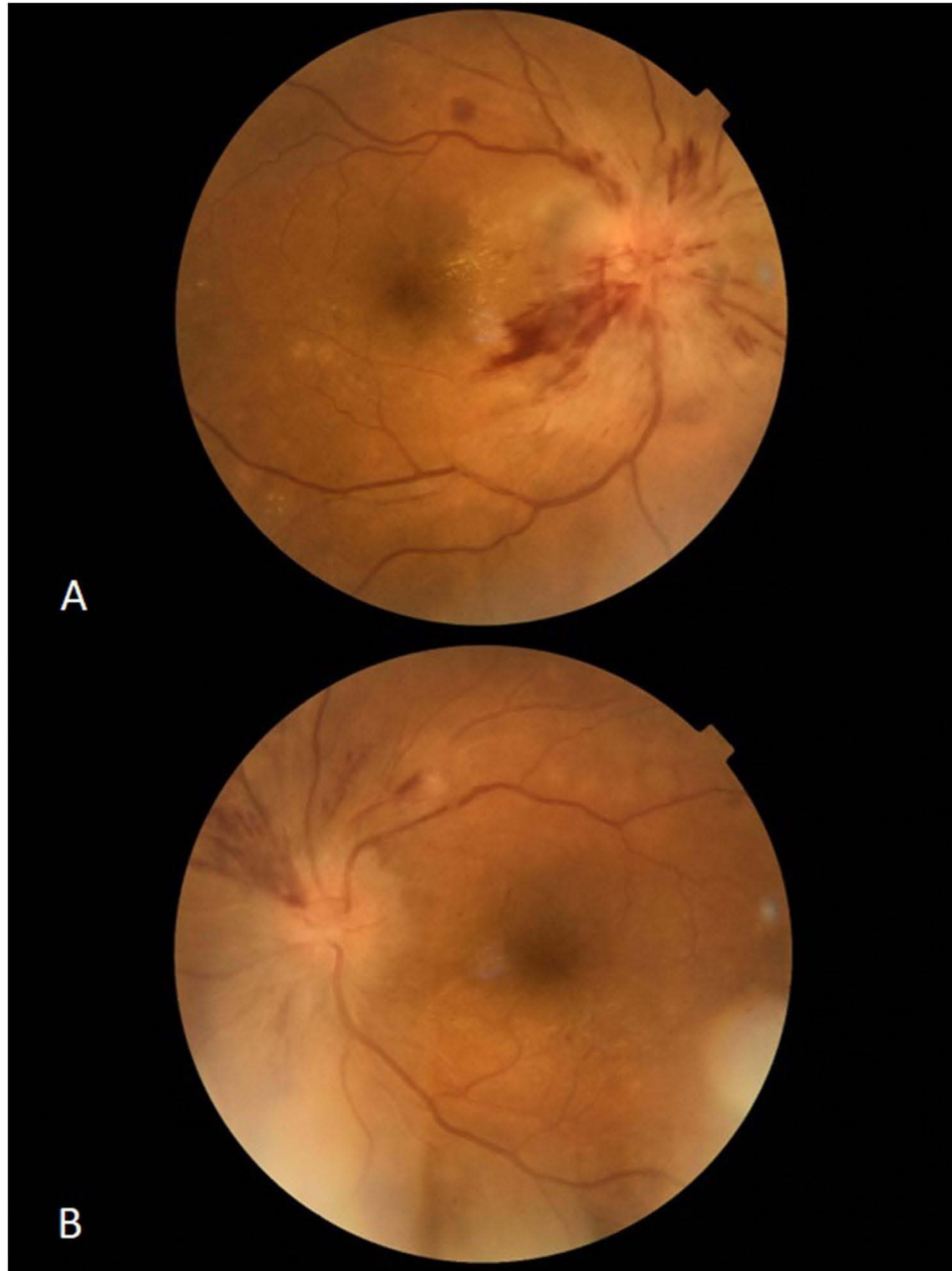


Figure 6 Bilateral optic neuritis associated with Covid-19 disease with no evidence of infection other than SARS-CoV-2 virus in a 45-year-old male patient. (A) right eye, (B) left eye (Picture from the collection of the Ophthalmology Department, Medical University of Bialystok).

inflammatory reaction or ischemia caused by hypercoagulability in the course of COVID-19.⁶⁹ In March 2022, a case report was published describing a patient with COVID-19 who developed thrombosis of the left internal carotid artery leading to ischemia of the left optic nerve.⁹⁹

There is also a report of a case of post-COVID-19 bilateral retrobulbar optic neuritis in a 56-year-old woman, which was characterized by sudden loss of visual acuity, painful ocular motility of both eyes and abnormal color perception. The patient was treated with steroid therapy with very good results and a significant improvement in visual acuity and color perception was achieved.¹⁰⁰

Pupil Abnormalities

In the context of COVID-19, cases of tonic pupil (Adie's pupil), both unilateral¹⁰¹ and bilateral¹⁰², have been observed. It is a symptom resulting from weakened parasympathetic innervation of the pupillary sphincter muscle, which leads to a weak reaction of the pupil to light, while relatively good accommodation is maintained. There is a report of a patient with bilateral tonic mydriasis due to COVID-19 and additional multifocal uveitis.¹⁰³ Ordás et al described a case of tonic pupil with trochlear nerve palsy associated with COVID-19.¹⁰⁴ There is no consensus in the available literature on how exactly the SARS-CoV2 virus causes the formation of a tonic pupil (Adie's pupil). According to the hypothesis raised by most researchers, in COVID-19 the tonic pupil is the result of delayed immune damage caused by the viral infection and not the result of a direct effect of the virus on the central nervous system.¹⁰³

Horner's syndrome, with eyelid ptosis and pupil abnormalities can occur in COVID-19 and refers to patients with involvement of the upper part of the lungs in whom other possible causes of Horner's syndrome have been excluded.^{85,105}

Visual Field Defects and Visual Disturbances of Central Origin

SARS-CoV-2 infection has the ability to induce inflammation and hypercoagulability, which contributes to an increased risk of stroke.^{81,103} Cases of ischemic stroke associated with SARS-CoV-2 infection have been described in the literature, leading to visual field disturbances²⁸ and even cortical blindness due to bilateral occipital stroke.^{28,80} Bondira et al reported the case of a patient with COVID-19 who experienced bilateral occipital stroke, leading to partial monotonous right hemianopia and reading difficulties.⁸¹ Priftis et al reported the case of a patient with COVID-19 who had a left occipital and temporal ischemic stroke, which resulted in alexia syndrome without agraphia and right-sided monomial visual field defects.⁸²

Cases of COVID-19-induced hypertensive encephalopathy (PRES) have been reported, affecting the cerebral cortex causing transient loss of vision or even hallucinatory palinopsia.^{106,107} A case of cerebral venous sinus thrombosis (CVST) associated with COVID-19 has also been reported, but is rare. Only a few cases of CVST have reported blurred vision and optic nerve edema.^{108,109} The disproportionately low incidence of visual disturbances in COVID-19-related CVST may be due to the severity of other symptoms or altered level of consciousness of the patients.

Additionally, cases of vision loss due to pituitary infarction have been reported in the setting of COVID-19.^{110,111}

Cranial Nerve Palsy

Due to COVID-19, paralysis of the third, fourth, sixth and seventh cranial nerves has been observed. They may occur as primary, isolated paralysis, but also in the context of broader conditions such as Miller Fisher syndrome, Guillain-Barré syndrome or myasthenia gravis.^{104,112–114}

Cases of isolated oculomotor nerve palsy have been reported, both with and without pupillary involvement.^{112,115} Similarly, isolated abducens nerve palsy has been reported associated with COVID-19.^{83,87} There are also known cases of unilateral trochlear nerve palsy with contralateral tonic pupil, as well as bilateral palsy of this nerve in the course of cerebral vasculitis associated with COVID-19.^{104,116}

Cases of isolated facial nerve palsy associated with COVID-19 have also been reported. Lima et al also described palsy of the VII nerve coexisting with ipsilateral VI nerve palsy.⁸⁴

Drugs such as hydroxychloroquine, azithromycin, corticosteroids, and intravenous immunoglobulins have been used in treatment of COVID-19-related cranial neuropathies. However, there is no clear data on the benefits of the treatment. These neuropathies also appear in the context of Miller Fisher and Guillain-Barré syndrome.^{87,88} Dinkin et al described a patient with COVID-19 in whom the use of intravenous immunoglobulins led to partial improvement of deficits associated with presumed Miller Fisher syndrome.⁸⁷ Gutiérrez-Ortiz et al reported a similar case with Miller Fisher

syndrome in which most of the deficits resolved after intravenous infusion of immunoglobulins.⁸⁸ Sansone et al showed that among patients with Guillain-Barré syndrome associated with SARS-CoV-2, the first neurological symptoms appeared approximately 10 days after the onset of SARS-CoV-2 symptoms.⁸⁶

Additionally, it has been reported that COVID-19 may be responsible for the emergence of new cases of myasthenia gravis.^{89,90} Restivo et al described in detail three patients whose myasthenic symptoms appeared 4–7 days after the initial symptoms of COVID-19.⁸⁹

Nystagmus and Abnormal Eye Movement

Various etiologies such as acute labyrinthitis, benign paroxysmal positional vertigo, myelitis, and Bickerstaff's encephalitis can lead to COVID-19-related acquired nystagmus.^{117–121} Several cases of opsoclonus and myoclonus syndrome (OMAS) have been reported in COVID-19 patients, with no identified causes other than SARS-CoV-2 virus infection.^{122–124} In addition to SARS-CoV-2, OMAS is also associated with other infections such as HIV, West Nile virus, Epstein-Barr virus, and enterovirus.¹²³ OMAS therapy for COVID-19, including intravenous immunoglobulin, levetiracetam, sodium valproate, clonazepam, and corticosteroids, has shown partial or complete recovery of patients. This suggests a parainfectious immune mechanism of COVID-19-related OMAS, as noted by Emamikhah et al.¹²²

Orbital Symptoms

Mucormycosis

Rhino-orbital cerebral mucormycosis (ROC), a form involving the orbit, is more frequently observed in patients with severe COVID-19, especially those with diabetes. Colonization of the nasal mucosa contributes to its occurrence.^{125,126} Diabetes, through hyperglycemia, impairs immune function, which increases the risk of mucormycosis - a life-threatening infection. COVID-19 patients are at risk of mucormycosis due to the weakened immune system caused by the virus and comorbidities such as kidney failure.^{127,128} The risk increases during treatment with corticosteroids.^{12,30} Moreover, the use of antibiotics, steroids and oxygen masks during the treatment of severe forms of COVID-19 may increase the risk of infection.¹²⁹

Post-Orbital Pain

COVID-19 can lead to symptoms such as bilateral retro-orbital pain, which is pronounced and may mimic dengue-like conditions. This highlights the fact that COVID-19 symptoms are often non-specific, able to mimic various common conditions.¹²

Inflammation of the Orbital Tissues

Orbital cellulitis and sinusitis were identified in two adolescents presenting with acute, unilateral orbital swelling and pain. Preoperative RT-PCR testing confirmed the presence of COVID-19.³² Another case involved a 76-year-old man who had an orbital abscess with perforation of the eyeball. Surgical intervention revealed sterile nasal mucosa, which pointed to thromboembolic complications of COVID-19 as a possible cause of these phenomena.¹³⁰ Other reports indicate additional orbital complications associated with COVID-19, such as myositis.¹³¹

Inflammation of the Lacrimal Gland

Inflammation of the lacrimal gland, called dacryoadenitis, is usually caused by a viral infection, is a leading cause of painful lesions in this gland in young adults.^{132,133} In one case, the patient had contact with individuals infected with COVID-19, which resulted in swelling and pain in the eyelids for four days. Tests for IgM and IgG antibodies were positive, while other tests for autoimmune and infectious diseases such as tuberculosis, mumps, adenovirus, Epstein-Barr virus (EBV), HSV, and HZV were negative. This suggests that acute inflammation of the lacrimal glands may be a late complication of COVID-19. The virus may have reached the lacrimal gland through both the tear ducts and directly through the bloodstream, leading to inflammation as a result of the immune response to the virus. Treatment with systemic steroids has been found to be effective.^{12,132}

Adverse Ophthalmic Reactions to COVID-19 Vaccinations

The COVID-19 pandemic prompted accelerated and intensive efforts towards developing effective vaccines against COVID-19. These efforts resulted in several vaccines being authorized for use in the human population. With the

widespread use of these vaccines, there were reports of adverse reactions as well as ophthalmic symptoms. A review of the available literature showed that ocular symptoms following vaccination varied, occurring in different locations and at different times, similar to ophthalmic symptoms during COVID-19. In most cases, post-vaccination complications were mild, but there were also reports of severe ocular complications.

Ocular adverse events included eyelid edema and erythema; purpuric lesions on the eyelid; reactivation of herpes simplex keratitis; corneal epithelitis caused by the herpes zoster virus; acute graft rejection in repeat penetrating keratoplasty (PKP) cases; dual graft rejection in post-PK situations; acute endothelial rejection following Descemet's Membrane Endothelial Keratoplasty (DMEK); reactivation of Vogt-Koyanagi-Harada disease (VKH); anterior and posterior uveitis; scleritis; bilateral choroiditis; toxoplasma retinochoroiditis; pars planitis; retinal vasculitis; bilateral panuveitis in cases of new-onset Behcet's disease; multiple evanescent white dot syndrome (MEWDS); acute macular neuroretinopathy; retinal vein occlusions; non-arteritic ischemic optic neuropathy; activation of quiescent choroidal neovascularization (CNV) due to myopia or uveitis; central serous chorioretinopathy; bilateral acute anterior ischemic optic neuropathy (AAION); bilateral acute zonal occult outer retinopathy (AZOOR); PAMM, AMN; disc edema and central serous chorioretinopathy (CSCR); branch retinal arterial occlusion; combined arterial and venous occlusion; nerve fiber layer infarction; bilateral AMN; episcleritis; Bell's palsy; abducens nerve palsy; optic neuritis; multiple cranial nerve palsies; Miller Fisher syndrome; bilateral superior ophthalmic vein thrombosis; immune thrombocytopenic purpura (ITP) and ischemic stroke; thyroid eye disease (TED); acute hemorrhagic conjunctivitis in systemic lupus erythematosus.¹³⁴⁻¹³⁶

There are publications that hypothesize that the human body's immune response to COVID-19 vaccinations may be involved in the pathogenesis of the ocular adverse effects post-COVID-19 vaccination.^{135,137}

While the occurrence of ocular symptoms is significantly less common in vaccinated individuals compared to those infected with COVID-19, it remains important for healthcare professionals to recognize potential links between COVID-19 vaccinations and eye-related symptoms. This awareness is crucial for prompt diagnosis and management of visual impairments or severe complications that could be life-threatening.¹³⁸

Treatment Approaches

Most patients with eye complaints secondary to the COVID-19 infection do not require targeted ophthalmic treatment.¹³⁸ COVID-19-associated conjunctivitis is mild in most cases and resolves within a few days without targeted therapy. In the case of secondary bacterial infection, antibiotics drops may be necessary.¹³⁹ Topical anti-inflammatory therapies play a role in keratitis, episcleritis, and uveitis. Patients with anterior or posterior uveitis should be treated with systemic and/or topical steroid drops and cyclopentolate until symptoms are resolved.^{140,141} Careful ophthalmic examinations (including funduscopy) in high-risk patients with COVID-19 is important, since systemic inflammation and the generation of thrombosis in the microvasculature may predispose patients to central retinal artery or vein occlusion. The inflammation and thromboembolic components of these diseases further support the use of systemic corticosteroids and anticoagulation based on guidelines for patients with severe COVID-19.¹⁴²

General inflammation can lead to demyelinating neuropathy as a likely etiology. Most patients do not need to receive specific treatment. Diplopia, ophthalmoplegia and ptosis have also been described in the context of Guillain-Barre and Miller-Fisher syndromes, which may be caused by eye viral inflammation of COVID-19. Some of these patients experienced at least a partial resolution of their symptoms with intravenous immunoglobulin treatment.¹⁴³

Although the neuro-ophthalmic complications of COVID-19 usually do not require targeted treatments, rapid recognition of these entities is essential, as these patients can benefit from interdisciplinary care involving ophthalmologists and neurologists and will require follow-up monitoring. Furthermore, proning protocols (in the position of patients in respiratory distress in their stomachs) have been associated with ischemic optic neuropathy and visual loss, again highlighting the importance of physical examination and pressure redistribution in minimizing iatrogenic injuries in ventilated patients with COVID-19.¹⁴⁴

Summary

The medical experience accumulated during the COVID-19 pandemic demonstrates complexity and unpredictability of the effects of this disease. One of the less obvious aspects of the infection is the occurrence of ophthalmological symptoms.

Although they are not dominant or common, they can appear at any stage of COVID-19 disease. Moreover, in some cases they may be the first symptoms of a disease, signaling other, more systemic ailments. The role of ophthalmologists in identifying and treating these symptoms is undeniably important. When treating COVID-19 patients, it is important to recognize both typical and atypical ophthalmic symptoms associated with the infection. However, knowledge on this subject should extend beyond the circle of eye disease specialists. All doctors, regardless of their specialty, should be aware of the possibility of such symptoms and ocular complications. Additionally, physicians treating COVID-19 should be alert to the specific risks that may be associated with this disease. Therefore, it is important that ophthalmology specialists participate in treatment teams dealing with COVID-19 patients. Their expertise in the diagnosis and treatment of eye diseases may be crucial in identifying and appropriately treating potential eye complications.

Both ophthalmologists and general practitioners need to remain vigilant regarding the potential, though infrequent, ocular side effects following COVID-19 vaccination. While ocular symptoms occur less frequently in vaccinated individuals compared to those infected with COVID-19, it is crucial for medical professionals to recognize potential links between COVID-19 vaccinations and eye-related symptoms. This knowledge is essential for the prompt identification and management of visual impairments or severe, potentially fatal complications.

Disclosure

The authors report no conflicts of interest in this work.

References

- Ahn DG, Shin HJ, Kim MH, et al. Current Status of Epidemiology, Diagnosis, Therapeutics, and Vaccines for Novel Coronavirus Disease 2019 (COVID-19). *J Microbiol Biotechnol.* 2020;30(3):313–324. doi:10.4014/jmb.2003.03011
- Galiatsatos P, Jones V, Bryan J, et al. The Health Education and Training (HEAT) Corps: a Medical–Community Collaboration Response during the COVID-19 Pandemic. *Int J Environ Res Public Health.* 2023;20(3):1829. doi:10.3390/ijerph20031829
- Yüce M, Filiztekin E, Özkaya KG. COVID-19 diagnosis -A review of current methods. *Biosens Bioelectron.* 2021;172:112752. doi:10.1016/j.bios.2020.112752
- Mathieu E, Ritchie H, Rodés-Guirao L, et al. Coronavirus Pandemic (COVID-19). Our World in Data; 2020. Available from: <https://ourworldindata.org/covid-vaccinations>. Accessed June 9, 2023.
- Carod-Artal FJ. Neurological complications of coronavirus and COVID-19. *Rev Neurol.* 2020;70(9):311–322. doi:10.33588/rn.7009.2020179
- D'Alessandro E, Kawasaki A, Eandi CM. Pathogenesis of Vascular Retinal Manifestations in COVID-19 Patients: a Review. *Biomedicines.* 2022;10(11):2710. doi:10.3390/biomedicines10112710
- Doerschug KC, Schmidt GA. Pulmonary Aspects of COVID-19. *Ann Rev Med.* 2022;73(1):81–93. doi:10.1146/annurev-med-042220-014817
- El-Anwar MW, Elzayat S, Fouad YA. ENT manifestation in COVID-19 patients. *Auris Nasus Larynx.* 2020;47(4):559–564. doi:10.1016/j.anl.2020.06.003
- Long B, Carius BM, Chavez S, et al. Clinical update on COVID-19 for the emergency clinician: presentation and evaluation. *Am J Emerg Med.* 2022;54:46–57. doi:10.1016/j.ajem.2022.01.028
- Panahi Y, Gorabi AM, Talaei S, et al. An overview on the treatments and prevention against COVID-19. *Virologia.* 2023;20:23. doi:10.1186/s12985-023-01973-9
- Raveendran AV, Jayadevan R, Sashidharan S. Long COVID: an overview. *Diabetes Metab Syndr.* 2021;15(3):869–875. doi:10.1016/j.dsx.2021.04.007
- Sen M, Honavar SG, Sharma N, Sachdev MS. COVID-19 and Eye: a Review of Ophthalmic Manifestations of COVID-19. *Indian J Ophthalmol.* 2021;69(3):488–509. doi:10.4103/ijo.IJO_297_21
- Soares MN, Eggelbusch M, Naddaf E, et al. Skeletal muscle alterations in patients with acute Covid-19 and post-acute sequelae of Covid-19. *J Cachexia, Sarcopenia Muscle.* 2022;13(1):11–22. doi:10.1002/jcsm.12896
- Goel R, Arora R, Chhabra M, Kumar S. Viral shedding in tears of COVID-19 cases presenting as conjunctivitis. *Indian J Ophthalmol.* 2020;68(10):2308. doi:10.4103/ijo.IJO_2567_20
- Keyal K, Wang F. Ophthalmic Manifestations in COVID-19 Patients, a Review. *Discov Med.* 2021;32(165):7–11.
- Rokohl AC, Grajewski RS, Matos PAW, Kopecky A, Heindl LM, Cursiefen C. Ocular Involvement in COVID-19: conjunctivitis and More. *Klin Monbl Augenheilkd.* 2021;238(5):555–560. doi:10.1055/a-1344-8138
- Scalinci SZ, Trovato Battagliola E. Conjunctivitis can be the only presenting sign and symptom of COVID-19. *IDCases.* 2020;20:e00774. doi:10.1016/j.idcr.2020.e00774
- Colavita F, Lapa D, Carletti F, et al. SARS-CoV-2 Isolation From Ocular Secretions of a Patient With COVID-19 in Italy With Prolonged Viral RNA Detection. *Ann Intern Med.* 2020:M20–1176. doi:10.7326/M20-1176
- Yener AÜ. COVID-19 and the Eye: ocular Manifestations, Treatment and Protection Measures. *Ocul Immunol Inflamm.* 2021;29(6):1225–1233. doi:10.1080/09273948.2021.1977829
- Gong X, Khan A, Wani MY, Ahmad A, Duse A. COVID-19: a state of art on immunological responses, mutations, and treatment modalities in riposte. *J Infect Public Health.* 2023;16(2):233–249. doi:10.1016/j.jiph.2022.12.019
- Wang Q, Iketani S, Li Z, et al. Alarming antibody evasion properties of rising SARS-CoV-2 BQ and XBB subvariants. *Cell.* 2023;186(2):279–286.e8. doi:10.1016/j.cell.2022.12.018

22. Hu K, Patel J, Swiston C, Patel BC. *Ophthalmic Manifestations of Coronavirus (COVID-19)*. StatPearls Publishing; 2023.
23. Willcox MD, Walsh K, Nichols JJ, Morgan PB, Jones LW. The ocular surface, coronaviruses and COVID-19. *Clin Exp Optom*. 2020;103(4):418–424. doi:10.1111/coo.13088
24. Nasiri N, Sharifi H, Bazrafshan A, Noori A, Karamouzian M, Sharifi A. Ocular Manifestations of COVID-19: a Systematic Review and Meta-analysis. *J Ophthalmic Vis Res*. 2021;16(1):103–112. doi:10.18502/jovr.v16i1.8256
25. Invernizzi A, Torre A, Parrulli S, et al. Retinal findings in patients with COVID-19: results from the SERPICO-19 study. *EClinicalMedicine*. 2020;27:100550. doi:10.1016/j.eclinm.2020.100550
26. Romero-Castro RM, Ruiz-Cruz M, Alvarado-de la Barrera C, et al. POSTERIOR SEGMENT OCULAR FINDINGS IN CRITICALLY ILL PATIENTS WITH COVID-19. *RETINA*. 2022;42(4):628. doi:10.1097/IAE.0000000000003457
27. Kollar R, Patel SD, Krothapalli N, et al. Optic Perineuritis in an Asymptomatic SARS-CoV-2 Infection. *Neurologist*. 2022. doi:10.1097/NRL.0000000000000472
28. Tisdale AK, Dinkin M, Chwalisz BK. Afferent and Efferent Neuro-Ophthalmic Complications of Coronavirus Disease 19. *J Neuroophthalmol*. 2021;41(2):154–165. doi:10.1097/WNO.0000000000001276
29. Tisdale AK, Chwalisz BK. Neuro-ophthalmic manifestations of coronavirus disease 19. *Curr Opin Ophthalmol*. 2020;31(6):489–494. doi:10.1097/ICU.0000000000000707
30. Bhattacharyya A, Sarma P, Sharma DJ, et al. Rhino-orbital-cerebral-mucormycosis in COVID-19: a systematic review. *Indian J Pharmacol*. 2021;53(4):317–327. doi:10.4103/ijp.ijp_419_21
31. Ruyi W, Hsu SY, Tsai HL, Chen CT, Tseng CP, Chen WT. COVID-19 mimicking dengue fever with the initial manifestation of retro-orbital pain – a Rare Case. *J Formos Med Assoc*. 2020;119(11):1715–1716. doi:10.1016/j.jfma.2020.05.039
32. Turbin RE, Wawrzusin PJ, Sakla NM, et al. Orbital cellulitis, sinusitis and intracranial abnormalities in two adolescents with COVID-19. *Orbit*. 2020;39(4):305–310. doi:10.1080/01676830.2020.1768560
33. Meduri A, Oliverio GW, Mancuso G, et al. Ocular surface manifestation of COVID-19 and tear film analysis. *Sci Rep*. 2020;10(1):20178. doi:10.1038/s41598-020-77194-9
34. Acar Eser N, Serbest Ceylanoglu K, Malkoc Sen E. Unilateral Ciliary Madarosis in a Child After Coronavirus Disease 2019 (COVID-19) Infection. *Ophthalmic Plast Reconstr Surg*. 2023;39(1):e1–e3. doi:10.1097/IOP.0000000000002295
35. Sindhuja K, Lomi N, Asif MI, Tandon R. Clinical profile and prevalence of conjunctivitis in mild COVID-19 patients in a tertiary care COVID-19 hospital: a retrospective cross-sectional study. *Indian J Ophthalmol*. 2020;68(8):1546–1550. doi:10.4103/ijo.IJO_1319_20
36. Chen L, Deng C, Chen X, et al. Ocular manifestations and clinical characteristics of 535 cases of COVID-19 in Wuhan, China: a cross-sectional study. *Acta Ophthalmol*. 2020;98(8):e951–e959. doi:10.1111/aos.14472
37. Danesh-Meyer HV, McGhee CNJ. Implications of COVID-19 for Ophthalmologists. *Am J Ophthalmol*. 2021;223:108–118. doi:10.1016/j.ajo.2020.09.027
38. Torres-Costa S, Lima-Fontes M, Falcão-Reis F, Falcão M. SARS-COV-2 in Ophthalmology: current Evidence and Standards for Clinical Practice. *Acta Med Port*. 2020;33(9):593–600. doi:10.20344/amp.14118
39. Ichhpujani P, Singh RB, Dhillon HK, Kumar S. Ocular manifestations of COVID-19 in pediatric patients. *Ther Adv Ophthalmol*. 2023;15:25158414221149916. doi:10.1177/25158414221149916
40. Navel V, Chiambaretta F, Dutheil F. Haemorrhagic conjunctivitis with pseudomembranous related to SARS-CoV-2. *Am J Ophthalmol Case Rep*. 2020;19:100735. doi:10.1016/j.ajoc.2020.100735
41. Alnajjar M, Al-Mashdali A, Nefatti N. COVID-19 case presented initially with keratoconjunctivitis: a case report. *Ann Med Surg*. 2021;71:102957. doi:10.1016/j.amsu.2021.102957
42. Cheema M, Aghazadeh H, Nazarali S, et al. Keratoconjunctivitis as the initial medical presentation of the novel coronavirus disease 2019 (COVID-19). *Can J Ophthalmol*. 2020;55(4):e125–e129. doi:10.1016/j.cjjo.2020.03.003
43. Hutama SA, Alkaff FF, Intan RE, Maharani CD, Indriaswati L, Zuhria I. Recurrent keratoconjunctivitis as the sole manifestation of COVID-19 infection: a case report. *Eur J Ophthalmol*. 2022;32(4):NP17–NP21. doi:10.1177/11206721211006583
44. Guo D, Xia J, Wang Y, Zhang X, Shen Y, Tong JP. Relapsing viral keratoconjunctivitis in COVID-19: a case report. *Virol J*. 2020;17(1):97. doi:10.1186/s12985-020-01370-6
45. Méndez Mangana C, Barraquer Kargacin A, Barraquer RI. Episcleritis as an ocular manifestation in a patient with COVID-19. *Acta Ophthalmologica*. 2020;98(8). doi:10.1111/aos.14484
46. Otaif W, Al somali AI, Al Habash A. Episcleritis as a possible presenting sign of the novel coronavirus disease: a case report. *Am J Ophthalmol Case Rep*. 2020;20:100917. doi:10.1016/j.ajoc.2020.100917
47. Shah V, Patel H, Oza J, et al. Atypical Immunologic Manifestations of COVID-19: a Case Report and Narrative Review. *SN Compr Clin Med*. 2023;5(1):108. doi:10.1007/s42399-023-01448-6
48. Feizi S, Meshksar A, Naderi A, Esfandiari H. Anterior Scleritis Manifesting After Coronavirus Disease 2019: a Report of Two Cases. *Cornea*. 2021;40(9):1204–1206. doi:10.1097/ICO.0000000000002795
49. Adenwala A, Shetty R, D'Souza S, Mahendradas P, Kundu G. Nodular scleritis-a rare presentation of COVID-19& variation with testing. *Am J Ophthalmol Case Rep*. 2022;25:101396. doi:10.1016/j.ajoc.2022.101396
50. Matsubara D, Tamura D, Kasuya Y, et al. Case Report: anterior Scleritis Presenting as a Primary Ocular Manifestation in Multisystem Inflammatory Syndrome in Children With COVID-19. *Front Pediatr*. 2022;10:943652. doi:10.3389/fped.2022.943652
51. Islam M, Chou M, Braithwaite T, Siddiqui A. Bilateral anterior non-necrotising scleritis, anterior uveitis, and unilateral facial nerve palsy in paediatric inflammatory multisystem syndrome temporally associated with COVID-19. *Lancet Rheumatol*. 2021;3(11):e818. doi:10.1016/S2665-9913(21)00272-1
52. Sanjay S, Agrawal S, Jayadev C, et al. Posterior segment manifestations and imaging features of COVID-19. *Med Hypothesis Discov Innov Ophthalmol*. 2021;10(3):95–106. doi:10.51329/mehdiophthal1427
53. Gaba WH, Ahmed D, Al Nuaimi RK, Dhanhani AA, Eatamadi H. Bilateral Central Retinal Vein Occlusion in a 40-Year-Old Man with Severe Coronavirus Disease 2019 (COVID-19) Pneumonia. *Am J Case Rep*. 2020;21. doi:10.12659/AJCR.927691
54. Invernizzi A, Pellegrini M, Messenio D, et al. Impending Central Retinal Vein Occlusion in a Patient with Coronavirus Disease 2019 (COVID-19). *Ocul Immunol Inflammation*. 2020;28(8):1290–1292. doi:10.1080/09273948.2020.1807023

55. Nguyen NCI, Eandi C, Guex-Crosier Y. Central Retinal Vein Occlusion after COVID-19 Infection. *Klin Monbl Augenheilkd.* 2023;240(04):509–513. doi:10.1055/a-2040-3653
56. Ionescu M, Stoian AP, Rizzo M, et al. The Role of Endothelium in COVID-19. *IJMS.* 2021;22(21):11920. doi:10.3390/ijms222111920
57. Yeo S, Kim H, Lee J, Yi J, Chung YR. Retinal vascular occlusions in COVID-19 infection and vaccination: a literature review. *Graefes Arch Clin Exp Ophthalmol.* 2023;261(7):1793–1808. doi:10.1007/s00417-022-05953-7
58. Al-Abri M, Al-Musalami A, Al-Rawahi B, Al-Hinai A, Al-Fadhil N. Central retinal vein occlusion in a young healthy COVID-19 patient: a case report and literature review. *Middle East Afr J Ophthalmol.* 2021;28(3):199. doi:10.4103/meajo.meajo_271_21
59. Larrea J, Villota-Deleu E, Fernández-Vega B, Fernández-Vega A. Late retinal and optic nerve vascular complications due to COVID-19 in young individuals. *Am J Ophthalmol Case Rep.* 2022;25:101327. doi:10.1016/j.ajoc.2022.101327
60. Acharya S, Diamond M, Anwar S, Glaser A, Tyagi P. Unique case of central retinal artery occlusion secondary to COVID-19 disease. *IDCases.* 2020;21:e00867. doi:10.1016/j.idcr.2020.e00867
61. Zamani G, Ataei Azimi S, Aminizadeh A, et al. Acute macular neuroretinopathy in a patient with acute myeloid leukemia and deceased by COVID-19: a case report. *J Ophthalm Inflamm Infect.* 2020;10(1):39. doi:10.1186/s12348-020-00231-1
62. De Oliveira M, Lucena AV, Higino T, Ventura C. Central retinal artery occlusion with cilioretinal artery sparing secondary to COVID-19: additional ocular complication. *Indian J Ophthalmol.* 2023;71(2):663. doi:10.4103/ijo.IJO_1246_22
63. Virgo J, Mohamed M. Paracentral acute middle maculopathy and acute macular neuroretinopathy following SARS-CoV-2 infection. *Eye.* 2020;34(12):2352–2353. doi:10.1038/s41433-020-1069-8
64. Bapaye MM, Nair AG, Bapaye CM, Bapaye MM, Shukla JJ. Simultaneous Bilateral Central Retinal Artery Occlusion following COVID-19 Infection. *Ocul Immunol Inflamm.* 2021;29(4):671–674. doi:10.1080/09273948.2021.1891262
65. Gascon P, Briantais A, Bertrand E, et al. Covid-19-Associated Retinopathy: a Case Report. *Ocul Immunol Inflammation.* 2020;28(8):1293–1297. doi:10.1080/09273948.2020.1825751
66. Rotzinger DC, Beigelman-Aubry C, Von Garnier C, Qanadli SD. Pulmonary embolism in patients with COVID-19: time to change the paradigm of computed tomography. *Thrombosis Res.* 2020;190:58–59. doi:10.1016/j.thromres.2020.04.011
67. Shroff D, Kumar S, Naidu A, Gupta C, Shroff C. Retinal vasooclusive spectrum following COVID-19. *Indian J Ophthalmol.* 2022;70(4):1412. doi:10.4103/ijo.IJO_2837_21
68. Turedi N, Onal Gunay B. Paracentral acute middle maculopathy in the setting of central retinal artery occlusion following COVID-19 diagnosis. *Eur J Ophthalmol.* 2022;32(3):NP62–NP66. doi:10.1177/1120672121995347
69. Benito-Pascual B, Gegúndez JA, Díaz-Valle D, et al. Panuveitis and Optic Neuritis as a Possible Initial Presentation of the Novel Coronavirus Disease 2019 (COVID-19). *Ocul Immunol Inflamm.* 2020;28(6):922–925. doi:10.1080/09273948.2020.1792512
70. François J, Collery AS, Hayek G, et al. Coronavirus Disease 2019–Associated Ocular Neuropathy With Panuveitis: a Case Report. *JAMA Ophthalmol.* 2021;139(2):247. doi:10.1001/jamaophthalmol.2020.5695
71. Zhang Y, Stewart JM. Retinal and choroidal manifestations of COVID-19. *Curr Opinion Ophthalmol.* 2021;32(6):536–540. doi:10.1097/ICU.0000000000000801
72. Maggio MC, Collura F, D’Alessandro MM, Gramaglia B, Corsello G. Tubulointerstitial nephritis and uveitis syndrome post-COVID-19. *Pediatric Investigation.* 2023;7(1):57–59. doi:10.1002/ped4.12362
73. Marinho PM, Marcos AAA, Romano AC, Nascimento H, Belfort R. Retinal findings in patients with COVID-19. *Lancet.* 2020;395(10237):1610. doi:10.1016/S0140-6736(20)31014-X
74. Pereira LA, Soares LCM, Nascimento PA, et al. Retinal findings in hospitalised patients with severe COVID-19. *Br J Ophthalmol.* 2022;106(1):102–105. doi:10.1136/bjophthalmol-2020-317576
75. Manoharan A, Agarwal A, Dutta Majumder P. Acute Retinal Necrosis: a Covid-19 Perspective. *Ocul Immunol Inflammation.* 2023;31(6):1270–1272. doi:10.1080/09273948.2022.2159842
76. Rojas-Correa DX, Reche-Sainz JA, Insausti-García A, Calleja-García C, Ferro-Osuna M. Post COVID-19 Myelin Oligodendrocyte Glycoprotein Antibody-Associated Optic Neuritis. *Neuro-Ophthalmology.* 2022;46(2):115–121. doi:10.1080/01658107.2021.1916044
77. Shaw VC, Chander G, Puttanna A. Neuromyelitis optica spectrum disorder secondary to COVID-19. *Br J Hosp Med.* 2020;81(9):1–3. doi:10.12968/hmed.2020.0401
78. Mao L, Jin H, Wang M, et al. Neurologic Manifestations of Hospitalized Patients With Coronavirus Disease 2019 in Wuhan, China. *JAMA Neurol.* 2020;77(6):683. doi:10.1001/jamaneurol.2020.1127
79. Chakraborty U, Chaudhuri J, Datta AK, et al. COVID-19 and optic neuritis: a series of three cases and a critical review. *Egypt J Neurol Psychiatry Neurosurg.* 2023;59(1):172. doi:10.1186/s41983-023-00772-x
80. Cyr DG, Vicidomini CM, Siu NY, Elmann SE. Severe Bilateral Vision Loss in 2 Patients With Coronavirus Disease 2019. *J Neuroophthalmol.* 2020;40(3):403–405. doi:10.1097/WNO.0000000000001039
81. Bondira IP, Lambert-Cheatham NA, Sakuru RC, et al. Inability to Read After Prolonged COVID-19 Hospitalization: MRI With Clinical Correlation. *J Neuroophthalmol.* 2021;41(3):e277–e278. doi:10.1097/WNO.0000000000001121
82. Priftis K, Prior M, Meneghetti L, Mercogliano T, Bendini M. Alexia without agraphia in a post COVID-19 patient with left-hemisphere ischemic stroke. *Neurol Sci.* 2021;42(6):2179–2181. doi:10.1007/s10072-021-05211-4
83. Greer CE, Bhatt JM, Oliveira CA, Dinkin MJ. Isolated Cranial Nerve 6 Palsy in 6 Patients With COVID-19 Infection. *J Neuroophthalmol.* 2020;40(4):520–522. doi:10.1097/WNO.0000000000001146
84. Lima MA, Silva MTT, Soares CN, et al. Peripheral facial nerve palsy associated with COVID-19. *J Neuroviro.* 2020;26(6):941–944. doi:10.1007/s13365-020-00912-6
85. Naor MS, Mathew PG, Sharon R. Transient Horner syndrome associated with COVID-19: a case report. *eNeurologicalSci.* 2021;25:100349. doi:10.1016/j.ensci.2021.100349
86. Sansone P, Giaccari LG, Aurilio C, et al. Post-Infectious Guillain-Barré Syndrome Related to SARS-CoV-2 Infection: a Systematic Review. *Life.* 2021;11(2):167. doi:10.3390/life11020167
87. Dinkin M, Gao V, Kahan J, et al. COVID-19 presenting with ophthalmoparesis from cranial nerve palsy. *Neurology.* 2020;95(5):221–223. doi:10.1212/WNL.0000000000009700

88. Gutiérrez-Ortiz C, Méndez-Guerrero A, Rodrigo-Rey S, et al. Miller Fisher syndrome and polyneuritis cranialis in COVID-19. *Neurology*. 2020;95(5):e601–e605. doi:10.1212/WNL.00000000000009619
89. Restivo DA, Centonze D, Alesina A, Marchese-Ragona R. Myasthenia Gravis Associated With SARS-CoV-2 Infection. *Ann Intern Med*. 2020;173(12):1027–1028. doi:10.7326/L20-0845
90. Mas Maresma L, Barrachina Esteve O, Navarro Vilasaró M, Moreno-Ariño M. Myasthenia gravis associated with SARS-CoV-2 infection: a conjunction of several factors. *Rev Esp Geriatr Gerontol*. 2020;55(6):360–361. doi:10.1016/j.regg.2020.08.004
91. Rodríguez-Rodríguez MS, Romero-Castro RM, Alvarado-de la Barrera C, González-Cannata MG, García-Morales AK, Ávila-Ríos S. Optic neuritis following SARS-CoV-2 infection. *J Neurovirol*. 2021;27(2):359–363. doi:10.1007/s13365-021-00959-z
92. Caudill GB, Wolin MJ. Myelin Oligodendrocyte Glycoprotein and Neuromyelitis Optica/Aquaporin-4 Antibody Negative COVID-19–Associated Optic Neuritis. *J Neuroophthalmol*. 2023;43(1):e1–e2. doi:10.1097/WNO.0000000000001364
93. de Ruijter NS, Kramer G, Gons RAR, Hengstman GJD. Neuromyelitis optica spectrum disorder after presumed coronavirus (COVID-19) infection: a case report. *Mult Scler Relat Disord*. 2020;46:102474. doi:10.1016/j.msard.2020.102474
94. Sawalha K, Adeodokun S, Kamoga GR. COVID-19-Induced Acute Bilateral Optic Neuritis. *J Investig Med High Impact Case Rep*. 2020;8:2324709620976018. doi:10.1177/2324709620976018
95. Kogure C, Kikushima W, Fukuda Y, et al. Myelin oligodendrocyte glycoprotein antibody-associated optic neuritis in a COVID-19 patient: a case report. *Medicine*. 2021;100(19):e25865. doi:10.1097/MD.00000000000025865
96. Colantonio MA, Nwafor DC, Jaiswal S, et al. Myelin oligodendrocyte glycoprotein antibody-associated optic neuritis and myelitis in COVID-19: a case report and a review of the literature. *Egypt J Neurol Psychiatr Neurosurg*. 2022;58(1):62. doi:10.1186/s41983-022-00496-4
97. Fernández Alcalde C, Granados Fernández M, Nieves Moreno M, Calvo Rey C, Falces Romero I, Noval Martín S. COVID-19 ocular findings in children: a case series. *World J Pediatr*. 2021;17(3):329–334. doi:10.1007/s12519-021-00418-z
98. Sinha A, Dwivedi D, Dwivedi A, Bajaj N. Optic Neuritis As a Presenting Symptom of Post-COVID-19 Multisystem Inflammatory Syndrome in Children (MIS-C). *Indian J Pediatr*. 2021;88(12):1269. doi:10.1007/s12098-021-03921-3
99. Tavakoli M, Sotoudeh H, Rezaei A, Saadatpour Z, Vaphides MS, Kline LB. Optic Nerve Infarction in a Patient With Coronavirus Disease 2019. *J Neuroophthalmol*. 2022;42(1):e347. doi:10.1097/WNO.0000000000001232
100. Sainath D, Paul A, Krishnagopal S, Kumar A. Acute bilateral retrobulbar optic neuritis - An atypical sequela of COVID-19. *Indian J Ophthalmol*. 2021;69(12):3761–3764. doi:10.4103/ijo.IJO_2155_21
101. Gopal M, Ambika S, Padmalakshmi K. Tonic Pupil Following COVID-19. *J Neuroophthalmol*. 2021;41(4):e764–e766. doi:10.1097/WNO.0000000000001221
102. Quijano-Nieto BA, Córdoba-Ortega CM. Tonic pupil after COVID-19 infection. *Arch Soc Esp Oftalmol*. 2021;96(7):353–355. doi:10.1016/j.oftale.2021.01.001
103. Ortiz-Seller A, Martínez Costa L, Hernández-Pons A, Valls Pascual E, Solves Alemany A, Albert-Fort M. Ophthalmic and Neuro-ophthalmic Manifestations of Coronavirus Disease 2019 (COVID-19). *Ocul Immunol Inflamm*. 2020;28(8):1285–1289. doi:10.1080/09273948.2020.1817497
104. Ordás CM, Villaceros-álvarez J, Pastor-Vivas AI, Corrales-Benítez Á. Concurrent tonic pupil and trochlear nerve palsy in COVID-19. *J Neurovirol*. 2020;26(6):970–972. doi:10.1007/s13365-020-00909-1
105. Portela-Sánchez S, Sánchez-Soblechero A, Melgarejo Otalora PJ, et al. Neurological complications of COVID-19 in hospitalized patients: the registry of a neurology department in the first wave of the pandemic. *Eur J Neurol*. 2021;28(10):3339–3347. doi:10.1111/ene.14748
106. Kaya Y, Kara S, Akinci C, Kocaman AS. Transient cortical blindness in COVID-19 pneumonia; a PRES-like syndrome: case report. *J Neurol Sci*. 2020;413:116858. doi:10.1016/j.jns.2020.116858
107. Ghosh R, Lahiri D, Dubey S, Ray BK, Benito-León J. Hallucinatory Palinopsia in COVID-19-Induced Posterior Reversible Encephalopathy Syndrome. *J Neuroophthalmol*. 2020;40(4):523–526. doi:10.1097/WNO.0000000000001135
108. Dakay K, Cooper J, Bloomfield J, et al. Cerebral Venous Sinus Thrombosis in COVID-19 Infection: a Case Series and Review of The Literature. *J Stroke Cerebrovasc Dis*. 2021;30(1):105434. doi:10.1016/j.jstrokecerebrovasdis.2020.105434
109. Klein DE, Libman R, Kirsch C, Arora R. Cerebral venous thrombosis: a typical presentation of COVID-19 in the young. *J Stroke Cerebrovasc Dis*. 2020;29(8):104989. doi:10.1016/j.jstrokecerebrovasdis.2020.104989
110. Katti V, Ramamurthy LB, Kanakpur S, Shet SD, Dhoot M. Neuro-ophthalmic presentation of COVID-19 disease: a case report. *Indian J Ophthalmol*. 2021;69(4):992–994. doi:10.4103/ijo.IJO_3321_20
111. Solorio-Pineda S, Almindárez-Sánchez CA, Tafur-Grandett AA, et al. Pituitary macroadenoma apoplexy in a severe acute respiratory syndrome-coronavirus-2-positive testing: causal or casual? *Surg Neurol Int*. 2020;11:304. doi:10.25259/SNI_305_2020
112. Douedi S, Naser H, Mazahir U, Hamad AI, Sedarous M. Third Cranial Nerve Palsy Due to COVID-19 Infection. *Cureus*. 2021;13(4):e14280. doi:10.7759/cureus.14280
113. Bingöl Kızıltunç P, Seven MY, Atilla H. Isolated abducens nerve palsy due to COVID-19. *Strabismus*. 2022;30(1):35–37. doi:10.1080/09273972.2021.2022718
114. Namavarian A, Eid A, Ziai H, Cheng EY, Enepekides D. Facial Nerve Paralysis and COVID-19: a Systematic Review. *Laryngoscope*. 2023;133(5):1007–1013. doi:10.1002/lary.30333
115. Fitzpatrick JC, Comstock JM, Longmuir RA, Donahue SP, Fitzpatrick JM, Bond JB. Cranial Nerve III Palsy in the Setting of COVID-19 Infection. *J Neuroophthalmol*. 2021;41(3):e286–e287. doi:10.1097/WNO.0000000000001160
116. Oliveira R, Takahashi JT. Bilateral trochlear nerve palsy due to cerebral vasculitis related to COVID-19 infection. *Arq Neuropsiquiatr*. 2020;78(6):385–386. doi:10.1590/0004-282X20200052
117. Perret M, Bernard A, Rahmani A, Manckoundia P, Putot A. Acute Labyrinthitis Revealing COVID-19. *Diagnostics (Basel)*. 2021;11(3):482. doi:10.3390/diagnostics11030482
118. Picciotti PM, Passali GC, Sergi B, De Corso E. Benign Paroxysmal Positional Vertigo (BPPV) in COVID-19. *Audiol Res*. 2021;11(3):418–422. doi:10.3390/audiolres11030039
119. Wong PF, Craik S, Newman P, et al. Lessons of the month 1: a case of rhombencephalitis as a rare complication of acute COVID-19 infection. *Clin Med Lond*. 2020;20(3):293–294. doi:10.7861/clinmed.2020-0182
120. Llorente Ayuso L, Torres Rubio P, Beijinho Do Rosário RF, Giganto Arroyo ML, Sierra-Hidalgo F. Bickerstaff encephalitis after COVID-19. *J Neurol*. 2021;268(6):2035–2037. doi:10.1007/s00415-020-10201-1

121. Garcia-Romo E, Blanco R, Nicholls C, Hernández-Tejero A, Fernández-de-Arévalo B. COVID-19 presenting with nystagmus. *Arch Soc Esp Oftalmol*. 2021;96(4):224–226. doi:10.1016/j.oftal.2020.09.008
122. Emamikhah M, Babadi M, Mehrabani M, et al. Opsoclonus-myoclonus syndrome, a post-infectious neurologic complication of COVID-19: case series and review of literature. *J Neurovirol*. 2021;27(1):26–34. doi:10.1007/s13365-020-00941-1
123. Nelson JL, Blume GM, Bansal SK, et al. Postinfectious SARS-CoV-2 Opsoclonus-Myoclonus-Ataxia Syndrome. *J Neuroophthalmol*. 2022;42(2):251–255. doi:10.1097/WNO.0000000000001498
124. Shah PB, Desai SD. Opsoclonus Myoclonus Ataxia Syndrome in the Setting of COVID-19 Infection. *Neurology*. 2021;96(1):33. doi:10.1212/WNL.00000000000010978
125. Sarkar S, Gokhale T, Choudhury SS, Deb AK. COVID-19 and orbital mucormycosis. *Indian J Ophthalmol*. 2021;69(4):1002–1004. doi:10.4103/ijo.IJO_3763_20
126. Sen M, Lahane S, Lahane TP, Parekh R, Honavar SG. Mucor in a Viral Land: a Tale of Two Pathogens. *Indian J Ophthalmol*. 2021;69(2):244–252. doi:10.4103/ijo.IJO_3774_20
127. Artis WM, Fountain JA, Delcher HK, Jones HE. A mechanism of susceptibility to mucormycosis in diabetic ketoacidosis: transferrin and iron availability. *Diabetes*. 1982;31(12):1109–1114. doi:10.2337/diacare.31.12.1109
128. Galletti B, Freni F, Meduri A, et al. Rhino-Orbito-Cerebral Mucormycosis in Diabetic Disease Mucormycosis in Diabetic Disease. *J Craniofac Surg*. 2020;31(4):e321–e324. doi:10.1097/SCS.00000000000006191
129. Pushparaj K, Kuchi Bhotla H, Arumugam VA, et al. Mucormycosis (black fungus) ensuing COVID-19 and comorbidity meets - Magnifying global pandemic grievance and catastrophe begins. *Sci Total Environ*. 2022;805:150355. doi:10.1016/j.scitotenv.2021.150355
130. Shires CB, Klug T, Dryden S, Ford J. Unusual cause of acute sinusitis and orbital abscess in COVID-19 positive patient: case report. *Int J Surg Case Rep*. 2021;79:164–168. doi:10.1016/j.ijscr.2021.01.043
131. Armstrong BK, Murchison AP, Bilyk JR. Suspected orbital myositis associated with COVID-19. *Orbit*. 2021;40(6):532–535. doi:10.1080/01676830.2021.1962366
132. Martínez Díaz M, Copete Piqueras S, Blanco Marchite C, Vahdani K. Acute dacryoadenitis in a patient with SARS-CoV-2 infection. *Orbit*. 2022;41(3):374–377. doi:10.1080/01676830.2020.1867193
133. Rodrigues G, Hiran H, Suprasanna K, Mendonca T, Suresh J. Ptosis and dacryoadenitis following COVID. *Clin Exp Optom*. 2023;1–3. doi:10.1080/08164622.2023.2197580
134. Kumari S, Anand R, Sambyal B, Singh Y, Rangappa P, Jha SK. Ocular adverse effects of COVID-19 vaccines: a systematic review. *J Family Med Prim Care*. 2022;11(9):5041–5054. doi:10.4103/jfmpe.jfmpe_747_22
135. Ng XL, Betzler BK, Testi I, et al. Ocular Adverse Events After COVID-19 Vaccination. *Ocul Immunol Inflamm*. 2021;29(6):1216–1224. doi:10.1080/09273948.2021.1976221
136. Sen M, Honavar SG. After the Storm: ophthalmic Manifestations of COVID-19 Vaccines. *Indian J Ophthalmol*. 2021;69(12):3398–3420. doi:10.4103/ijo.IJO_2824_21
137. Ng XL, Betzler BK, Ng S, et al. The Eye of the Storm: COVID-19 Vaccination and the Eye. *Ophthalmol Ther*. 2022;11(1):81–100. doi:10.1007/s40123-021-00415-5
138. Lee YK, Huang YH. Ocular Manifestations after Receiving COVID-19 Vaccine: a Systematic Review. *Vaccines*. 2021;9(12):1404. doi:10.3390/vaccines9121404
139. Binotti W, Hamrah P. COVID-19-related Conjunctivitis Review: clinical Features and Management. *Ocul Immunol Inflammation*. 2023;31(4):778–784. doi:10.1080/09273948.2022.2054432
140. Smith JR, Lai TYY. Managing Uveitis during the COVID-19 Pandemic. *Ophthalmology*. 2020;127(9):e65–e67. doi:10.1016/j.ophtha.2020.05.037
141. Feng H, Zhao M, Mo J, Cao X, Chen W, Wang H. New onset or recurrence of uveitis following COVID-19 infection. *BMC Ophthalmol*. 2024;24(1):23. doi:10.1186/s12886-024-03289-w
142. Abbati G, Fazi C, Fortunato P, Trapani S. Central retinal artery occlusion in a young child affected by COVID-19: a first case report. *BMC Pediatr*. 2023;23(1):462. doi:10.1186/s12887-023-04276-8
143. Pimentel V, Luchsinger VW, Carvalho GL, et al. Guillain-Barré syndrome associated with COVID-19: a systematic review. *Brain Behav Immunity*. 2023;28:100578. doi:10.1016/j.bbih.2022.100578
144. Abdul-Salam State SE, Sfredel V, Mocanu CL, Albu CV, Bălăşoiu AT. Optic neuropathies post-Covid 19 - review. *Rom J Ophthalmol*. 2022;66(4):289–298. doi:10.22336/rjo.2022.54

Clinical Ophthalmology

Dovepress

Publish your work in this journal

Clinical Ophthalmology is an international, peer-reviewed journal covering all subspecialties within ophthalmology. Key topics include: Optometry; Visual science; Pharmacology and drug therapy in eye diseases; Basic Sciences; Primary and Secondary eye care; Patient Safety and Quality of Care Improvements. This journal is indexed on PubMed Central and CAS, and is the official journal of The Society of Clinical Ophthalmology (SCO). The manuscript management system is completely online and includes a very quick and fair peer-review system, which is all easy to use. Visit <http://www.dovepress.com/testimonials.php> to read real quotes from published authors.

Submit your manuscript here: <https://www.dovepress.com/clinical-ophthalmology-journal>