



Since January 2020 Elsevier has created a COVID-19 resource centre with free information in English and Mandarin on the novel coronavirus COVID-19. The COVID-19 resource centre is hosted on Elsevier Connect, the company's public news and information website.

Elsevier hereby grants permission to make all its COVID-19-related research that is available on the COVID-19 resource centre - including this research content - immediately available in PubMed Central and other publicly funded repositories, such as the WHO COVID database with rights for unrestricted research re-use and analyses in any form or by any means with acknowledgement of the original source. These permissions are granted for free by Elsevier for as long as the COVID-19 resource centre remains active.

# Journal Pre-proof

The impact of COVID-19 infection on miscellaneous inflammatory disorders of the gastrointestinal tract.

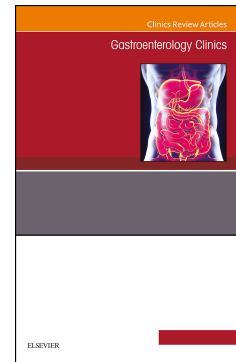
Mitchell S. Cappell, MD, PhD, Martin Tobi, MB, ChB, David M. Friedel, MD

PII: S0889-8553(22)00069-3

DOI: <https://doi.org/10.1016/j.gtc.2022.10.002>

Reference: GTC 1241

To appear in: *GASTROENTEROLOGY CLINICS OF NORTH AMERICA*



Please cite this article as: Cappell MS, Tobi M, Friedel DM, The impact of COVID-19 infection on miscellaneous inflammatory disorders of the gastrointestinal tract., *GASTROENTEROLOGY CLINICS OF NORTH AMERICA* (2022), doi: <https://doi.org/10.1016/j.gtc.2022.10.002>.

This is a PDF file of an article that has undergone enhancements after acceptance, such as the addition of a cover page and metadata, and formatting for readability, but it is not yet the definitive version of record. This version will undergo additional copyediting, typesetting and review before it is published in its final form, but we are providing this version to give early visibility of the article. Please note that, during the production process, errors may be discovered which could affect the content, and all legal disclaimers that apply to the journal pertain.

© 2022 Published by Elsevier Inc.

**The impact of COVID-19 infection on miscellaneous inflammatory disorders of the gastrointestinal tract.**

Mitchell S. Cappell, MD, PhD, Martin Tobi, MB, ChB, and David M. Friedel, MD

Mitchell S. Cappel, MD, PhD, Division of Gastroenterology, Department of Medicine, Aleda E. Lutz Veterans Hospital, Main Building, Room 3212, 1500 Weiss St, Saginaw, MI 48602. Email: [Mitchell.cappell@va.gov](mailto:Mitchell.cappell@va.gov).

Martin Tobi:, MB, ChB, Department of Research and Development, John D. Dingell Veterans Affairs Medical Center, 4747 John R. Street, MI Detroit, MI 48201. Email: [adnabnine@va.gov](mailto:adnabnine@va.gov).

David M. Friedel, MD, Division of Therapeutic Endoscopy, Division of Gastroenterology, Department of Medicine, 259 1st St, Mineola, 11501, NY of New York University Langone Hospital. Email: [david.friedel@nyulangone.org](mailto:david.friedel@nyulangone.org)

Short title: COVID-19 infection and miscellaneous gastrointestinal inflammatory disorders

Key words: COVID-19, pandemic; SARS; gastrointestinal; inflammation

*Address correspondence to:*

Mitchell S. Cappell: MD, PhD

Gastroenterology Service,

Department of Medicine,

Aleda E. Lutz Veterans Hospital

Building 1, Room 3212,

1500 Weiss St, Saginaw, MI 48602.

Email: [mitchell.cappell@va.gov](mailto:mitchell.cappell@va.gov).

## Abstract

The novel coronavirus, COVID-19, pandemic has emerged as a highly significant recent threat to global health with about 600,000,000 known infections and more than 6,450,000 deaths worldwide since its emergence in late 2019. COVID-19 symptoms are predominantly respiratory with mortality largely related to pulmonary manifestations, but the virus also potentially infects all parts of the gastrointestinal tract with related symptoms and manifestations that impact treatment and outcome. COVID-19 can directly infect the gastrointestinal tract because of the presence of widespread angiotensin converting enzyme-2 (ACE-2) receptors in the stomach and small intestine which can cause local COVID-19 infection and associated inflammation. COVID-19 can affect the gastrointestinal (GI) tract by direct infection from GI ulcerations related to stress, particularly in mechanically-ventilated patients or patients administered corticosteroids, and incidentally by deferred screening for gastrointestinal neoplasms or malignancies such as Barrett's esophagus or colorectal neoplasms due to patient preference or inability of health systems to accommodate endoscopic screenings due to COVID-19 exigencies. Moreover, COVID-19 infection may also affect those with underlying chronic gastrointestinal diseases, and treatment for COVID-19 and its complications may in turn impact these chronic conditions. We review the gastrointestinal manifestations of COVID-19 as well as its impact on patients with underlying gastrointestinal conditions, except for inflammatory bowel disease (IBD), specific gastrointestinal symptoms, gastrointestinal bleeding, and gastrointestinal endoscopy which are reviewed in separate chapters in this monograph. This review takes an anatomic, organ-based approach beginning with the pharynx and ending with the anus.

## INTRODUCTION

The novel coronavirus pandemic with COVID-19 has caused immense morbidity and mortality, with more than one million deaths in the United States and more than six million deaths globally (1). Mortality occurs in all groups but are disproportionately higher in the elderly, infirm, male gender, lower socioeconomic classes, and patients having significant comorbidities including those suffering from diabetes mellitus, and obesity (2). Moreover, the pandemic causes considerable morbidity and can persist in a chronic form as reviewed in another chapter in this monograph. Development of relatively effective vaccines, sporadically mandated public health measures such as masks, increasing percentage of the population already infected with the virus, moderately effective therapy, and perhaps less virulent emerging viral strains have significantly diminished COVID-19 infection severity and mortality, but the pandemic endures, with associated morbidity and mortality, especially in the unvaccinated and vulnerable populations. Long (chronic) COVID-19 can relatively frequently cause GI infections or symptoms in some patients who had contracted symptomatic acute COVID-19 infection and is reviewed in another chapter in this monograph.

Organs, including the GI tract, that express angiotensin converting enzyme-2 (ACE-2) are susceptible to local COVID-19 infection and associated inflammation. COVID-19 can affect the gastrointestinal (GI) tract by direct infection and local inflammation, or indirectly from GI ulcerations related to stress, particularly in mechanically-ventilated patients or patients administered corticosteroids, and incidentally by deferred screening for gastrointestinal neoplasms or malignancies such as Barrett's esophagus or colorectal neoplasms due to patient preference or inability of health systems to accommodate endoscopic screenings due to COVID exigencies.

## METHODS

The medical and scientific community is generally aware of the nature and importance of systematic reviews. The essence of systematic reviews is that the method and particulars of the literature search are tabulated so that the reader could potentially reconstruct all the data (articles) used in the literature review if needed, including (1) all the articles surveyed by the literature search using the computerized search terms of the literature review, and (2) all the articles excluded in the literature search with the listed reasons for every excluded article. The first task is an integral and essential part of a systematic review that requires little documentation, whereas the second task requires extensive documentation by compiling all individual articles excluded from the review article while specifying the reason(s) for exclusion for each exclusion. It is reasonable to separate these two distinct tasks and denote the accomplishment of the first task without the second task by creating a new term of “semiquantitative review”. By this term a review encompassing the first part of a systematic review but not the second part of a systematic review is denoted. This new term is useful because the first task of a systematic review provides one-half or more of the quality of a systematic review, while requiring much less documentation that is entailed in the second task.

This article inaugurates a “semiquantitative review” by declaring all the search terms used in the literature search (with the number of articles reviewed) without detailing the extensive list of excluded articles. This literature review was performed using PubMed and Ovid, independent literature search engines. The literature review was last conducted (and is up to date) as of August 26, 2022, when this article was submitted for publication, and included the following search terms or phrases (with number of identified articles per search term, as derived from PubMed listed in parenthesis): pharynx and COVID-19 (1,514); oropharynx and COVID-19 (284); oropharyngeal involvement and COVID-19 (81); anosmia and COVID-19 (1662); dysgeusia and COVID-19 (406); olfactory dysfunction and COVID-19 (886); geographic tongue and COVID-19 (12); COVID tongue (217); gastroesophageal reflux (GERD) and COVID-19 (36);

Barrett's epithelium and COVID-19 (13); proton pump inhibitor and COVID-19 (114); intestinal metaplasia and COVID-19 (6); laryngopharyngeal reflux and COVID-19 (3); esophagus, candida, and COVID-19 (1); esophagogastroduodenoscopy (EGD) and COVID-19 (13); nasal endoscopy (EGD) and COVID-19 (134); Barrett's ablation and COVID-19 (1); Barrett's esophagus screening and COVID-19 (7); cytosponge and COVID-19 (2); high resolution manometry and COVID-19 (7); esophageal varices and COVID-19 (14); achalasia and COVID-19 (6); esophageal necrosis and COVID-19 (5); Boerhave's syndrome and COVID-19 (2); scleroderma and COVID-19 (94); pill esophagitis and COVID-19 (1); corrosive esophagitis and COVID-19 (1); eosinophilic esophagitis and COVID-19 (10); gastropathy and COVID-19 (115); gastroduodenitis and COVID-19; ulcers and COVID-19; H. pylori and COVID-19 (51); H. pylori antigen and COVID-19 (12); gastrointestinal hemorrhage and COVID-19 (134); gastrointestinal bleeding and COVID-19 (262); melena and COVID-19 (35); hematemesis and COVID-19 (23); iron deficiency anemia and COVID-19 (39); fecal occult blood and COVID-19 (82); primary COVID ulcers (69); gastric ulcers and COVID-19 (20); duodenal ulcers and COVID-19 (15); celiac and COVID-19 (133); multisystem inflammatory syndrome and COVID-19 (2,132); Crohn's disease and COVID-19 (328); ulcerative colitis and COVID-19 (310); mesenteric ischemia and COVID-19 (94); pneumatosis intestinalis and COVID-19 (19); pneumatosis coli and COVID-19 (12); gastrointestinal perforation and COVID-19 (75); gastrointestinal obstruction and COVID-19 (110); intussusception and COVID-19 (56); mucormycosis and COVID-19 (747); microscopic colitis and COVID-19 (5); lymphocytic colitis and COVID-19 (3); collagenous colitis and COVID-19 (3); protein-losing enteropathy and COVID-19 (2); cytokine release syndrome and COVID-19 (2,045); tocilizumab, perforation, and COVID-19 (19); Clostridium difficile and COVID-19 (131); Clostridiodes and COVID-19 (5); appendicitis and COVID-19 (403); diverticulitis and COVID-19 (41); colonic pseudo-obstruction and COVID-19 (5); irritable bowel syndrome (IBS) and COVID-19 (56); colon cancer and COVID-19 (215); colonic polyps and COVID-19 (11); colonoscopy and COVID-19 (218); enteroscopy and COVID-19 (2); capsule endoscopy and COVID-19 (29); balloon endoscopy and COVID-19 (5); CT colonography (CTC) and COVID-19 (10); hemorrhoids and COVID-

19 (105); anal fistula and COVID-19 (5); anal abscess and COVID-19 (2); anal fissure and COVID-19 (3); and Long (chronic) COVID-19 and gastrointestinal (77). This work illustrates the utility of a semiquantitative literature review that reviews so many articles, because a systematic review of this literature would encompass so many excluded articles thereby encumbering such an article with an impractically long list.

## PHARYNX

COVID-19 has been detected in oral and nasopharyngeal tissues and secretions, with implications for pathogenesis, transmissibility, and contamination. For example, chewing gum saturated with soluble ACE2 (angiotensin-converting enzyme 2) proteins but lacking the virus may reduce viral transmission by 95% (3). Oropharyngeal involvement most commonly pathologically produces erosions or ulcers (4,5). Loss of smell (anosmia) and loss of taste (ageusia) or a taste disorder (dysgeusia) are commonly encountered with COVID-19 infection. For example, in a study of 322 COVID-19 patients treated at a hospital in India from August through November 2020, 226 COVID-19 patients (70.2%) experienced olfactory and gustatory disorders, including 165 (51.2%) patients with both olfactory and gustatory disorders, 34 (10.6%) patients with solely olfactory dysfunction, and 27 (8.4%) patients with solely gustatory dysfunction (6). These symptoms usually present without gross oropharyngeal pathology of nasopharyngitis, nasal obstruction or glossitis, without the symptom of rhinorrhea, and without zinc deficiency. The true mechanism(s) remain(s) conjectural and unknown. It has been hypothesized that a decrease in the sensitivity of olfactory neurons and co-expression of ACE2 and TMPRSS2 in alveolar epithelial cells may cause these olfactory-gustatory disorders (7). These symptoms often are the first to appear with COVID-19 infection and the last to resolve (8,9). Corticosteroids have been proposed as a therapy, but their efficacy is unproven (10). Alternative therapies include nirmatrelvir/ritonavir (Paxlovid) and anti-cytokine monoclonals (11). However, efficacy in clinical trials may not apply to the general population (10).



Geographic tongue manifests as irregular loss of filiform papillae towards the rear of the tongue. This disorder affects about 1-2% of patients in the general population and is strongly related to psoriasis and is believed due to genetic and immunological factors. In a Spanish study of 666 patients with COVID-19 infection, 3.9% had irregular depapillation of the distal lingual dorsum consistent with geographic tongue, also known as COVID tongue (12). Geographic tongue has been linked with high expression of ACE-2 in epithelial cells at the back of the tongue, possibly leading to injury of infected papillae (13). Candidiasis of the tongue (14) is reviewed under esophageal candidiasis. Oral manifestations and salivary duct abnormalities from acute COVID infection may persist for months (15).

## ESOPHAGUS

A database incorporating more than 26,000 COVID-19-infected patients reported 19% had symptoms of GERD (gastroesophageal reflux disease) (16). It is unknown whether COVID-19 increases the frequency of GERD symptoms because this study was performed without a control group for comparison. Moreover, GERD symptoms and those directly attributed to COVID-19 infection, such as cough and chest discomfort may overlap, especially when mild, creating a diagnostic dilemma (17). However, recent advancements in the rapidity and accuracy of COVID-19 testing generally permits differentiation of these two entities (17). Conversely, patients presenting with predominantly or solely GI symptoms may still have COVID-19 infection in an endemic area (18). Lastly, these two entities commonly coexist in obese subjects who are at high risk of GERD as well as at high risk of severely symptomatic COVID-19 infection. A genetic relationship between GERD and COVID-19 has been proposed, but obesity seems to be the most significant underlying cofactor (19). Laryngopharyngeal reflux may be disproportionately increased with COVID-19 infection, and melatonin has been proposed as therapy for this condition (20,21).

The relationship between medications to treat GERD and COVID-19 has been well analyzed. COVID-19 may preferentially infect Barrett's metaplastic epithelium (akin to small bowel epithelium) over

normal esophageal columnar mucosa, thereby increasing susceptibility (22). Proton pump inhibitor (PPI) therapy is associated with increased COVID-19 susceptibility (23), and worse COVID-19 outcomes (24, 25,26). Other investigators have refuted this association and advocated that other risk factors are more important in patient outcome (27,28). Famotidine was previously touted as the preferred histamine-2 (H<sub>2</sub>) receptor antagonists for hospitalized patients with COVID-19 (29) possibly due to decreasing the risk of cytokine storm, but clinical trials unfortunately showed no therapeutic benefits for famotidine compared to other H<sub>2</sub> receptor antagonist therapies (30,31).

Patients with severe COVID-19 infection are at high risk of developing invasive esophageal candidiasis, especially patients with acute respiratory distress syndrome (ARDS), chronically receiving corticosteroid therapy, or undergoing prolonged endotracheal intubation (32). Other proposed clinical risk factors for esophageal candidiasis include prolonged intensive care unit (ICU) stays, central venous catheters, prolonged broad-spectrum antibiotic therapy, and prior bouts of esophageal candidiasis (32). Patients with such risk factors are highly susceptible to candidial infection because *Candida* species are frequent constituents of the human mycobiome. Deep-seated candidial infections are associated with increased mortality. Esophageal candidiasis is associated with the profound immune dysregulation in COVID-19 infection, but the specific underlying immunologic defects are unknown. Esophageal candidiasis typically presents with dysphagia or odynophagia. At esophagogastroduodenoscopy (EGD) esophageal candidiasis classically presents as a cheesy white superficial exudate. EGD with endoscopic brushings are usually diagnostic. Clinical awareness and screening are needed in the setting of severe COVID-19 infection. Echinocandins and azoles are the primary antifungals used to treat esophageal candidiasis. In patients with advanced COVID-19 infection, *Candida* spp. may exhibit resistance to traditional antifungal agents.

The COVID-19 pandemic has greatly disrupted esophageal testing, especially EGD. Diversion of physician resources and endoscopy suite time to the COVID-19 pandemic crisis has decreased the use of

screening and other routine endoscopic procedures, but it has spurred use of alternative testing modalities and innovations, especially regarding equipment. For example, one center substituted chest computed tomography (CT) for endoscopy to screen for esophageal varices (33). A large United States database reported that esophageal cancer diagnosis, as well as Barrett's esophagus screening and ablation, decreased during the peak of the pandemic, but the rate of performing esophagectomies did not change (34). Unsedated nasal endoscopy using topical anesthetic agents such as benzocaine (35), modified masks for esophageal function testing, and use of the cytosponge device are notable innovations (36,37,38). Fortunately, transmission of COVID-19 in the endoscopy suite to endoscopists, endoscopy staff, and noninfected patients has been exceedingly rare (39). Practical triage permits optimal utilization of endoscopic resources. As with EGDs, the number of high-resolution manometries (HRM) decreased by 17.2% from 1587 in 1999 to 1314 in 2020 attributed to the COVID pandemic that peaked in April and May 2020 (40). Notably, the rate of performing HRM hardly decreased in 2020 in areas of Japan relatively affected by the COVID-19 pandemic. One case of endoscopic variceal ligation was successfully performed with cessation of esophageal variceal hemorrhage in an intubated patient with COVID-19 infection (41). The endoscopy staff successfully applied strict medical precautions to prevent spread of COVID-19 infection to medical personnel participating in the endoscopic procedure.

Uncommon esophageal diseases have been incidentally reported in COVID-19 patients, including achalasia (42), esophageal necrosis (43), esophageal rupture/Boerhave's syndrome (44), and scleroderma esophagus/systemic sclerosis (45). A patient with pneumonia and respiratory failure from COVID-19 infection had massive upper gastrointestinal hemorrhage from prolonged nasogastric tube placement (46). Pill-induced esophagitis was more prevalent in COVID-19 infected patients, partially related to doxycycline antibiotic therapy for treating COVID-19 infection (47). Mental health issues may underlie the increased corrosive ingestion during the pandemic (48). In one notable case, esophageal ulceration was detected at the site of COVID-19 virus infection, as detected by electron microscopy (49).

## Eosinophilic esophagitis

Severity of COVID-19 infection and COVID-19-induced EoE (eosinophilic esophagitis) or EGID (eosinophilic gastrointestinal disorder) flares were analyzed in a global registry incorporating 94 cases of EoE and EGID patients who developed acute COVID-19 infection between March and April 2021 (median age, 21 years; range, 1.5-53 years; 73% male) (50). Most patients had a history of atopy (73%) and most had isolated EoE (80%). Before infection with COVID-19, the EoE/EGID activity was reported in clinical remission in 51 (54%) and as moderate in 20 (21%). EoE/EGID treatments at the time of COVID-19 infection included proton pump inhibitors in 49 (52%), swallowed or topical corticosteroids in 48 (51%), and dietary elimination therapy in 34 (36%). COVID-19 symptoms included cough (56%), pyrexia (49%), anosmia (21%), and ageusia (22%). Patients with COVID-19 infection typically had mild infection, with 15% asymptomatic, 70% with mild disease, 12% moderate disease, and only 2% with severe disease. Only three patients were hospitalized. No patients had intensive care unit admissions or deaths. Only one patient experienced an EGID flare during COVID-19 infection. Based on this global registry, patients with EoE do not appear to be at increased risk for severe COVID-19 infection or at increased risk of EoE/EGID flares during acute COVID-19 infection.

In a survey of 102 patients with EoE followed at The University of Salerno and Padua, one patient, a 23-year-old-male with a history of EoE for about ten years, developed acute COVID-19 infection (51), while chronically administered therapy with oral viscous budesonide, 15 ml twice daily, and following a legumes-free diet for a suspected dietary history of allergy to legumes. The patient developed acute symptoms of asthenia, headache, anosmia, and ageusia. At diagnosis of acute COVID-19 infection, therapy with budesonide was discontinued and azithromycin therapy (500 mg per day) was initiated for 5 days. The patient never developed dysphagia, odynophagia, or other esophageal symptoms; and never required respiratory assistance or oxygen therapy; findings consistent with moderate COVID-19 infection. He became COVID-19 free by nasal swab several weeks after diagnosis.

## STOMACH

Common GI symptoms, such as nausea and vomiting or abdominal pain, may relate to COVID-19 affinity to the abundant ACE2 receptors in the GI tract, including the stomach and duodenum (52). A large European study of endoscopic findings in COVID-19-infected patients noted common upper GI pathology, including: ulcers (25%), erosive/superficial ulcerative gastroduodenitis (16%), and petechial/hemorrhagic gastropathy (9%) (53). A systematic review of EGD in COVID-19-infected patients reported upper GI ulcers in nearly half of subjects (54). Gastric ulcers in patients with COVID-19 infection were associated with a poor prognosis in one small study (55). An elderly COVID-19-infected patient died from emphysematous gastritis (56). Gastric perforation has been reported in patients with COVID-19 infection (57,58).

In a study conducted from June 1 to July 20, 2020, 108 patients diagnosed with COVID-19 infection underwent antigen screening tests to determine the presence of *H. pylori* in stool samples. Thirty-one of the patients were *H. pylori*-positive, including 8 women (25.8%), and 77 patients were *H. pylori*-negative. The presence of *H. pylori* infection was significantly associated with abdominal pain (19.4% vs 2.6%,  $p=.007$ ) and diarrhea (32.3% vs 9.1%,  $p=.006$ ). *H. pylori* positivity was not significantly associated with hospital length of stay, severity of the course of COVID-19 infection, or the outcome of COVID-19 infection. This study suggests that *H. pylori* does not affect the severity or outcome of COVID-19 infection but does increase the frequency of symptoms of abdominal pain and diarrhea (59).

## GI Hemorrhage

Gastrointestinal hemorrhage is uncommon in hospitalized patients with COVID-19 infection, especially relative to the frequency of other GI complaints. There is a paucity of endoscopic data reflecting prioritization of endoscopic resources and understandable reluctance to perform nonessential, elective endoscopies in COVID-19 infected patients. The spectrum of patient presentation parallels that expected for hospitalized patients with predominant pulmonary or multisystem pathology and prothrombotic

tendency. Clinical presentations include progressive anemia, hemoccult-positive stool, hematemesis, melena, abdominal pain, and altered vital signs. Administration of anticoagulants, commonly administered to COVID-19-infected patients to prevent thrombosis, can exacerbate the bleeding. GI hemorrhage was reported in up to 13% of patients hospitalized with COVID-19 infection, but most studies reported a significantly lower prevalence (60,61,62,63). Another global meta-analysis reported 9% of more than 25,000 COVID-19 infected patients presented with hematemesis (64). The most common findings in this relatively sparse data set were peptic disease, including gastritis and gastroduodenal erosions/ulcers (60,61,62,63). Pulmonary manifestations usually predominate in patients hospitalized with COVID-19 infection, but occasionally GI hemorrhage may be the presenting symptom (65). GI hemorrhage can sometimes present with subtle symptoms and signs of GI bleeding and can sometimes present with subtle symptoms and signs of COVID-19 infection (65). Several patients presented with GI bleeding from esophageal or gastrointestinal ulcers presumably from primary COVID-19 infection, as evidenced by findings on electron microscopy (66,67).

GI hemorrhage in COVID-19 infected patients may be self-limited and may be inferred without performing endoscopy, but sometimes the bleeding is severe or even life-threatening mandating endoscopy (68,69,70,71). Most, but not all, studies suggest a worse prognosis for COVID-19-infected patients with GI bleeding as compared to those without GI bleeding (70,71,72). A meta-analysis of 123 patients with GI bleeding noted a reluctance to perform EGD for GI bleeding, with only 40% undergoing EGD and EGD reserved for patients with more severe GI bleeding (65). This monograph has a chapter dedicated to GI bleeding in COVID-19 infected patients.

Similarly, a survey of 184 general surgeons reported that they operated on  $\geq 7$  cases on average per week before the COVID-19 pandemic compared with only 31 (8.5%) respondents reporting the same number of operations during the pandemic ( $p < 0.001$ ). Two-hundred and nine respondents (57.6%) reported that at least 25% of their elective surgeries were canceled or postponed, whereas only 50

(13.8%) reported that at least 25% of their emergent surgeries were canceled or postponed ( $p < 0.001$ )(73).

#### Small intestine

The vast small intestinal mucosal surface area, with a plethora of lymphatics, constitutes a battleground for host response to foreign antigens, including viruses. Both respiratory alveoli and enterocyte brush borders have abundant angiotensin converting enzyme two receptors and viral RNA of SARS-CoV-19 has been detected in stool, sometimes persisting for many weeks (74). Theoretically this can lead to immune-mediated pathology in both organs. Fecal–oral transmission of COVID-19 is likely (75). There is burgeoning evidence for bidirectional cross talk between the lungs and gut microbiome that has potential implications for COVID-19 dissemination and for disruption of the microbiota by antibiotics (75, 76). Modulation of the gut microbiome by probiotics has a potential role in the prevention of COVID-19 infection and as adjunctive therapy (76,77).

Celiac patients do not seem to have increased susceptibility to COVID-19 infection, though one group noted an increased incidence of concomitant celiac disease and type I diabetes during the pandemic (78,79). There is a concern about increased celiac cases in the future due to the pandemic (80). Celiac patients do not have a worse outcome with acute COVID-19 infection (81). One study suggested COVID-19 infection disproportionately disrupted amino acid absorption, with nutritional implications (82). The mainstay of therapy for celiac disease in COVID-19-infected patients is strict maintenance of a gluten-free diet (83).

Multisystem inflammatory syndrome, a newly described syndrome in children, mimics regional enteritis and has been found in pediatric COVID-19 patients associated with viral cytopathic affects coupled with an abnormal immune response (84). A similar presentation was noted in a young adult male (85), who recovered from COVID-19 infection but presented later with small bowel obstruction, fistula,

and contained perforation, deemed secondary to prior enteritis. COVID-19 may be associated with acute exacerbations of Crohn's disease (85,86).

The most severe small intestinal manifestations of COVID-19 infection are enteritis, hemorrhage, infarction, and perforation likely secondary to microcirculatory and sometimes large vessel thromboses. Histologic examination of intestinal ischemia in COVID-19-infected patients noted small vessel fibrin thrombi, submucosal vessels with fibrinous degeneration, and perivascular neutrophils (87). Acute mesenteric ischemia in COVID-19 patients may result from acute emboli, thrombosis, and non-occlusive mesenteric ischemia, or combinations thereof (88). A database of almost 3,000 Italian patients hospitalized with COVID-19 infection noted 0.7% had mesenteric ischemia either at presentation or during the hospitalization, with almost 40% mortality reported in patients with mesenteric ischemia (89). In a pooled database, 24% of COVID-19 patients with mesenteric ischemia had small intestinal involvement (90). Small series note small intestinal infarction (91). Symptoms of early mesenteric ischemia are nonspecific and CT findings are often only moderately specific leading to frequent delayed diagnosis and delayed intervention; especially during the pandemic (92). Large vessel thromboses have been reported in COVID-19-infected patients, including involvement of the superior mesenteric artery or the portal/mesenteric veins (92,93,94).

Twenty-two percent of a series of COVID-19-infected patients with pneumatosis had isolated small intestinal involvement (95). A child with multisystem inflammatory syndrome developed pneumatosis and small intestinal perforation but survived after undergoing surgery (96). A Mexican series of COVID-19-infected patients included 10 patients with intestinal perforations, of whom four had perforations located in the proximal jejunum (97). A case report described a child with both pneumatosis and protein losing enteropathy (98). Two cases of severe enteritis necessitating small bowel resections were reported, including one COVID-19-infected patient without respiratory symptoms (99,100).



COVID-19 infection may be associated with intussusception in infants or children due to bowel wall inflammation (101,102). Two children had intussusception with COVID-19 infection with evidence of the virus causing inflammation in mesenteric and intestinal tissue (103).

COVID-19-infected patients with underlying risk factors including uncontrolled diabetes, high-dose corticosteroid therapy, and exposure to mechanical ventilation have increasingly developed mucormycosis, sometimes with GI involvement (104). Clinicians must be vigilant for invasive mucormycosis complicating the therapy for advanced COVID-19 infection (105).

#### Colon

A large study surveilling the incidence and severity of COVID-19 infection from February 1 through July 31, 2020 in 10,552 patients with microscopic colitis (MC), including 3237 with the MC type denoted collagenous colitis (CC) and 7315 with the MC type denoted lymphocytic colitis (LC), versus 52,624 matched controls without MC, as diagnosed by colonic biopsies in Sweden from 1989 through 2016 (using the Epidemiology Strengthened by histoPathology Reports in Sweden (ESPRESSO study) reported that patients with the CC type had a significantly higher risk of developing COVID-19 infection (Hazard ratio (HR) =1.72; 95% CI, 1.29–2.28), a significantly higher risk of hospitalization for COVID-19 infection (HR=3.40; 95% CI, 2.03–5.70), and a significantly higher risk of developing severe COVID-19 infection (HR, 2.48; 95% CI, 1.33–4.63) compared to controls (106). Severe COVID-19 infection was defined by hospitalization with laboratory-confirmed COVID-19 as the primary diagnosis or by intensive care unit admission or death within 30 days of hospital admission with COVID-19 infection regardless of whether COVID-19 was the primary diagnosis on admission. Individuals suffering from severe COVID-19 infection or death prior to July 31, 2020, were censored to further follow-up. These results were not due to potential confounders of immunosuppression from oral corticosteroid therapy (used to treat MC) or PPI use (associated with MC). Contrariwise, there were no associations between the LC type of MC and

severe COVID-19 outcomes. This work strongly suggests an association between CC and COVID-19 infection and severe COVID-19 infection/poor patient outcome, but no such association between LC and these parameters of severe COVID-19 infection were observed. Although the precise biologic mechanism for the observed association between CC and severe COVID-19 outcomes are unknown, the increased risk may relate to genetic factors that modify immune responses to viral pathogens, such as an extended HLA haplotype associated with CC (but unassociated with LC), that is associated with impaired immune responses to microbial and viral pathogens with CC. Interestingly, this study demonstrated an increased prevalence of the rs13071258 A variant on the genetic locus 3p21.31 in individuals with CC but not with LC. This locus harbors six genes potentially affecting immunologic defense to viral infections. This study provides important insight into the divergent response of CC versus LC to acute COVID-19 infection, but this study requires further confirmation of the postulated biologic mechanisms.

Interestingly, this locus would be subject to chromosomal amplification in trisomy-21 (Down syndrome) because of the extra copy of this allele in this syndrome. This phenomenon may underlie the worse GI or other organ outcomes in patients with COVID-19 infection who have Down syndrome (107). For example, patients with Down syndrome and COVID-19 infection have worse outcomes from chronic GERD than controls with COVID-19 infection without Down syndrome (108).

In a case report, one patient with severe, chronic, CC had severe acute COVID-19 infection manifested by prolonged hospitalization (109). Notably, this patient exhibited protein-losing enteropathy (PLE), attributed to collagenous duodenitis (CD) coexistent with advanced collagenous colitis from a pathologically thick microscopic collagen layer in the duodenum that likely prevented normal absorption of individual and small chains of amino acids in the small bowel. The reported novel association of CD (and CC) with PLE and their association with severe COVID-19 infection was potentially attributed to relative immunosuppression from hypoproteinemia, hypoalbuminemia, hypogammaglobulinemia, and severe malnutrition from PLE. This patient (109), however, was not analyzed for the presence of the

rs13071258 A variant on the genetic locus 3p21.31 which is potentially associated with severe COVID-19 infection in individuals with CC (106).

A 62-year-old female, with chronic GERD, but no administration of proton pump inhibitors or non-steroidal anti-inflammatory drugs (NSAIDs) for several years and no other gastrointestinal symptoms or disorders, developed acute COVID-19 infection manifesting as acute onset of cough, severe headache, and low-grade pyrexia (110). After ten days of gradual improvement after instituting symptomatic therapy, the patient developed watery, non-bloody, diarrhea, with up to six bowel movements daily, and rectal urgency, that persisted for 3 months despite symptomatic treatment with acetaminophen and loperamide. Stool microscopy and cultures were negative for standard enteric pathogens. Complete blood count, liver function tests, kidney function tests, thyroid function tests, and C-reactive protein levels were within normal limits. Tissue transglutaminase antibody (tTG-IgA) test was negative. Colonoscopy, performed for persistent diarrhea, revealed only scattered uncomplicated sigmoid diverticula. Histopathological analysis of sigmoid and descending colonic biopsies revealed increased chronic inflammatory cell infiltration of the lamina propria, lymphocytes extending into the surface epithelium and the epithelium lining the crypts, findings typical for lymphocytic colitis without findings of collagenous colitis or inflammatory bowel disease. This case report suggests that lymphocytic colitis should be considered in the differential of chronic persistent watery diarrhea after acute COVID-19 infection, before diagnosing long-term COVID, even though COVID-19 likely does not increase the risks of lymphocytic colitis (106).

A 43-year-old man developed GI bleeding after treatment with tocilizumab, a monoclonal antibody against interleukin-6 (IL-6), for severe acute COVID-19 infection complicated by acute respiratory distress syndrome believed due to cytokine release syndrome (CRS)(111). Supportive investigations for CRS included highly elevated levels of interleukin-6 (IL-6), ferritin, and lactate dehydrogenase. Colonoscopy performed for GI bleeding revealed terminal ileal and cecal ulcers. The

patient required surgical resection of the diseased terminal ileum and cecum because of cecal perforation. This patient had a history of potential confounders including lupus anticoagulant without receiving chronic anticoagulation therapy, chronic renal insufficiency, and the cytokine release syndrome itself, all of which could promote enteric ulcerations. Tocilizumab has been previously associated with lower GI perforation and colonic diverticular perforation during treatment for rheumatoid arthritis (112) but has not been previously associated with GI perforation during treatment for the cytokine release syndrome from severe COVID-19 infection.

In a study of 11 hospitals in New York City, the rate of Clostridioides (*Clostridium*) difficile infection increased from the spring of 2019 to the spring of 2020 associated with the onset of the COVID-19 pandemic crisis in spring 2020 (113). Approximately one-third of cases of *C. difficile* in spring of 2020 were in patients with COVID-19 infection, but two-thirds of cases were unassociated with COVID-19 infection. The increase in *C. difficile* during the spring of 2020 correlated with a 20% increase in antibiotic usage in spring 2020 from the year earlier that was correlated with increased cephalosporin therapy to treat infections but was uncorrelated with increased use of other antibiotics. Cephalosporins are a known significant risk factor for *C. difficile* infection. This correlation occurred in each of the 11 study hospitals, which employed independent antibiotic protocols.

In a retrospective study of 6,002 abdominal CT examinations conducted at five hospitals by investigators at the Massachusetts General Hospital the rates of positive diagnoses of acute appendicitis and/or diverticulitis over the six weeks just before versus the six weeks just after the onset of the COVID-19 pandemic in March 2022 were 4% (144) versus 4% (100) for appendicitis and 8% versus 7% for diverticulitis ( $p>0.2$  for both) (114). For positive CT examinations, the rates of perforation, hospitalization, surgery, and catheter drainage changed minimally from before to after the pandemic onset: by -2%, -3%, -2%, and -3%, respectively, for appendicitis ( $n=244$ ,  $p>0.3$  for all) and by +6% ( $p=0.2$ ) +9% ( $p=0.06$ ), +4% ( $p=0.01$ ), and +1% ( $p=0.6$ ), respectively, for diverticulitis ( $n=443$ ). CT examinations performed for

suspected appendicitis or diverticulitis declined slightly after the pandemic onset most likely reflecting patients leaving urban centers due to the pandemic and altered triage of non-COVID-19 patients. However, the diagnostic rates, disease severity at presentation, and treatment approach otherwise remained mostly unchanged during the first six weeks of the COVID pandemic compared to the previous six weeks.

Several cases of acute colonic pseudo-obstruction have been reported in patients with severe COVID-19-associated pneumonia (115). Patients typically are elderly, have normal serum lactate levels, clinically obscure hypoxia, abdominal distension, sluggish bowel sounds, and colonic dilatation supported by radiographic findings at abdominal flat plate or abdominal computerized tomography. Acute colonic pseudo-obstruction in patients admitted with COVID-19 pneumonia requires a high index of suspicion as it warrants early mitigation by discontinuing offending agents, optimizing electrolytes, and therapeutic colonic decompression to decrease morbidity and mortality.

The COVID-19 pandemic has affected colonoscopy for screening or surveillance of colon cancer or colonic polyps. The COVID-19 pandemic has created a backlog of colonoscopy for such indications with attendant stricter application of colonoscopy indications due to potential risks to patients or endoscopy personnel from exposure to COVID-19 infection (116). One approach to decrease exposure to COVID-19 infection is to offer some patients CT colonography (CTC). Indications for CTC in a study of 224 patients at four academic British hospitals included: change in bowel habits (116/224; 48%), positive fecal immunochemical test (69/224; 31%), iron deficiency anemia (50/224; 23%), weight loss (27/224; 7.6%), bleeding per rectum (27/224; 12%), polyp surveillance (25/224; 11%), and abdominal pain (20/224; 9%). Of 224 patients undergoing CT colonography In May to July 2020 at four British hospitals, 55 patients (24.6%), had a  $\geq 6$  mm colonic polyp detected by CTC (117). Of 169 patients contacted by telephone for follow-up, none reported any new symptoms of COVID-19 infection (cough, pyrexia, anosmia, ageusia) within 14 days of the CTC. None of the 86 staff performing CT colonography who were contacted

developed COVID-19 infection after the procedure. These findings suggest that CT colonography can be performed relatively safely during the COVID-19 pandemic, with a relatively high yield of colonic polyps by expert GI radiologists. The risks of developing COVID-19 infection from CTC are low in patients and in the radiology staff.

In a study of 190 consecutive tertiary referrals with irritable bowel syndrome (IBS), patients seen during the COVID-19 pandemic had greater IBS severity (IBS-SSS: 352 vs. 318,  $p=0.03$ ), more severe extra-intestinal symptoms (non-colonic score: 269 vs. 225,  $p=0.03$ ), more frequent sleep difficulties ( $p=0.03$ ), and feelings of helplessness and loss of control ( $p=0.02$ ) compared to baseline patients before the pandemic (118). However, patients during the pandemic had similar HAD-Anxiety ( $p=0.96$ ) and HAD-Depression ( $p=0.84$ ) scores. During the pandemic, unmarried patients ( $p=0.03$ ), and workers in stressful jobs ( $p=0.0038$ ) had greater IBS severity. This study demonstrated that patients seen in tertiary care with refractory IBS during the COVID-19 pandemic had a significantly higher symptom burden. These findings suggest the importance of the gut-brain axis in IBS and that lack of support and perceived loss of patient control during the COVID-19 pandemic may exacerbate the symptoms of IBS.

COVID-19-infected patients with inflammatory bowel disease as compared to patients without COVID-19 infection have a worse prognosis when treated with corticosteroids but not with tumor necrosis factor (TNF) antagonists (119,120). The management of patients with cancer receiving immune checkpoint inhibitor therapy may be affected by COVID-19 infection due to the occurrence of immune checkpoint inhibitor colitis (121).

## Anus

Hemorrhoids are very common in both the general population and COVID-19-infected patients. Surgery for hemorrhoids should be prioritized according to symptoms and signs, with deferral of elective surgery. An e-consult may help in prioritizing patients for surgery (122).

Anal fissures are very common during the pandemic and may be increased by COVID-19 infection, with a reported rate of 30% in chronic COVID-19 patients attributed to sitting on a chair in front of a computer while working at home, and shared risk factors, especially obesity (123).

In a survey of 45 office procedures performed by proctologists during the pandemic, the most common indication for surgery was anal abscesses and/or fistula (48.9%) (124).

## Conclusions

While most of the morbidity and mortality of the COVID-19 pandemic involves the respiratory system, the virus also prominently affects the gastrointestinal system in which it produces considerable symptoms and contributes to patient morbidity and mortality. The COVID-19 virus can directly infect gastrointestinal mucosa due to the abundant angiotensin converting enzyme two receptors within these organs. This work describes the effect of COVID-19 on miscellaneous gastrointestinal disorders (Table 1), thereby supplementing other chapters in this monograph reviewing individual gastrointestinal symptoms or disorders in patients with COVID-19 infection, inflammatory bowel disease, gastrointestinal bleeding, gastrointestinal endoscopy, surgical considerations with gastrointestinal disorders, diagnostic and therapeutic gastrointestinal radiology (Table 2), gastrointestinal pathology, and chronic (long) COVID infection. Other chapters in this monograph review pancreatic and hepatic symptoms and disorders associated with COVID-19 infection.

## References

1. Schreiber M. What a million Covid dead means for the U.S.'s future. Scientific American. [www.scientificamerican.com](http://www.scientificamerican.com) March 29 2022. Accessed April 8, 2022.
2. Parohan M, Yaghoubi S, Seraji A, et al. Risk factors for mortality in patients with coronavirus disease 2019 (COVID-19) infection: a systematic review and meta-analysis of observational studies. *Aging Male* 2020; 23(5):1416-1424.
3. Daniell H, Nair SK, Esmaeili N, Wakade G, Shahid N, Ganesan PK, et al. Debulking SARS-CoV-2 in saliva using angiotensin converting enzyme 2 in chewing gum to decrease oral virus transmission and infection. *Mol Ther*. 2022 May 4;30(5):1966-1978. doi: 10.1016/j.ymthe.2021.11.008. Epub 2021 Nov 11. PMID: 34774754; PMCID: PMC8580552.
4. de Sousa FACG, Paradella TC. Considerations on oral manifestations of COVID-19. *J Med Virol* 2021; 93(2):667-668.
5. Barbato L, Bernardelli F, Braga G, et al. Surface disinfection and protective masks for SARS-CoV-2 and other respiratory viruses: A review by SIdP COVID-19 task force. *Oral Dis* 2020; 18;10.1111/odi.
6. Manhas M, Koul D, Kalsotra G, Manhas A, Kalsotra P, Kumar P, Bhat A, Gupta A, Saraf A. Incidence of olfactory and gustatory dysfunctions in the early stages of COVID-19: An objective evaluation. *Int Arch Otorhinolaryngol*. 2022 May 20;26(2):e265-e271. doi: 10.1055/s-0042-1743274. PMID: 35602269.
7. Neta FI, Fernandes ACL, Vale AJM, Pinheiro FI, Cobucci RN, Azevedo EP, Guzen FP. Pathophysiology and possible treatments for olfactory-gustatory disorders in patients affected by COVID-19. *Curr Res Pharmacol Drug Discov*. 2021;2:100035. doi: 10.1016/j.crphar.2021.100035. Epub 2021 Jun 5. PMID: 34870148.



8. Benezit F, Le Turnier P, Declerck C, et al. Utility of hyposmia and hypogeusia for the diagnosis of COVID-19. *Lancet Infect Dis* 2020; 20(9):1014-1015.
9. Jalessi M, Barati M, Rohani M, et al. Frequency and outcome of olfactory impairment and sinonasal involvement in hospitalized patients with COVID-19. *Neurol Sci.* 2020; 41(9):2331-2338.
10. Khani E, Khiali S, Beheshtirouy S, et al. Potential pharmacologic treatments for COVID-19 smell and taste loss: A comprehensive review. *Eur J Pharmacol* 2021; 5; 912:174582.
11. Extance A. Covid-19: What is the evidence for the antiviral Paxlovid? *BMJ.* 2022 Apr 27;377:o1037. doi: 10.1136/bmj.o1037. PMID: 35477536.
12. Nuño González A, Magaletskyy K, Martín Carrillo P, Lozano Masdemont B, Mayor Ibarguren A, Feito Rodríguez M, Herranz Pinto P. Are oral mucosal changes a sign of COVID-19? A cross-sectional study at a field hospital. *Actas Dermosifiliogr (Engl Ed).* 2021 Feb 27;112(7):640–4. English, Spanish. doi: 10.1016/j.ad.2021.02.007. Epub ahead of print. PMID: 33652010.
13. Iranmanesh B, Khalili M, Amiri R, Zartab H, Aflatoonian M. Oral manifestations of COVID-19 disease: A review article. *Dermatol Ther.* 2021 Jan;34(1):e14578. doi: 10.1111/dth.14578. Epub 2020 Dec 13. PMID: 33236823; PMCID: PMC7744903.
14. Bardellini E, Bondioni MP, Amadori F, et al. Non-specific oral and cutaneous manifestations of Coronavirus Disease 2019 in children. *Med Oral Patol Oral Circ Bucal* 2021; 26(5):e549-e553.
15. Gherlone EF, Polizzi E, Tetè G, et al. Frequent and persistent salivary gland ectasia and oral disease after COVID-19. *J Dent Res.* 2021; 100(5):464-471.
16. Wang L, Foer D, MacPhaul E, et al. PASClex: A comprehensive post-acute sequelae of COVID-19 (PASC) symptom lexicon derived from electronic health record clinical notes. *J Biomed Inform.* 2022; 125:103951.

17. Kaulamo JT, Lätti AM, Koskela HO. Cough in the elderly during the COVID-19 pandemic. *Lung* 2022; 17;1-8.
18. Saito H, Ozaki A, Mizuno Y, Todo K. Difficulty in diagnosing mild cases of COVID-19 without respiratory symptoms during the novel coronavirus pandemic: Careful monitoring needed for patients with persistent upper gastrointestinal symptoms. *Clin Case Rep*. 2020; 31:8(12):2787-2790.
19. Ong JS, Gharahkhani P, Vaughan TL, et al. Assessing the genetic relationship between gastro-esophageal reflux disease and risk of COVID-19 infection. *Hum Molec Genet*. 2022;31(3):471-480.
20. Jiang G, Cai Y, Yi X, et al. The impact of laryngopharyngeal reflux disease on 95 hospitalized patients with COVID-19 in Wuhan, China: A retrospective study. *J Med Virol* 2020; 92(10):2124-2129.
21. Kow CS, Hasan SS. Could melatonin be used in COVID-19 patients with laryngopharyngeal reflux disease? *J Med Virol* 2021; 93(1):92-93.
22. in RU, Brown JW, Li QK, et al. Tropism of severe acute respiratory syndrome coronavirus 2 for Barrett's esophagus may increase susceptibility to developing coronavirus disease 2019. *Gastroenterology* 2021; 160(6):2165-2168.e4.
23. Almario CV, Chey WD, Spiegel BMR. Increased risk of COVID-19 among users of proton pump inhibitors. *Am J Gastroenterol* 2020; 115(10):1707-1715.
24. Kim HB, Kim JH, Wolf BJ. Acid suppressant use in association with incidence and severe outcomes of COVID-19: a systematic review and meta-analysis. *Eur J Clin Pharmacol* 2022; 78(3):383-391.
25. Ramachandran P, Perisetti A, Gajendran M, et al. Pre-hospitalization proton pump inhibitor use and clinical outcomes in COVID-19. *Eur J Gastroenterol Hepatol* 2022; 1;34(2):137-141.

26. Lee SW, Ha EK, Yeniova AÖ, et al. Severe clinical outcomes of COVID-19 associated with proton pump inhibitors: a nationwide cohort study with propensity score matching. *Gut* 2021; 70(1):76-84.
27. Israelsen SB, Ernst MT, Lundh A, Lundbo LF, Sandholdt H, Hallas J, Benfield T. Proton pump inhibitor use is not strongly associated with SARS-CoV-2 related outcomes: A nationwide study and meta-analysis. *Clin Gastroenterol Hepatol*. 2021; 19(9):1845-1854.e6.
28. Shafir A, Benson AA, Katz LH, et al. The association between proton pump inhibitors and COVID-19 is confounded by hyperglycemia in a population-based study. *Front Pharmacol*. 2022; 4;13:791074.
29. Pahwani S, Kumar M, Aperia F, Gul M, Lal D, Rakesh F, Shabbir MR, Rizwan A. Efficacy of oral famotidine in patients hospitalized with severe acute respiratory syndrome Coronavirus 2. *Cureus*. 2022 Feb 20;14(2):e22404. doi: 10.7759/cureus.22404. PMID: 35345695; PMCID: PMC8942052.
30. Malone RW. More than just heartburn: Does famotidine effectively treat patients with COVID-19? *Dig Dis Sci* 2021; 66(11):3672-3673.
31. Shoaibi A, Fortin SP, Weinstein R, et al. Comparative effectiveness of famotidine in hospitalized COVID-19 patients. *Am J Gastroenterol* 2021; 116(4):692-699.
32. Arastehfar A, Carvalho A, Nguyen MH, Hedayati MT, Netea MG, Perlin DS, Hoenigl M. COVID-19-associated candidiasis (CAC): An underestimated complication in the absence of immunological predispositions? *J Fungi (Basel)*. 2020 (Oct 8); 6(4):211. doi: 10.3390/jof6040211.
33. Jothimani D., Danielraj S., Nallathambi B., et al. Optimal diagnostic tool for surveillance of oesophageal varices during COVID-19 pandemic. *Clin Radiol*. 2021;76(7):550.e1–550.e7
34. Trindade AJ, Zhang J, Hauschild J, et al. Impact of Coronavirus Disease 2019 on the diagnosis and therapy for Barrett's esophagus and esophageal cancer in the United States. *Gastroenterology* 2022; 162(3):978-980.e6.

35. Darwin P, Zangara J, Heller T, Haluszka O, Laurin J. Unsedated esophagoscopy for the diagnosis of esophageal varices in patients with cirrhosis. *Endoscopy*. 2000; 32(12):971-973. Doi:org/10.1055/s-2000-9624.
36. Grant RK, Brindle WM, Robertson AR, et al. Unsedated transnasal endoscopy: A safe, well-tolerated and accurate alternative to standard diagnostic peroral endoscopy. *Dig Dis Sci*. 2022; 3:1-11.
37. Berté R, Arsié E, Penagini R. Safe esophageal function testing during the COVID-19 pandemic: A modified surgical mask for patients. *Neurogastroenterol Motil*. 2020;32(9):e13979.
38. Pilonis ND, Killcoyne S, Tan WK, et al. Use of a cytosponge biomarker panel to prioritize endoscopic Barrett's oesophagus surveillance: a cross-sectional study followed by a real-world prospective pilot. *Lancet Ocol* 2022; 23(2):270-278.
39. Elli L, Tontini GE, Filippi E, et al. Efficacy of endoscopic triage during the Covid-19 outbreak and infective risk. *Eur J Gastroenterol Hepatol* 2020;32(10):1301-1304.
40. Ominami M, Sato H, Fujiyoshi Y, Abe H, Shiwaku H, Shiota J, Sato C, Sakae H, Hata Y, Fukuda H, Ogawa R, Nakamura J, Tatsuta T, Ikebuchi Y, Yokomichi H, Fujiwara Y, Inoue H. Impact of the COVID-19 pandemic on high-resolution manometry and peroral endoscopic myotomy for esophageal motility disorder in Japan. *Dig Endosc*. 2022 May;34(4):769-777. doi: 10.1111/den.14133. Epub 2021 Sep 27. PMID: 34510551; PMCID: PMC8653167.
41. El Kassas M, Al Shafie A, Abdel Hameed AS, Mahdi M. Emergency endoscopic variceal band ligation in a COVID-19 patient presented with hematemesis while on mechanical ventilation. *Dig Endosc*. 2020 Jul;32(5):812-815. doi: 10.1111/den.13694. Epub 2020 Jun 7. PMID: 32289878; PMCID: PMC7262052.
42. Cali A, La Fortezza RF, Fusaroli P. An unexpected thoracic finding in a patient with COVID-19. *Gastroenterology* 2021; 161(4):1111-1112.

43. Deliwala SS, Gurvits GE. Acute esophageal necrosis in a patient with COVID-19. *Am J Gastroenterol* 2021; 116(10):1977.
44. Rahman A, Alqasai S, Downing C. Unusual presentation of COVID pneumonia as esophageal rupture ended with successful management. *Cureus* 2021; 13(8):e17348.
45. Chandra A, Kahaleh B. Systemic sclerosis (SSc) after COVID-19: A case report. *Cureus* 2022 Mar 15; 14(3):e23179. doi: 10.7759/cureus.23179. eCollection 2022 Mar.14(3):e23179.
46. Hlayhel A, Foran L, Trivedi A, et al. A case of esophageal ulcer and hemorrhage due to aberrant subclavian in a COVID positive patient. *J Surg Case Rep.* 2022 ;2022(1).
47. Panigrahi MK, Nayak HK, Samal SC. A recent surge of doxycycline-induced pill esophagitis during the corona virus disease 2019 (COVID-19) pandemic. *Indian J Gastroenterol* 2022; 7;1-2.
48. Thongchum C, Mahawongkajit P, Kanlerd A. The effect of the COVID-19 on corrosive ingestion in Thailand. *Open Access Emerg Med.* 2021; 13:299-304.
49. Binder L, Högenauer C, Langner C. Gastrointestinal effects of an attempt to avoid contracting COVID-19 by 'disinfection'. *Histopathology* 2020; 77(2): 327-328.
50. Zevit N, Chehade M, Leung J, Marderfeld L, Dellon ES. Eosinophilic esophagitis patients are not at increased risk of severe COVID-19: A report from a global registry. *Allergy Clin Immunol Pract* 2022 Jan;10(1):143-149.e9. Epub 2021 Oct 22. doi: 10.1016/j.jaip.2021.10.019. PMID: 34688963.
51. Mennini M, Rea F, Riccardi C, De Angelis P, Tambucci R. SARS-COV2 and eosinophilic esophagitis: a first case. *Eur J Gastroenterol Hepatol.* 2021 Aug 1;33(8):1131-1132. doi: 10.1097/MEG.0000000000002109. PMID: 34213509.

52. Xu J, Chu M, Zhong, et al. Digestive symptoms of COVID-19 and expression of ACE2 in digestive tract organs. *Cell Death Discov.* 2020; 11:6:76.
53. Vanella G, Capurso G, Burti C, et al. Gastrointestinal mucosal damage in patients with COVID-19 undergoing endoscopy: an international multicentre study. *BMJ Open Gastroenterol* 2021; 8(1):e000578.
54. Ashktorab H, Russo T, Oskrochi G, et al. Clinical and endoscopic outcomes in Coronavirus Disease-2019 patients with gastrointestinal bleeding. *Gastro Hep Adv.* 2022;1(4):487-499.
55. Deb A, Thongtan T, Costilla V. Gastric ulcerations in COVID-19: an ominous sign? *BMJ Case Rep.* 2021 19;14(7):e244059.
56. Garrosa-Muñoz S, López-Sánchez J, González-Fernández LM, et al. Could SARS-CoV-2 be associated with emphysematous gastritis? *Dig Liver Dis* 2021; 53(5):540.
57. Poggiali E, Vercelli A, Demichele E, et al. Diaphragmatic rupture and gastric perforation in a patient with COVID-19 pneumonia. *Eur J Case Rep Intern Med.* 2020; 27;7(6):001738.
58. Gupta K, Thakur A, Kler N, et al. Gastric perforation and necrotizing enterocolitis associated with COVID antibodies. *Indian J Pediatrics* 2022; 89(1):93.
59. Balamtekin N, Artuk C, Arslan M, Gülşen M. The effect of *Helicobacter pylori* on the presentation and clinical course of coronavirus disease 2019 infection. *J Pediatr Gastroenterol Nutr.* 2021 Apr 1;72(4):511-513. doi: 10.1097/MPG.0000000000003005. PMID: 33306581; PMCID: PMC7984630.
60. Martin TA, Wan DW, Hajifathalian K, et al. Gastrointestinal bleeding in patients with coronavirus disease 2019: A matched case-control study. *Am J Gastroenterol.* 2020; 115(10):1609-1616.
61. Marasco G, Maida M, Morreale GC, et al. Gastrointestinal bleeding in COVID-19 patients: A systematic review with meta-analysis. *Can J Gastroenterol Hepatol* 2021; 2534975.

62. Elshazli RM, Kline A, Elgaml A, et al. Gastroenterology manifestations and COVID-19 outcomes: A meta-analysis of 25,252 cohorts among the first and second waves. *J Med Virol* 2021; 93(5):2740-2768.
63. Melazzini, F, Lenti, MV, Maur, A, De Grazia, F; Di Sabatino, A. Peptic ulcer disease as a common cause of bleeding in patients with Coronavirus disease 2019. *Am J Gastroenterol*. 2020; 115(7):1139-1140. doi: 10.14309/ajg.0000000000000710. PMID: 32618672
64. Goyal H, Sachdeva S, Perisetti A, et al. Management of gastrointestinal bleeding during COVID-19: less is more! *Eur J Gastroenterol Hepatol* 2021; ;33(9):1230-1232
65. Gulen M, Satar S. Uncommon presentation of COVID-19: Gastrointestinal bleeding. *Clin Res Gastroenterol Hepatol*. 2020; 44(4):e72-e76.
66. Bisseling TM, van Laarhoven A, Huijbers A, Brink M, Rovers R, Wagner B, Nagtegaal ID, van der Post RS. Coronavirus disease-19 presenting as esophageal ulceration. *Am J Gastroenterol*. 2021; 1;116(2):421-424. doi: 10.14309/ajg.0000000000000927. PMID: 33086224.
67. Li X, Huang S, Lu J, et al. Upper gastrointestinal bleeding caused by SARS-CoV-2 infection. *Am J Gastroenterol*. 2020; 115(9):1541-1542.
68. Barrett LF, Lo KB, Stanek SR, et al. Self-limited gastrointestinal bleeding in COVID-19. *Clin Res Hepatol Gastroenterol*. 2020; 44(4):e77-e80.
69. Mohamed M, Nassar M, Nso N, et al. Massive gastrointestinal bleeding in a patient with COVID-19. *Arab J Gastroenterol*. 2021; 22(2):177-179.
70. Trindade AJ, Izard S, Coppa K, et al. Gastrointestinal bleeding in hospitalized COVID-19 patients: a propensity score matched cohort study. *J Intern Med*. 2021; 289(6):887-894.

71. Hongxin Chen, Zhenhua Tong, Zhuang Ma, et al. Gastrointestinal bleeding, but not other gastrointestinal symptoms, is associated with worse outcomes in COVID-19 patients. *Front Med (Lausanne)*. 2021; 8: 759152.
72. Iqbal U, Patel PD, Pluskota CA, et al. Outcomes of acute gastrointestinal bleeding in patients with COVID-19: A case-control study. 2022; 15(1): 13–18.
73. Wu, Xian-rui. Zhang, Yun-feng; Lan, Nan; Zhang, Zhong-tao; Wang, Xi-shan; Shen, Bo; Lan, Ping;; Kiran, Ravi P; On behalf of Chinese Society of Colorectal Surgery of China Medical Association Practice Patterns of Colorectal Surgery During the COVID-19 Pandemic. *Practice patterns of colorectal surgery during the COVID-19 pandemic Diseases of the Colon & Rectum: December 2020; 63; (12);1572-1574* doi: 10.1097/DCR.0000000000001840
74. Ding S, Liang TJ. Is SARS-CoV-2 Also an enteric pathogen with potential fecal-oral transmission? A COVID-19 virological and clinical review. *Gastroenterology* 2020; 159(1):53-61.
75. Konturek PC, Harsch IA, Neurath MF, et al. COVID-19 - more than respiratory disease: a gastroenterologist's perspective. *J Physiol Pharamacol* 2020; 71(2).
76. Bottari B, Castellone V, Neviani E. Probiotics and Covid-19. *Int J Food Sci Nutr*. 2021; 72(3):293-299.
77. Tobi M, Talwar H, McVicker B. The celiac disease microbiome depends on the Paneth cells of the puzzle. *Gastroenterology*. 2021 Jul;161(1):359. doi: 10.1053/j.gastro.2021.02.023. Epub 2021 Feb 11. PMID: 33581121.
78. Zhen J, Stefanolo JP, Temprano MP, et al. The risk of contracting COVID-19 is not increased in patients with celiac disease. *Clin Gastroenterol Hepatol*. 2021; ;19(2):391-393.
79. Cakir M, Guven B, Issi F, et al. New-onset celiac disease in children during COVID-19 pandemic. *Acta Paediatr*. 2022; 111(2):383-388.



80. Trovato CM, Montuori M, Pietropaoli N, et al. COVID-19 and celiac disease: A pathogenetic hypothesis for a celiac outbreak. *Int J Clin Pract.* 2021; 75(9):e14452.
81. Lebwohl B, Larsson E, Söderling J, et al. Risk of severe Covid-19 in patients with celiac disease: A population-based cohort study. 2021; 13:121-130.
82. Nisoli E, Cinti S, Valerio A. COVID-19 and Hartnup disease: an affair of intestinal amino acid malabsorption. *Eat Weight Disord.* 2021; 26(5):1647-1651.
83. Samasca G, Lerner A. Celiac disease in the COVID-19 pandemic. *J Transl Autoimmun.* 2021; 4:100120. doi: 10.1016/j.jtauto.2021.100120. Epub 2021 Aug 31. PMID: 34485888; PMCID: PMC8406545.
84. Sahn B, Eze OP, Edelman MC, et al. Features of intestinal disease associated with COVID-related multisystem inflammatory syndrome in children. *J Pediatr Gastroenterol Nutr.* 2021; 72(3):384-387.
85. Parigi TL, Bonifacio C, Danese S. Is It Crohn's Disease? *Gastroenterology* 2020; 159(4):1244-1246.
86. Abbassi B, Deb A, Costilla V, et al. Subacute enteritis two months after COVID-19 pneumonia with mucosal bleeding, perforation, and internal fistulas. *Am Surg.* 2021; 1;31348211023461.
87. Zhang ML, Jacobsen F, Pepe-Mooney BJ, et al. Clinicopathological findings in patients with COVID-19-associated ischaemic enterocolitis. *Histopathology* 2021; 79(6):1004-1017.
88. Patel S, Parikh C, Verma D, et al. Bowel ischemia in COVID-19: A systematic review. *Int J Clin Pract.* 2021; 75(12):e14930.
89. Norsa L, Bonafinni PA, Caldato M, et al. Intestinal ischemic manifestations of SARS-CoV-2: Results from the ABDOCOVID multicentre study. *World J Gastroenterol.* 2021; 27(32):5448-5459.
90. Serban D, Tribus LC, Vancea G, et al. Acute mesenteric Ischemia in COVID-19 Patients. *J Clin Med* 2022; 11(1): 200.

91. Ignat M, Philouze G, Aussenac-Belle L, et al. Small bowel ischemia and SARS-CoV-2 infection: An underdiagnosed distinct clinical entity. *Surgery* 2020; 168(1):14-16.
92. Ojha V, Mani A, Mukherjee A, et al. A Mesenteric ischemia in patients with COVID-19: An updated systematic review of abdominal CT findings in 75 patients. *Abdom Radiol.* 2022; 47(5):1565-1602.
93. Abeysekera KW, Karteszi H, Clark A, Gordon FH. Spontaneous portomesenteric thrombosis in a non-cirrhotic patient with SARS-CoV-2 infection. 2020; 13(12):e238906. *BMJ Case Rep.* 2020 Dec 22;13(12):e238906. doi: 10.1136/bcr-2020-238906. PMID: 33371000
94. Sukegawa M, Nishiwada S, Terai T, et al. Acute superior mesenteric artery occlusion associated with COVID-19 pneumonia: A case report. *Surg Case Rep.* 2022; 10;8(1):6. doi: 10.1186/s40792-022-01360-6. PMID: 35001200
95. Wong K, Kim DH, Khanijo S, et al. Pneumatosis intestinalis in COVID-19: Case series. *Cureus* 2020; 12(10):e10991. DOI: 10.7759/cureus.10991 PMID: 33209547
96. Heza L, Olive A, Miller J. Pneumatosis intestinalis and intestinal perforation in a case of multisystem inflammatory syndrome in children. *BMJ Case Rep.* 2021; 14(4):e241688.
97. Estevez-Cerda SC, Saldaña-Rodríguez JA, Alam-Gidi AG, et al. Severe bowel complications in SARS-CoV-2 patients receiving protocolized care. *Rev Gastroenterol Mex (English).* 2021; 86(4):378-386. DOI: 10.1016/j.rgmxen.2021.08.009 PMID: 34400118
98. Rohani P, Karimi A, Tabatabaie SR, et al. Protein losing enteropathy and pneumatosis intestinalis in a child with COVID 19 infection. *J Ped Surg Case Rep.* 2021; 64:101667. doi: 10.1016/j.epsc.2020.101667. Epub 2020 Nov 5. PMID: 33173753.
99. Amarapurkar AD, Vichare P, Pandya N, et al. Haemorrhagic enteritis and COVID-19: causality or coincidence. *J Clin Pathol.* 2020; 73(10):686. doi: 10.1136/jclinpath-2020-206743. PMID: 32482887

100. Francese M, Ferrari C, Lotti M, et al. The thin red line: ileal angiodysplasia versus SARS-CoV-2-related haemorrhagic enteritis. *J Clin Path* 2022; jclinpath-2021-207754. doi: 10.1136/jclinpath-2021-207754. PMID: 35039451
101. Noviello C, Bollettini T, Mercedes R, et al. COVID-19 can cause severe intussusception in infants: Case report and literature review. *Pediatric Inf Dis J*. 2021 ;40(11):e437-e438.
102. Athamnah MN, Masade S, Hamdallah H, et al. COVID-19 presenting as intussusception in infants: A case report with literature review. *J Pediatr Case Rep*. 2021; 66:101779.
103. Scottoni F, Giobbe GG, Zambaiti E, Khalaf S, Sebire NJ, Curry J, De Coppi P, Gennari F. Intussusception and COVID-19 in Infants: Evidence for an Etiopathologic Correlation. *Pediatrics*. 2022 Jun 1;149(6):e2021054644. doi: 10.1542/peds.2021-054644. PMID: 35322271
104. Sannathimmappa MB, Nambiar V, Aravindakshan R. Storm of a rare opportunistic life threatening mucormycosis among post COVID-19 patients: A tale of two pathogens. *Int J Crit Illn Inj Sci*. 2022 Jan-Mar;12(1):38-46. doi: 10.4103/ijciis.ijciis\_48\_21. Epub 2022 Mar 24. PMID: 35433396'
105. Sharma A, Goel A. Mucormycosis: risk factors, diagnosis, treatments, and challenges during COVID-19 pandemic. *Folia Microbiol (Praha)*. 2022 Jun;67(3):363-387. doi: 10.1007/s12223-021-00934-5. Epub 2022 Feb 26. PMID: 35220559; PMCID: PMC8881997.
106. Khalili H, Zheng T, Söderling J, Larsson E; COVID-19 and microscopic colitis collaborators, Munch A, Sjoberg K, Almer S, Vigren L, Janczewska I, Ohlsson B, Bresso F, Mellander MR, Olén O, Roelstraete B, Franke A, Simon TG, D'Amato M, Ludvigsson JF. Association between collagenous and lymphocytic colitis and risk of severe coronavirus disease 2019. *Gastroenterology*. 2021 Jun;160(7):2585-2587.e3. doi: 10.1053/j.gastro.2021.02.029. Epub 2021 Feb 19. PMID: 33610527.

107. Illouz T, Biragyn A, Frenkel-Morgenstern M, Weissberg O, Gorohovski A, Merzon E, Green I, Iulita F, Flores-Aguilar L, Dierssen M, De Toma I, Lifshitz H, Antonarakis SE, Yu E, Herault Y, Potier MC, Botté A, Roper R, Sredni B, Sarid R, London J, Mobley W, Strydom A, Okun E. Specific Susceptibility to COVID-19 in Adults with Down Syndrome. *Neuromolecular Med.* 2021 Dec;23(4):561-571. doi: 10.1007/s12017-021-08651-5. Epub 2021 Mar 4. Erratum in: *Neuromolecular Med.* 2021 May 4;: Erratum in: *Neuromolecular Med.* 2021 Nov 19;: PMID: 33660221; PMCID: PMC7929736.)
108. Hüls A, Costa ACS, Dierssen M, Baksh RA, Bargagna S, Baumer NT, Brandão AC, Carfi A, Carmona-Iragui M, Chicoine BA, Ghosh S, Lakhanpaul M, Manso C, Mayer MA, Ortega MDC, de Asua DR, Rebillat AS, Russell LA, Sgandurra G, Valentini D, Sherman SL, Strydom A; T21RS COVID-19 Initiative. Medical vulnerability of individuals with Down syndrome to severe COVID-19-data from the Trisomy 21 Research Society and the UK ISARIC4C survey. *EClinicalMedicine.* 2021 Mar;33:100769. doi: 10.1016/j.eclinm.2021.100769. Epub 2021 Feb 22. PMID: 33644721; PMCID: PMC7897934.
109. Gill I, Shaheen AA, Edhi AI, Amin M, Rana K, Cappell MS. Novel case report: A previously reported, but pathophysiologically unexplained, association between collagenous colitis and protein-losing enteropathy may be explained by an undetected link with collagenous duodenitis. *Dig Dis Sci.* 2021 Dec;66(12):4557-4564. doi: 10.1007/s10620-020-06804-3. PMID: 33537921.
110. Nassar IO, Langman G, Quraishi MN, Sharma N. SARS-CoV-2-triggered lymphocytic colitis. *BMJ Case Rep.* 2021 Aug 24;14(8):e243003. doi: 10.1136/bcr-2021-243003.PMID: 34429288
111. Bruce-Hickman D, Sajeed SM, Pang YH, Seow CS, Chen W, Gulati Kansal M. Bowel ulceration following tocilizumab administration in a COVID-19 patient. *BMJ Open Gastroenterol.* 2020 Aug;7(1):e000484. doi: 10.1136/bmjgast-2020-000484. PMID: 32816957.

112. Strangfeld A, Richter A, Siegmund B, et al. Risk for lower intestinal perforations in patients with rheumatoid arthritis treated with tocilizumab in comparison to treatment with other biologic or conventional synthetic DMARDs. *Ann Rheum Dis* 2017; 76:504–10. doi: 10.1136/annrheumdis-2016-209773.
113. Maro A, Asrat H, Qiu W, Liang R, Sunny S, Aslam S, Abdallah M, Fornek M, Episcopia B, Quale L. Trends in *Clostridioides difficile* infection across a public health system in New York City 2019-2021: A cautionary note. *Am J Infect Control*. 2022 May 17:S0196-6553(22)00403-5. doi: 10.1016/j.ajic.2022.04.015. Online ahead of print. PMID: 35569616
114. Kilcoyne A, Goiffon RJ, Anderson MA, Cahalane AM, O'Shea A, Balthazar P, Yeung T, Jang S, Som A, Qadan M, Lee SI. Impact of COVID-19 on CT-diagnosed acute appendicitis and diverticulitis: was there collateral damage? *Clin Radiol*. 2022 Apr 8:S0009-9260(22)00170-2. doi: 10.1016/j.crad.2022.03.013. Epub ahead of print. PMID: 35487779.xxxxx
115. Samuel SV, Viggesswarpu S, Wilson BP, Gopinath KG. Acute colonic pseudo-obstruction in two patients admitted with severe acute respiratory syndrome-coronavirus-2 pneumonia. *ID Cases*. 2021; 25:e01205. doi: [10.1016/j.idcr.2021.e01205](https://doi.org/10.1016/j.idcr.2021.e01205). Epub 2021 Jun 24. PMID: 34189047.
116. Xiao AH, Chang SY, Stevoff CG, Komanduri S, Pandolfino JE, Keswani RN. Adoption of multi-society guidelines facilitates value-based reduction in screening and surveillance colonoscopy volume during COVID-19 pandemic. *Dig Dis Sci*. 2021 Aug;66(8):2578-2584. doi: 10.1007/s10620-020-06539-1. Epub 2020 Aug 16. PMID: 32803460; PMCID: PMC7429116.
117. Peprah D, Plumb A, Corr A, Muckian J, Smith K, Sergot A, Kuah JY, Stephenson J. Re-initiation of CT colonography services during the COVID-19 pandemic: Preliminary evaluation of safety. *Br J Radiol*. 2021 May 1;94(1121):20201316. doi: 10.1259/bjr.20201316. Epub 2021 Apr 9. PMID: 33835838.

118. Noble H, Hasan SS, Whorwell PJ, Vasant DH. The symptom burden of irritable bowel syndrome in tertiary care during the COVID-19 pandemic. *Neurogastroenterol Motil.* 2022 Mar 3:e14347. doi: 10.1111/nmo.14347. Epub ahead of print. PMID: 35238428.
119. Brenner EJ, Ungaro RC, Gearry RB, Kaplan GG, Kissous-Hunt M, Lewis JD, Ng SC, Rahier JF, Reinisch W, Ruemmele FM, Steinwurz F, Underwood FE, Zhang X, Colombel JF, Kappelman MD. Corticosteroids, but not TNF antagonists, are associated with adverse COVID-19 outcomes in patients With Inflammatory bowel diseases: Results from an international registry. *Gastroenterology.* 2020 Aug;159(2):481-491.e3. doi: 10.1053/j.gastro.2020.05.032. Epub 2020 May 18. PMID: 32425234
120. Burke KE, Kochar B, Allegretti JR, Winter RW, Lochhead P, Khalili H, Colizzo FP, Hamilton MJ, Chan WW, Ananthakrishnan AN. Immunosuppressive therapy and risk of COVID-19 infection in patients with inflammatory bowel diseases. *Inflamm Bowel Dis.* 2021 Jan 19;27(2):155-161. doi: 10.1093/ibd/izaa278. PMID: 33089863
121. Grover S, Bond SA, Mansour MK, Friedman S. Management of immunotherapy colitis: Special considerations in the COVID-19 era. *Cancer.* 2020 Nov 1; 126(21):4630-4633. doi: 10.1002/cncr.33125. Epub 2020 Aug 14. PMID: 32797685118.
122. Campennì P, Marra AA, Ferri L, Orefice R, Parello A, Litta F, De Simone V, Goglia M, Ratto C. Impact of COVID-19 quarantine on advanced hemorrhoidal disease and the role of telemedicine in patient management. *J Clin Med.* 2020 Oct 25;9(11):3416. doi: 10.3390/jcm9113416. PMID: 33113796; PMCID: PMC7694108.
123. Hassan SM, Jawad MJ, Jawad MJ, Abu-Raghif AR, Hadi NR. Gastrointestinal and metabolic disturbances in post-COVID-19 disease outcomes. *Wiad Lek.* 2021;74(12):3160-3167. PMID: 35058383.

124. Giani I, Gallo G, Grossi U, Tanda C, Linari C, Elbetti C; Resumption of Proctology Algorithm Working Group. The impact of COVID-19 pandemic on a tertiary referral proctology center: no one should be left behind. *Minerva Surg.* 2022 Feb;77(1):30-34. doi: 10.23736/S2724-5691.21.08897-3. Epub 2021 Jun 23. PMID: 34160175.

Journal Pre-proof

TABLE 1. Effect of COVID-19 infection on gastrointestinal disorders and diseases

<b>Disease or disorder</b>	<b>Clinical characteristics</b>	<b>Mechanism</b>
Anosmia & ageusia/dysgeusia	Very common. Often the first symptom to manifest with COVID-19 infection and the last symptom to resolve. Bothersome symptoms but not life-threatening. Proposed, unproven therapies include corticosteroids and Paxlovid.	Not associated with nasopharyngitis, nasal obstruction, glossitis, zinc deficiency, or rhinorrhea. Postulated decreased sensitivity of olfactory neurons associated with expression of ACE-2 in alveolar epithelial cells.
Geographic (COVID) tongue	Affects about 4% of infected patients. Associated with minor symptoms.	Loss of filiform papillae in rear of tongue from damage caused by high expression of ACE-2 in epithelial cells.
GERD (Gastro-esophageal reflux disease)	Very common with COVID-19 infection but also very common without COVID-19 infection. GERD likely does not arise from acute COVID-19 infection but likely arises from shared risk factors, such as obesity.	COVID-19 may preferentially infect Barrett's epithelium over normal esophageal mucosa, and PPI therapy may be associated with increased COVID-19 susceptibility.
Esophageal candidiasis	Risk factors include: acute respiratory distress syndrome, chronic corticosteroid therapy, and prolonged endotracheal intubation. Often associated with severe COVID-19 infection and has a high mortality due to this association. Typical symptoms are dysphagia and odynophagia. EGD classically demonstrates a cheesy exudate in esophagus. Endoscopic brushings usually diagnostic. Primary therapies are echinocandins and azoles.	Associated with profound immune dysregulation with COVID-19 infection, but the specific underlying immunological defects are unknown.
Pill-induced esophagitis	More prevalent in COVID-19 infected patients.	Partly related to increased use of doxycycline antibiotics to treat COVID-19 infection and increased corrosive ingestion due to COVID-19 pandemic-related stress.
Eosinophilic esophagitis	Apparently eosinophilic esophagitis does not increase the frequency or severity of COVID-19 infection. Acute COVID-19 infection does not apparently cause flares of eosinophilic esophagitis.	Patients with eosinophilic esophagitis typically have mild COVID-19 infection. COVID-19 esophageal infection might be related to oral corticosteroid therapy for eosinophilic esophagitis.
Gastric ulcers	Gastric ulcers very common in patients with COVID-19 infection who are undergoing EGD.	<i>H. pylori</i> does not apparently affect the severity of COVID-19 infection. Several patients had esophageal or gastric ulcers from primary COVID-19 infection, as demonstrated by electron microscopy.
GI (gastrointestinal) hemorrhage	Occurs in about 9% or less of hospitalized COVID-19 infected patients. Often the GI bleeding is mild and does not mandate endoscopy. Patients with GI bleeding often have a worse prognosis from COVID-19 infection than nonbleeding COVID-19- infected patients. GI hemorrhage in COVID-19 patients is often from gastric ulcers. GI bleeding may sometimes arise from anticoagulation used to treat a hypercoagulopathy associated with COVID-19 infection.	GI bleeding rarely due to ulcers associated with primary COVID-19 infection.



Celiac disease	Celiac patients do not have increased susceptibility to COVID-19 infection and do not have a worse outcome from COVID-19 infection. The mainstay of therapy in COVID-19 infected patients is maintenance of a gluten-free diet.	The two different diseases do not appear to significantly interact.
Multisystem inflammatory syndrome	Rare syndrome that occurs in children. Clinically can resemble regional enteritis. Can cause GI obstruction, fistula, or contained GI perforation.	Syndrome associated with an abnormal immune response due to viral cytopathic effects.
Mesenteric ischemia	COVID-19 infection likely increases the risk of mesenteric ischemia. Mesenteric ischemia has a high mortality in COVID-19-infected patients.	Most likely increased frequency of mesenteric ischemia due to microcirculatory thrombosis, but sometimes can occur from large vessel thrombosis. COVID-19 can produce a hypercoagulopathy. High mortality from mesenteric ischemia attributed to delayed diagnosis because symptoms can be confused with acute COVID-19 infection.
Small bowel intussusception	Frequency may increase with COVID-19 infection.	Attributed to bowel wall or mesenteric lymph node inflammation, edema and thickening from local viral infection that forms a lead point for the intussusception.
GI infection with mucormycosis	Increased risk with advanced COVID-19 infection due to immunosuppression. Associated with high mortality.	Increased risk attributed to high-dose corticosteroid therapy, exposure to mechanical ventilation, and advanced COVID-19 infection.
Collagenous colitis	Significantly higher rate of contracting COVID-19 infection, having severe COVID-19 infection, and of being hospitalized for COVID-19 infection than patients with lymphocytic colitis or controls.	May relate to genetic factors associated with predisposition to developing collagenous colitis such as an extended HLA haplotype or the rs13071258 A variant on genetic locus 3p21.31 associated with collagenous colitis. This genetic locus harbors 6 genes potentially affecting the immune defense against viral infections.
Lymphocytic colitis	Has similar rate of contracting COVID-19 infection and developing severe infection as controls. Lymphocytic colitis should be considered in the differential of watery diarrhea after contracting acute COVID-19 infection.	Unlike collagenous colitis, lymphocytic colitis is not associated with genetic abnormalities affecting host defenses against viruses.
Tocilizumab-associated colonic perforation	Case report of developing terminal ileal and cecal ulcers that caused colonic perforation after initiating tocilizumab therapy for suspected cytokine release syndrome in a patient with COVID-19 infection.	Tocilizumab has previously been associated with lower gastrointestinal perforation and colonic diverticular perforation after its use to treat rheumatoid arthritis.
Acute appendicitis and acute diverticulitis	COVID-19 infection does not affect the frequency of hospitalization, colonic perforation, or surgery from these two diseases.	COVID-19 infection does not appear to affect the natural history of these two diseases.
Irritable bowel syndrome	During pandemic patients with irritable bowel syndrome experienced more severe gastrointestinal symptoms, more severe extra-intestinal symptoms,	Patients likely experience more severe symptoms of irritable bowel syndrome due to anxiety related to the pandemic.

	and more sleep difficulties than before the COVID-19 pandemic.	
Inflammatory bowel disease	COVID-19 infected patients have a worse outcome from inflammatory bowel disease when treated with corticosteroids but not when treated with tumor necrosis factor antagonists.	Corticosteroids may decrease immunologic defenses against COVID-19 infection. Another chapter in this monograph is devoted to COVID-19 infection in patients with inflammatory bowel disease.

ACE-2: angiotensin converting enzyme-2, PPI: proton pump inhibitor, EGD: esophagogastroduodenoscopy, GI: gastrointestinal.

Journal Pre-proof

Table 2. Frequency of performing diagnostic and therapeutic GI tests during the COVID-19 pandemic (extensively reviewed in another chapter in this monograph on gastrointestinal endoscopy during the COVID-19 pandemic)

Test or procedure	Effects associated with COVID-19 pandemic	Postulated mechanism
Esophagogastroduodenoscopy	The frequency of performing EGD during the acute pandemic peak (in March-April 2000) fell dramatically to just a few percent of its baseline rate before the pandemic. The rate has recovered vigorously after March-April 2020 but still is lower than the baseline rate before the pandemic.	EGD is often deferred in patients with mild GI bleeding or other mild symptoms because of patient preference or concerns about transmission of COVID-19 infection to endoscopy suite personnel. EGD should be performed for urgent or emergent indications.
Esophagogastroduodenoscopy for screening/surveillance of Barrett's esophagus and esophageal adenocarcinoma.	Markedly decreased performance of EGDs for these indications during the pandemic.	EGD often deferred or postponed due to these indications for EGD considered a lower priority during pandemic compared to urgent indications for EGD. EGD should be performed urgently or emergently for suspected esophageal cancer.
Computed tomography of chest	Has been used as an alternative diagnostic test for EGD, (e.g., to detect esophageal varices)	CT, however, has limited applicability because it is rarely therapeutic. For example, CT, unlike EGD, cannot be used to band esophageal varices.
Cytosponge device	Recent innovation that permits acquiring esophageal tissue with less procedure time and at lower cost than EGD.	Experimental procedure that may soon provide a substitute for EGD that is less costly and less labor-intensive.
Unsedated nasal endoscopy	Can be used as an alternative to EGD. Does not require a nurse-anesthetist.	Less costly than EGD. Requires less endoscopic resources, less endoscopic personnel, and less procedure time.
Screening and surveillance colonoscopy	Screening colonoscopy declined dramatically during the acute COVID-19 pandemic peak but has gradually recovered somewhat.	Screening colonoscopy is generally contraindicated in patients with acute COVID-19 infection. Screening colonoscopy is often deferred or postponed in favor of more urgent colonoscopy indications even in patients who are not positive for COVID-19 infection.

Other colonoscopy indications	Colonoscopy for emergent or urgent indications usually performed. Colonoscopy may be deferred for elective indications depending upon the indication and local practice patterns.	Colonoscopy may sometimes be deferred for elective indications due to perceived risk of contracting COVID-19 infection during colonoscopy to endoscopy staff or patients.
High-resolution manometry (HRM)	Number performed markedly decreased during pandemic.	Decrease attributed to risks of contracting or transmitting COVID-19 infection during the procedure. Also attributed to patient preference and strict endoscopy suite guidelines for performing procedures during the pandemic.

EGD – esophagogastroduodenoscopy; GI – gastrointestinal.