

Alopecia due to an allergic reaction to metal head-pins used in a neurosurgical operation

Hajime Ono, Hiroshi Takasuna¹, Yuichiro Tanaka¹

Division of Neurosurgery, St. Marianna University School of Medicine, Toyoko Hospital, ¹Division of Neurosurgery, St. Marianna University School of Medicine, Kawasaki, Kanagawa, Japan

E-mail: *Hajime Ono - gen21@marianna-u.ac.jp; Hiroshi Takasuna - hiroxneuro@marianna-u.ac.jp; Yuichiro Tanaka - tanaka@marianna-u.ac.jp

*Corresponding author

Received: 30 July 15 Accepted: 14 October 15 Published: 07 January 16


Abstract

Background: Allergic reactions to the metal head-pins of a head fixation holder are rare.

Case Description: A 45-year-old woman was referred to our hospital for the treatment of unruptured cerebral aneurysms. She underwent successful surgical treatment using four head-pins of the Sugita frame. At her first outpatient visit 3 weeks after discharge, redness, sores, and focal hair loss were noted at all four areas where the pinning had been performed. The pin fixation was considered to be responsible for the alopecia because the condition of the scalp lesions was even in all four parts. Six months later, the scalp regained hair. The head-pins were made of stainless steel, containing iron, nickel, chromium, and other components. A previous history of contact dermatitis to metal jewellery was later proven.

Conclusion: The history of metal allergy should have been carefully elicited because head fixation with head-pins is essential for neurosurgical procedures.

Key Words: Alopecia, complication, head-pin, metal allergy, stainless steel

Access this article online
Website: www.surgicalneurologyint.com
DOI: 10.4103/2152-7806.173557
Quick Response Code: 

INTRODUCTION

An allergic reaction to metal and alopecia caused by head-pins as a complication following neurosurgery is very rare. The Sugita multipurpose head frame system (Sugita frame, Mizuho Medical Co., Ltd., Tokyo, Japan) is safe and widely used in neurosurgery. Recently, head-pins used in the Sugita frame have been available as disposable pins (Dispo-pin[®], Mizuho Medical Co., Ltd., Tokyo, Japan). The material of the Dispo-pin is stainless steel. Stainless steel rarely causes metal allergy, but it is possible that allergic reactions can occur from the chromium (Cr) and nickel (Ni) components. A rare case of allergy to metal head-pins is reported.

CASE HISTORY

A 45-year-old woman was referred to our hospital because of incidentally found unruptured multiple aneurysms

located in the anterior communicating artery (ACoA) and left A2. A neurological examination detected no focal deficits. Clipping surgery was planned, and the three-dimensional computed tomography angiography study on admission demonstrated a 7.0-mm aneurysm of the ACoA and a 2.5-mm aneurysm of the left A2. She underwent clipping surgery with the head placed in a horizontal position using a Sugita frame [Figure 1a] with four head-pins [Figure 1b and c], with a bilateral frontal

This is an open access article distributed under the terms of the Creative Commons Attribution-NonCommercial-ShareAlike 3.0 License, which allows others to remix, tweak, and build upon the work non-commercially, as long as the author is credited and the new creations are licensed under the identical terms.

For reprints contact: reprints@medknow.com

How to cite this article: Ono H, Takasuna H, Tanaka Y. Alopecia due to an allergic reaction to metal head-pins used in a neurosurgical operation. *Surg Neurol Int* 2016;7:S5-7.

<http://surgicalneurologyint.com/Alopecia-due-to-an-allergic-reaction-to-metal-head-pins-used-in-a-neurosurgical-operation/>

craniotomy. An anterior interhemispheric approach was used. An aneurysm was successfully clipped using a titanium Sugita aneurysmal clip (Mizuho Medical Co., Ltd., Tokyo, Japan) without complications. The patient recovered well after surgery and was able to resume her usual activities without neurological deficits. However, redness and itching of her scalp in the four areas of the head-pins were noted at the time of the first outpatient visit after discharge, and redness and hair loss were observed 3 weeks after surgery [Figure 2].

There was no description of a metal allergy in her record. Therefore, a careful allergy history was taken and revealed a strong skin reaction to the metal of accessories and clothes. A patch test was recommended, but the patient refused consent. After consultation with a dermatologist, treatment with a corticosteroid ointment was given. Six months after the surgery, the redness and sores had improved with regrowth of hair [Figure 3].

DISCUSSION

Metal is essential to our daily life and is used in many products.^[1] However, cobalt, nickel, chromium, and mercury are prone to cause metal allergy. Nearly 10% of the general population experiences nickel dermatitis.^[11]

Metal allergies have been reported in a wide range of surgical cases from orthopaedics^[7] to dermatology.^[5] Rates have ranged as high as 28% in the orthopedic literature for early studies of metal-on-metal hip replacement.^[2] In addition, metal allergy to a stainless steel injection needle has been reported by Urushibata *et al.*^[10]

In the neurosurgical literature related to clipping, metal allergies were reported in three cases after placement of a cobalt-nickel alloy clip.^[4,6,8] In a case of reversible intracranial parenchymal changes after treatment with stent-assisted coiling, the authors reported the possibility of nickel allergy to the stent.^[9] For a metal allergy to occur, the presence of metal ions is needed.^[5] Ionization can occur even in a medical instrument. Stainless steel is an alloy mainly composed of iron (Fe), chromium, nickel, manganese, and others.^[1] Since stainless steel has been previously considered to never rust, it was thought that metal allergy does not occur. However, in recent years, it has become clear that stainless steel becomes easily ionized in saline.

The Sugita frame has been widely used in neurosurgery because it is safe and effective for microscopic procedures.^[3] The head-pins of the Sugita frame are now disposable pins made of stainless steel; the chemical component is SUS316L. SUS316L is a material made of 18Cr-12Ni-2.5Mo-low C type: 65–69% iron, 16–18% chromium, 10–12% nickel, 2–3% molybdenum (Mo), and ≤0.08% carbon (C).

Mayfield head-pins (Ohio Medical Instrument Company, Inc., Cincinnati, OH, USA) are also often used for head fixation in Japan, but the disposable Mayfield head-pin is also stainless steel made of SUS630. SUS630 consists of 17Cr-4Ni-4Cu-Nb-low C type: 71–77% Fe, 15–17% Cr, 3–5% Ni, 3–5% copper (Cu), 0.15–0.45% niobium (Nb), and ≤0.07% C. Metal allergy is also possible even with the Mayfield head-pin.

The diagnosis of a metal allergy includes an examination of the skin for a rash and sores. By screening for patients who

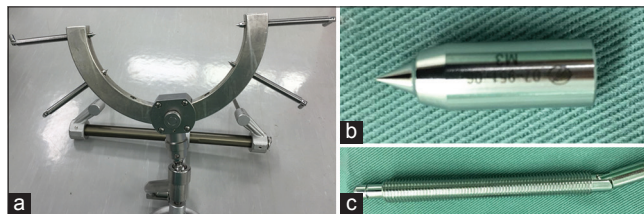


Figure 1: The patient's head is held in the center of the Sugita head holder (a) using four metal pins. The Dispo-pin® (b) is separated from the shaft (c)

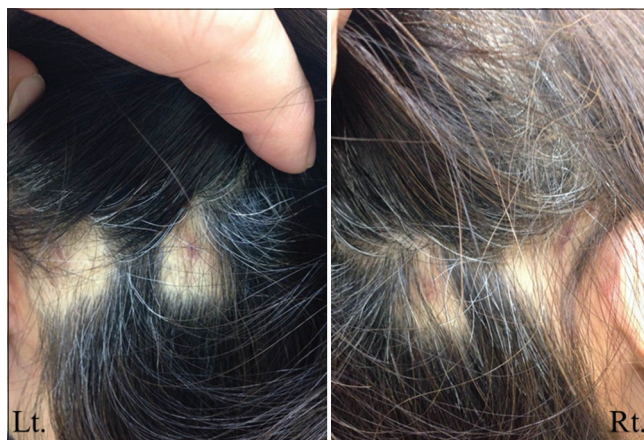


Figure 2: The scalp 3 weeks after surgery, showing the focal hair loss and redness at the sites corresponding to the pinning

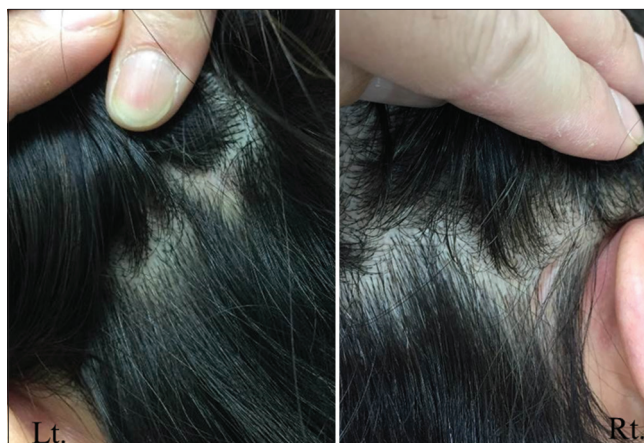

Figure 3: The scalp 6 months after surgery showing improvement of redness and regrowth of hair

previously had a reaction (e.g., after wearing some jewellery), the diagnosis can be confirmed with a positive patch test.

In the present case, although the patient's consent was not obtained, the manufacturer (Mizuho Medical Co., Ltd., Tokyo, Japan) of the head-pin prepared for a patch test. Medical management of the metal allergy includes both corticosteroids ointment and antihistamines. It is important to check for a history of metal allergy before surgical treatment, as many metals are present in the equipment used in neurosurgery.

Financial support and sponsorship

Nil.

Conflicts of interest

There are no conflicts of interest.

REFERENCES

1. Adachi A. The diagnosis of metal contact allergy and systematic metal allergy. *J Environ Dermatol Cutan Allergol* 2011;5:1-10.
2. Benson MK, Goodwin PG, Brostoff J. Metal sensitivity in patients with joint replacement arthroplasties. *Br Med J* 1975;4:374-5.
3. Goto T, Hongo K. Difference between conventional head-pin and dispo-pin in the sugita multipurpose head frame system. *Neurol Med Chir (Tokyo)* 2013;53:21-5.
4. Grande A, Grewal S, Tackla R, Ringer AJ. Life-threatening allergic vasculitis after clipping an unruptured aneurysm: Case report, weighing the risk of nickel allergy. *Surg Neurol Int* 2014;5 Suppl 4:S161-4.
5. Kase K. A case study of contact dermatitis induced by steel. *Toho Igakkai Zasshi* 1995;42:269-78.
6. Ross IB, Warrington RJ, Halliday WC. Cell-mediated allergy to a cerebral aneurysm clip: Case report. *Neurosurgery* 1998;43:1209-11.
7. Shishido M, Orui T, Fujita M, Shinkai H, Ebata T, Imai K. A case of contact dermatitis due to orthopedic metal implant. *Jpn J Dermatol Allergol* 1996;4:61-6.
8. Tan T, Tee JW, Han TF. Cell-mediated allergy to cerebral aneurysm clip causing extensive cerebral edema. *J Neurosurg* 2014;121:924-8.
9. Ulus S, Yakupoglu A, Kararslan E, Islak C, Siva A, Koçer N. Reversible intracranial parenchymal changes in MRI after MCA aneurysm treatment with stent-assisted coiling technique; possible nickel allergy. *Neuroradiology* 2012;54:897-9.
10. Urushibata O, Kase K, Makino A, Saito R. Contact dermatitis caused by injection needle. *Jpn J Dermatol Allergol* 1993;1:60-3.
11. Usatine RP, Riojas M. Diagnosis and management of contact dermatitis. *Am Fam Physician* 2010;82:249-55.