

Congenital anal atresia with rectovestibular fistula, scoliosis, unilateral renal agenesis, and finger defect (VACTERL association) in a patient with partial bicornuate uterus and distal vaginal atresia

A case report

Jia Kang, MD, Meng Mao, MD, Ye Zhang, MD, Fang-Fang Ai, MD, Lan Zhu, MD*

Abstract

Rationale: Vertebral defect, anal atresia, cardiac defect, tracheoesophageal fistula/esophageal atresia, renal defect, and limb defect (VACTERL) association and Müllerian duct anomalies are rare conditions. We present a rare condition with the co-occurrence of the VACTERL association and Müllerian duct hypoplasia to characterize patients' clinical presentations, outcomes, and treatment.

Patient concerns: An 11-year-old girl presented to our hospital with severe lower abdominal pain, lower vaginal atresia with enlargement of the upper vagina and a bicornuate uterus with a Y-shaped uterine cavity filled with hematometra on pelvic magnetic resonance imaging. Her medical history included congenital anal atresia with a rectovestibular fistula, congenital right renal deficiency, congenital right thumb malformation, and scoliosis.

Diagnoses: 1. Congenital genital tract malformations, a partial bicornuate uterus, and distal vaginal atresia (U3_aC0V4); 2. VACTERL association (congenital anal atresia with rectovestibular fistula, scoliosis with hemi vertebra and butterfly vertebra, unilateral renal agenesis, and finger defect).

Interventions: Colpotomy, laparoscopic exploration, pelvic adhesiolysis, and hysteroscopy were performed.

Outcomes: Two months after surgery, a pelvic examination showed an unobstructed vagina which was 10 cm long and 2 fingers wide, without adhesion or constriction.

Lessons: Clinicians should have a high index of suspicion when evaluating patients with genital malformations associated with VACTERL. Early diagnosis of distal vaginal atresia with appropriate surgical intervention decreases long-term morbidity.

Abbreviations: OMIM = Online Mendelian Inheritance in Man, VACTERL = vertebral anomalies, anal atresia, cardiac malformations, tracheoesophageal fistula, renal dysplasia, and limb abnormalities.

Keywords: distal vaginal atresia, müllerian duct abnormality, rare diseases, VACTERL association

1. Introduction

Müllerian duct anomalies are congenital anomalies of the female genital tract resulting from non-development or non-fusion of the Müllerian ducts, or failed resorption of the uterine and/or vaginal septum.^[1] A bicornuate uterus is defined as a uterus with an

abnormal fundal outline and is characterized by the presence of an external indentation at the fundal midline exceeding 50% of the uterine wall thickness.^[2] A bicornuate uterus results from the incomplete fusion of the Müllerian ducts in a local area or throughout their normal line of fusion and accounts for 39% of uterine anomalies.^[3] Vaginal atresia is a type of rare malformation of the Müllerian ducts. Complete or partial failure of the vaginal plate to canalize results in vaginal agenesis. Vaginal agenesis may be distal to a normal uterus, cervix, and upper vagina or near total/complete with associated degrees of Müllerian aplasia. The prevalence of vaginal atresia has been estimated to be 1/10,000 to 1/4000—of live female births.^[4] Females typically present to the hospital during early puberty due to primary amenorrhea and periodic abdominal pain. However, other complaints include dyspareunia. We have classified vaginal atresia into 2 types based on the surgical findings. Type I is characterized by distal vaginal atresia with normal uterus, cervix, and upper vagina and type II is associated with total vaginal absence and cervical aplasia, normally with an anatomically normal corpus. The cause(s) of vaginal atresia remains unknown. Because vaginal atresia is a type of genital obstruction, surgery is needed to drainage menstrual blood and create a new vagina to allow sexual intercourse.

Editor: N/A.

The authors have no conflicts of interest to disclose.

Department of Obstetrics and Gynecology, Peking Union Medical College Hospital, Peking Union Medical College, Chinese Academy of Medical Sciences, Beijing, P. R. of China.

*Correspondence: Lan Zhu, Department of Obstetrics and Gynecology, Peking Union Medical College Hospital, No. 1 Shuaifu Road, Dongcheng District, Beijing, China, 100730 (e-mail: zhu_julie@vip.sina.com)

Copyright © 2018 the Author(s). Published by Wolters Kluwer Health, Inc. This is an open access article distributed under the terms of the Creative Commons Attribution-Non Commercial License 4.0 (CCBY-NC), where it is permissible to download, share, remix, transform, and buildup the work provided it is properly cited. The work cannot be used commercially without permission from the journal.

Medicine (2018) 97:45(e12822)

Received: 22 June 2018 / Accepted: 20 September 2018

<http://dx.doi.org/10.1097/MD.00000000000012822>

Vertebral anomalies, anal atresia, cardiac malformations, tracheoesophageal fistula, renal dysplasia, and limb abnormalities (VACTERL) association (Online Mendelian Inheritance in Man [OMIM] 192350) is a condition characterized by multisystem congenital malformations that result in severe physical disability in affected individuals. It is typically defined by the concurrence of at least 3 of the following component features: VACTERL.^[5] The incidence is estimated to be 0.3 to 2.1 per 10,000 live births.^[6] It is typically a sporadic occurrence, though rare cases of familial inheritance have also been reported in the literature.^[7] The etiology is thought to be embryologically related.^[8] Management usually depends on correcting specific congenital anomalies immediately after birth, followed by long-term medical management of any sequelae resulting from the congenital malformations. Although genital defects—are not the major defect of VACTERL association, in a study by Botto et al of 286 infants with Vertebral anomalies, anal atresia, tracheoesophageal fistula, renal dysplasia, and limb abnormalities (VATERL) association, 81 (28.3%) had severe genital defects.^[5]

Here we report a rare case of co-occurrence of VACTERL association (congenital anal atresia with a rectovestibular fistula, scoliosis with butterfly vertebra and hemivertebrae, unilateral renal agenesis, and finger defect) with a partial bicornuate uterus and distal vaginal atresia in a patient who presented to our surgical center. Reporting cases of rare conditions are important to expand our knowledge of possible etiological factors, treatment, and outcomes. Our case presentation is combined with a review of the literature in which we have identified cases of VACTERL association coexisting with female genital malformation to characterize patients' clinical presentations, outcomes, and treatment.

2. Case report

An 11-year-old female, with no history of menstruation, presented to our hospital with severe lower abdominal pain, of 5 days duration. She had no complaints of headache, fever, nausea, or shifting pain. Her medical history was significant for congenital anal atresia, rectovestibular fistula, congenital right thumb malformation, and scoliosis. She was a student with a formal education and had never sexual contact. Her mother denied any history of radioactive, toxic substance, or drugs

exposures during her pregnancy. Excision to correct the congenital anal atresia and repair of the rectovestibular fistula were performed when the patient was 7 days old. Surgical correction was performed due to a right thumb malformation when she was 5 years old.

On physical examination, the patient was of small stature, with normal hearing, and normal mental status. Her breast development was consistent with Tanner stage II. Pelvic clinical examination revealed sparse pubic hair and a vaginal dimple, but a blind-ended vagina. On transanal examination, a 7 cm tender cystic mass was palpated anterior to the anus.

Transabdominal ultrasound and magnetic resonance imaging (MRI) revealed lower vaginal atresia with an enlarged upper vagina (70*42*32mm) caused by hematocolpos. A bicornuate uterus was identified with a Y-shaped uterine cavity with hematometra (Fig. 1). No pelvic mass or pelvic effusion was found. Skeletal abnormalities, renal defect and heart defect were also noted. Karyotype analysis was performed, and CA-125 and sex hormones were also evaluated. A plain film X-ray showed scoliosis with butterfly vertebra and hemivertebrae (Fig. 2). A transabdominal ultrasound identified a normal left kidney and an absent right kidney. An ultrasonic cardiogram did not identify any heart defect. The karyotype analysis result was 46, XX. Sex hormones were within a normal range, and CA-125 was higher than the upper limit (130.9U/mL).

Transvaginal colpotomy and laparoscopic exploration, pelvic adhesiolysis and hysteroscopy were performed. Laparoscopy conformed a bicornuate uterus to a broad fundus and adhesions in the pouch of Douglas and uterosacral ligament (Fig. 3). Fortunately, both ovaries and fallopian tubes were normal. Pelvic adhesiolysis was performed followed by colpotomy. We placed the left index into the anus as a guide and cut the obstructed vagina using an electric knife. Careful blunt dissection was conducted superiorly, taking precautions to avoid the urethra/bladder and rectum. Then, we used a wide-bore needle to puncture the hematocolpos. The incision was extended with a sharp knife. Once the upper vagina was reached and the hematocolpos drained, the incisional edges were approximated with interrupted sutures. Afterwards, a hysteroscopy was performed that identified a broad cavity with distinct bilateral oviduct openings. A soft mold was placed in the vagina and the labia were

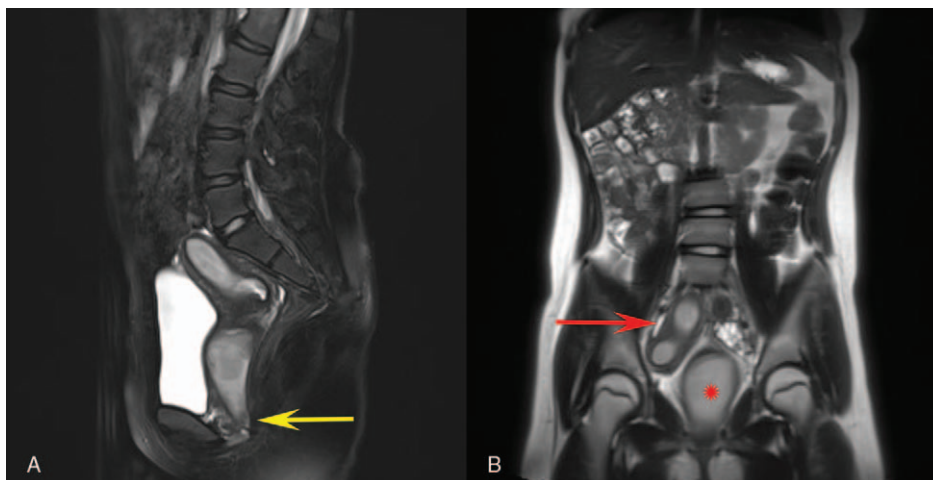


Figure 1. Magnetic resonance imaging scan showing (A) distal vaginal atresia (yellow arrow) and (B) a dilated upper vagina due to hematocolpos (red asterisk) with a bicornuate uterus with 2 horns (red arrow).

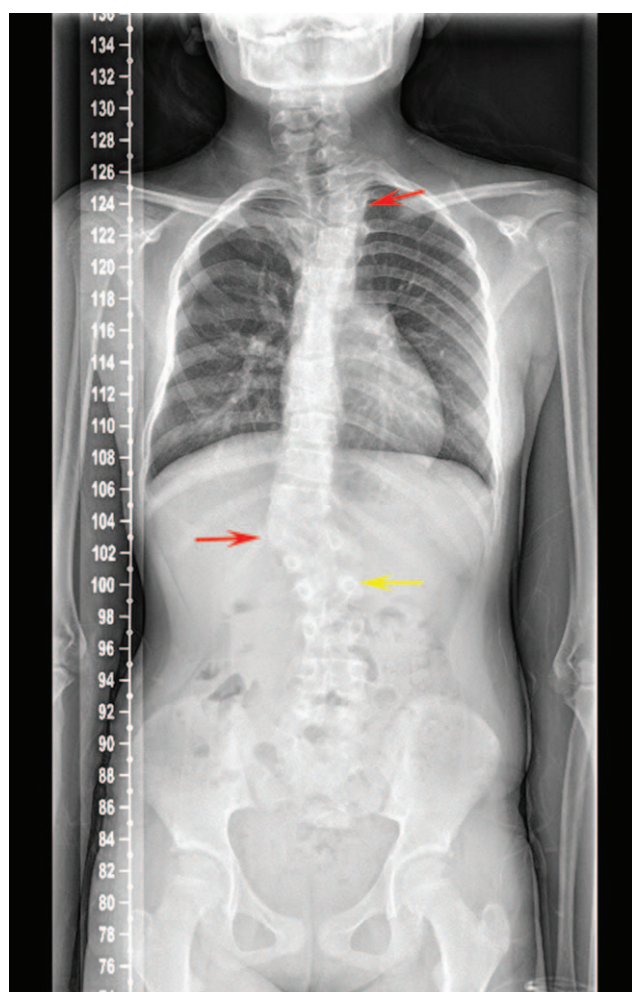


Figure 2. A plain film X-ray revealed scoliosis with butterfly vertebra (yellow arrow) and hemivertebrae (red arrow).

reapproximated using a discontinuous suture to secure the mold. The operation was smooth and uneventful with duration of 30 minutes. The amount of intraoperative blood loss was approximately 30mL. On the third post-operative day, labial stitches were removed, and the soft mold was replaced by a firm mold.

The patient was instructed to dilate the vagina twice a day for 20 minutes, using a mold each time. Two months after surgery, pelvic examination showed an unobstructed vagina which was 10 cm long and 2 fingers wide, without adhesion or constriction.

Ethical approval was not required for this case report. Informed written consent was obtained from the patient for publication of this case report and accompanying images.

3. Discussion

The multisystem congenital malformations described above, including congenital anal atresia with recto-scapoid fossa fistula, scoliosis, unilateral renal agenesis, and finger defect, are consistent with VACTERL association, without the cardiac malformations and tracheo-esophageal fistula.

VACTERL association has previously been reported to coexist with female genital malformation. Solomon BD reported 9 female patients with genitourinary anomalies among 89 VACTERL patients. Among the 9 patients, 5 had cloacal anomalies with 1

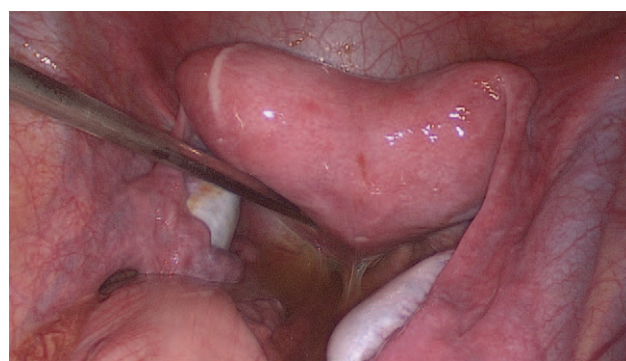

Figure 3. Laparoscopy confirmed the bicornuate uterus with a broad fundus and adhesions in the pouch of Douglas and uterosacral ligament.

duplex vagina and 1 genital absence, 2 had a rectovestibular fistula, 1 had a perineal fistula, and 1 had uterus didelphys. Genitourinary anomalies were more common in patients with VACTERL association with anorectal atresia and renal anomalies and less common in patients with esophageal atresia and preaxial limb anomalies.^[9] Bjorsum-Meyer et al reported 2 cases of a co-occurrence of Mayer-Rokitansky-Küster-Hauser syndrome and vertebral defect, anal atresia, cardiac defect, tracheoesophageal fistula/esophageal atresia, renal defect, and limb defect association.^[10] Vaginal atresia with VACTERL association has not been reported. To our knowledge, this is the first case report of coexisting VACTERL association with distal vaginal atresia and a partial bicornuate uterus.

As the normal developmental biology is still being elucidated, the coexisting of VACTERL association and genitourinary anomalies can only be hypothetically ascribed to embryonal dysplasia. The precise positions and sizes of the urogenital and anorectal structures are thought to be determined by a process termed “transformation”, wherein the caudal end of the embryo expands and rotates, and the cloacal structures are incorporated into the contour of the embryo. Because the spinal cord and the musculoskeletal system also participate in the process of transformation, it is conceivable that anomalies affecting the vertebral, anal, and genitourinary systems may occur concurrently if transformation is dysregulated.^[9]

Establishing a diagnosis of distal vaginal atresia, bicornuate uterus, or VACTERL association is not difficult.^[4] However, imperforate hymen, transverse septa, and distal vaginal agenesis also similarly present with pain and hematocolpos and may also appear the same on examination. Therefore, imaging should be used to better differentiate the anomaly. In addition, only a vaginal dimple may be visualized on examination of the genitalia in patients with vaginal distal atresia.

Treatment of vaginal atresia becomes necessary at puberty because the genital tract becomes painfully distended during each menstruation. Colpotomy is usually performed to drain the menstrual blood and to facilitate sexual intercourse, with the preservation of reproductive potential. Hurst and Rock^[11] advocated an alternative approach that involved delaying surgical repair by using needle aspirated drainage, continuous oral contraceptives to suppress the reaccumulation of hematocolpos, and vaginal dilation to lengthen the lower vaginal segment. Rebacca et al reported the use of vaginal pull-through for lower vaginal agenesis. They advised use of intraoperative ultrasound to determine the appropriate angle of dissection in the presence of a unicornuate system.^[12] Regarding the timing of

surgical correction, we advise that the surgery should be performed during menstruation when a large hematocolpos has formed, which acts as a natural tissue expander. Careful blunt dissection should be conducted superiorly, taking precautions to avoid the urethra/bladder and rectum, followed by puncture, excision, dilation, drainage, and trimming. Then, a soft mold should be inserted into the vagina to avoid postoperative adhesions. After surgery, regular dilation of the vagina is necessary until the patient engages in regular sexual activity to avoid the development of adhesion, strictures or reobstruction.

This case demonstrates that patients with female genital malformations may have VACTERL association. Publication of additional case reports and case series in the future would further expand our knowledge about this phenomenon.

4. Conclusion

Given the findings in this study and similar findings in previous studies, clinicians should have a high index of suspicion for females who present with genital malformations and VACTERL association. Early diagnosis of distal vaginal atresia with appropriate surgical intervention decreases long-term morbidity. Untreated patients develop retrograde tubal reflux and endometriosis, which may lead to impaired fertility and other obstetric complications later in life.

Author contributions

Formal analysis: Jia Kang, Ye Zhang.

Investigation: Meng Mao.

Supervision: Lan Zhu.

Writing – original draft: Jia Kang.

Writing – review & editing: Fang Fang Ai.

References

- [1] Golan A, Langer R, Bukovsky I, et al. Congenital anomalies of the mullerian system. *Fertil Steril* 1989;51:747–55.
- [2] Grimbizis GF, Gordts S, Di Spiezio Sardo A, et al. The ESHRE/ESGE consensus on the classification of female genital tract congenital anomalies. *Hum Reprod* 2013;28:2032–44.
- [3] Nahum GG. Uterine anomalies. How common are they, and what is their distribution among subtypes. *J Reprod Med* 1998;43:877–87.
- [4] Committee on Adolescent Health CACOG Committee Opinion No. 728: Mullerian Agenesis: Diagnosis, Management, and Treatment. *Obstet Gynecol* 2018;131:e35–42.
- [5] Botto LD, Khoury MJ, Mastroiacovo P, et al. The spectrum of congenital anomalies of the VATER association: an international study. *Am J Med Genet* 1997;71:8–15.
- [6] Solomon BD. VACTERL/VATER association. *Orphanet J Rare Dis* 2011;6:56.
- [7] Hilger A, Schramm C, Draaken M, et al. Familial occurrence of the VATER/VACTERL association. *Pediatr Surg Int* 2012;28:725–9.
- [8] Padma S, Sundaram PS, Sonik B. A case of VACTERL and non-VACTERL association without the “V and L”. *Indian J Nucl Med* 2014;29:46–9.
- [9] Solomon BD, Raam MS, Pineda-Alvarez DE. Analysis of genitourinary anomalies in patients with VACTERL (vertebral anomalies, anal atresia, cardiac malformations, tracheo-esophageal fistula, renal anomalies, limb abnormalities) association. *Congenit Anom (Kyoto)* 2011;51:87–91.
- [10] Bjorsum-Meyer T, Herlin M, Qvist N, et al. Vertebral defect, anal atresia, cardiac defect, tracheoesophageal fistula/esophageal atresia, renal defect, and limb defect association with Mayer-Rokitansky-Kuster-Hauser syndrome in co-occurrence: two case reports and a review of the literature. *J Med Case Rep* 2016;10:374.
- [11] Hurst BS, Rock JA. Preoperative dilatation to facilitate repair of the high transverse vaginal septum. *Fertil Steril* 1992;57:1351–3.
- [12] Jessel RH, Laufer MR. Management of lower vaginal agenesis in a patient with unicornuate uterus. *J Pediatr Adolesc Gynecol* 2013;26:e21–23.