



Case report

Atypical presentation of neuronal ceroid lipofuscinosis type 8 in a sibling pair and review of the eye findings and neurological features



Rossana L. Sanchez ^a, Jiong Yan ^b, Sarah Richards ^a, Gary Mierau ^c, Eric P. Wartchow ^c,
Christin D. Collins ^a, Suma P. Shankar ^{a, b, *}

^a Department of Human Genetics, Emory University School of Medicine, 615 Michael Street, Suite 301, Atlanta, GA 30322, USA

^b Department of Ophthalmology, Emory University School of Medicine, 615 Michael Street, Suite 301, Atlanta, GA 30322, USA

^c Department of Pathology, Children's Hospital Colorado, 13123, E 16th Ave, Aurora, CO, USA

ARTICLE INFO

Article history:

Received 3 February 2016

Received in revised form

8 July 2016

Accepted 25 July 2016

Available online 27 August 2016

Keywords:

Chromosome microarray

Epilepsy

Lysosomal storage disorder

Neuronal ceroid lipofuscinosis

Next generation sequencing panel

Vision loss

ABSTRACT

Purpose: To report atypical presentation of neuronal ceroid lipofuscinoses type 8 (CLN8) to the eye clinic and review clinical features of CLN8.

Observations: Detailed eye exam by slit lamp exam, indirect ophthalmoscopy, fundus photography, optical coherence tomography, visual fields and electroretinogram (ERG). Molecular genetic testing using Next Generation Sequencing panel (NGS) and array Comparative Genomic Hybridization (aCGH).

The siblings in this study presented to the eye clinic with retinitis pigmentosa and cystoid macular edema, and a history of seizures but no severe neurocognitive deficits or regression. Genetic testing identified a c.200C > T (p.A67V) variant in the *CLN8* gene and a deletion encompassing the entire gene. Electron microscopy of lymphocytes revealed fingerprint inclusions in both siblings.

Conclusions and Importance: Pathogenic variants in *CLN8* account for the retinitis pigmentosa and seizures in our patients however, currently, they do not have regression or neurocognitive decline. The presentation of NCL can be very diverse and it is important for ophthalmologists to consider this in the differential diagnosis of retinal disorders with seizures or other neurological features. Molecular genetic testing of multiple genes causing isolated and syndromic eye disorders using NGS panels and aCGH along with additional complementary testing may often be required to arrive at a definitive diagnosis.

© 2016 The Authors. Published by Elsevier Inc. This is an open access article under the CC BY-NC-ND license (<http://creativecommons.org/licenses/by-nc-nd/4.0/>).

1. Introduction

Neuronal ceroid lipofuscinoses (NCL) are a heterogeneous group of neurodegenerative disorders characterized by lysosomal accumulation of autofluorescent material in multiple tissues. Clinical features include developmental delay or regression, seizures, abnormal movements, impaired vision and premature death^{1–4}. NCL is classified as infantile, late-infantile, juvenile and adult forms based on age of onset and progression of disease^{5,6}. The juvenile form (Batten disease) caused by *CLN3* is the most common and often present to eye clinic with vision problems^{6,7}. We report two siblings with a protracted presentation of NCL caused by mutations in *CLN8* gene confirmed by electron microscopy (EM).

2. Findings

2.1. Case 1

A 14-year-old Hispanic female presented to eye clinic with decreased central vision for one year. She had well-controlled generalized tonic-clonic seizures since 7 years of age and bilateral postaxial polydactyly, but no history of motor or cognitive decline. However, she had formal psychoeducational evaluation during 3rd grade and was diagnosed as having ADHD. She is currently on treatment with Ritalin. She has completed 10th grade with tutoring in math and chemistry. She also requires extra time to perform written tests due to her ADHD. Family history revealed a 22-year-old brother with RP and seizures, an unaffected brother, and a mother with a history of postaxial polydactyly.

Her visual acuity was 20/40 OU, color vision was normal, fundus exam showed macular cystoid macular edema OU, and spectral domain optical coherence tomography demonstrated macular

* Corresponding author. Department of Human Genetics, Emory University School of Medicine, 615 Michael Street, Suite 301, Atlanta, GA 30322, USA.

E-mail address: suma.shankar@emory.edu (S.P. Shankar).

cystic change and diffuse macular schisis involving the outer nuclear and the outer plexiform layers. The schisis is an unusual finding (Fig. 1).

Full field ERG revealed severe rod dysfunction and milder cone dysfunction. Goldmann visual field revealed large central scotoma bilaterally (Fig. 1). The rest of the physical and neurologic exam as well as MRI of brain were normal.

Given the history of seizures and vision loss, she was referred for genetic evaluation. Genetic testing was pursued via a comprehensive NGS Eye Panel including genes causing CLNs. It revealed a hemizygous variant of unknown significance (VUS) c.200C > T (p.A67V) in the *CLN8* gene. A search in Exome Aggregation Consortium (ExAC) revealed that this variant is very rare with an allele frequency = 0.00003296 and did not report any homozygotes. Further, deletion/duplication analysis showed a heterozygous deletion in 8p23.3 encompassing the entire *CLN8* gene. Parental testing revealed that these variants were in *trans*; mother carried the deletion and the father carried the c.200C > T (p.A67V) missense VUS. EM of lymphocytes was performed and showed fingerprint like inclusions consistent with NCL (Fig. 2).

2.2. Case 2

This patient is a 22-year-old Hispanic male, brother of case 1, followed in ophthalmology clinic due to decreased night vision since age 5 years. He developed tonic-clonic seizures, well controlled by medication at 16 years of age. He did not require special help during school nor had a formal psychoeducational testing. He has a master's degree in engineering and is in a full time job living independently. At 22 years of age, his visual acuity was OD 20/25 and OS 20/30. His fundus exam revealed pallor of optic nerves, attenuated vasculature, peripheral bone spicules and diffuse retinal pigment epithelial mottling but no cystoid macular edema or schisis (Fig. 3). His full field ERG showed markedly attenuated rod and cone photoreceptor system function bilaterally. Humphrey's visual fields revealed generalized constriction as well as large peripheral scotomas (Fig. 3). OCT was not performed. At time of initial assessment, he was diagnosed with retinitis pigmentosa, likely autosomal recessive. He was followed annually and had a stable course. Given sister's presentation and molecular results, he had targeted genetic testing that revealed the same VUS,

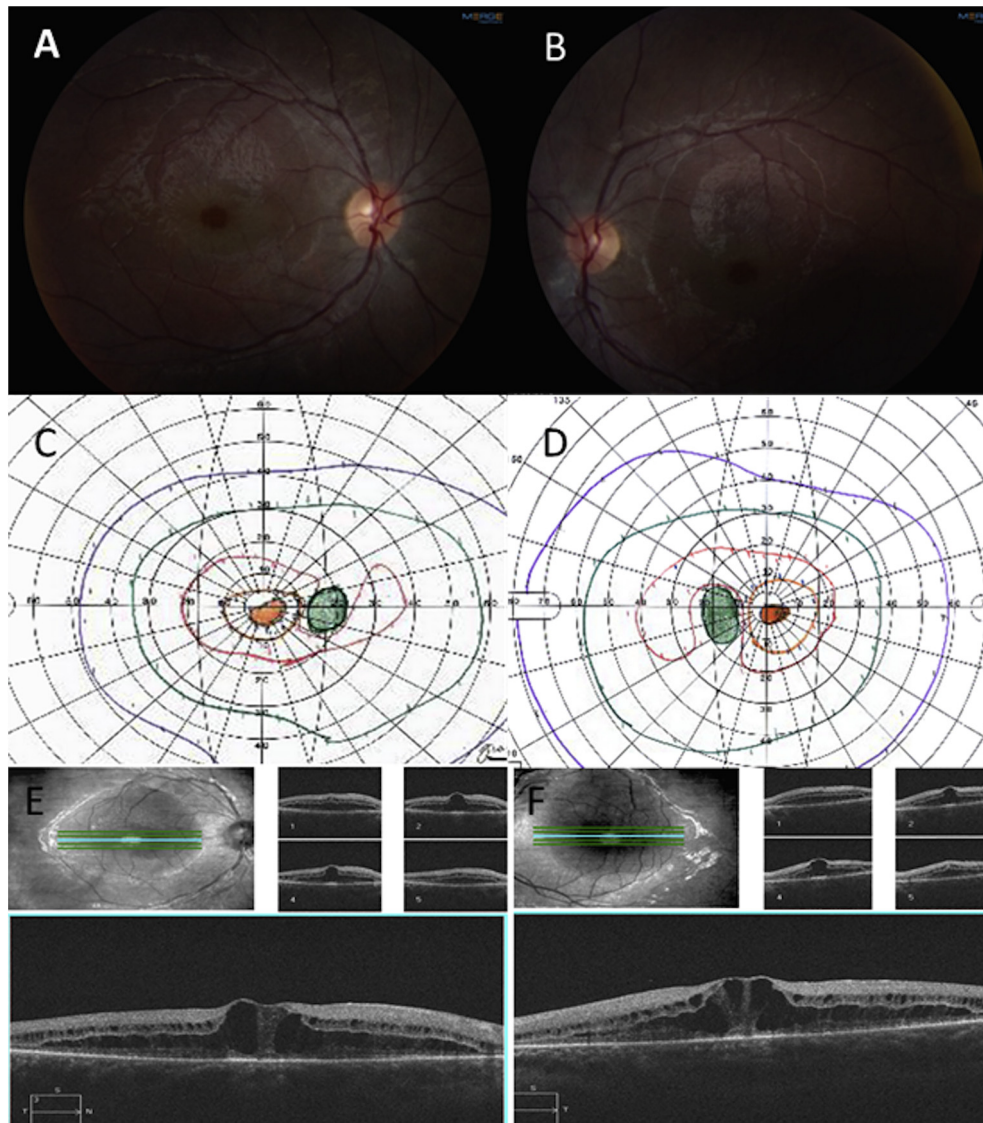


Fig. 1. Case 1, Fundus photos showing healthy appearing optic discs, mild arteriolar attenuation and cystoid macular edema. (A, B), Goldmann Visual Field—showing bilateral central scotomas (C, D), Optical coherence tomography demonstrating cystoid macular edema and diffuse macular schisis involving the outer nuclear and outer plexiform layers of the retina (E, F).

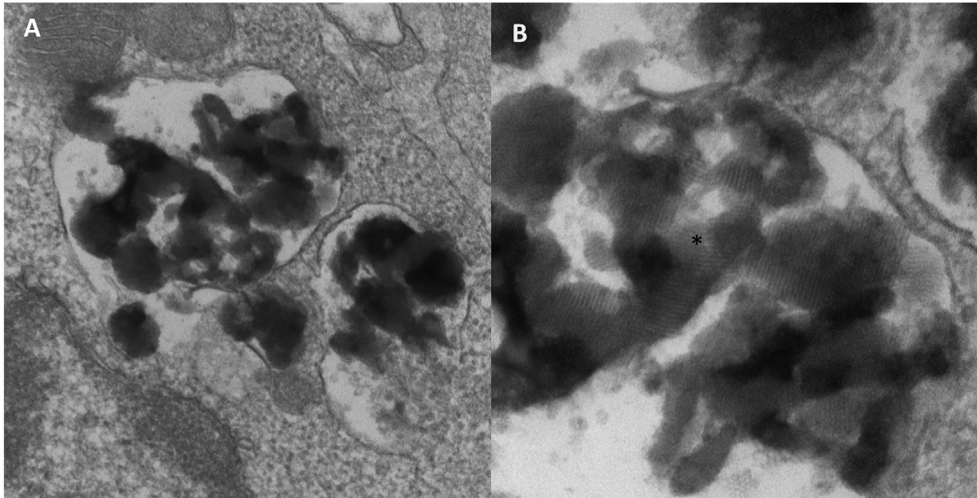


Fig. 2. Case 1, Electron microscopy of lymphocytes from Case 1 showing intracytoplasmic inclusions (A). Fingerprint like inclusions seen in high resolution (B).

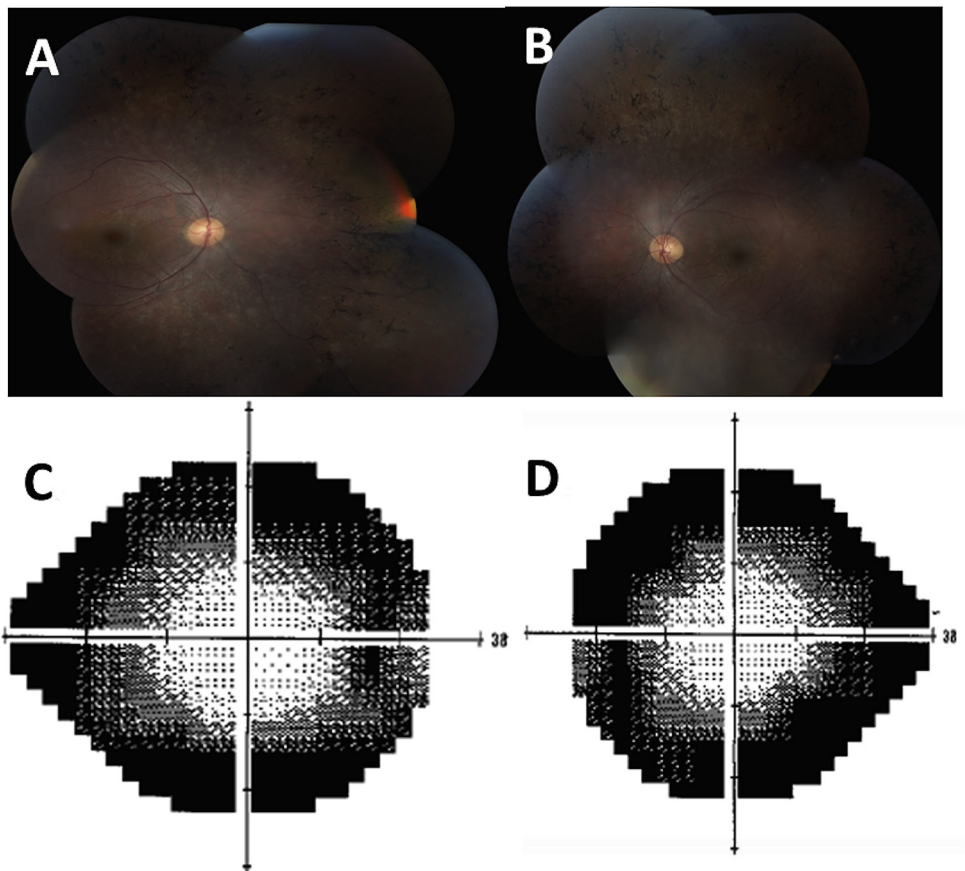


Fig. 3. Case 2, Fundus photos showing pallor of optic nerves, attenuated vasculature, peripheral bone spicules and diffuse retinal pigment epithelial modeling (A, B). Humphrey visual field showing peripheral scotomas (C, D).

c.200C > T (p.A67V), as well as the heterozygous deletion of the *CLN8* gene and positive EM test suggesting that they have the same condition.

3. Discussion

Pathogenic variants in the *CLN8* gene cause two distinct allelic diseases, a progressive epilepsy with mental retardation (EPMR,

OMIM #610003), and a more severe variant late infantile form (CLN-8, OMIM #600143). EPMR is common in Finnish populations, presents at 5–10 years of age with seizures and cognitive decline but usually no vision loss⁸.

The variant late infantile form of NCL is common in Turkish and Italian populations^{9–12} presenting around 3–7 years of age with motor decline, severe epilepsy and severe vision loss^{6,9,10}. We compare the variation in the clinical presentation of our patients

with other previously reported individuals with CLN8 in the [Supplementary table](#) ^{6,7,11–15}. Other common findings reported include dystonia, ataxia and other pyramidal signs. Life expectancy of variant late infantile CLN8 is between ages 6 and adolescence. However, our patients are currently 15 and 23 years of age and have no developmental delays, cognitive decline or psychomotor symptoms.

Missense variants and haploinsufficiency have been previously reported but with a more severe phenotype than our patients ^{5,6,12,15,16}. It is possible that the novel missense variant, c.200C > T (p.A67V) in the *CLN8* gene in our family results in a milder disease. This a very rare allele with a frequency of 0.00003296 in ExAC database ¹⁷. We also report the finding of macular schisis involving the outer nuclear and plexiform layers for the first time in an individual with *CLN8* gene mutations.

Our proband and her mother also had finding of post-axial polydactyly. Non-syndromic post-axial polydactyly is usually inherited in an autosomal dominant manner and has a prevalence of 1.6–10.7 in 1000 ¹⁸. We believe this was an isolated finding and that it is not associated with our patients' diagnosis of CLN8. Our patients did not exhibit other signs of Bardet-Biedl syndrome or other ciliopathies. Moreover, the next generation sequencing panel assessed in our patients included many ciliopathy genes and we did not find any pathogenic variants in these genes.

4. Conclusions

In individuals presenting with retinal degenerative conditions, history of additional clinical features such as seizures, polydactyly or developmental delays should prompt evaluation of systemic disorders such as NCL or ciliopathies. The individuals presented here demonstrate extensive variability in clinical presentation, rate of progression and age of onset and have a milder disease. It is possible that they may develop neurocognitive decline at a later date. Testing of multiple genes by NGS panels with reflex to deletion/duplication analysis aid in more accurate diagnoses and additional investigations such as EM of leukocytes help to resolve the uncertainty of VUS. Our patients increase the phenotypic spectrum of neuronal ceroid lipofuscinoses type 8.

Patient consent

The patients provided written consent for publication of personal information including medical record details and photographs.

Acknowledgements

We are grateful to the family for allowing us to present their findings. Emory, Department of Ophthalmology is supported by unrestricted RPB grant P30EY006360.

Appendix A. Supplementary data

Supplementary data related to this article can be found at <http://dx.doi.org/10.1016/j.ajoc.2016.07.005>.

Conflict of interest

Suma P Shankar is medical director for Emory Genetics Laboratory; Christin Collins is Laboratory director for Emory Genetics Laboratory. The following authors have nothing to declare: Rossana Sanchez, Jiong Yan, Sarah Richards, Gary Mierau, Eric Wartchow.

References

- Mole SE, Williams RE, Goebel HH. *The Neuronal Ceroid Lipofuscinoses (Batten Disease)*. 2ed. Oxford: UKL Oxford University Press; 2011.
- Santavuori P. Neuronal ceroid-lipofuscinoses in childhood. *Brain Dev.* 1998;10: 80–83.
- Anderson Glenn W, Goebel Hans H, Simonati Alessandro. Human pathology in NCL. *Biochimica Biophysica Acta.* 2013;1832:1807.
- Kousi M, Lehesjoki AE, Mole SE. Update of the mutation spectrum and clinical correlations of over 360 mutations in eight genes that underlie the neuronal ceroid lipofuscinoses. *Hum. Mutat.* 2012;33:42–63.
- Jalanko Anu, Braulke Thomas. Neuronal ceroid lipofuscinoses. *Biochimica Biophysica Acta.* 2009;1793:697–709.
- Mole SE, Williams RE. Neuronal Ceroid-Lipofuscinoses. 2001 Oct 10 [Updated 2013 Aug 1]. In: Pagon RA, Adam MP, Ardinger HH, et al., editors. GeneReviews® [Internet]. Seattle (WA): University of Washington, Seattle; 1993–2015. Available from: <http://www.ncbi.nlm.nih.gov/books/NBK1428/>.
- Williams Ruth E, Aberg Laura, Autti Taina, Goebel Hans H, Kohlschutter Alfried, Lonnqvist Tuula. Diagnosis of the neuronal ceroid lipofuscinoses: an update. *Biochimica Biophysica Acta.* 2006;1762:865–872.
- Herva R, Tyynela J, Hirvasniemi A, Syrjakallio-Yitalo M, Haltia M. Northern epilepsy: a novel form of neuronal ceroid lipofuscinoses. *Hum. Mutat.* 2004;10: 215–222.
- Zelnick Nathanel, Mahajna Muhammad, Iancu Theodore C, Sharony Reuven, Zeigler Marsha. A novel mutation of the CLN8 gene: is there a Mediterranean phenotype? *Pediatr. Neurol.* June 2007;36(6):411–413.
- Cannelli N, Cassandrini D, Bertini E, et al. Novel mutations in CLN8 in Italian variant late infantile neuronal ceroid lipofuscinosis: another genetic hit in the Mediterranean. *Neurogenetics.* 2006;7:111e7.
- M Mahajnah, Zelnick N. Phenotypic heterogeneity in consanguineous patients with a common CLN8 mutation. *Pediatr. Neurol.* 2012 Oct;47(4):303–305. <http://dx.doi.org/10.1016/j.pediatrneurol.2012.05.016>.
- Allen NM, O'hici B, Anderson G, Nestor T, Lynch SA, King MD. Variant late-infantile neuronal ceroid lipofuscinosis due to a novel heterozygous CLN8 mutation and de novo 8p23.3 deletion. *Clin. Genet.* 2012;81(6):602–604. <http://dx.doi.org/10.1111/j.1399-0004.2011.01777.x>. Epub 2011 Dec 28.
- Jadav RH, Sinha S, Yasha TC, Aravinda H, Rao S, Bindu PS, Satishandra P. Magnetic resonance imaging in neuronal ceroid lipofuscinosis and its subtypes. *Neuroradiol. J.* 2012;25(6):755–761. Epub 2012 Dec 20.
- P1 Striano, Specchio N, Biancheri R, Cannelli N, Simonati A, Cassandrini D, Rossi A, Bruno C, Fusco L, Gaggero R, Vigeveno F, Bertini E, Zara F, Santorelli FM, Striano S. Clinical and electrophysiological features of epilepsy in Italian patients with CLN8 mutations. *Epilepsy Behav.* 2007;10(1):187–191. Epub 2006 Nov 28.
- NCL resource mutation data base, MRC Laboratory for Molecular Cell Biology, University College London, Gower Street, London. WC1E 6BT. United Kingdom (URL: <http://www.ucl.ac.uk/ncl/mutation.shtml>).
- Reinhardt K, Grapp M, Schlachter K, Bruck W, Gartner J, Steinfeild R. Novel CLN8 mutations confirm the clinical and ethnic diversity of late infantile neuronal ceroid lipofuscinosis. *Clin. Genet.* 2010;77(Suppl. 1):79–85, 7pp.
- Exome Aggregation Consortium (ExAC), Cambridge, MA (URL: <http://exac.broadinstitute.org>).
- Malik S. Polydactyly: phenotypes, genetics and classification. *Clin. Genet.* 2014;85(3):203–212. <http://dx.doi.org/10.1111/cge.12276>. Epub 2013 Oct 18.