



Case Report

Primary Non-Hodgkin Lymphoma of the temporal bone: A rare case report

Chaker Kaoutar^{*}, Ahmed Brahim Ahmedou^{**}, Oukessou youssef, Rouadi Sami, Redallah Abada, Roubal Mohamed, Mahtar Mohamed

ENT, Head and Neck Surgery Department, Ibn Rochd University Hospital, Faculty of Medicine and Pharmacy, Hassan II, Casablanca, Morocco



ARTICLE INFO

Keywords:

Lymphoma
Temporal bone
Chemotherapy
Complete remission

ABSTRACT

Introduction: Primary lymphoma of the temporal bone is extremely rare, difficult to diagnose and to manage. It is essential that the clinician keeps in mind the possibility of this pathology as a differential diagnosis with the infections resistant to the usual treatment.

Case report: We report a rare case of a diffuse large B-cell lymphoma in a 70-year-old woman, with history of diabetes. The pathological study was in favor of a Non-Hodgkin Lymphoma of the Temporal Bone.

Discussion: Lymphomas defined as malignant monoclonal proliferation of lymphoid cells, are not uncommon in the head and neck region. Literature presents with few cases.

Conclusion: The aim of this article is to report a rare case of a diffuse large B-cell lymphoma with primary mastoid and external auditory canal infiltration without systemic involvement initially presented as a benign ear infection.

1. Introduction

Lymphomas are the second most frequent malignant tumor with an incidence of 2.5% in the head and neck region after squamous cell carcinoma [1]. Knowing that malignant involvement of the temporal bone is rare with an incidence of less than 0.2% among all head and neck cancers and that some authors have reported the involvement of the temporal bone by generalized lymphoma [2]; primary involvement of temporal bone without systemic involvement is broadly rare [3]. Only few cases of primary involvement of the temporal bone by lymphoma were reported in the past 20 years of which only 3 cases have been reported in the last year [4,5]. Lymphomas can be widely classified as Hodgkin's lymphoma (HL) or non-Hodgkin's lymphoma (NHL). NHL can be sub-categorized into B-cell lymphoma, T-cell lymphoma, or natural killer (NK) cell lymphoma [6].

The aim of this article is to report a rare case of a diffuse large B-cell lymphoma with primary mastoid and external auditory canal infiltration without systemic involvement initially presented as a benign ear infection. We present a case in accordance with SCARE 2020 criteria [23].

2. Case report

We report a case of an 70-year-old woman with history of diabetes.

She was presented to the otolaryngology department with a House-Brackmann grade 5 right facial nerve palsy with a 2 weeks history of right postauricular pain and progressive unilateral hearing loss associated with a fever of 38.5 °C. Clinical examination showed a firm scalp swelling and nontender margins could not be well identified. Otoscopy revealed a right inflammatory polyp that completely obstructs the external auditory canal. There were no disorders of the balance notably no spontaneous or provoked nystagmus; also there was no cervical lymphadenopathy.

White blood count was elevated with 16,030 (80% neutrophils, 13% lymphocytes, and 7% monocytes). Computed tomography (CT) of the temporal bones showed a homogenous soft tissue density measuring 60 Hounsfield units, with pseudopagetooid reorganization of the texture of the whole of the petrous bone, with osteolysis of the walls of the middle ear, bone erosion of the second portion of the facial nerve, filling of the mastoid cells, of the external and middle ear. Retention of fluid in the right mastoid air cell system and the middle ear was noted. No radiological sign raising suspicion of cholesteatoma was seen. (Fig. 1). Magnetic resonance imaging (MRI) demonstrated a heterogeneous enhancing process at the level of the temporal bone (Fig. 2). The lesion was hypointense on T1-weighted imaging and hyperintense on T2-weighted imaging. A large intermediate signal petrous apex mass with extension into the right middle ear cavity and attic along with fluid

* Corresponding author.

** Corresponding author.

E-mail address: kaoutar1990ckr@gmail.com (C. Kaoutar).

<https://doi.org/10.1016/j.amsu.2021.102205>

Received 17 February 2021; Received in revised form 28 February 2021; Accepted 1 March 2021

Available online 4 March 2021

2049-0801/© 2021 The Authors. Published by Elsevier Ltd on behalf of IJS Publishing Group Ltd. This is an open access article under the CC BY-NC-ND license

(<http://creativecommons.org/licenses/by-nc-nd/4.0/>).

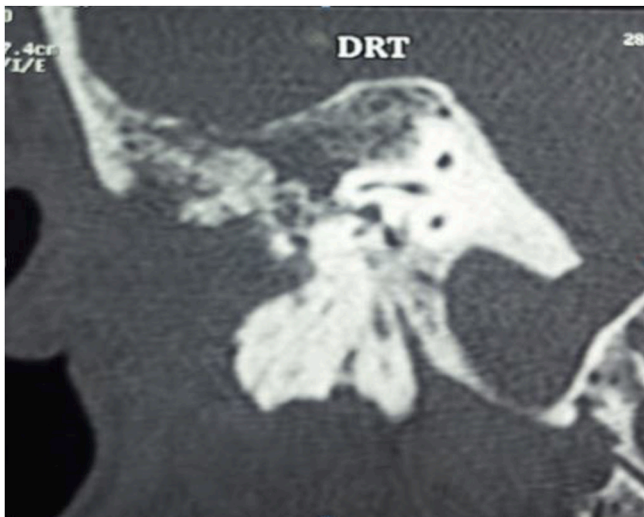


Fig. 1. Computed tomography showing a pseudopagetoid reorganization of the texture of the whole of the petrous bone.

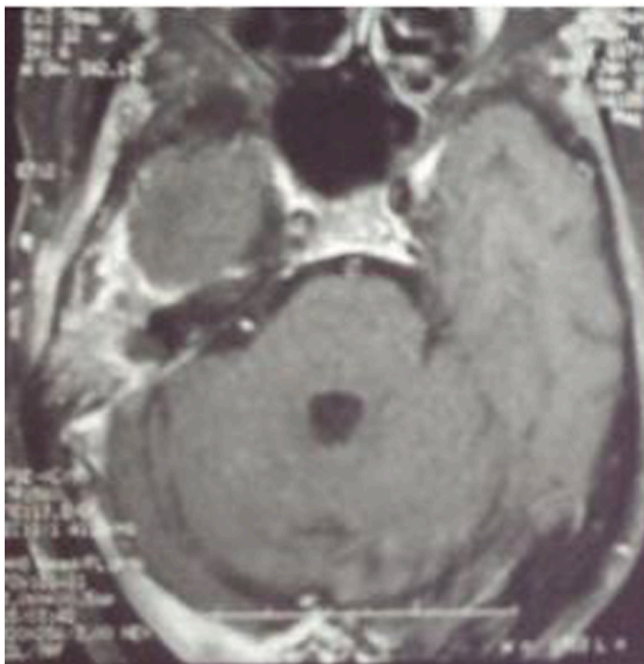


Fig. 2. (MRI) demonstrated a heterogeneous enhancing process at the level of the temporal bone.

retention in the mastoid air cells was confirmed on the MRI. No lymph node involvement was present on either CT or MRI.

Intravenous antibiotics and topical ciprofloxacin/dexamethasone drops were continued with no improvement. We carried out an excisional biopsy under local anesthesia of the inflammatory polyp. The histologic examination of the mass revealed a peripheral B-cell NHL: diffuse large cells 60% and follicular 40%, with an immune-proliferative activity (Ki-67 index) of 60%. The immunohistochemical study showed the negativity of CK, EMA, PT, PB, and the positivity of CD79a.

Assessment of extension made of cervico-thoraco-abdominal scanner and cerebral scanner did not show any lesion making suspect other localizations of lymphoma. The patient was subsequently referred to the Hematology department for osteomedullary biopsy and treatment. The rituxan, cyclophosphamide, doxorubicin, vincristine, and prednisone chemotherapy protocol were commenced with subsequent positive

clinical response after the initial treatment.

At two years, follow-up evaluation shows stable complete remission without localized recurrence or any systemic involvement. Otoloscopic examination did not reveal any anomaly but the hearing loss remained stationary.

3. Discussion

Lymphomas defined as malignant monoclonal proliferation of lymphoid cells; are not uncommon in the head and neck region (incidence of 2.5%) [2], and involve Waldeyer's ring, nasal cavity, paranasal sinuses, salivary glands, thyroid gland, and orbit [7]. The mastoid, middle ear most commonly, and the external/internal auditory canals are involved in a lesser degree [8]. All ages can be affected but this malignancy but it may have a tendency to appear in adult onset and with male predominance (male-to female ratio ranges from 1.5 to 2: 1) [1]. Some authors reported that typically the most common symptom of primary lymphoma of the temporal bone is conductive hearing loss, however sensori neural hearing loss occurs when cranial nerve VIII is involved [9]. Other reported that the most common initial symptom is localized pain, secondarily patients may present with a palpable mass, or rarely facial nerve palsy [10–13], this is due to the fact that the nerve sheath is resistant into tumor invasion and occurs when the bony facial canal is broken by the tumor and nerve fibers are involved by the tumor cells [14]; and affect usually the geniculate ganglion [15]. Therefore all of these malignant disorders are misdiagnosed and treated as external otitis. In our particular case, the right facial nerve palsy was due to erosion of the second bony segment of the right facial nerve canal.

HRCT play an important role in the diagnosis [16], it shows extensive irregular permeative osteolytic destruction of the temporal bone with soft tissue opacification of the mastoid air cells and erosion of the intercellular septae [2]. This osteolytic lesions of the temporal bones should be considered with a high degree of suspicion for malignancy in general or aggressive infective pathologies [17]. There by, HRCT and contrast enhanced MRI scans are important for a better evaluation of malignancies involving the temporal bone [2]. HRCT provides details on the type of bone destruction, middle ear condition, ossicular chain evaluation, exact site/extent of the intratemporal bony facial canal and the integrity of the tegmen tympani. The main role MRI is to identify meningeal and brain parenchymal invasion, to give detailed mapping about the entire extent of extracranial soft tissue involvement as well as the perineural spread on the facial nerve [18,19]. Therefore, any abnormal radiologic findings that are suspicious for a neoplasm should be biopsied. The cells of primary bone lymphoma may be mixed in appearance so that osteomyelitis is suspected [20].

Delgado and al [21]. described that a single biopsy could not be sufficient in some cases. Thus, Fish and al. [22], reported that incisional biopsy may cause a misdiagnosis or a delay in diagnosis.

4. Conclusion

Lymphoma of the Temporal Bone is extremely a rare tumor in current practice, it is also a difficult tumor to be diagnosed, beside that Literature presents with few cases. It is a diagnosis to think of him face to an infection resistant to the usual treatment. The diagnosis is confirmed after a biopsy with anatomopathological examination.

Ethical approval

I declare on my honor that the ethical approval has been exempted by my establishment.

Sources of funding

None.

Author contribution

Chaker Kaoutar: Corresponding author writing the paper.
 Ahmed Brahim Ahmedou: Corresponding author writing the paper.
 Youssef Oukessou: study concept.
 Sami Rouadi: study concept.
 Redallah Abada: study concept.
 Mohamed Roubal: correction of the paper.
 Mohamed Mahtar: correction of the paper.

Registration of research studies

Researchregistry5198.

Guarantor

DR AHMED BRAHIM AHMEDOU.
 DR CHAKER KAOUTAR.

Consent

Written informed consent was obtained from the patient for publication of this case report and accompanying images.

Provenance and peer review

Not commissioned, externally peer reviewed.

Declaration of competing interest

The authors declare having no conflicts of interest for this article.

References

- [1] Luca Bruschini, Andrea De Vito, Susanna Fortunato, Marco Pelosini, Giulia Cervetti, Mario Petrini, and Stefano Berrettini. A case of primary non-Hodgkin's lymphoma of the external auditory canal. <https://doi.org/10.1155/2013/138397>.
- [2] Sanjay Vaid, Jyoti Jadhav, Aparna Chandorkar, and Neelam Vaid. Bilateral non-Hodgkin's lymphoma of the temporal bone: a rare and Unusual Presentation. <https://doi.org/10.1155/2016/2641876>.
- [3] S. Ogawa, I. Tawara, S. Ueno, et al., De novo CD5-positive diffuse large B-cell lymphoma of the temporal bone presenting with an external auditory canal tumor, *Intern. Med.* 45 (11) (2006) 733–737.
- [4] Yi Liu, Qiuqian Chen, Si Yu, Zhi Gang Zhang, Temporal Bone Histopathology Case of the Month Hodgkin's Lymphoma of the Temporal Bone Accompanied by Intracranial Abscess, vol. 35, *Otology & Neurotology, Inc*, 2014, e95Ye96.
- [5] Christopher Y. Chang, Elizabeth K. O'halloran, and Samuel R. Fisher. reportPrimary Non-hodgkin's Lymphoma of the Petrous Bone: Case Report. American Academy of Otolaryngology–Head and Neck Surgery Foundation, Inc 10.1067/j.otohns.2003.08.006.
- [6] Sameer A. Alvi, John P. Flynn, yMelissa Gener, zRobert Cullen, Burkitt lymphoma of the temporal bone, *Otol. Neurotol.* 39 (2018). No. xx.
- [7] R.C. Jordan, P.M. Speight, "Extranodal non-Hodgkin's lymphomas of the oral cavity, *Curr. Top. Pathol.* 90 (1996) 125–146.
- [8] S.P. Hersh, W.G. Harrison, D.J. Hersh, Primary B cell lymphoma of the external auditory canal, *Ear Nose Throat J.* 85 (9) (2006) 597–599.
- [9] H.F. Schuknecht, A.F. Allam, Y. Murakami, Pathology of secondary malignant tumors of the temporal bone, *Ann. Otol. Rhinol. Laryngol.* 77 (1) (1968) 5–22.
- [10] S. Ogawa, I. Tawara, S. Ueno, M. Kimura, K. Miyazaki, H. Nishikawa, M. Yamaguchi, T. Kobayashi, H. Shiku, De novo CD5-positive diffuse large B-cell lymphoma of the temporal bone presenting with an external auditory canal tumor, *Intern. Med.* 45 (11) (2006) 733–737, <https://doi.org/10.2169/internalmedicine.45.1671>. Epub 2006 Jul 3. PMID: 16819255.
- [11] P. Dubey, C.S. Ha, P.C. Besa, et al., Localized primary malignant lymphoma of bone, *Int. J. Radiat. Oncol. Biol. Phys.* 37 (1997) 1087–1093.
- [12] J. Baar, R.L. Burkes, R. Bell, M.E. Blackstein, B. Fernandes, F. Langer, Primary non-Hodgkin's lymphoma of bone. A clinicopathologic study, *Cancer* 73 (4) (1994) 1194–1199.
- [13] U. Bockmuhl, K.-L. Bruchhage, H. Enzmann, Primary non-Hodgkin's lymphoma of the temporal bone, *Eur. Arch. Oto-Rhino-Laryngol.* 252 (6) (1995) 376–378.
- [14] H. Saito, K. Chinzei, M. Furuta, Pathological features of peripheral facial paralysis caused by malignant tumour, *Acta Oto-Laryngol. - Suppl.* 446 (1988) 165–171.
- [15] D.L. Tucci, P.R. Lambert, D.J. Innes Jr., Primary lymphoma of the temporal bone, *Arch. Otolaryngol. Head Neck Surg.* 118 (1) (1992) 83–85.
- [16] K. Koral, J.G. Curran, A. Thompson, Primary non-Hodgkin's lymphoma of the temporal bone CT findings, *Journal of Clinical Imaging* 27 (2003) 386–388.
- [17] M.L. Paige, J.R. Bernstein, Transcalvarial primary lymphoma of bone. A report of two cases, *Neuroradiology* 37 (6) (1995) 456–458.
- [18] W.R. Nemzek, S. Hecht, R. Gandour-Edwards, P. Donald, K. McKenna, Perineural spread of head and neck tumors: how accurate is MR imaging? *Am. J. Neuroradiol.* 19 (4) (1998) 701–706.
- [19] M.L. Paige, J.R. Bernstein, Transcalvarial primary lymphoma of bone: a report of two cases, *Neuroradiology* 37 (6) (1995) 456–458.
- [20] M.L. Ostrowski, K.K. Unni, P.M. Banks, et al., Malignant lymphoma of bone, *Cancer* 58 (12) (1986) 2646–2655.
- [21] A.G. Delgado, F.A. Marco, N.S. Martinez, C.S. Gasso, T cell Non Hodgkin's lymphoma of the external auditory canal, *Acta Otorrinolaringologica Española* 59 (2008) 200–201.
- [22] B.M. Fish, R. Huda, S.A.C. Dundas, T.H.J. Lesser, Clinical records: B-cell lymphoma of the external auditory meatus, *J. Laryngol. Otol.* 116 (1) (2002) 39–41.
- [23] R.A. Agha, T. Franchi, C. Sohrabi, G. Mathew, for the Scare Group, The SCARE 2020 guideline: Updating consensus surgical Case REport (SCARE) guidelines, *Int. J. Surg.* 84 (2020) 226–230.