


## ORIGINAL ARTICLE

# Near zero vascular complications using echo-guided puncture during catheter ablation of arrhythmias: A retrospective study and literature review

Pier Luigi Pellegrino MD, PhD<sup>1</sup> | Antonio Di Monaco MD<sup>2,3</sup>  |  
Francesco Santoro MD, PhD<sup>1,4</sup> | Massimo Grimaldi MD, PhD<sup>2</sup> | Girolamo D'Arienzo MD<sup>1</sup> |  
Grazia Casavecchia MD, PhD<sup>1</sup> | Riccardo Ieva MD<sup>1</sup> | Matteo Di Biase MD<sup>4</sup> |  
Massimo Iacoviello MD, PhD<sup>1,4</sup> | Natale Daniele Brunetti MD, PhD<sup>1,4</sup>

<sup>1</sup>Cardiology Unit, Policlinico Riuniti University Hospital, Foggia, Italy

<sup>2</sup>Department of Cardiology, General Regional Hospital "F. Miulli", Bari, Italy

<sup>3</sup>Department of Clinical and Experimental Medicine, University of Foggia, Foggia, Italy

<sup>4</sup>Department of Medical and Surgical Sciences, University of Foggia, Foggia, Italy

## Correspondence

Antonio Di Monaco, Department of Cardiology, General Regional Hospital "F. Miulli", Acquaviva delle Fonti, BA, Italy.  
Email: [a.dimonaco@gmail.com](mailto:a.dimonaco@gmail.com)

## Abstract

**Background:** Catheter ablation (CA) is routinely used for the treatment of arrhythmias. Vascular complications are the most common complications during these procedures. Previous data reported that ultrasound (US)-guided puncture is a useful method to avoid vascular complications. We reported our experience using US-guided puncture in patients undergoing CA for arrhythmias.

**Methods:** A total of 273 patients (mean age  $57 \pm 17$  years; 58% male) were referred to our center for CA of arrhythmias from January 2016 to December 2019. All procedures were performed by expert operators, and US-guided vascular access was performed on all patients. Doppler sonography was performed the day after the procedure on all patients.

**Results:** Eighty-four patients (31%) underwent atrioventricular nodal reentrant tachycardia ablation, 49 patients (18%) atrioventricular reentrant tachycardia ablation, 14 patients (5%) atrial tachycardia ablation, 25 patients (9%) atrial flutter ablation, 63 patients (23%) atrial fibrillation ablation, and 38 patients (14%) ventricular tachycardia ablation. Vascular pseudo-aneurysms and arteriovenous fistula were defined as major complications; furthermore, venous thrombosis and inguinal hematomas were as defined minor complications. The percentage of major vascular complications was 0.3% (1 arteriovenous fistula) and the percentage of minor vascular complications was 0.3% (1 venous thrombosis).

**Discussion:** Ultrasound-guided vascular puncture in patients undergoing CA is useful to improve procedural success and reduce complications.

## KEYWORDS

cardiac arrhythmias, catheter ablation, ultrasound-guided vascular puncture

Pier Luigi Pellegrino and Antonio Di Monaco made same contribution to the article.

This is an open access article under the terms of the [Creative Commons Attribution-NonCommercial-NoDerivs](https://creativecommons.org/licenses/by-nc-nd/4.0/) License, which permits use and distribution in any medium, provided the original work is properly cited, the use is non-commercial and no modifications or adaptations are made.

© 2022 The Authors. *Journal of Arrhythmia* published by John Wiley & Sons Australia, Ltd on behalf of the Japanese Heart Rhythm Society.

## 1 | INTRODUCTION

Catheter ablation (CA) is routinely used for the treatment of arrhythmias.<sup>1-3</sup> Supraventricular tachycardia (SVT) ablation is associated with a low incidence of adverse events,<sup>3,4</sup> whereas ablation of complex tachycardia, such as atrial fibrillation (AF) or ventricular tachycardia (VT), is associated with a significant risk of serious complications.<sup>1,2,4-7</sup> Among those, vascular complications are the most common since patients are frequently anticoagulated and procedures require the insertion of multiple sheaths. The incidence of serious vascular complications varies from 0.2% to 1.5%.<sup>1-8</sup> In particular, a world survey on AF ablation published in 2010 described a complication rate of 1.5%,<sup>8</sup> whereas a recent study reported 1.53% of vascular complications requiring blood transfusion or surgical repair.<sup>9</sup> In patients undergoing VT, ablation vascular complications were higher up to 6.9%.<sup>10,11</sup>

Recent data reported that ultrasound (US)-guided puncture is a useful method to avoid major and minor vascular complications.<sup>12-14</sup> In particular, US imaging allows direct visualization of arterial and venous anatomy and evaluates the anatomical variants of the vessels.

In this article, we reported our experience using US-guided puncture in patients undergoing CA for arrhythmias.

## 2 | METHODS

### 2.1 | Study population

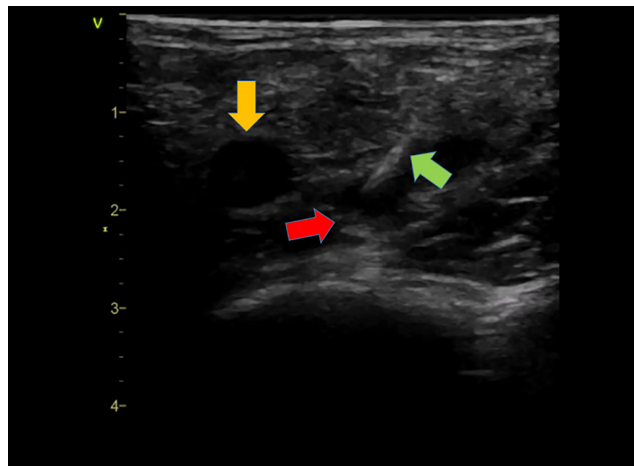
A total of 273 patients (mean age  $57 \pm 17$  years; 58% male) were referred to our center for CA of arrhythmias from January 2016 to December 2019. All procedures were performed by expert operators, and ultrasound-guided vascular access was performed on all patients.

Furthermore, Doppler sonography was performed the day after the procedure in all patients to assess possible vascular complications. Vascular pseudo-aneurysms and arteriovenous fistula were defined as major complications; furthermore, venous thrombosis and inguinal hematomas were defined as minor complications. This study was approved by the Ethics Committee of Policlinico Riuniti University Hospital, Foggia, Italy.

### 2.2 | Ultrasonography and venous access

The femoral puncture was performed using a mobile US system with a dual probe (VScan, GE Medical System) or an 8 MHz linear ultrasound transducer connected to a portable echocardiograph (GE Vivid/E, Health Medical, Horten, Norway).

The ultrasound preparation was performed, with the help of a nonsterile staff member, positioning the ultrasound gel on the probe of the 8 MHz linear ultrasound transducer, and placing the probe itself in a sterile probe cover. In consideration of the small size, however, the mobile ultrasound system was inserted entirely in



**FIGURE 1** Vascular ultrasound image showing visualization of the right femoral artery (yellow arrow), right femoral vein (red arrow), and the needle inside the right femoral vein (green arrow)

the sterile probe cover and the ultrasound setting (depth, 2D, color doppler, image acquisition) was performed directly by the operator. In addition, sterile saline was applied to the patient's skin.

The transducer was covered with a sterile sleeve and positioned at a 90° angle to the course of the vein in the groin region to obtain a transverse view. Real-time US imaging of the spatial relationship of the artery and vein and of the course of the access needle visually guided the puncture. The target vessel was centered in the middle of the screen with the probe held with the left hand perpendicular to the skin. Using the Seldinger technique, the needle was introduced with the right hand below the US probe toward its center while watching for tissue movement on the US screen (Figure 1). Finally, the operator used US to check the guidewires course and to rule out vascular damages.

### 2.3 | Electrophysiological study and CA

The procedure was performed in nonsedated patients after informed written consent. A three catheter configuration was routinely used at our institution for CA of atrioventricular nodal reentrant tachycardia (AVNRT), atrioventricular reentrant tachycardia (AVRT), atrial tachycardia, and atrial flutter. In particular, during these procedures, we introduced the sheaths in the right femoral vein: a 6-Fr decapolar and quadripolar deflectable diagnostic catheters for electrophysiological study (Inquiry Bio Inc., St. Jude Medical, Inc.) and a 7-Fr deflectable 4 mm tip ablation catheter inserted for mapping and ablation (Celsius Thermocool; Cordis; Biosense Webster, Inc). Moreover, in patients with left accessory pathways, we used femoral arterial access to insert the ablation catheter in the heart through a retrograde transaortic approach.

A four-catheter configuration was routinely used for the ablation in patients with AF: a 6-Fr decapolar deflectable diagnostic catheter and an 8-Fr intracardiac echocardiogram (ACUSON AcuNav™; Biosense Webster, Inc) were introduced the sheaths in the left

femoral vein; a multipolar mapping catheter (Lasso or Pentaray, Biosense Webster Inc.) and an irrigated 3.5 mm tip ablator catheter (Smarth Touch, Biosense Webster Inc) were introduced through the 8-Fr sheaths in the right femoral vein. A single transeptal puncture and long vascular sheaths (SLO, St. Jude Medical, Inc.) were used.

A two-catheter configuration was used for the ablation in patients with left VT through right femoral vein. In particular, an 8-Fr intracardiac echocardiogram (ACUSON AcuNav™; Biosense Webster, Inc) was positioned in the right chambers of the heart and a multipolar mapping catheter (Pentaray, Biosense Webster Inc.) was inserted in the left ventricle through the transeptal puncture. After substrate mapping, the multipolar catheter was removed and replaced with an irrigated 3.5 mm tip ablator catheter (Smarth Touch, Biosense Webster Inc.).

A single- or two-catheter configuration was, respectively, used for ablation in patients with right and left premature ventricular ectopy. In particular, an 8-Fr intracardiac echocardiogram (ACUSON AcuNav™; Biosense Webster, Inc) was positioned in the right chambers of the heart and an 8-Fr irrigated ablator catheter with contact force (Smart Touch, Biosense Webster) was inserted through the right femoral vein or right femoral artery.

Regarding anticoagulation therapy, AF ablation was performed in patients taking warfarin if PT-INR was between 2 and 2.5 the day of the procedure and, furthermore, in patients taking direct oral anticoagulants, one dose the day of the procedure was skipped.<sup>1,15,16</sup> During AF ablation, intravenous heparin was administered in order to maintain the activated clotting time of at least 300s. Moreover, during CA in the left ventricle, heparin was administered in order to maintain the activated clotting time of at least 300s. All the sheaths were withdrawn if the activated clotting time were less than 250s.

No suturing devices were used and manual compression was performed until the bleeding stopped (a compression bandage was used after all the arterial punctures). Patients remained in bed for 4–6 h after the venous puncture and for 24 h after the arterial puncture.

## 2.4 | Statistical analysis

Descriptive statistics are summarized as the mean  $\pm$  standard deviation for continuous variables and the number or percentages for categorical variables. Statistical analyses were performed using STATA software, version 14 (Stata).

## 3 | RESULTS

All clinical characteristics were reported in Table 1. In particular, 84 patients (31%) underwent AVNRT ablation, 49 patients (18%) AVRT ablation, 14 patients (5%) atrial tachycardia ablation, 25 patients (9%) atrial flutter ablation, 63 patients (23%) AF ablation, and 38 patients (14%) VT ablation.

All patients with AF were taking anticoagulant therapy; in particular, 8% with warfarin and 92% with direct oral anticoagulants.

TABLE 1 Clinical characteristics of enrolled patients

	Patients (n = 273)
Age (years)	57 $\pm$ 17
Male gender	58 (58%)
Smoking history	68 (25%)
Body Mass Index >30kg/m <sup>2</sup>	60 (22%)
Hypertension	137 (50%)
Dyslipidemia	63 (63%)
Diabetes mellitus	84 (31%)
Familiarity for cardiovascular disease	110 (40%)
Dysthyroidism	34 (12%)
Coronary artery disease	88 (32%)
ACE inhibitors	75 (27%)
Angiotensin-II-receptor antagonists	43 (16%)
Beta-blocker	134 (49%)
Diuretics	67 (25%)
Calcium channel blocker	87 (32%)
Antiplatelet	110 (40%)
Anticoagulant	29 (10%)
Amiodarone	63 (23%)
Statins	94 (34%)

The percentage of major vascular complications was 0.3%. In particular, one patient had an arteriovenous fistula (size 1.5 mm) documented the day after AVNRT ablation. This complication was treated by mechanical compression for 24 h without obtaining closure of the fistulous passage. However, a complete resolution of the complication was documented after 1 month.

The percentage of minor vascular complications was 0.3%. In particular, venous thrombosis at the site of vascular puncture was documented in a patient undergoing ablation of the right posteroseptal accessory pathway. The patient was treated with Edoxaban 60 mg/day for 1 month with a resolution of venous thrombosis. No other vascular complications were documented.

## 4 | DISCUSSION

The findings of the present study indicate that US-guided puncture in patients undergoing CA is useful to improve procedural success and reduce complications.

Vascular damage represents the major source of complications associated with CA of arrhythmias.<sup>1–11</sup> These vascular complications are more frequent in patients taking anticoagulant therapy, in patients affected by obesity and diabetes mellitus, and in female patients.<sup>1–3</sup>

The femoral vein originates in the terminal part of the adductor canal and ends behind the inguinal ligament, where it continues in the external iliac vein. The femoral artery, on the other hand, originates behind the inguinal ligament, halfway between the anterior

superior iliac spine and the pubic symphysis, and occupies the lateral corner of the vessel gap. Among these structures, there is a close anatomical relationship and, in particular, the femoral vein origins behind and laterally to the artery, while at the level of Scarpa's triangle, it is placed medially with different degrees of overlap observed from the ligament inguinal up to the distal tract. In fact, in adult subjects, a portion of the femoral artery overlaps the common femoral vein in 65% of patients.<sup>17,18</sup> In pediatric patients, however, overlapping is less frequent (12% of cases) and the puncture guided by an anatomical approach is associated with 20% of cannulation failure of the femoral vein.<sup>19,20</sup> Furthermore, there are variations between the right and left vascular bundles as those on the right originate more distal to the inguinal ligament and have a more vertical orientation than those on the left.<sup>17,18</sup>

Before the use of the US-guided approach, the femoral venous puncture was performed by identifying by palpation the point of maximum pulsation of the femoral artery 1 cm below the inguinal ligament and pricking the vein 1 cm medially with respect to the artery. Some studies have shown that this approach can be ineffective in up to 35% of cases with a percentage of complications up to 19%,<sup>21</sup> with the formation of major femoral or retroperitoneal hematoma of 1.4%.<sup>22</sup> Moreover, the approach used for vascular puncture can determine the type of vascular complications. In particular, a low venous puncture could generate a pseudo-aneurysm or an arteriovenous fistula as some medial branches of the femoral artery can run superficially to the femoral vein. On the other hand, a too high venous puncture could lead to a greater probability of retroperitoneal hematoma.

Previous data reported a complication rate of 1 up to 13% performing vascular access without US use. Deshmukh et al.<sup>6</sup> reported a vascular complications rate of 1.5% in 93,801 patients ablated for AF in the United States. Moreover, the vascular complication rate in patients ablated for VT was 6.9% in a previous report of 4653 procedures<sup>10</sup> and 4.7% in the Thermocool VT trial.<sup>23</sup>

Previous studies demonstrated the effectiveness of different strategies in reducing femoral complications after ablation procedures; in particular, the use of smaller needles to obtain vascular access and mainly the use of US.<sup>12-14</sup> The main strength of the US-guided technique is the ability to visualize the vascular structures, as well as their size, depth, and optimal route of access. This explains the lower rate of major and minor vascular complications using this technique. In most cases, this technique is simple and the learning curve is fast.

The ULTRA FAST trial<sup>24</sup> reported data from 320 patients who underwent CA of arrhythmias. In particular, major vascular complications were 0.6% in patients undergoing US-guided procedures and 1.9% in those undergoing the conventional procedure. Otherwise, considering the secondary objectives: accidental puncture of the artery, a reduced puncture time, and the number of attempts, the data are favorable to the advantage of the US-guided procedure.

Other studies showed an effective advantage in using the US-guided technique compared with the traditional one. A study by Sharma et al.<sup>14</sup> provided a practical and detailed guide to the

US-guided procedure and analyzed the benefits derived from the use of this procedure. Furthermore, the retrospective analysis performed by Tanaka et al.<sup>12</sup> reported a significant reduction in total vascular complications from 1.7% to 0.5% and a seven-fold reduction in the incidence of major vascular complications in the group of patients who underwent US-guided procedure. In this study, moreover, vascular complications in patients taking anticoagulants were reduced from 4.3% to 0.5%.

Regarding the reduction of vascular complications, a study previously conducted in our center showed that in patients undergoing ablation of SVT, a simplified approach with a reduced number of catheters, resulted in a high acute success rate with a low percentage of vascular complications of 1.4% compared with about 3% reported in previous reports.<sup>25</sup>

In our current study, the percentage of vascular complications was reduced to 0.6% including major and minor complications. However, these complications were resolved with no sequelae for patients. This method allows to perform procedures with a lower percentage of complications and greater procedural success. Through the US-guided approach, each operator can use the number of catheters necessary to obtain procedural success without the limitation due to vascular accesses. For example, during complex procedures, further vascular access is usually useful to insert the intracardiac echocardiogram probe, a tool capable to improve procedural success and reduce complications. The main limitation of this study is the low number of patients.

## 5 | CONCLUSION

Ultrasound-guided vascular puncture in patients undergoing CA is useful to improve procedural success and reduce complications.

## CONFLICT OF INTEREST

Authors declare no conflict of interests for this article.

## ORCID

Antonio Di Monaco  <https://orcid.org/0000-0002-1297-2056>

## REFERENCES

1. Calkins H, Hindricks G, Cappato R, Kim YH, Saad EB, Aguinaga L, et al. 2017 HRS/EHRA/ECAS/APHS/SOLAECE expert consensus statement on catheter and surgical ablation of atrial fibrillation. *Europace*. 2018;20:e1-e160.
2. Cronin EM, Bogun FM, Maury P, Peichl P, Chen M, Namboodiri N, et al. 2019 HRS/EHRA/APHS/LAHS expert consensus statement on catheter ablation of ventricular arrhythmias. *Europace*. 2019;21:1143-4.
3. Brugada J, Katriotis DG, Arbelo E, Arribas F, Bax JJ, Blomström-Lundqvist C, et al. 2019 ESC guidelines for the management of patients with supraventricular tachycardia. The task force for the management of patients with supraventricular tachycardia of the European Society of Cardiology (ESC). *Eur Heart J*. 2020;41:655-720.

4. Bohnen M, Stevenson WG, Tedrow UB, Michaud GF, John RM, Epstein LM, et al. Incidence and predictors of major complications from contemporary catheter ablation to treat cardiac arrhythmias. *Heart Rhythm*. 2011;8:1661–6.
5. Prudente LA, Moorman JR, Lake D, Xiao Y, Greebaum H, Mangrum JM, et al. Femoral vascular complications following catheter ablation of atrial fibrillation. *J Interv Card Electrophysiol*. 2009;26:59–64.
6. Deshmukh A, Patel NJ, Pant S, Shah N, Chothani A, Mehta K, et al. In-hospital complications associated with catheter ablation of atrial fibrillation in the United States between 2000 and 2010: analysis of 93 801 procedures. *Circulation*. 2013;128:2104–12.
7. Katz DF, Turakhia MP, Sauer WH, Tzou WS, Heath RR, Zipse MM, et al. Safety of ventricular tachycardia ablation in clinical practice: findings from 9699 hospital discharge records. *Circ Arrhythmia Electrophysiol*. 2015;8:362–70.
8. Cappato R, Calkins H, Chen SA, Davies W, Iesaka Y, Kalman J, et al. Updated worldwide survey on the methods, efficacy, and safety of catheter ablation for human atrial fibrillation. *Circ Arrhythm Electrophysiol*. 2010;3:32–8.
9. Hoyt H, Bhonsale A, Chilukuri K, et al. Complications arising from catheter ablation of atrial fibrillation: temporal trends and predictors. *Circulation*. 2013;128:2104–12.
10. Palaniswamy H, Kolte D, Harikrishnan P, et al. Catheter ablation of postinfarction ventricular tachycardia: ten-year trends in utilization, in-hospital complications, and in-hospital mortality in the United States. *Heart Rhythm*. 2014;11:2056–63.
11. Peichl P, Wichterle D, Pavlu L, Cihak R, Aldhoon B, Kautzner J. Complications of catheter ablation of ventricular tachycardia a single-center experience. *Circ Arrhythm Electrophysiol*. 2014;7:684–90.
12. Tanaka-Esposito CC, Chung MK, Abraham JEM, Cantillon DJ, Abi-Saleh B, Tchou PJ. Real-time ultrasound guidance reduces total and major vascular complications in patients undergoing pulmonary vein antral isolation on therapeutic warfarin. *J Interv Card Electrophysiol*. 2013;37:163–8.
13. Errahmouni A, Bun SS, Lactu DG, Saoudi N. Ultrasound-guided venous puncture in electrophysiological procedures: a safe method. *Rapidly Learned PACE*. 2014;37:1023–8.
14. Sharma PS, Padala SK, Gunda S, Koneru JN, Ellenbogen KA. Vascular complications during catheter ablation of cardiac arrhythmias: a comparison between vascular ultrasound guided access and conventional vascular access. *J Cardiovasc Electrophysiol*. 2016;27:1160–6.
15. Pelargonio G, Di Monaco A, Guida P, et al. Atrial fibrillation ablation: is common practice far from guidelines' world? The Italian experience from a national survey. *J Interv Card Electrophysiol*. 2021 Feb 10;63:125–32. <https://doi.org/10.1007/s10840-021-00955-7>
16. Di Monaco A, Guida P, Vitulano N, et al. Catheter ablation of atrial fibrillation with uninterrupted anticoagulation: a meta-analysis of six randomized controlled trials. *J Cardiovasc Med (Hagerstown)*. 2020;21:483–90.
17. Hughes P, Scott C, Bodenham A. Ultrasonography of the femoral vessels in the groin: implications for vascular access. *Anaesthesia*. 2000;55:1198–202.
18. Baum PA, Matsumoto AH, Teitelbaum GP, Zuurbier RA, Barth KH. Anatomical relationship between the common femoral artery and vein: CT evaluation and clinical significance. *Radiology*. 1989;173:775–7.
19. Warkentine FH, Pierce MC, Lorenz D, Kim K. The anatomic relationship of femoral vein to femoral artery in euvoletic pediatric patients by ultrasonography: implications for pediatric femoral central venous access. *Acad Emerg Med*. 2008;15:426–30.
20. Bhatia N, Sivaprakasam J, Allford M, Guruswamy V. The relative position of femoral artery and vein in children under general anesthesia – an ultrasound-guided observational study. *Paediatr Anaesth*. 2014;24:1164–8.
21. Brass P, Hellmich M, Kolodziej L, Schick G, Smith AF. Ultrasound guidance versus anatomical landmarks for subclavian or femoral vein catheterization. *Cochrane Database Syst Rev*. 2015;1:CD011447.
22. Merrer JK, De Jonghe B, Golliot F, et al. Complications of femoral and subclavian venous catheterization in critically ill patients. A randomized controlled trial. *JAMA*. 2001;286:700–7.
23. Marchlinski FE, Haffajee CI, Beshai JF, Dickfeld TML, Gonzalez MD, Hsia HH, et al. Long-term success of irrigated radiofrequency catheter ablation of sustained ventricular tachycardia: post-approval THERMOCOOL VT trial. *J Am Coll Cardiol*. 2016;67:674–83.
24. Yamagata K, Wichterle D, Roubícek T, et al. Ultrasound-guided versus conventional femoral venipuncture for catheter ablation of atrial fibrillation: a multicentre randomized efficacy and safety trial (ULTRA-FAST trial). *Europace*. 2018;20:1107–14.
25. Pellegrino PL, Grimaldi M, Di Martino L, et al. Long-term safety and efficacy of supraventricular tachycardia ablation with a simplified approach. *Acta Cardiol*. 2016;71:724–9.

**How to cite this article:** Pellegrino PL, Di Monaco A, Santoro F, Grimaldi M, D'Arienzo G, Casavecchia G, Near zero vascular complications using echo-guided puncture during catheter ablation of arrhythmias: A retrospective study and literature review. *J Arrhythmia*. 2022;38:395–399. <https://doi.org/10.1002/joa3.12723>