Transvenous endocardial conduction system pacing in patients with a Fontan operation

Benjamin W. Hale, MD, MS, FHRS,[1] Rajiv Devanagondi, MD,[1] Osamah Aldoss, MD,[2] Mark D. Olson, PA-C,[1] Ian H. Law, MD, FHRS[1]

From the [1]Division of Pediatric Cardiology, Department of Pediatrics, University of Iowa Roy J. and Lucille A. Carver College of Medicine, Iowa City, Iowa, and [2]Medical College of Wisconsin, Milwaukee, Wisconsin.

Introduction

Ventricular pacing in patients with a Fontan operation is associated with poor outcomes.[1] Moreover, delivering ventricular pacing is challenging; it is traditionally performed with epicardial leads, where dense epi-pericardial scar tissue can limit site selection for optimal electromechanical synchrony and can result in suboptimal acute lead function and decreased lead longevity. The advent of conduction system pacing (CSP) in patients with biventricular anatomy has generated a flurry of research in the past 10–20 years, leading to widespread acceptance because of superior systolic function and heart failure outcomes compared with other pacing techniques.[2] Yet, we are not aware of any reports of attempted CSP in any patient with a Fontan operation. The fact that the conduction system resides within the systemic arterial circulation is undoubtedly the main barrier to the exploration of this technique. However, there are several reports of chronically paced patients after the Fontan operation who received both leaded[3–7] and leadless[8–12] pacing hardware in their systemic ventricle when the epicardial approach was deemed unsuitable.

Here, we report the procedures and short-term outcomes from two young adult patients with a Fontan operation and atrioventricular block (AVB), who received CSP with transvenous dual-chamber pacemaker systems via a transbaffle approach. Electroanatomic mapping in the single ventricle was used to identify and target the conduction system with a ventricular pacing lead.

Case 1

A 19-year-old woman with a double inlet left ventricle, d-looped transposition of the great arteries, and pulmonary stenosis had staged Fontan palliation with initial pulmonary artery banding at 8 months of age, Damus-Kaye-Stansel and bidirectional Glenn operations at 12 months, and extracardiac Fontan operation with patch closure of the tricuspid valve at 5 years. She developed postsurgical AVB after the Fontan operation and received an epicardial dual-chamber pacemaker system. At 15 years of age, she underwent pacemaker generator replacement. At 19 years of age, 6 months prior to the case, she underwent her fifth median sternotomy operation for epicardial lead revision owing to atrial lead failure and high ventricular lead threshold. Because of dense scar tissue, non–steroid-eluting screw-in epicardial leads were implanted. Within months of her operation, her ventricular lead threshold climbed dramatically, progressing to noncapture at maximal output (Table 1). Her escape rhythm was a narrow complex with rates in 40–50 beats/min. She was deemed a poor candidate for another lead revision by the surgical team, and transvenous pacemaker implantation was planned after an appropriate multidisciplinary shared decision-making process.

The procedure was performed under general anesthesia. The right internal jugular and the left axillary vein were accessed percutaneously. To avoid the prosthetic extracardiac Fontan baffle, a perforation from the Fontan pathway at the base of the left pulmonary artery to the systemic atrium was created using the Baylis VersaCross radiofrequency (RF) wire system (Boston Scientific) from the right internal jugular access. The perforation was balloon dilated with a 6 mm × 4 cm high-pressure balloon. Simultaneously, a

KEY TEACHING POINTS

- Conduction system pacing can be achieved after the Fontan operation with a transvenous lead placed across the Fontan baffle.
- Electroanatomic mapping systems can aid in targeting variable conduction system anatomy.
- Long-term outcomes of a transbaffle conduction system pacing lead, including the risk of thromboembolism, durability of lead function, and effect on ventricular function, are unknown.

KEYWORDS Fontan; Conduction system; Pacemaker; Electroanatomic map; Single ventricle; AV block
(Heart Rhythm Case Reports 2025;11:1131–1136)

Address reprint requests and correspondence: Dr Benjamin W. Hale, Division of Pediatric Cardiology, BT-1010, 200 Hawkins Dr., Iowa City, Iowa 42242. E-mail address: Benjamin-hale@uiowa.edu.

2214-0271/© 2025 Heart Rhythm Society. Published by Elsevier Inc. This is an open access article under the CC BY-NC-ND license (http://creativecommons.org/licenses/by-nc-nd/4.0/).

https://doi.org/10.1016/j.hrcr.2025.08.006

Table 1 Electrical measures for ventricular pacing systems described in case 1

Pacing system	Days from implantation	Threshold (V @ 0.4 ms)	Impedance (Ω)	R wave (mV)	Estimated longevity (y)	Atrial pacing (%)	Ventricular pacing (%)
Epicardial lead	0	1	1539	>20	–	–	–
	1	1	551	14.3	10.2	33.6	100
	8	4.5	418	9.4	8.2	5.4	96.8
	19	3.25	475	13.6	3.4	16	100
	54	5.5 (@1.5 ms)	418	8.3	1.3	39	89.9
	69	8 (@1.5 ms)	399	8.3	1.2	28.9	100
	187	No capture	437	5.3	1	36.6	90.3
Conduction system pacing lead	0	0.4	627	8.4	–	–	–
	1	0.25	608	6.9	–	8.6	100
	20	0.5	608	6.8	11.3	13.8	100
	59	0.5	570	6.8	15.8	–	–
	153	0.5	494	5.9	11.7	26.7	100
	254	0.5	551	5.3	11.6	30.4	100
	348	0.625	532	5.8	11.3	34.6	100
	423	1.25	513	8.8	9.7	35.9	100
	516	1.625	551	5.8	9.8	24.9	100

All variables were measured in the bipolar configuration, with chronic programming in DDD mode and a lower rate limit of 60 beats/min.

Medtronic SelectSite deflectable delivery catheter was positioned at the perforation site from the left axillary access and used to pass a guidewire to the systemic atrium as the balloon deflated. A double-wire technique was used to pass a second wire through the dilated perforation, allowing the SelectSite catheter to be advanced transbaffle.

A 5-F deflectable decapolar catheter (Abbott inquiry, 2-5-2 spacing, Abbott, Inc.) was advanced through the SelectSite catheter to the ventricle. A 3-dimensional electroanatomic map (EAM) of the ventricle was created using the EnSite X (Abbott Inc.) electroanatomic mapping system, with a prior computed tomography scan imported for reference (Figure 1A). Sharp conduction system potentials were recorded on the remnant interventricular septum, and pacing from these sites produced a narrow QRS complex (Figure 1B).

A Medtronic SelectSecure 3830-69 cm lead was pinned into the electroanatomic mapping system in a unipolar configuration, allowing real-time visualization of the lead tip location on the EAM. The lead was fixed in the vicinity of the targeted site, which was accessible after changing the deflectable SelectSite catheter for a fixed-curve Medtronic 315-His delivery catheter modified outside the body by reversing the primary curve so the secondary curve pointed anteriorly, similar to a recently reported technique.[13] At the implant site, the lead recorded a sharp, early ventricular electrogram (Figure 1C) and resulted in a narrow paced QRS complex (Figure 1D), with a slightly different axis than the intrinsic junctional rhythm (Figure 2A and 2B).[14] The lead position on the EAM shifted slightly in the bipolar configuration. An atrial lead was implanted, and the leads were connected to a dual-chamber generator (Medtronic Azure XT DR) placed in a prepectoral pocket. Recovery from the operation was uneventful.

In follow-up over 22 months, the electrical function of the lead system has maintained low thresholds, with only a slight recent climb in pacing thresholds. There is an excellent estimated longevity as programmed in DDD mode with a lower rate limit of 60 beats/min (Table 1). Therapeutic anticoagulation has been maintained with rivaroxaban. There has been no systemic thromboembolism. Ventricular function by echocardiography at ∼8 months postimplantation has remained normal, with mild mitral valve regurgitation.

Case 2

A 25-year-old man with L-looped transposition of the great arteries, ventricular septal defect (VSD), and left atrioventricular valve atresia (hypoplastic left-sided right ventricle) underwent staged Fontan palliation with initial pulmonary artery banding and atrial septectomy at 1 week of age, hemi-Fontan operation at 8 months of age, and lateral tunnel Fontan operation at 20 months of age. He developed progressive AVB, initially with rate-responsive second-degree AVB at 24 years of age. Exercise testing the following year demonstrated a maximal heart rate of 72 beats/min with a peak oxygen consumption of 43% predicted, indicating depressed cardiorespiratory fitness. Because of exertional symptoms attributed to lack of chronotropy, a dual-chamber pacemaker was recommended. After an appropriate multidisciplinary shared decision-making process over the course of several clinic visits, the patient elected to undergo transvenous implantation with attempted CSP.

The procedure was performed under general anesthesia. An EAM of the Fontan pathway was created using EnSite X and an HD Grid catheter (Abbott) from the right femoral vein, and the EAM was merged with a prior computed tomography scan. Because of lateral tunnel Fontan anatomy, direct transbaffle puncture was performed from a percutaneous left axillary vein access site with the SupraCross RF transseptal solution and a pigtail RF wire (Boston Scientific), guided by fluoroscopy, transesophageal echocardiography, and electroanatomic mapping. The sheath was advanced across the baffle. An EAM of the systemic ventricle was

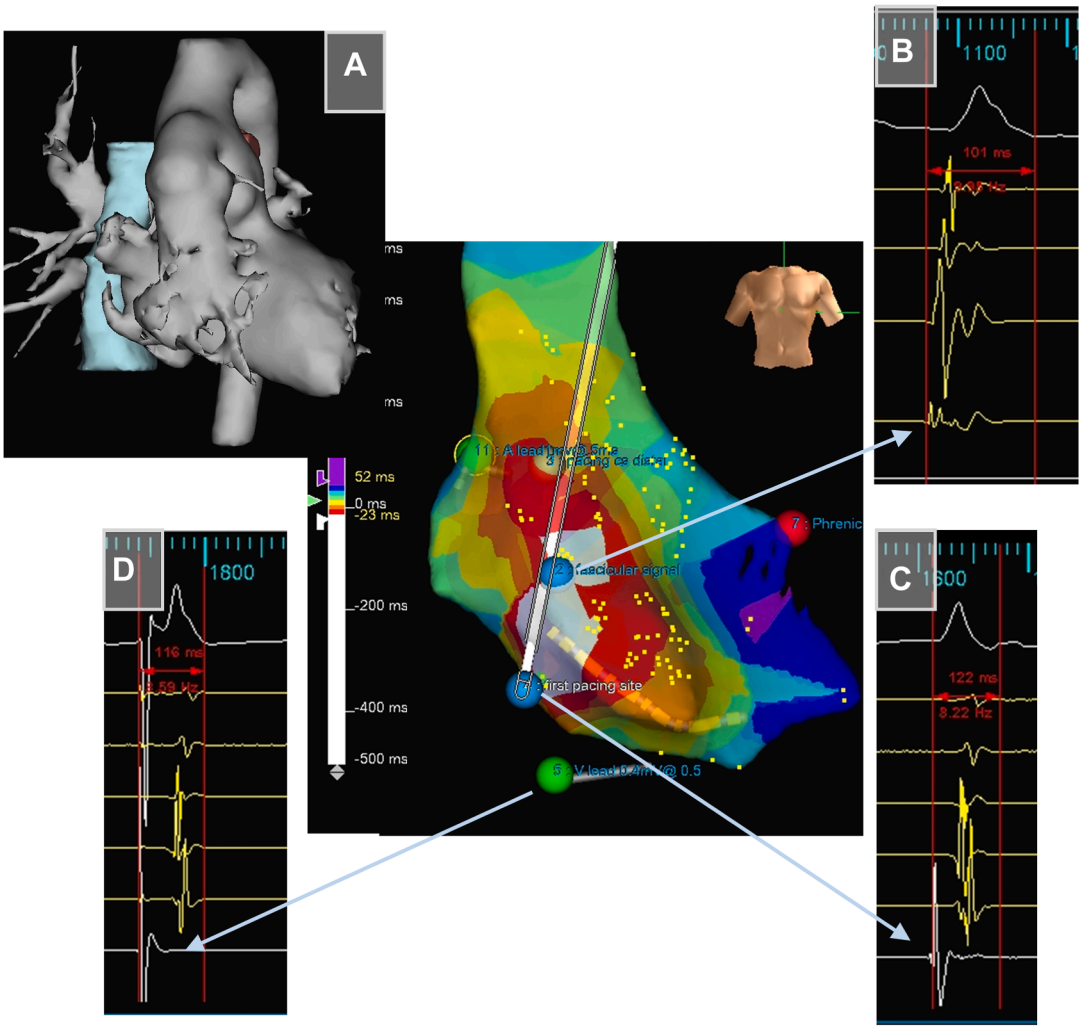

Figure 1 Case 1 electroanatomic map (EAM) with notable locations tagged. (**A**) The EAM was referenced to the cardiac computed tomography data. At (**B**), the mapping catheter recorded sharp prepotentials along the remnant intraventricular septum, which were targeted for implantation. The lead was able to be implanted nearby at (**C**) with unipolar guidance, where an early ventricular electrogram was recorded, though no clear conduction system potential was present. When the lead was connected in a bipolar configuration, the position shifted slightly to (**D**), where the paced QRS duration remained narrow.

created (Figure 3A), annotating timing and emphasizing high-frequency early potentials (Figure 3B). Conduction system potentials were found to course anterior to the VSD in the expected anatomical location. The sheath was removed over a guidewire.

A Medtronic 3830-69 cm lead was fixed in the area of the conduction system potentials with electroanatomic mapping guidance using a Medtronic SelectSite catheter. At the ultimate implant site, just apical to the VSD, the pacemaker lead recorded a sharp pre-QRS potential (Figure 3C), and pacing resulted in a QRS complex nearly identical to intrinsic conduction (Figure 2C and 2D). The electrical function of the lead was excellent (Table 2). An atrial lead was implanted in the Fontan pathway. The leads were connected to a dual-chamber pacemaker generator (Medtronic Azure XT DR) placed in a prepectoral pocket. Recovery from the procedure was uncomplicated. Anticoagulation with rivaroxaban was initiated on the evening of the procedure.

Echocardiography on postoperative day 1 revealed normal ventricular function and trivial mitral regurgitation. Electrical measures have remained favorable through early follow-up (Table 2).

Discussion

Here, we report, to the best of our knowledge, for the first instances of CSP via endocardial dual-chamber pacemaker implantation in two patients with a Fontan operation. The resulting ventricular paced QRS complexes are markedly narrow, suggesting excellent electromechanical synchrony and likely a low risk of pacing-related dysfunction. Early electrical function of the leads is excellent. Given that the population with single ventricles is particularly susceptible to the maladies of chronic ventricular pacing, this technique deserves further exploration.

In an international, multicenter, case-controlled study,[1] patients with single ventricles and ventricular pacing were

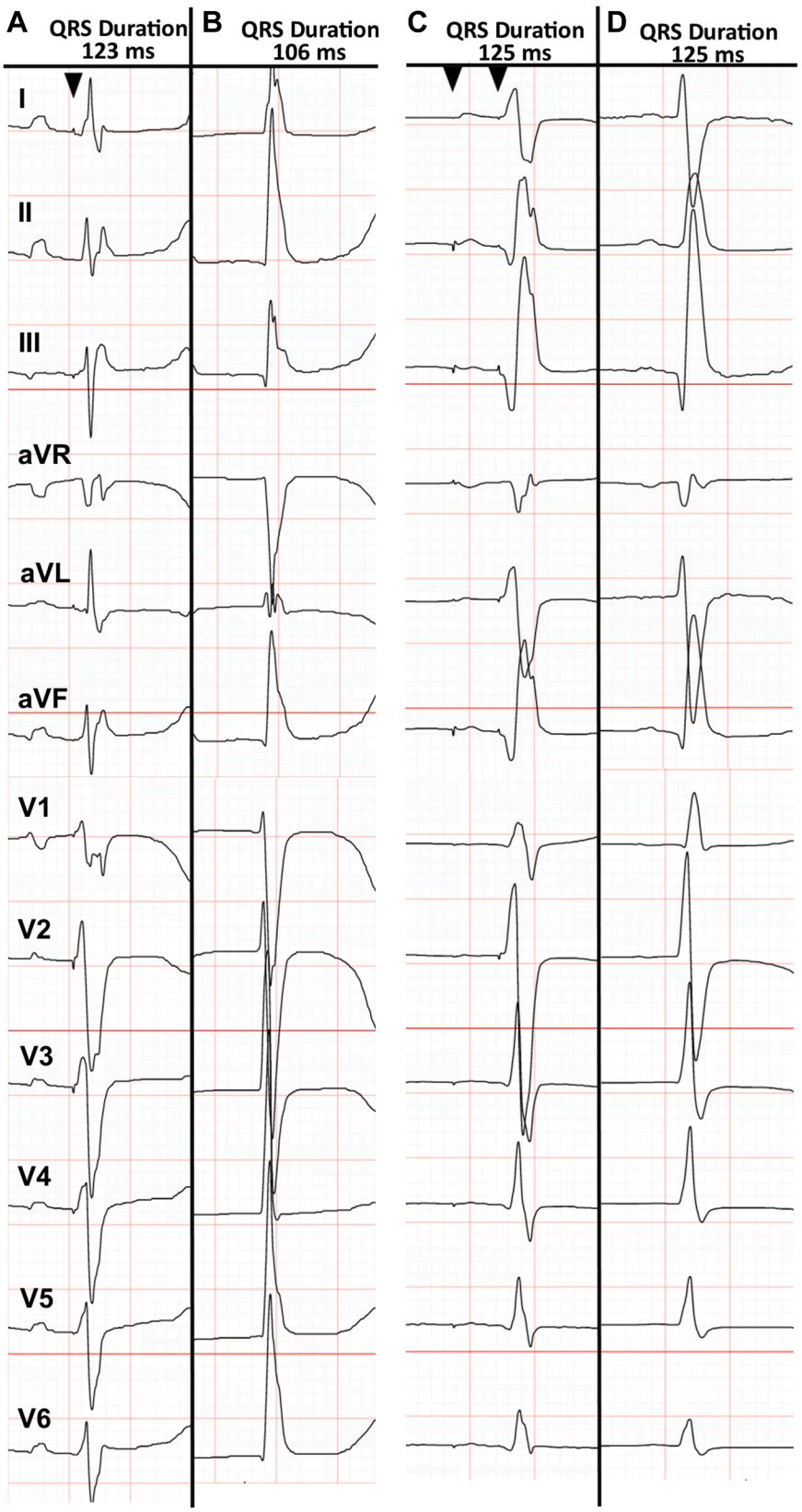

Figure 2 Paced (**A**) and intrinsic (**B**) 12-lead electrocardiograms (ECGs) for case 1. The paced QRS duration of 123 ms is 116% of the intrinsic QRS duration, with a z score of +3.5.[14] Paced (**C**) and intrinsic (**D**) 12-lead ECGs for case 2 (leads half-standard). The paced QRS axis and duration are nearly identical to intrinsic values, with a z score of +2.5.

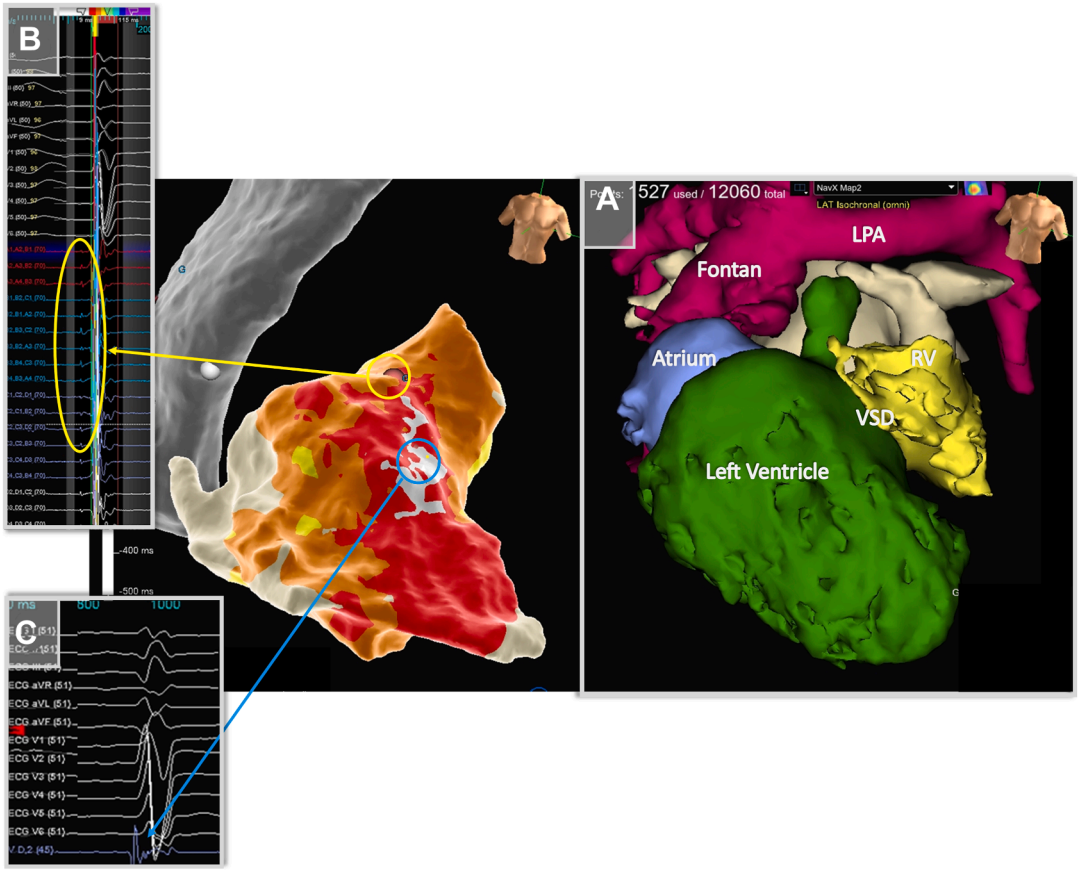

Figure 3 Case 2 electroanatomic map (EAM) with notable locations tagged. (**A**) The EAM was referenced to the cardiac computed tomography data. At (**B**), electrograms recorded by the HD Grid catheter anterior to the ventricular septal defect (VSD) demonstrated conduction system potentials. The lead was implanted at (**C**), just apical to the VSD, and recorded a sharp pre-QRS fascicular potential. LPA = left pulmonary artery; RV = right ventricle.

found to have a 3.8 times higher risk of transplantation or death than do matched nonpaced patients, with this outcome occurring in 22.1% of the paced cohort over a median follow-up of 7.0 years. QRS complex duration z score was identified as a risk factor for the primary outcome in univariable and multivariable analyses, highlighting the importance of electromechanical synchrony in avoiding this form of pacemaker morbidity. Implanting the ventricular pacing lead in the conduction system is a well-established technique in patients with normal cardiac anatomy to achieve narrow QRS complex and electromechanical synchrony, which appears to be at least as good as biventricular pacing in patients with reduced ejection fraction.[2] There is a reason to believe that this benefit would extend to patients with single ventricle physiology. The potential to improve on the poor outcomes associated with pacing a single ventricle is significant.

Any potential benefit from improved electromechanical synchrony with this technique will need to be balanced with the long-term risk of systemic thromboembolism, which may not be trivial, and the burden of lifelong anticoagulation, which we consider mandatory. There are insufficient data on systemic ventricular pacemaker implants after Fontan operation to accurately estimate this risk. The few reported cases do not include reports of stroke during short follow-up,[3–12] though we are aware of anecdotes of stroke in patients with single ventricles and arterial pacing hardware, including while on anticoagulation. Pacemaker leads in the venous

Table 2 Electrical measures for ventricular pacing system described in case 2

Days from implantation	Threshold (V @ 0.4 ms)	Impedance (Ω)	R wave (mV)	Estimated longevity (y)	Atrial pacing (%)	Ventricular pacing (%)
0	0.5	760	15	–	–	–
1	0.5	646	12.3	–	0.5	99.9
3	0.625	551	–	11.6	4.7	99.8
6	0.75	570	–	11.5	5.5	99.9
10	1	570	15.3	11.6	18	100

All variables were measured in the bipolar configuration, with chronic programming in DDD mode and a lower rate limit of 70 beats/min.

Fontan circuit have been associated with higher rates of thrombosis, which can be improved by systemic anticoagulation.[15] However, with different flow dynamics and lead exposure to the arterial bloodstream, the rates may be different in the systemic circulation, analogous to the higher rates of mechanical valve thrombosis in the venous vs arterial circulation.[16] The ALternate Site Cardiac ReSYNChronization study[17] evaluated transseptal endocardial left ventricular pacing for cardiac resynchronization in a cohort of biventricular anatomy patients and reported strokes and transient ischemic attacks in 2.5 and 7.4 events per 100 patient-years, respectively. Subtherapeutic international normalized ratio was reported in 86% of events, and no event led to severe disability. With limited evidence available, we have elected to use rivaroxaban to maximize adherence and minimize variability in the level of anticoagulation, though this approach could be debated. Additional long-term incremental risks, including extraction of a transbaffle lead and the risk of rising thresholds, are similarly unknown.

The Fontan operation is a heterogeneous operation used for many forms of univentricular heart disease, with variable conduction system anatomy. By using electroanatomic mapping, a technique that has been previously established as an adjunctive tool for targeting pacemaker lead implant in congenital heart disease[18] and CSP,[19] we were able to survey the ventricular endocardial surface for conduction system potentials and directly visualize the location of the lead relative to these potentials. In case 2, mapping with a multipolar catheter improved visualization. Still, transvenous CSP may not be an option for all patients with single ventricles. Notably, both patients had a systemic left ventricle, with a morphologic left bundle as the pacing target. Extending this technique to patients with a single right ventricle, where the narrower and more fragile right bundle is the target, may not be feasible or yield as desirable an electromechanical result. The approach to the systemic atrium is also dependent on the type of Fontan operation and prosthetic materials present and may not always be possible.

Conclusion

Transvenous CSP can be achieved in certain patients who underwent a Fontan operation via a transbaffle approach, with electroanatomic mapping resulting in excellent electromechanical synchrony. Additional study is required to evaluate long-term heart failure outcomes, lead function, and, importantly, the risk of systemic thromboembolism associated with this approach.

Acknowledgments

The authors acknowledge Sarah McGraw of Abbott Inc. for providing the maps and electroanatomic mapping images for both cases.

Funding Sources: This research did not receive any specific grant from funding agencies in the public, commercial, or not-for-profit sectors.

Disclosures: Dr Hale has received consulting fees from Philips Medical. All other authors have no conflicts of interest.

References

1. Chubb H, Bulic A, Mah D, et al. Impact and modifiers of ventricular pacing in patients with single ventricle circulation. J Am Coll Cardiol 2022; 80:902–914.
2. Ferreira Felix I, Collini M, Fonseca R, et al. Conduction system pacing versus biventricular pacing in heart failure with reduced ejection fraction: a systematic review and meta-analysis of randomized controlled trials. Heart Rhythm 2024; 21:881–889.
3. Huntley GD, Deshmukh AJ, Warnes CA, Kapa S, Egbe AC. Longitudinal outcomes of epicardial and endocardial pacemaker leads in the adult Fontan patient. Pediatr Cardiol 2018;39:1476–1483.
4. Segar DE, Maldonado JR, Brown CG, Law IH. Transvenous versus epicardial pacing in Fontan patients. Pediatr Cardiol 2018;39:1484–1488.
5. Randall JT, Aldoss OT, Law IH, Divekar AA. Novel direct approach for placement of permanent transvenous pacing leads after Fontan procedure. Ann Pediatr Cardiol 2018;11:187–190.
6. Umamaheshwar KL, Singh AS, Sivakumar K. Endocardial transvenous pacing in patients with surgically palliated univentricular hearts: a review on different techniques, problems and management. Indian Pacing Electrophysiol J 2019; 19:15–22.
7. DeWitt E, Callahan R, Blume E, Marshall A, Mah D. Trans-Fontan baffle placement of an endocardial systemic ventricular pacing lead. HeartRhythm Case Rep 2016;3:129–132.
8. Goulden CJ, Khanra D, Llewellyn J, Rao A, Evans A, Ashrafi R. Novel approaches for leadless pacemaker implantation in the extra-cardiac Fontan cohort: options to avoid leaded systems or epicardial pacing. J Cardiovasc Electrophysiol 2023;34:2386–2392.
9. Das S, Boe BA, Saef J, et al. Leadless pacemaker implantation in Fontan patients with multimodality imaging: tips and tricks. J Innov Card Rhythm Manag 2024; 15:5990–5996.
10. Calvert P, Yeo C, Rao A, Neequaye S, Mayhew D, Ashrafi R. Transcarotid implantation of a leadless pacemaker in a patient with Fontan circulation. HeartRhythm Case Rep 2022;9:53–58.
11. Ferrero P, Yeong M, D'Elia E, Duncan E, Graham Stuart A. Leadless pacemaker implantation in a patient with complex congenital heart disease and limited vascular access. Indian Pacing Electrophysiol J 2016;16:201–204.
12. Dunne L, Breatnach C, Walsh KP. Systemic ventricular implantation of a leadless pacemaker in a patient with a univentricular heart and atrioventricular node calcification. HeartRhythm Case Rep 2020;6:265–267.
13. Vlach M, Reddy M, Serfas JD, Chang PM, Noheria A. Left bundle branch area pacing in complex congenital heart disease—overcoming access limitations in patients with unconventional central venous anatomy. HeartRhythm Case 2025;11:731–736.
14. Chubb H, Ceresnak SR, Motonaga KS, Dubin AM. A proposed method for the calculation of age-dependent QRS duration z-scores. J Electrocardiol 2020; 58:132–134.
15. Assaad IE, Pastor T, O'Leary E, et al. Atrial pacing in Fontan patients: the effect of transvenous lead on clot burden. Heart Rhythm 2021;18:1860–1867.
16. Dangas GD, Weitz JI, Giustino G, Makkar R, Mehran R. Prosthetic heart valve thrombosis. J Am Coll Cardiol 2016;68:2670–2689.
17. Morgan JM, Biffi M, Gellér L, et al. ALternate Site Cardiac ResYNChronization (ALSYNC): a prospective and multicentre study of left ventricular endocardial pacing for cardiac resynchronization therapy. Eur Heart J 2016; 37:2118–2127.
18. Pompa AG, Hale BW. Use of an electroanatomic mapping system with high-density multipolar mapping catheters to guide transvenous atrial pacing lead implantation in a Fontan patient. HeartRhythm Case Rep 2023; 10:49–52.
19. León-Salas B, Infante-Ventura D, Hernández-Yumar A, et al. Conduction system pacing using electro-anatomical mapping-guided system vs. fluoroscopy: a systematic review, meta-analysis and economic evaluation. Front Cardiovasc Med 2025;11:1519127.