

Combatting COVID-19: is ultrasound an important piece in the diagnostic puzzle?

Cian McDermott ,^{1,2} Joseph Daly ,^{1,2} Simon Carley ^{3,4}

Handling editor Ed Benjamin Graham Barnard

► Additional material is published online only. To view please visit the journal online (<http://dx.doi.org/10.1136/emmermed-2020-209721>).

¹Department of Emergency Medicine, Mater Misericordiae University Hospital, Dublin, Ireland

²The Pillar Centre for Transformative Healthcare, Mater Misericordiae University Hospital, Dublin, Ireland

³Department of Emergency Medicine, Central Manchester and Manchester Children's University Hospitals NHS Trust, Manchester, UK

⁴Department of Emergency Medicine, Manchester Metropolitan University - All Saints Campus, Manchester, UK

Correspondence to

Dr Cian McDermott, Emergency Medicine, Mater Misericordiae University Hospital, Dublin D07 R2WY, Ireland; cianmcdermott@gmail.com

Received 8 April 2020

Revised 10 August 2020

Accepted 18 August 2020

ABSTRACT

The current COVID-19 pandemic is causing diagnostic and risk stratification difficulties in Emergency Departments (ED) worldwide. Molecular tests are not sufficiently sensitive, and results are usually not available in time for decision making in the ED. Chest x-ray (CXR) is a poor diagnostic test for COVID-19, and computed tomography (CT), while sensitive, is impractical as a diagnostic test for all patients. Lung ultrasound (LUS) has an established role in the evaluation of acute respiratory failure and has been used during the COVID-19 outbreak as a decision support tool. LUS shows characteristic changes in viral pneumonitis, and while these changes are not specific for COVID-19, it may be a useful adjunct during the diagnostic process. It is quick to perform and repeat and may be done at the bedside. The authors believe that LUS can help to mitigate uncertainty in undifferentiated patients with respiratory symptoms. This review aims to provide guidance regarding indications for LUS, describe the typical sonographic abnormalities seen in patients with COVID-19 and provide recommendations around the logistics of performing LUS on patients with COVID-19 and managing the infection control risk of the procedure. The risk of anchoring bias during a pandemic and the need to consider alternative pathologies are emphasised throughout this review. LUS may be a useful point-of-care test for emergency care providers during the current COVID-19 pandemic if used within a strict framework that governs education, quality assurance and proctored scanning protocols.

INTRODUCTION

COVID-19 is caused by the novel coronavirus SARS-CoV-2, first described in Wuhan, China, in late 2019. The disease was declared a global pandemic on 11 March 2020. Diagnosis of cases and risk stratification of those with symptoms has been a challenge for healthcare systems worldwide owing to the limited number of available diagnostic tests and/or the poor sensitivity of those tests.

Formal diagnosis of COVID-19 can be obtained via polymerase chain reaction (PCR) testing of respiratory secretion samples.¹ However, the sensitivity of PCR for naso-oropharyngeal swab samples is reported to be as low as 70% at initial presentation, and this figure is reduced if proper specimen collection technique is not adhered to.² CXR may suggest COVID-19, but patients can have a range of changes, or absence of any changes, on plain imaging that may result in diagnostic uncertainty. CT imaging of the thorax has been suggested as a potential diagnostic modality owing to its increased sensitivity relative to PCR and CXR, and the fact

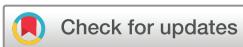that CT findings can be identified more rapidly than PCR testing can be performed.³ However, CT is impractical as a diagnostic test for all patients presenting with COVID-19 symptoms.

Clinicians are frequently left with a degree of uncertainty as to the actual diagnosis in the initial hours and sometimes days of treating patients with suspected COVID-19. LUS has been proposed as a diagnostic aid and risk stratification tool. LUS is known to be more sensitive than CXR in the diagnosis of interstitial patterns including pulmonary oedema, consolidation and effusions.⁴ Preliminary studies show that there are characteristic sonographic pleuropathic findings of COVID-19.^{5,6} Although LUS is unlikely to replace PCR as a confirmatory test, it has the potential to be faster, repeatable and to contribute additional clinical information at the time of care. There is also a risk of anchoring bias towards a diagnosis of COVID-19 during the current pandemic, and LUS combined with focused cardiac ultrasound may be useful to identify alternative pathologies resulting in respiratory failure. The management of critically unwell patients with suspected COVID-19 may be altered where features suggestive of pulmonary embolism (PE) or superimposed bacterial pneumonia are identified using point-of-care ultrasound.

Traditional literature sources may struggle to keep pace with the latest available information during a rapidly evolving pandemic situation. Every effort has been made to source evidence for this review from peer-reviewed publications. A thorough review of the available literature was conducted using the MEDLINE, Embase, Scopus and The Cochrane Library databases. Prepublication servers such as Social Science Research Network, figshare.com and medRxiv.org are often used to rapidly disseminate preliminary information ahead of the peer-review process, and they were found to be of use in conducting this review. Some of the information in this article has been 'crowdsourced' or extrapolated from shared knowledge of global expert user groups. There are many innovative approaches to use of LUS in COVID-19 available on social media, collated under the twitter hashtag #POCUSforCOVID, and on specialist point-of-care ultrasound websites.^{7,8} The authors acknowledge that this is a novel and non-traditional approach to the evidence-gathering process.

CHEST IMAGING FOR COVID-19

Chest imaging is important for diagnostic and prognostic reasons in patients with suspected COVID-19. The ideal test would be quick, reliable, reproducible, deliverable at the bedside and has



© Author(s) (or their employer(s)) 2020. No commercial re-use. See rights and permissions. Published by BMJ.

To cite: McDermott C, Daly J, Carley S. *Emerg Med J* Epub ahead of print: [please include Day Month Year]. doi:10.1136/emmermed-2020-209721

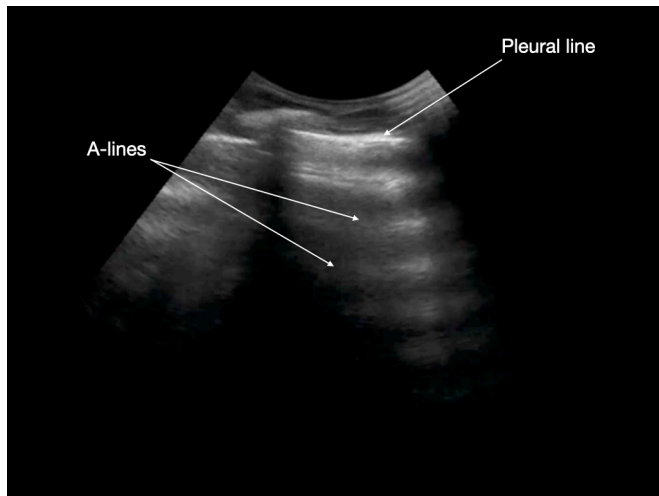


Figure 1 Normal anterior lung. Pleural line is sharp, smooth and lies inferior to and bordered on each side by dark rib shadows. A-lines appear as horizontal bright lines inferior to the pleural line and equidistant from the transducer.

high sensitivity and specificity. Most patients will receive a chest radiograph; however, CXR has poor sensitivity as compared with CT and LUS. CXR may miss up to 40% of confirmed COVID-19 cases.^{5,9} The reason for the reported low sensitivity of plain radiography is that virus particles are small and lodge in terminal alveoli close to the pleural interface. These areas are well visualised on CT and LUS but are more difficult to see on plain imaging.⁶

Thoracic CT has been proposed as a primary screening tool for COVID-19 detection since it performs better than PCR.^{2,3,10} The sensitivity of CT findings for COVID-19 is thought to be between 88% and 97%, whereas PCR of nasopharyngeal swabs is believed to have a sensitivity of approximately 72%.^{3,9} However, CT is a finite resource and may be unavailable in some healthcare settings. There is significant radiation exposure for patients, especially in vulnerable groups such as children and pregnant women.^{11,12} Decontamination protocols are not well defined and are time consuming. The practicalities of moving critically ill patients to CT are difficult, and thus a risk-benefit approach should be taken, reserving this technology for patients with complications of COVID-19 infection or when other causes of illness such as PE are suspected.¹³

Because most lung pathology in COVID-19 occurs peripherally at the terminal alveoli, it may be evaluated using LUS. Although not unique to COVID-19, LUS has unique sonographic findings^{5,6,14} in viral pneumonia, which should be detectable for those trained and skilled in performing and interpreting LUS. False-negative LUS results may be obtained in atypical cases of COVID-19 where lesions are located centrally in the lung and therefore not adjacent to the pleura. LUS is a bedside test that is quick to perform and repeat, is low cost and avoids radiation exposure compared with thoracic CT.^{5,15} Studies indicate that the sensitivity of LUS for COVID-19 diagnosis is close to 100% when performed by experienced operators, with a specificity of approximately 78.6%.¹⁶ The relatively low specificity of LUS when compared with thoracic CT is because some sonographic findings suggestive of viral pneumonia can also be seen in chronic lung conditions resulting in pleural abnormalities, including pulmonary fibrosis and chronic obstructive pulmonary disease. This necessitates using LUS in conjunction with other confirmatory tests such as PCR.

LIMITATIONS TO USING LUS FOR COVID-19

A number of limitations to LUS use during the current COVID-19 pandemic exist. Many EDs will lack an adequate number of portable ultrasound machines to enable widespread use of LUS. Operators are in close contact with suspected cases when performing LUS and may be placed at increased risk of contracting COVID-19. Performing and interpreting LUS is highly operator dependent, and many centres will lack the expertise to implement LUS as a primary imaging modality. We would be concerned if LUS were to be used without adequate training, supervision and governance. Competence in the recognition of B-lines may be achieved in as little as 4 hours of training.¹⁷ A comprehensive education programme that includes image review and clinical integration will take considerably more time, but this will yield increased long-term benefits.

In the first instance, we see LUS in COVID-19 to be adopted by those already familiar with ultrasound techniques and with prior experience of using LUS for the detection of pathologies such as pneumothorax, cardiac failure, infection and effusion. We suggest that local US champions should plan now to enable and upskill current users in COVID-19 pathological features using the resources linked in this article and available online.

Recent studies have shown that the specificity of LUS for COVID-19 lies around 78.6% in ED patients.^{18,19} In a high-prevalence situation such as a pandemic, the majority of positive tests will represent true positives, and this is less important. However, LUS is unable to distinguish early COVID-19 from other viral pneumonitis such as RSV, H1N1²⁰ or H7N9.²¹ In the coming months, if the pendulum swings away from COVID-19 and towards alternate causes of respiratory failure, a rethink of the diagnostic approach of COVID-19 using LUS will be necessary.

LUS ABNORMALITIES IN COVID-19

Sonoanatomy of the normal lung includes sliding of the pleural line, A-line artefacts, B-line artefacts and a smooth, sharp appearance of the pleural line (figure 1).²² A-lines are a type of long-path reverberation artefact found in the lung. These appear as repetitive, horizontal bright lines deep to the reflective pleural line and air within the lungs. B-lines are short-path non-fatiguing artefacts formed by reverberation of ultrasound waves within a fluid-filled collection (alveolus) that is surrounded by air. These appear as thin, vertical bright lines starting at the pleural line and extending to the lung far field. Up to 3 B-lines per intercostal space may be considered as a normal finding, whereas more than 3 B-lines in multiple intercostal spaces is suggestive of lung pathology. B-lines are found in several conditions including pulmonary oedema, viral pneumonitis, acute respiratory distress syndrome (ARDS), pulmonary fibrosis and pulmonary contusion.

Abnormal LUS findings in COVID-19 pneumonitis^{5,6,23}:

- ▶ Significant lung involvement is unlikely if an A-line pattern is noted (figure 1).
- ▶ Small localised peripheral consolidations (less than 1.5 cm) appear as dark areas immediately inferior to the pleural line (figure 2).
- ▶ A pleuropathy develops as the pleural line appears coarse, irregular and fragmented (figure 2). Skip lesions may appear as normal pleura lies alongside thickened pleura (patchy areas). Similar changes may also be seen in chronic lung conditions such as idiopathic pulmonary fibrosis. Skip lesions may appear as normal pleura lies alongside thickened pleura (patchy areas).

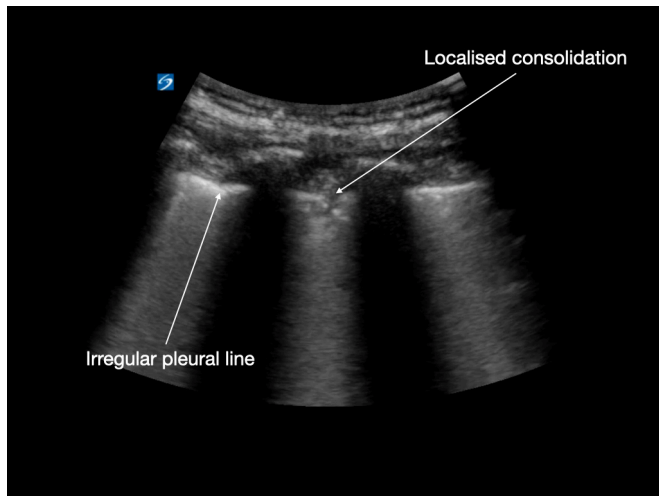


Figure 2 Small, peripheral localised consolidation and irregular pleural line appearance.

- ▶ B-lines appear in focal, multifocal and confluent patterns. They can initially be seen at the postero-lateral lung bases. As disease severity increases, B-lines increase in number and occur closer together (confluent pattern) at sites distant from the lung bases (figure 3). A broad, band-shaped vertical B-line pattern ('light beam' artefact) is thought to be representative of early COVID-19 disease.²³
- ▶ As increasing amounts of inflammatory fluid fills the alveoli, areas of consolidated lung appear (hepatisation) especially at the lung bases (figure 4). Residual air may be trapped in the bronchi; this is known as a sonographic air bronchogram.
- ▶ Large volume pleural effusions are uncommon; if these are seen, alternative lung pathology should be considered. Bacterial superinfection is suggested by basal consolidations with dynamic air bronchograms, reduced pleural sliding and the presence of pleural effusions. This ultrasound finding may guide the decision to initiate antibiotics.²⁴

Characteristic sonographic patterns on LUS may help categorise patients into groups with low probability, moderate probability, high probability and a further group with alternate pathology other than COVID-19.²³ Accurate interpretation may

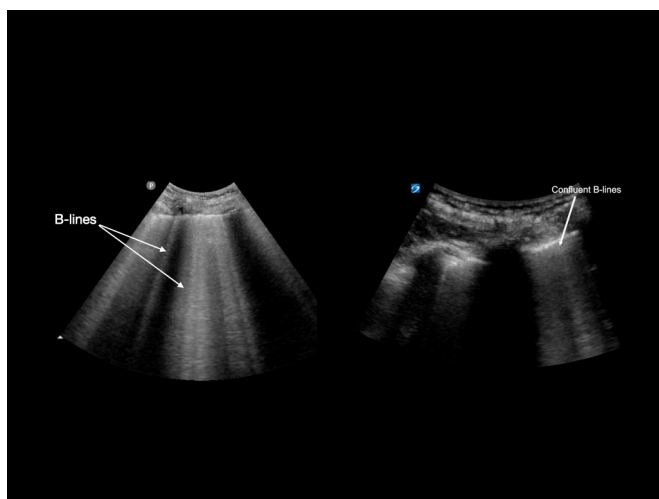


Figure 3 Left: discrete B-lines arising from a thin pleural line (most often cardiogenic). Right: confluent B-lines as may be seen in COVID-19 pneumonitis.

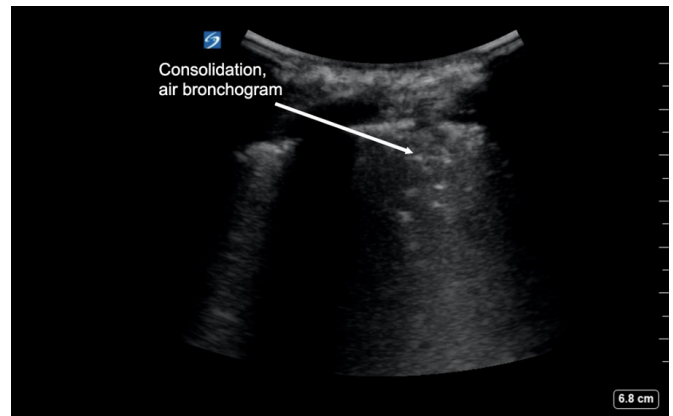


Figure 4 Larger consolidation stippled with air bronchogram, typical of more advanced lung changes seen in COVID-19.

present a challenge to novice operators since there is a degree of subjectivity involved in these classifications. It is not uncommon to encounter patients with few respiratory symptoms that have severe abnormalities on LUS. The converse is not usually true—few patients with severe respiratory failure will have a normal LUS. LUS findings seem to peak in severity 2 weeks after the onset of symptoms and regress gradually afterwards.²⁵

Further research is needed to clarify the diagnostic and prognostic role of LUS in COVID-19. Investigators at the University of Pennsylvania are currently undertaking the Prognostic Value of Point of Care Cardiac and Lung Ultrasound in COVID-19 (CLUSCO) study to examine the potential role of LUS in predicting outcomes of patients with COVID-19.²⁶ Such studies are needed to provide an evidence base for incorporation of LUS into practice during the current pandemic.

PATIENT SELECTION FOR LUS DURING THE COVID-19 PANDEMIC

The role of LUS during the COVID-19 pandemic is to identify characteristic sonographic abnormalities as well as to support clinical decision making. Not all patients with clinically suspected COVID-19 will warrant LUS, and appropriate patient selection is essential to minimise unnecessary exposure of health-care workers (HCWs) to this virus. LUS should be performed after the medical history is taken, when a specific clinical question arises and with a pretest probability of COVID-19 diagnosis already in mind.

- ▶ The majority of patients who are clinically well and fit for discharge are unlikely to benefit from LUS, as they will be managed based on clinical appearance.
- ▶ In clinically well patients with risk factors for severe COVID-19 (such as chronic lung disease, obesity, diabetes mellitus or cardiovascular disease), abnormal LUS findings may identify a patient cohort that would benefit from closer observation such as a home pulse oximeter and remote monitoring.
- ▶ Critically ill patients should be resuscitated without delay, and LUS is not useful for the primary diagnosis of COVID-19. Ultrasound is useful in critically unwell patients to examine for other causes of undifferentiated shock, for example, PE, cardiac tamponade or hypovolaemia, thus avoiding anchoring bias in the midst of the current pandemic.
- ▶ Goal-directed focused cardiac ultrasound may help identify left ventricular and right ventricular size and function in the case of COVID-19 heart–lung complications, which

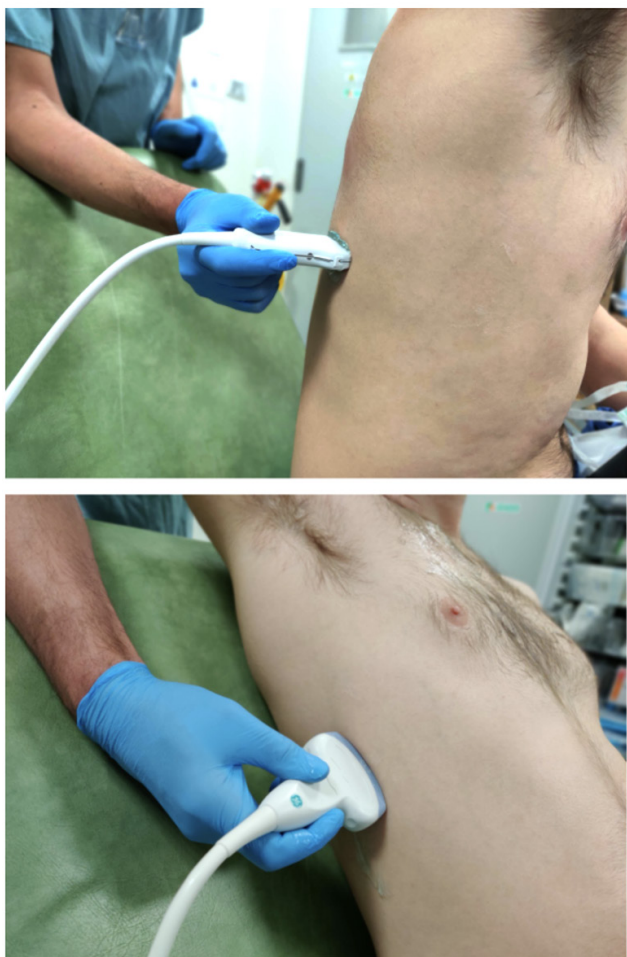


Figure 5 Transverse orientation with linear transducer between ribs in the intercostal space (top). Sagittal/longitudinal orientation with curvilinear transducer across ribs in the intercostal space (bottom).

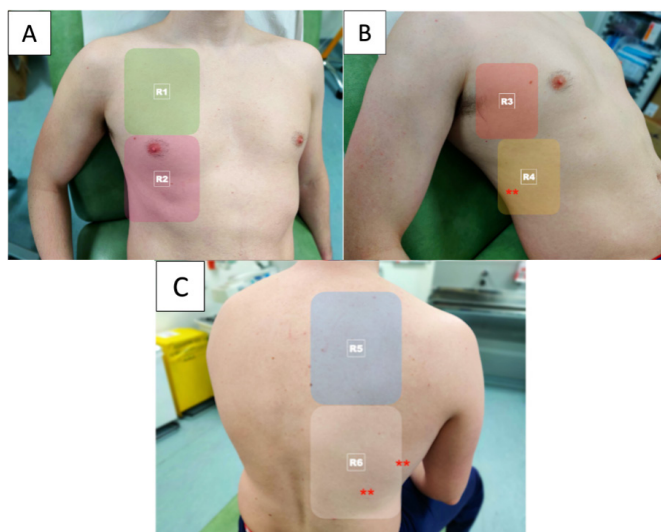


Figure 6 The 12-zone technique for LUS in suspected COVID-19. (A) Right anterior zones, (B) right lateral zones and (C) right posterior zones. Early pathology tends to occur at the postero-basal lung zones, and these should be areas for particular scrutiny (marked with asterisks). In comparison, the FUSIC protocol uses three zones on each side of the chest: two anterior zones (R1+R2) and one posterolateral zone (R4).²³

include myocarditis, right-sided and left-sided heart failure and PE.^{27 28}

- ▶ Ultrasound can also be used to assess volume status and guide fluid resuscitation where necessary.²⁹
- ▶ Ultrasound can be used to assist with emergency central or peripheral venous access.

LUS SCANNING TECHNIQUE

In general, principles and techniques of LUS are the same for patients with suspected COVID-19 as they were in the pre-COVID-19 era. Some modifications necessary for patients with suspected COVID-19 will also be outlined.

Transducer selection³⁰

- ▶ Linear transducers (5–10 MHz) are better for visualising superficial structures (figure 5). These may be used to view pleural line irregularities, small superficial effusions, skip lesions and B-lines.
- ▶ Curvilinear transducers (2–7 MHz) may be better for posterior and deeper or central pathology such as consolidation, hepatisation and air or fluid bronchograms.

Optimising settings

- ▶ Optimise the depth of field of view so that the pleural line is in the middle of the screen.
- ▶ Adjust the transducer focal zone to the level of the pleural line for increased spatial resolution.
- ▶ Turn off smoothing algorithms such as compounding and tissue harmonic imaging filters to allow visualisation of lung artefacts. Most lung presets will default to this mode.
- ▶ Record cine loop clips rather than still images to visualise subtle pleural changes that may not appear on a single frame.

Transducer hold

Hold the transducer close to the crystal matrix, between the tips of the index finger and the thumb of the insonating hand (figure 5). Fingers of the insonating hand should be spread out to stabilise the transducer and hand position. Brace the insonating hand against the surface being scanned. These techniques will facilitate small adjustments of the transducer and will allow for greater probe stability and better quality images to be shown on the screen.

Scanning protocol

Traditional lung scanning protocols suggest evaluation of several anterior, lateral and posterior lung zones. Chinese authors have described COVID-19 scanning using a 12-zone protocol (figure 6).⁶ Soldati *et al*³⁰ have proposed a 9-zone protocol and associated scoring system to quantify pulmonary involvement. It is possible to perform a focused study (six chest zones) in less than 2 min,³¹ and the Intensive Care Society has endorsed this approach as part of the Focused Ultrasound in Intensive Care (FUSIC) lung accreditation module (figure 6).³²

Modifications to minimise exposure risk

COVID-19 changes are often found in postero-basal zones.^{6 30} It may be quicker and safer for the point-of-care ultrasound provider to:

- ▶ Scan with the patient facing away from the operator to minimise healthcare worker (HCW) exposure to droplets (figure 5). The ultrasound machine may also become less contaminated if placed behind the patient.

- ▶ Start by scanning the patient's back using the linear transducer in vertical orientation.
- ▶ Start medial to the scapula sliding inferior to the lower rib border and moving laterally towards the posterior axillary line.
- ▶ Evaluate each rib space first with the transducer in a vertical (crossing the ribs) orientation (figure 5) then evaluate each rib space again with the transducer in a horizontal orientation (between the ribs) especially if any abnormalities are seen.
- ▶ Finish by scanning lateral zones of the lung in the midaxillary line. Using the curvilinear probe here may be helpful (figure 5).

Cleaning and disinfection protocols

Strict adherence to decontamination strategies are vital to prevent patient-to-patient COVID-19 transmission as well as patient-to-HCW transmission. What follows are summary points drawn from a number of international best practice standards^{33 34} and should be considered when using ultrasound with suspected COVID-19 patients:

- ▶ Place a dedicated ultrasound machine in the COVID-19 'hot zone' of the ED.
- ▶ Wear standard personal protective equipment when performing LUS and wear gloves when moving the machine between cubicles.
- ▶ Strip away ECG leads, gel bottles, extra buckets and straps from the machine.
- ▶ Use a barcode scanner to enter patient details to avoid further contact with the machine.
- ▶ Use the machine in battery mode; precharge at all times to avoid use of cables.
- ▶ Use a touchscreen device rather than a keyboard, cart-based system.
- ▶ Consider using a handheld device, for example, Lumify or ButterflyIQ systems, with the advantage that the whole device can be placed within a probe cover and images are uploaded to the cloud for remote reviewing.
- ▶ Consider use of a transparent, disposable drape to cover the screen, cradle and cart of the ultrasound machine.
- ▶ Use chlorhexidine/alcohol or soap-based wipes to clean transducer heads, as well as the entire length of probe cables, screen and cart after scanning.³⁵ Wait for up to 3 min 'dry time' after using disinfectant wipes before using the machine again.
- ▶ Use a transducer sheath/probe cover for all high-risk patients.
- ▶ Use single-use gel packets rather than gel bottles.

CONCLUSION

LUS appears promising as a comprehensive imaging modality in clinically suspected or diagnosed COVID-19, when implemented mindfully and in conjunction with other diagnostic modalities. LUS findings should be interpreted alongside a careful history, physical examination and with pretest probability in mind. Point-of-care ultrasound may help to identify the need for further investigations or may guide the physician towards an alternative diagnosis.

Incorporating ultrasound into the evaluation of COVID-19 patients will depend on available resources, expertise of personnel and logistic configurations unique to each situation.

Twitter Cian McDermott @cianmcdermott, Joseph Daly @josephdaly111 and Simon Carley @EMManchester

Contributors All authors have contributed to the design of the paper, the writing of the manuscript and have seen and approved the final manuscript; they all meet the definition of an author as stated by the International Committee of Medical Journal Editors.

Funding The authors have not declared a specific grant for this research from any funding agency in the public, commercial or not-for-profit sectors.

Competing interests None declared.

Patient and public involvement Patients and/or the public were not involved in the design, or conduct, or reporting, or dissemination plans of this research.

Patient consent for publication Not required.

Provenance and peer review Not commissioned; externally peer reviewed.

This article is made freely available for use in accordance with BMJ's website terms and conditions for the duration of the covid-19 pandemic or until otherwise determined by BMJ. You may use, download and print the article for any lawful, non-commercial purpose (including text and data mining) provided that all copyright notices and trade marks are retained.

ORCID iDs

Cian McDermott <http://orcid.org/0000-0003-2017-8669>

Joseph Daly <http://orcid.org/0000-0003-1412-2247>

Simon Carley <http://orcid.org/0000-0003-1561-5553>

REFERENCES

- 1 Watson J, Whiting PF, Brush JE. Interpreting a covid-19 test result. *BMJ* 2020;369:m1808.
- 2 Fang Y, Zhang H, Xie J, *et al.* Sensitivity of chest CT for COVID-19: comparison to RT-PCR. *Radiology* 2020;296:E115–7.
- 3 Ai T, Yang Z, Hou H, *et al.* Correlation of chest CT and RT-PCR testing for coronavirus disease 2019 (COVID-19) in China: a report of 1014 cases. *Radiology* 2020;296:E32–40.
- 4 Tierney DM, Huelster JS, Overgaard JD, *et al.* Comparative performance of pulmonary ultrasound, chest radiograph, and CT among patients with acute respiratory failure. *Crit Care Med* 2020;48:151–7.
- 5 Peng Q-Y, Wang X-T, Zhang L-N, *et al.* Findings of lung ultrasonography of novel corona virus pneumonia during the 2019-2020 epidemic. *Intensive Care Med* 2020;46:849–50.
- 6 Huang Y, Wang S, Liu Y, *et al.* A preliminary study on the ultrasonic manifestations of peripulmonary lesions of non-critical novel coronavirus pneumonia (COVID-19). *SSRN Electronic Journal* 2020.
- 7 Ultrasound gel. Available: <http://ultrasoundgel.org> [Accessed 3 Jun 2020].
- 8 Diagnostic ultrasound training for medical doctors. Available: <http://ultrasoundtraining.com> [Accessed 3 Jun 2020].
- 9 Guan W-J, Z-Y N, Hu Y, *et al.* Clinical characteristics of coronavirus disease 2019 in China. *N Engl J Med* 2020.
- 10 Xie X, Zhong Z, Zhao W, *et al.* Chest CT for typical 2019-nCoV pneumonia: relationship to negative RT-PCR testing. *Radiology* 2020;200343.
- 11 Moro F, Buonsenso D, Moruzzi MC, *et al.* How to perform lung ultrasound in pregnant women with suspected COVID-19. *Ultrasound Obstet Gynecol* 2020;55:593–8.
- 12 Denina M, Scolfaro C, Silvestro E, *et al.* Lung ultrasound in children with COVID-19. *Pediatrics* 2020;146:e20201157.
- 13 The Royal College of Radiologists. The role of CT in patients suspected with COVID-19 infection. Available: <https://www.rcr.ac.uk/college/coronavirus-covid-19-what-rcr-doing/clinical-information/role-ct-chest/role-ct-patients> [Accessed 3 Jun 2020].
- 14 Poggiali E, Dacrema A, Bastoni D, *et al.* Can lung us help critical care clinicians in the early diagnosis of novel coronavirus (COVID-19) pneumonia? *Radiology* 2020;295:E6.
- 15 Mayo PH, Copetti R, Feller-Kopman D, *et al.* Thoracic ultrasonography: a narrative review. *Intensive Care Med* 2019;45:1200–11.
- 16 Tung-Chen Y, Marti de Gracia M, Díez-Tascón A, *et al.* Correlation between chest computed tomography and lung ultrasonography in patients with coronavirus disease 2019 (COVID-19). *Ultrasound Med Biol* 2020. doi:10.1016/j.ultrasmedbio.2020.07.003
- 17 Baker K, Rippey J. Lung ultrasound in a COVID pandemic – choosing wisely. *Australas J Ultrasound Med* 2020;15.
- 18 Lu W, Zhang S, Chen B, *et al.* A Clinical Study of Noninvasive Assessment of Lung Lesions in Patients with Coronavirus Disease-19 (COVID-19) by Bedside Ultrasound. *Ultraschall Med* 2020;41:300–7.
- 19 Lomoro P, Verde F, Zerboni F, *et al.* COVID-19 pneumonia manifestations at the admission on chest ultrasound, radiographs, and CT: single-center study and comprehensive radiologic literature review. *Eur J Radiol Open* 2020;7:100231.
- 20 Tsung JW, Kessler DO, Shah VP. Prospective application of clinician-performed lung ultrasonography during the 2009 H1N1 influenza A pandemic: distinguishing viral from bacterial pneumonia. *Crit Ultrasound J* 2012;4:16.

- 21 Zhang Y-K, Li J, Yang J-P, *et al.* Lung ultrasonography for the diagnosis of 11 patients with acute respiratory distress syndrome due to bird flu H7N9 infection. *Virology* 2015;12:176.
- 22 Miller A. Practical approach to lung ultrasound. *BJA Educ* 2016;16:39–45.
- 23 Volpicelli G, Lamorte A, Villén T. What's new in lung ultrasound during the COVID-19 pandemic. *Intensive Care Med* 2020;46:1445–8.
- 24 Convissar DL, Gibson LE, Berra L, *et al.* Application of lung ultrasound during the COVID-19 pandemic: a narrative review. *Anesth Analg* 2020;131:345–50.
- 25 Xing C, Li Q, Du H, *et al.* Lung ultrasound findings in patients with COVID-19 pneumonia. *Crit Care* 2020;24:174.
- 26 Penn ultrasound. Available: <https://pennultrasound.org/clusco> [Accessed 4 Jun 2020].
- 27 Bonow RO, Fonarow GC, O'Gara PT, *et al.* Association of coronavirus disease 2019 (COVID-19) with myocardial injury and mortality. *JAMA Cardiol* 2020. doi:10.1001/jamacardio.2020.1105
- 28 Tavazzi G, Pellegrini C, Maurelli M, *et al.* Myocardial localization of coronavirus in COVID-19 cardiogenic shock. *Eur J Heart Fail* 2020;22:911–5.
- 29 Koratala A, Ronco C, Kazory A. Need for objective assessment of volume status in critically ill patients with COVID-19: the Tri-POCUS approach. *Cardiorenal Med* 2020;10:1–8.
- 30 Soldati G, Smargiassi A, Inchingolo R, *et al.* Proposal for international standardization of the use of lung ultrasound for COVID-19 patients; a simple, quantitative, reproducible method. *J Ultrasound Med* 2020.
- 31 Cox EGM, Wiersema R, Wong A, *et al.* Six versus eight and twenty-eight scan sites for B-line assessment: differences in examination time and findings. *Intensive Care Med* 2020;46:1063–4.
- 32 Advanced Solutions International, Inc. FUSIC_Accreditation. Available: https://www.ics.ac.uk/ICS/FUSIC/ICS/FUSIC/FUSIC_Accreditation.aspx?hkey=c88fa5cd-5c3f-4c22-b007-53e01a523ce8 [Accessed 23 Mar 2020].
- 33 Guideline for ultrasound transducer cleaning and disinfection. Available: <https://www.acep.org/patient-care/policy-statements/guideline-for-ultrasound-transducer-cleaning-and-disinfection/> [Accessed 29 Mar 2020].
- 34 Lorentzen T, Nolsøe CP, Ewertsen C, *et al.* EFSUMB guidelines on interventional ultrasound (INVUS), part I. General aspects (long version). *Ultraschall Med* 2015;36:E1–14.
- 35 Shukla B, Howell V, Griffiths A, *et al.* Superiority of chlorhexidine 2%/alcohol 70% wipes in decontaminating ultrasound equipment. *Ultrasound* 2014;22:135–40.