



Comparison of Locking Plate Osteosynthesis versus Coracoclavicular Stabilization for Neer Type IIB Lateral Clavicle Fractures

Beom-Soo Kim, MD, Du-Han Kim, MD, Byung-Chan Choi, MD, Chul-Hyun Cho, MD

Department of Orthopedic Surgery, Keimyung University Dongsan Hospital, Keimyung University School of Medicine, Daegu, Korea

Background: The best option for the treatment of Neer type IIB lateral clavicle fractures remains controversial. The aim of this study was to compare outcomes and complications between pre-contoured locking plate osteosynthesis (PLPO) and coracoclavicular stabilization (CCS) using a TightRope for the treatment of type IIB fractures.

Methods: Forty-six consecutive type IIB fractures were treated with PLPO (17 cases) or CCS (29 cases). The mean follow-up period was 33.7 months (range, 12–144 months). Radiographic outcomes were evaluated using serial plain radiographs. Clinical outcomes were evaluated using the University of California, Los Angeles (UCLA) score, the American Shoulder and Elbow Surgeons (ASES) score, and subjective shoulder value (SSV).

Results: Of the 46 cases, complete bony union within 6 months after surgery was achieved in 42 cases (91.3%). The union rate was 100% (17/17) in the PLPO group and 86.2% (25/29) in the CCS group, showing a statistically significant difference ($p = 0.043$). No significant differences in terms of UCLA score (32.8 vs. 32.1), ASES score (93.2 vs. 90.8), or SSV (89.1% vs. 90.3%) were observed between the PLPO and CCS groups. The complication rates were 17.6% (3/17; 2 cases of screw breakage and 1 case of stiffness) in the PLPO group and 37.9% (11/29; 4 cases of nonunion, 3 cases of stiffness, 2 cases of skin irritation, 1 case of superficial infection, and 1 case of coracoid button migration) in the CCS group, showing no statistically significant difference ($p > 0.05$). Four cases with nonunion after CCS did not require reoperation because they had good to excellent clinical outcomes without radiographic progression.

Conclusions: Although a higher nonunion rate was observed in the CCS group compared with the PLPO group, satisfactory clinical outcomes were obtained for both groups. Both techniques can be regarded as useful options for the treatment of Neer type IIB lateral clavicle fractures.

Keywords: Lateral clavicle, Fracture, Locking plate, TightRope

Lateral clavicle fractures account for 10% to 30% of all clavicle fractures.¹⁾ These fractures are less common than

shaft fractures; however, treatment is often challenging.²⁾ Neer classification, which is based on the relationship of the fracture line to the coracoclavicular (CC) ligament and acromioclavicular (AC) joint, has been widely used in real clinical practice.³⁾ Neer type II lateral clavicle fractures are less stable than type I or III fractures with a higher nonunion rate; therefore, surgical treatment has traditionally been recommended.^{1,2,4)} Type II fractures are subdivided into type IIA and IIB; type IIA fractures arise from medial to the CC ligament, while type IIB fractures arise from more laterally with the CC ligament torn from the medial

Received March 6, 2022; Revised May 19, 2022;

Accepted May 26, 2022

Correspondence to: Chul-Hyun Cho, MD

Department of Orthopedic Surgery, Keimyung University Dongsan Hospital, Keimyung University School of Medicine, 1035 Dalgubeol-daero, Dalseo-gu, Daegu 42601, Korea

Tel: +82-53-258-4771, Fax: +82-53-258-4773

E-mail: oscho5362@dsmc.or.kr

fragment.³⁾

Surgical options for the treatment of unstable type II fractures include pre-contoured locking plate osteosynthesis (PLPO), hook plate fixation, firm or flexible CC stabilization (CCS), tension band wiring, or transacromial intramedullary fixation.^{1,2,4)} There is little controversy regarding treatment of type IIA fractures with PLPO because the lateral fragment is long enough to obtain stability.^{2,4)} However, the best option for the treatment of type IIB fractures remains still controversial. It is not easy to achieve stable fixation in type IIB fractures because the lateral fragment is relatively small. Recent studies reported that CCS using a suture button device or cerclages, PLPO, and hook plate fixation are the latest options for surgical treatment of type IIB fractures.⁵⁻²⁰⁾ Several studies reported that hook plate fixation can be a useful surgical option for achievement of satisfactory clinical results, if the lateral fragment is too small for insertion of screws.^{4,17,21,22)} However, a high complication rate has been reported for hook plate fixation and there is a drawback regarding the need for implant removal within 6 months after surgery.^{4,9,23)} Several authors advocated that PLPO can be a reliable surgical option for treatment of type IIB fractures because it facilitates better stability of the small lateral fragment by multi-planar locking screw fixation.^{4,18,24,25)} A major advantage of PLPO over hook plate fixation is that neither the AC joint nor the subacromial space is violated.^{4,25)} Recently, based on the concept that the CC ligament is a crucial structure for fracture stability and the healing process in type IIB fractures, several studies reported satisfactory clinical and radiographic outcomes after CCS using a suture button device for type IIB fractures.^{5-7,11-13,15,26)}

To date, several comparative studies between these surgical techniques for the treatment of unstable lateral clavicle fractures have been reported.^{9,17,21-23,27)} However, no comparative study between PLPO and CCS using a suture button device for type IIB fractures has been reported. The purpose of this study was to compare outcomes and complications between PLPO and CCS using a TightRope (Arthrex, Naples, FL, USA) for type IIB fractures. This study was conducted to verify the hypothesis that satisfactory clinical outcomes after surgery would be achieved in both groups and the PLPO group would show superior radiographic outcomes compared with the CCS group.

METHODS

The study was approved by Institutional Review Board of Keimyung University Dongsan Hospital (IRB No. 2019-05-055). Written informed consent was obtained.

Seventy-three consecutive cases with Neer type IIB fractures between January 2010 and May 2018 were reviewed retrospectively. Surgical treatment was administered by the senior author (CHC) in all cases. The inclusion criteria were as follows: (1) an adult patient (> 20 years of age), (2) a Neer type IIB fracture, and (3) a minimum follow-up period of 12 months after surgery. The exclusion criteria were as follows: (1) a history of shoulder surgery, (2) previous shoulder problems (e.g., rotator cuff tear, calcific tendinitis, osteoarthritis), or (3) incomplete follow-up period. Out of the 73 patients, 27 patients were excluded due to loss of follow-up (14 cases) and previous shoulder problems (13 cases). Forty-six patients were finally included in this study. The mean age of the patients was 53.0 years and there were 26 men and 20 women. The mean follow-up period was 33.7 months (range, 12–144 months).

Pre-contoured Locking Plate Osteosynthesis

In the PLPO group, 17 cases (13 men and 4 women; mean age of 52.3 years) were treated with a 3.5 mm LCP superior lateral clavicle plate (Acumed, Hillsboro, OR, USA). The mean time from initial trauma to surgery was 5.5 days (range, 1–18 days). A curved incision was made over the lateral clavicle in the beach-chair position. Following exposure of the fracture site, the fracture was reduced using a reduction clamp or temporary Kirschner-wire (K-wire) fixation across the AC joint. The plate was fixed, followed by insertion of as many 2.3-mm lateral locking screws as possible (Fig. 1). Additional cerclage wiring (5 cases) or K-wire tension band technique (3 cases) was used depending on the type of fracture. Wearing Kenny-Howard braces for 6 weeks after surgery, passive range of motion exercise was initiated from 1 to 2 weeks after surgery and active ROM exercise was allowed 6 weeks after surgery. The mean follow-up period was 36.9 months (range, 12–139 months).

CCS Using A Suture Button Device

In the CCS group, 29 cases (16 women and 13 men; mean age of 53.5 years) were treated with CCS using a TightRope. The mean time from initial trauma to surgery was 6.8 days (range, 1–17 days). A 5–6 cm longitudinal incision was made from 1 cm medial to the AC joint to the coracoid process in the beach-chair position. After creating clavicular and coracoid tunnels, the fracture was reduced using cerclage wiring or temporary K-wire fixation. A TightRope was then passed through the clavicular and coracoid tunnels (Fig. 2). The fracture was reduced, and the TightRope device was tightened and secured. In oblique fractures, additional circumferential suture (No.

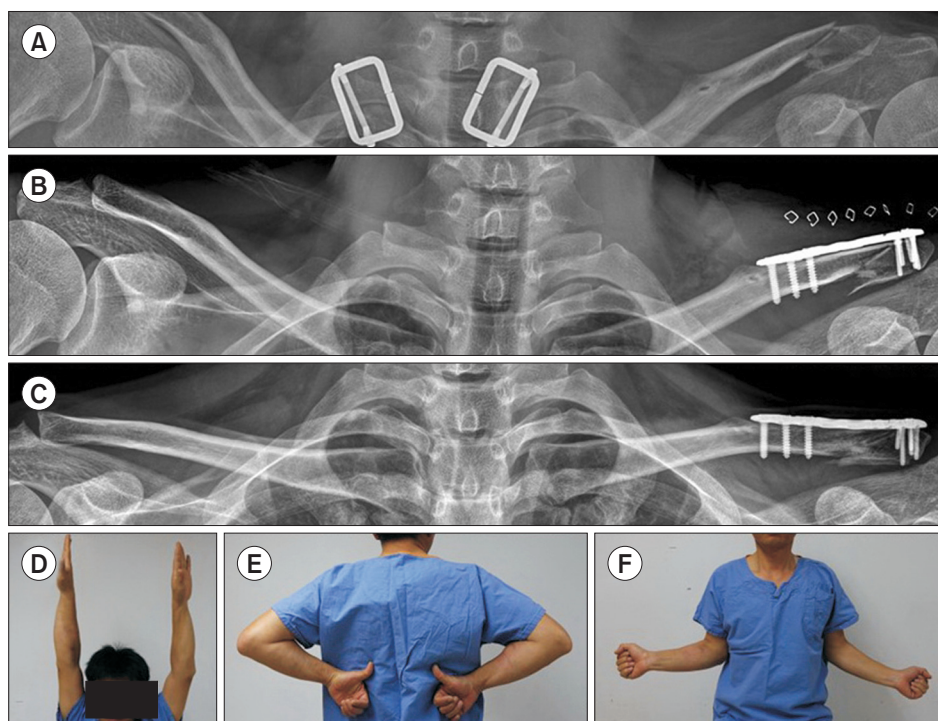


Fig. 1. A 44-year-old man. (A) Plain radiograph at initial trauma showing a Neer type IIB lateral clavicle fracture. (B) Plain radiograph after surgery showing open reduction and internal fixation using a pre-contoured locking plate. Plain radiograph at 6 months after surgery showing fracture healing (C) and satisfactory function (D-F).

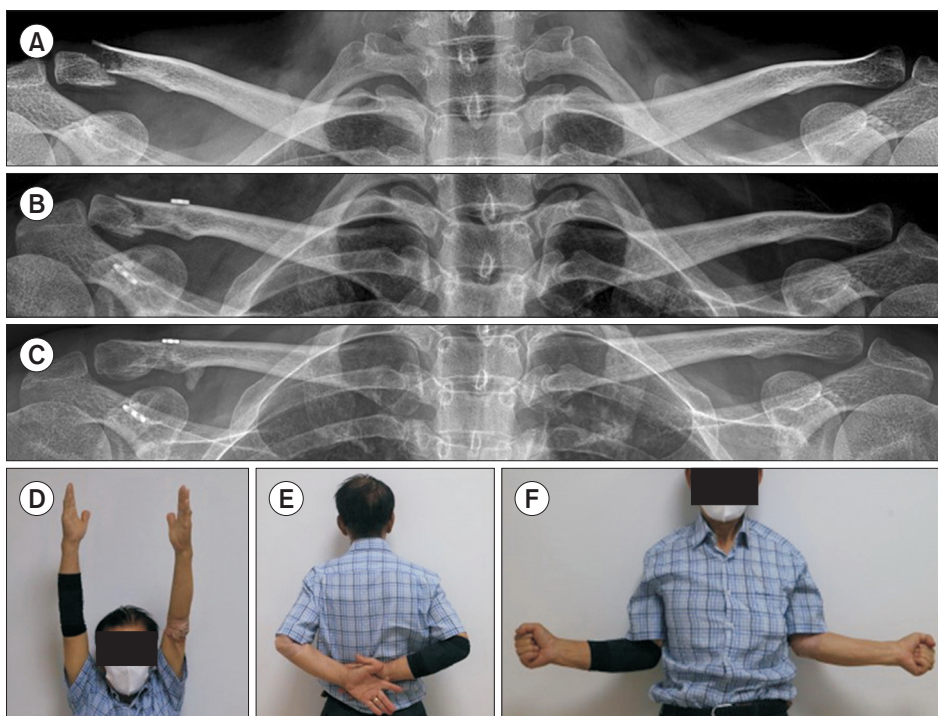


Fig. 2. A 73-year-old man. (A) Plain radiograph at initial trauma showing a Neer type IIB lateral clavicle fracture. (B) Plain radiograph after surgery showing open reduction and coracoclavicular stabilization using a TightRope. Plain radiograph at 6 months after surgery showing fracture healing (C) and satisfactory function (D-F).

2 Ethibond; Ethicon, Somerville, NJ, USA) was placed for reduction and stability. The postoperative rehabilitation protocol was the same as that used for the PLPO group. The mean follow-up period was 31.8 months (range, 12–144 months).

Outcome Assessment & Statistical Analysis

Radiographic outcomes were evaluated using serial plain radiographs including both clavicle anteroposterior and oblique views and shoulder axial view. Clinical outcomes were assessed using the University of California, Los An-

geles (UCLA) score, the American Shoulder and Elbow Surgeons (ASES) score, and subjective shoulder value (SSV) at final follow-up evaluation. Complications were also assessed.

Statistical analysis was performed using the IBM SPSS ver. 25.0 (IBM Corp., Armonk, NY, USA). In statistical analysis, the chi-square test and the independent *t*-test were used for assessment of the association of variables between the two groups. A paired *t*-test was performed for analysis of the difference in CC distance at the immediate postoperative and final follow-up evaluations in each group. The level of statistical significance was set at a *p*-value of < 0.05.

RESULTS

No significant differences in baseline demographics were

observed between the two groups ($p > 0.05$), except that the proportion of women was higher in the CCS groups compared with the PLPO group ($p = 0.032$) (Table 1). On preoperative radiographs, the average size of fracture fragments of the lateral clavicle was 24.3 mm and 19.4 mm in the PLPO and CCS groups, respectively; the average number of fragments at the fracture site was 1.2 and 1.0 in the PLPO and CCS groups, respectively; differences were not statistically significant ($p > 0.05$) (Table 2).

Of the 46 cases, complete bony union within 6 months after surgery was achieved in 42 cases (91.3%). The union rate was 100% (17/17) in the PLPO group and 86.2% (25/29) in the CCS group, showing a statistically significant difference ($p = 0.043$). No significant differences were observed between the mean CC distances of the affected side measured at the immediate postoperative and final follow-up evaluations in both groups ($p > 0.05$).

Table 1. Demographic Data

Variable	PLPO group	CCS group	<i>p</i> -value
Age (yr)	52.3 ± 17.6	53.5 ± 14.7	0.813
Sex (male : female)	13 : 4	13 : 16	0.032*
Involved side (right : left)	5 : 12	11 : 18	0.568
Injury mechanism			0.847
Slip down : fall down : MVA : sports injury	9 : 0 : 7 : 1	14 : 1 : 13 : 1	
Interval from initial trauma to surgery (day)	5.5 ± 4.8	6.8 ± 4.4	0.361
Follow-up period (mo)	36.9 ± 32.5	31.8 ± 28.3	0.537

Values are presented as mean ± standard deviation.

PLPO: pre-contoured locking plate osteosynthesis, CCS: coracoclavicular stabilization, MVA: motor vehicle accident.

Table 2. Comparison of Radiographic Outcomes between the Two Groups

Variable	PLPO group	CCS group	<i>p</i> -value
Size of lateral fragment (mm)	24.3 ± 3.8	19.4 ± 4.2	0.176
Number of fragments	1.2 ± 0.4	1.0 ± 0.2	0.087
CC distance (mm)			
Injured side at immediate postoperative	9.2 ± 2.3	4.8 ± 3.0	
Injured side at final follow-up evaluation	9.3 ± 2.7	5.7 ± 2.6	
<i>p</i> -value (immediate postoperative vs. final follow-up)	0.839	0.106	
Union rate, % (n)	100 (17/17)	86.2 (25/29)	0.043*

Values are presented as mean ± standard deviation unless otherwise indicated.

PLPO: pre-contoured locking plate osteosynthesis, CCS: coracoclavicular stabilization, CC: coracoclavicular.

*Statistically significant difference.

At the final follow-up evaluation, the mean UCLA score, ASES score, and SSV were 32.8, 93.2, and 89.1%, respectively, in the PLPO group, and 32.1, 90.8, and 90.3%, respectively, in the CCS group (Table 3). According to the grading of ASES score, the PLPO group included 14 excellent and 3 fair and the CCS group included 22 excellent, 2 good, 1 fair, and 4 poor. No significant differences in terms of UCLA score, ASES score, or SSV were observed between the groups ($p > 0.05$).

In the PLPO group, complications occurred in 3 cases (17.6%) including 2 cases of lateral screw breakage and 1 case of shoulder stiffness. In the CCS group, complications occurred in 11 cases (37.9%) including 4 cases of nonunion, 3 cases of shoulder stiffness, 2 cases of skin irritation, 1 case of superficial infection, and 1 case of coracoid button migration (Table 4). No significant difference in terms of complication rate was observed between the groups ($p > 0.05$). Four cases with nonunion after CCS did

not require reoperation because they had good to excellent clinical outcomes without radiographic progression (Fig. 3). In the PLPO group, 14 patients underwent implant removal after bony union because of a cosmetic problem or patient's request. In the CCS group, 4 patients underwent removal of the clavicular button and suture knot because of skin irritation (2 patients), superficial infection (1 patient), and patient's request (1 patient).

DISCUSSION

To the best of our knowledge, this is the first study to compare outcomes and complications between PLPO and CCS using a suture button device for type IIB fractures. In the current study, satisfactory clinical outcomes after surgery were achieved in both groups; however, a high nonunion rate was observed in the CCS group compared with the PLPO group. Cases with nonunion had good to excellent

Table 3. Comparison of Clinical Outcomes between the Two Groups

Variable	PLPO group	CCS group	<i>p</i> -value
UCLA score	32.8 ± 2.9	32.1 ± 5.2	0.614
ASES score	93.2 ± 10.2	90.8 ± 15.1	0.558
Excellent	14	22	
Good	0	2	
Fair	3	1	
Poor	0	4	
SSV (%)	89.1 ± 11.8	90.3 ± 14.8	0.762

Values are presented as mean ± standard deviation or number.

PLPO: pre-contoured locking plate osteosynthesis, CCS: coracoclavicular stabilization, UCLA: University of California, Los Angeles, ASES: American Shoulder and Elbow Surgeons, SSV: subjective shoulder value.

Table 4. Comparison of Postoperative Complications between the Two Groups

Variable	PLPO group	CCS group	<i>p</i> -value
Total complication, % (n)	17.6 (3/17)	37.9 (11/29)	0.133
Nonunion	0	4	
Stiffness	1	3	
Skin irritation	0	2	
Screw breakage	2	0	
Superficial infection	0	1	
Coracoid button migration	0	1	

PLPO: pre-contoured locking plate osteosynthesis, CCS: coracoclavicular stabilization.

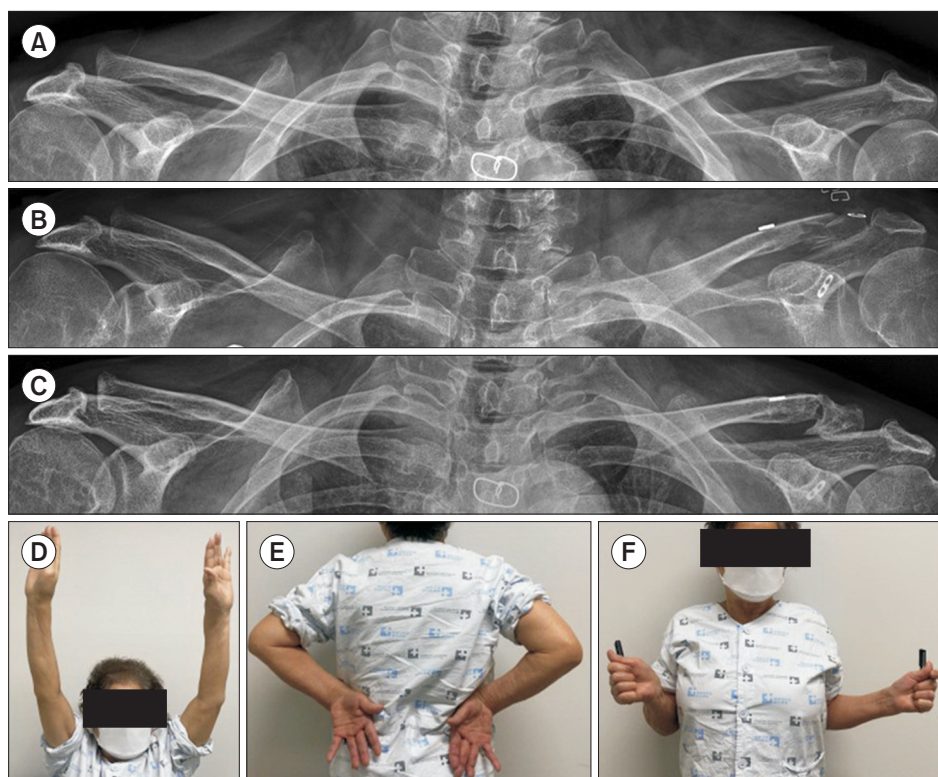


Fig. 3. A 72-year-old woman. (A) Plain radiograph at initial trauma showing a Neer type IIB lateral clavicle fracture. (B) Plain radiograph after surgery showing open reduction and coracoclavicular stabilization using a TightRope. (C) Plain radiograph at 4 years after surgery showing nonunion. (D-F) Despite the presence of fracture site nonunion, the clinical function was satisfactory.

clinical outcomes without requiring reoperation. These results demonstrated that both techniques can be regarded as useful options for the treatment of type IIB fractures.

Various surgical options have been introduced for the treatment of unstable lateral clavicle fractures, including PLPO, hook plate fixation, CCS (using suture anchor, suture button device, cable, tape, or screw), tension band wiring, and transacromial intramedullary fixation.⁴⁾ However, the best option for the treatment of type IIB fractures remains controversial because achievement of stable fixation with relatively small lateral fragments is not easy. To date, numerous studies have reported clinical and radiographic outcomes after surgical treatment of unstable type II fractures; however, outcome studies for only type IIB fractures have rarely been reported. According to a review of literature, CCS using a suture button device or cerclages, PLPO, and hook plate fixation are the latest options for surgical treatment of type IIB fractures.⁵⁻²⁰⁾ However, comparative outcome studies between these surgical options for the treatment of type IIB fractures have rarely been reported. Only 2 comparative studies between PLPO and hook plate for the treatment of type IIB fractures have been reported.^{9,17)}

A few studies reported that hook plate fixation for type IIB fractures resulted in satisfactory clinical outcomes after surgery, if the lateral fragment is too small for inser-

tion of screws.^{4,17,21,22)} However, hook plate fixation has a high complication rate of acromial osteolysis or fracture, hook cutting-out, subacromial impingement, and rotator cuff tears.^{4,9,23)} In addition, there is a drawback regarding the requirement for implant removal within 6 months after surgery.^{4,9,23)} Zhang et al.²³⁾ compared outcomes of 66 cases with unstable lateral clavicle fractures who underwent hook plate fixation and PLPO. Although there were no significant differences regarding the clinical score and union rate, a higher rate of complications (56% vs. 23.3%) and a lower rate of return to work within 3 months (94.4% vs. 73.3%) were observed in the hook plate group.²³⁾ Erdle et al.⁹⁾ reported a comparative analysis of the outcomes of hook plate fixation (19 cases) and PLPO (13 cases) for type IIB fractures. Although no significant differences regarding the clinical scores were observed between the groups, a higher overall complication rate was observed for hook plate fixation (89%) compared to PLPO (38%).

To date, numerous surgeons have recommended PLPO for treatment of unstable type II fractures with satisfactory clinical outcomes and high union rates. However, there are controversies with regard to type IIB fractures because the lateral fragment is often too small for sufficient placement of screws. Ying et al.²⁰⁾ reported that only PLPO for type IIB fractures may provide insufficient mechanical strength. On the other hand, several authors

advocated that PLPO can be a reliable surgical option for type IIB fractures because it facilitates better stability of the small lateral fragment by multi-planar locking screw fixation.^{4,18,24,25)} A major advantage of PLPO over hook plate fixation is that neither the AC joint nor subacromial space is violated.^{4,25)} Shin et al.¹⁸⁾ reported satisfactory clinical outcomes and a high union rate with PLPO for 16 type IIB fractures. They mentioned that stable fixation without additional CCS could be achieved because 2.3-mm lateral locking screws with diverging configuration maximize purchase of small lateral fragment and increase pullout resistance.¹⁸⁾

Based on the concept that the CC ligament is a crucial structure for stability in type IIB fractures, recent studies reported satisfactory clinical and radiographic outcomes after CCS using a suture button device for this type of fractures.^{5-7,11-13,15)} Cho et al.⁶⁾ reported on outcomes of 18 cases with type IIB fractures treated with open CCS using a TightRope and a mean ASES score of 88.6 with a union rate of 94.4%. They emphasized that the primary advantage of CCS using a suture button device is that implant removal is not required. Loriaut et al.¹²⁾ reported on outcomes of 21 cases with type IIB fractures treated with arthroscopy-assisted CCS using a TightRope. With satisfactory clinical outcomes, bony union was obtained in all patients (95%) except 1 who experienced nonunion with implant failure. However, in the nonunion cases, there were no symptoms at the final follow-up and reoperation was not required. They mentioned that this technique could provide satisfactory clinical outcomes while minimizing the risk of complications in patients with type IIB fractures. While Mochizuki et al.¹³⁾ raised a question regarding whether CCS using a suture button device alone is a strong construct for maintenance of reduction between the medial and lateral fragments. Despite reports of good results in several studies, it is important to properly position the tunnel of the coracoid process for fixation. If a patient has a small coracoid process, as may occur more commonly in female patients or patients with severe osteoporosis, great care should be taken when generating the coracoid process tunnel.⁶⁾

In the current study, satisfactory clinical outcomes after surgery without a significant difference in terms of UCLA score (32.8 vs. 32.1), ASES score (93.2 vs. 90.8), or SSV (89.1% vs. 90.3%) were achieved in both the PLPO and CCS groups. Although a higher complication rate was observed for the CCS group (37.9%) compared to the PLPO group (17.6%), there was no significant difference. Bony union was achieved in 100% (17/17) in the PLPO group and 86.2% (25/29) in the CCS group, showing a

significant difference. Four cases with nonunion after CCS did not require reoperation because they had good to excellent clinical outcomes without radiographic progression. These results demonstrated that both techniques can be regarded as useful options for the treatment of type IIB fractures.

The number of cases treated with additional CCS using a suture button device or suture anchor combined with PLPO has shown a recent increase.^{8,10,14,16)} These studies highlighted that additional CCS to improve vertical stability should be performed with PLPO in type IIB fractures because the remaining instability allows motion of the lateral fragment with an increased nonunion. Han et al.¹⁰⁾ reported on outcomes of 12 cases treated with PLPO combined with CCS using a suture anchor for type IIB fractures. They reported achievement of bony union in all patients with no major complications. As there is no high level of evidence reported in the literature, well-designed prospective randomized controlled trials are warranted to verify the best option for the treatment of type IIB fractures.

The current study has several limitations. First, the sample size was small. It was not sufficient to procure an adequate power for determination of statistical significance between outcomes and complications. Second, it was retrospective and not randomized, which could have resulted in selection bias. Despite these limitations, this is a valuable first study to compare outcomes and complications between PLPO and CCS using a suture button device for the treatment of type IIB fractures. Although a higher nonunion rate was observed in the CCS group compared with the PLPO group, satisfactory clinical outcomes were obtained for both groups. Both techniques can be regarded as useful options for the treatment of Neer type IIB lateral clavicle fractures.

CONFLICT OF INTEREST

No potential conflict of interest relevant to this article was reported.

ACKNOWLEDGEMENTS

The authors thank Eun-Ji Jeon, MD and Ye-Ji Kim, MD (Keimyung University Dongsan Hospital) for their support with data collection.

ORCID

Beom-Soo Kim <https://orcid.org/0000-0002-8728-512X>

Du-Han Kim <https://orcid.org/0000-0002-6636-9340>
 Byung-Chan Choi <https://orcid.org/0000-0002-0171-1862>
 Chul-Hyun Cho <https://orcid.org/0000-0003-0252-8741>

REFERENCES

- Banerjee R, Waterman B, Padalecki J, Robertson W. Management of distal clavicle fractures. *J Am Acad Orthop Surg.* 2011;19(7):392-401.
- Cho CH, Kim BS, Kim DH, Choi CH, Dan J, Lee H. Distal clavicle fractures: a new classification system. *Orthop Traumatol Surg Res.* 2018;104(8):1231-5.
- Craig EV. Fractures of the clavicle. In: Rockwood CA, Matsen FA, eds. *The shoulder.* Philadelphia: WB Saunders; 1990. 367-412.
- Kim DW, Kim DH, Kim BS, Cho CH. Current concepts for classification and treatment of distal clavicle fractures. *Clin Orthop Surg.* 2020;12(2):135-44.
- Blake MH, Lu MT, Shulman BS, Glaser DL, Huffman GR. Arthroscopic cortical button stabilization of isolated acute Neer type II fractures of the distal clavicle. *Orthopedics.* 2017;40(6):e1050-4.
- Cho CH, Jung JH, Kim BS. Coracoclavicular stabilization using a suture button device for Neer type IIB lateral clavicle fractures. *J Shoulder Elbow Surg.* 2017;26(5):804-8.
- Cisneros LN, Reiriz JS. Management of unstable distal third clavicle fractures: clinical and radiological outcomes of the arthroscopy-assisted conoid ligament reconstruction and fracture cerclage with sutures. *Eur J Orthop Surg Traumatol.* 2017;27(3):373-80.
- Dey Hazra RO, Blach RM, Ellwein A, Lill H, Warnhoff M, Jensen G. Additional coracoclavicular augmentation reduces revision rates in the treatment of lateral clavicle fractures as compared to angle-stable plate osteosynthesis alone. *Arch Orthop Trauma Surg.* 2022;142(6):1083-90.
- Erdle B, Izadpanah K, Jaeger M, et al. Comparative analysis of locking plate versus hook plate osteosynthesis of Neer type IIB lateral clavicle fractures. *Arch Orthop Trauma Surg.* 2017;137(5):651-62.
- Han L, Hu Y, Quan R, Fang W, Jin B, Huang L. Treatment of Neer IIB distal clavicle fractures using anatomical locked plate fixation with coracoclavicular ligament augmentation. *J Hand Surg Am.* 2017;42(12):1036.e1-6.
- Li Y, Shi S, Ou-Yang YP, Liu TL. Minimally invasive treatment for Neer IIB distal clavicle fractures with titanium cable. *J Trauma.* 2011;71(2):E37-40.
- Loriaut P, Moreau PE, Dallaudiere B, et al. Outcome of arthroscopic treatment for displaced lateral clavicle fractures using a double button device. *Knee Surg Sports Traumatol Arthrosc.* 2015;23(5):1429-33.
- Mochizuki Y, Kaneko T, Kawahara K, Toyoda S, Ikegami H, Musha Y. Outcome of arthroscopy-assisted treatment for distal clavicle fractures. *Arch Orthop Trauma Surg.* 2019;139(10):1393-8.
- Perskin CR, Tejwani NC, Jazrawi LM, Leucht P, Egol KA. Clinical outcomes of a combined osteoligamentous reconstruction technique of Neer type IIB distal clavicle fractures. *J Orthop.* 2021;25:134-9.
- Sautet P, Galland A, Airaudi S, Argenson JN, Gravier R. Arthroscopy-assisted fixation of fracture of the distal part of the clavicle by subcoracoid suture and clavicle button. *Orthop Traumatol Surg Res.* 2018;104(8):1237-40.
- Schliemann B, Rosslenbroich SB, Schneider KN, Petersen W, Raschke MJ, Weimann A. Surgical treatment of vertically unstable lateral clavicle fractures (Neer 2b) with locked plate fixation and coracoclavicular ligament reconstruction. *Arch Orthop Trauma Surg.* 2013;133(7):935-9.
- Seo JB, Kwak KY, Yoo JS. Comparative analysis of a locking plate with an all-suture anchor versus hook plate fixation of Neer IIB distal clavicle fractures. *J Orthop Surg (Hong Kong).* 2020;28(3):2309499020962260.
- Shin SJ, Ko YW, Lee J, Park MG. Use of plate fixation without coracoclavicular ligament augmentation for unstable distal clavicle fractures. *J Shoulder Elbow Surg.* 2016;25(6):942-8.
- Tiefenboeck TM, Boesmueller S, Binder H, et al. Displaced Neer type IIB distal-third clavicle fractures: long-term clinical outcome after plate fixation and additional screw augmentation for coracoclavicular instability. *BMC Musculoskelet Disord.* 2017;18(1):30.
- Ying H, Wang J, Sun Y, Dai K, Yu C, Yang F. Treatment of unstable distal clavicle fractures (Neer type IIB): a modified system using a miniature locking plate with a single button. *J Int Med Res.* 2021;49(6):3000605211022505.
- Flinkkila T, Heikkila A, Sirnio K, Pakarinen H. TightRope versus clavicular hook plate fixation for unstable distal clavicular fractures. *Eur J Orthop Surg Traumatol.* 2015;25(3):465-9.
- Yoon B, Kim JY, Lee JS, Jung HS. The radiologic compari-

- son of operative treatment using a hook plate versus a distal clavicle locking plate of distal clavicle fracture. *Clin Shoulder Elb.* 2018;21(4):227-33.
23. Zhang C, Huang J, Luo Y, Sun H. Comparison of the efficacy of a distal clavicular locking plate versus a clavicular hook plate in the treatment of unstable distal clavicle fractures and a systematic literature review. *Int Orthop.* 2014;38(7):1461-8.
 24. Beirer M, Siebenlist S, Cronlein M, et al. Clinical and radiological outcome following treatment of displaced lateral clavicle fractures using a locking compression plate with lateral extension: a prospective study. *BMC Musculoskelet Disord.* 2014;15:380.
 25. Fleming MA, Dachs R, Maqungo S, du Plessis JP, Vrettos BC, Roche SJ. Angular stable fixation of displaced distal-third clavicle fractures with superior precontoured locking plates. *J Shoulder Elbow Surg.* 2015;24(5):700-4.
 26. Huang FT, Lin KC, Lin CY, Chang WN. Concomitant acromioclavicular and coracoclavicular ligament reconstruction with a duo-figure-8 autogenic graft wrapping technique for treating chronic acromioclavicular separation. *Clin Orthop Surg.* 2021;13(3):366-75.
 27. Yagnik GP, Brady PC, Zimmerman JP, Jordan CJ, Porter DA. A biomechanical comparison of new techniques for distal clavicular fracture repair versus locked plating. *J Shoulder Elbow Surg.* 2019;28(5):982-8.