



## Case Report

## Invisible incarcerated umbilical hernia: A case report

Bernardus Parish Budiono<sup>a,\*</sup>, Melissa Angela Chionardes<sup>b</sup>, Sigit Adi Prasetyo<sup>a</sup>,  
Ignatius Riwanto<sup>a</sup>

<sup>a</sup> Surgery Department, Faculty of Medicine, Diponegoro University, Semarang, Indonesia

<sup>b</sup> Faculty of Medicine, Diponegoro University, Semarang, Indonesia

## ARTICLE INFO

## Keywords:

invisible umbilical hernia  
Abdominal CT scan  
Small bowel distention in central abdomen  
Intestinal obstruction  
Case report

## ABSTRACT

**Introduction:** Umbilical hernia usually manifests as a bulging of umbilicus. Invisible incarcerated umbilical hernia has never been reported.

**Case presentation:** A 53-years-old obese woman admitted to hospital with abdominal pain and vomitus one day after discharged from other hospital, was managed conservatively as an adhesion small bowel obstruction (ASBO) for seven days. There was history of caesarean section 20 years ago. Abdomen was bloated, there was transverse scar wound in hypogastric region and no signs of external abdominal hernia. Plain abdominal x-ray showed dilated small bowel located in the central part of the abdomen. Abdominal CT scan was done to determine the other cause besides adhesion, it showed incarcerated umbilical hernia and gallbladder stone. Herniorrhaphy and laparoscopic cholecystectomy were performed. During surgery, there was a loop of vital small bowel, trapped in the umbilical defect. Mayo method was performed to close the defect.

**Discussion:** The other causes of small bowel obstruction should be determined besides adhesion, infectious disease and trauma. Umbilical hernia should be considered in obese women even without bulging in the umbilicus. Abdominal CT scan with oral water-soluble contrast is preferred as diagnostic tool to identify the cause of small bowel obstruction.

**Conclusion:** Invisible incarcerated umbilical hernia is possible in obese patients. Routine palpation on potential sites of developing hernia and abdominal CT Scan are necessary to be done in obese patients with small bowel obstruction.

## 1. Introduction

Patients with signs and symptoms of intestinal obstruction, history of abdominal surgery and small bowel obstruction shown in abdominal plain x-ray, mostly are diagnosed and managed as adhesive small bowel obstruction (ASBO). The indications of emergency surgery for ASBO are peritonitis, strangulated and signs of ischemia. In cases without those indications of emergency surgery, the management of ASBO is primarily conservative by nasogastric tube, nil by mouth and intravenous supplementation of fluid, electrolyte as well as nutrition. Conservative management of ASBO for 72 hours is contributed to a successful recovery for around 70%. The unsuccessful case can be caused by adhesion from previous surgery. Several causes of peritoneal injury resulting adhesion formation are radiotherapy, endometriosis, inflammation and local response to tumors. Therefore recent guideline of ASBO

recommends abdominal computed tomography (CT) scan with oral water-soluble contrast as preferred imaging in initial evaluation [1]. Small bowel obstruction can be caused by abdominal hernia which can be identified easily by the presence of abdominal wall bulging. The incidence of adult umbilical hernia is around 2% and very common in obese multiparous women and cirrhotic patients. The main complaint is bulging in the umbilical site. The content of the hernial sac can be small bowel or omentum. In case of unreducible umbilical hernia that the small intestine is trapped, the symptoms will be nausea, vomitus and colicky despite of umbilical bulging [2]. This case reported an obese woman who was previously diagnosed and managed as adhesive small bowel obstruction, partially recovered and discharged home, then admitted to other hospital with invisible incarcerated umbilical hernia based on Abdominal CT scan.

\* Corresponding author.

E-mail addresses: [parishbudiono@yahoo.com](mailto:parishbudiono@yahoo.com) (B.P. Budiono), [melissaangelac@gmail.com](mailto:melissaangelac@gmail.com) (M.A. Chionardes), [seagate\\_82@yahoo.com](mailto:seagate_82@yahoo.com) (S.A. Prasetyo), [iriwanto@gmail.com](mailto:iriwanto@gmail.com) (I. Riwanto).

<https://doi.org/10.1016/j.amsu.2022.103311>

Received 12 December 2021; Received in revised form 12 January 2022; Accepted 23 January 2022

Available online 26 January 2022

2049-0801/© 2022 The Authors. Published by Elsevier Ltd on behalf of IJS Publishing Group Ltd. This is an open access article under the CC BY-NC-ND license

(<http://creativecommons.org/licenses/by-nc-nd/4.0/>).

## 2. Case presentation

A 53-years-old woman admitted to hospital with frequent vomitus and abdominal pain. The patient was previously discharged from other hospital one day before admission, was diagnosed as adhesive small bowel obstruction, based on history of frequent vomitus, abdominal pain, history of cesarean section 20 years ago and small bowel distention on abdominal plain X-ray. There was no history of abdominal trauma, massage and infection. The previous management was conservative by nasogastric tube, nil by mouth, intravenous supplementation of fluid, electrolyte and nutrition for 7 days. As the abdominal distention and pain subsided as well as no vomitus, patient was discharged. The patient vomited again after meals and admitted to the hospital.

On physical examination resulted body weight 96 kg and height 154 cm, obesity with body mass index of  $40.5 \text{ kg/m}^2$ , blood pressure 100/60 mmHg, pulse rate 96 times per minute, respiratory rate 24 times per minute, dry skin and sunken eyes. Abdomen was slightly distended, there was transverse operative scar in hypogastric area without bulging, neither in the umbilical nor inguinal region as seen in Fig. 1, no tenderness, no muscular rigidity and increased peristaltic without metallic sound. There was no bulging of the umbilicus while standing either. On rectal examination, sphincter tone was good, rectal was collapsed, there was no tumor, uterus and adnexa were within normal limit and there was no fecal material.

Laboratory findings showed hemoglobin 13.4 g/dl (N: 14.0–16.0), leucocyte  $7,500/\mu\text{l}$  (N: 4,000–11,000), thrombocyte  $235,000/\mu\text{l}$  (N: 150,000–400,000), sodium 134 mmol/L (N: 138–146), chloride 104 mmol/L (N: 98–109), potassium 3.2 mmol/L (N: 3.5–4.9), urea 96 mg/dl (N: 19–44), creatinine 2.7 mg/dl (N: 0.62–1.17), blood sugar level 245 mg/dl. Reevaluation of abdominal plain x-ray showed small bowel dilatation that fixed in central abdomen, with air-fluid level, as shown in Fig. 2. Cesarean section was done extraperitoneally, hence the risk of adhesion was only in case with peritoneal torn. Abdominal CT scan was performed to explore the cause of small bowel obstruction. As shown in Fig. 3, both axial and sagittal plane showed small bowel dilatation and a loop of small bowel with air-fluid level within the abdominal wall in the umbilical area. The sagittal plane showed gall bladder stone. Re-anamnesis to find any symptomatic gallbladder stone found that the patient had mild chronic right upper quadrant pain. Palpation of the umbilicus felt there was smooth and soft ballooning mass below the umbilical crest, without bulging in inspection. Diagnosis was invisible incarcerated umbilical hernia and symptomatic gallbladder stone. Herniorrhaphy and laparoscopic cholecystectomy were performed. In surgery, there was a vital small bowel loop and was easily pushed back to

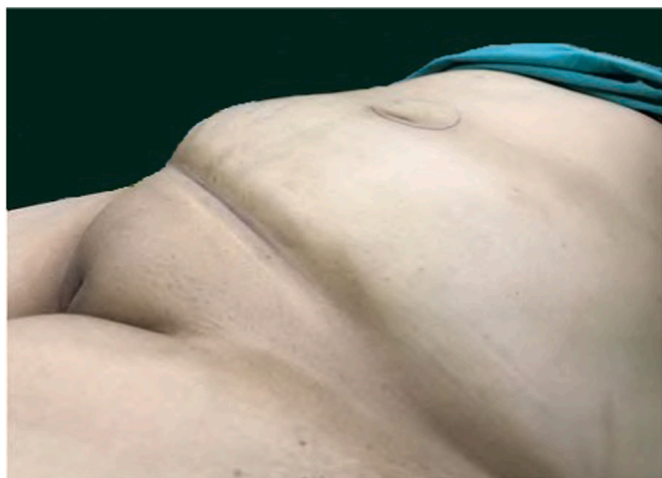

Fig. 1. Abdominal appearance was slightly distended with transverse scar in hypochondrium area, without bulging in wound scar, umbilicus or inguinal area.

abdominal cavity after umbilical ring enlargement (Fig. 4) continued with laparoscopy cholecystectomy. As there was small defect, Mayo method hernioplasty was done. Patient was recovered and discharged on 5th post-operative day. This case report has been reported in line with the SCARE Criteria [3].

## 3. Discussion

Umbilical hernia is a ventral abdominal hernia located in umbilical region. However, European Hernia Society (EHS) defines umbilical hernia as hernia that located 3 cm above to 3 cm below the umbilicus, which is usually round or oval shaped. According to EHS, the classification of hernia is based on its size: small for less than 2 cm, medium for between 2 and 4 cm and large for more than 4 cm [4]. From this definition, umbilical hernia should be a bulging in the umbilical region. From literature searching, there is no report regarding invisible incarcerated umbilical hernia. The only reports related to invisible umbilical hernia were spontaneous umbilical enterocutaneous fistula resulting from an incarcerated Richter's hernia [5] and strangulated Richter's umbilical hernia [6]. Referred to our case, it was invisible incarcerated umbilical hernia, as the patient admitted with small bowel obstruction without umbilical bulging and was diagnosed based on abdominal CT scan. Previous case reports regarding umbilical hernia were all with umbilical bulging, such as incarcerated umbilical Littre's hernia at the trocar site of a previous laparoscopic surgical procedure [7], sister Mary Joseph's nodule originating from endometrial carcinoma incidentally detected during surgery for an umbilical hernia [8], umbilical hernia masking primary umbilical endometriosis [9] and umbilical hernia with small bowel obstruction hidden within a chronic umbilical hernia sac in 45 years-old obese women with history of 5 years umbilical bulging [10].

Umbilical opening, which umbilical vein (ligamentum teres hepatis) is in the cranial and urachus (median ligament) as well as right and left umbilical artery (medial ligament) are in caudal part emerge, is located in linea alba. Fascia transversalis in the umbilical region is thickened and called as umbilical fascia or Richet fascia. As umbilical vein, urachus and umbilical artery are located between peritoneum and fascia transversalis, hence there are 4 openings in Richet fascia. In the center of umbilicus, the skin is replaced by cicatricial tissue and attached directly to fascia without fat in between. Umbilical hernia may develop through the opening of ligamentum teres hepatis and bulge will be cranial to cicatricial tissue of umbilicus. Otherwise, it may develop through caudal opening and bulge will be caudal of the cicatricial tissue. However, the umbilical hernia can be central due to weakened Richet fascia, so cicatricial tissue is in center of the bulging [11]. The most common umbilical hernia protrudes through ligament teres hepatis [2]. Regarding the patient in this case, the loop of intestine located in the caudal of the umbilical crest, therefore the hernia went through the caudal defect. The surgery met difficulty to identify the weak point was either the median or medial ligament. The hypothesis was umbilical hernia in cranial part of cicatricial tissue would be clearly seen due to gravitation, in contrast with caudal part, especially in very obese patients, the small hernia would not be seen.

Adult umbilical hernia is mostly acquired (90%), only 10% of patients have history of umbilical hernia at childhood. Risk factor for developing umbilical hernia is increasing intra-abdominal pressure such as ascites, multiple pregnancy, obesity and chronic abdominal distention. Abdominal organs, mostly small bowel or omentum may be pushed to the weak area in the umbilicus and develop umbilical hernia [2]. Increased intra-abdominal pressure due to any cause forces a portion of the circumference of bowel wall into the hernia sac through the internal ring. If less than one-third of the bowel wall is involved, patients will be without ileus and known as Richter hernia; between one-third and two thirds of the bowel wall is involved, patients will have incomplete obstruction; and more than two-thirds of the bowel wall is involved, with obvious obstruction symptoms, called as incarcerated umbilical

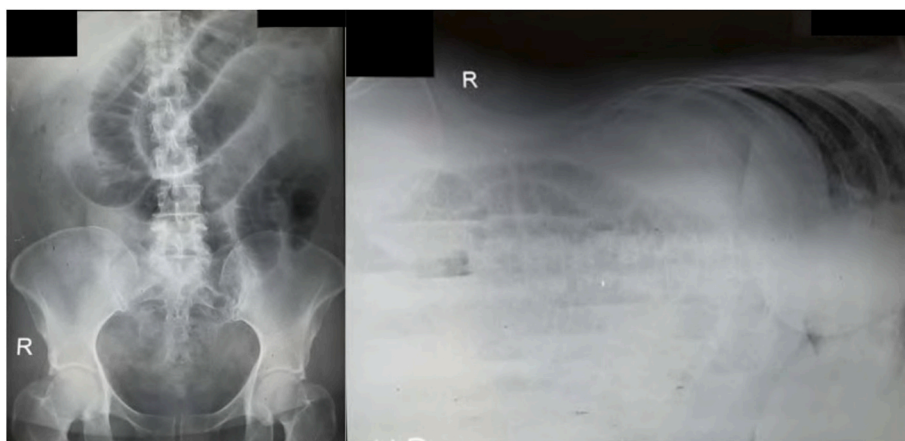


Fig. 2. Abdominal plain x-ray supine and left lateral decubitus showed fixed central small bowel distention with air-fluid level.

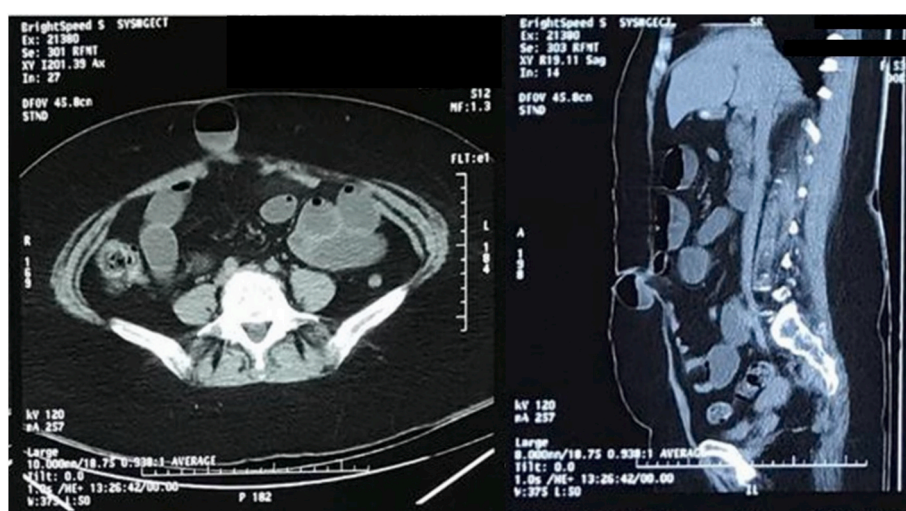


Fig. 3. Abdominal CT scan both axial and sagittal plane showed a loop of small bowel with air-fluid level within the abdominal wall in umbilical area.

hernia [5]. In this case report, a loop of small bowel (100% circumference) was trapped, however the hernia was invisible.

#### 4. Conclusion

The other causes of small bowel obstruction should be considered besides adhesion. Invisible incarcerated umbilical hernia is one of the possible cause in obese patients. Routine palpation on potential sites of developing hernia and abdominal CT Scan are necessary to be done in obese patients with small bowel obstruction.

#### Ethical approval

This article type (case report) does not require a formal ethical committee approval. Access to data was approved by the head of the department.

#### Sources of funding

No Source of Funding.

#### Author contribution

Bernardus Parish Budiono: Data collection, reference collection and original draft. Melissa Angela Chionardes: Data collection, reference

collection and editing the manuscript. Sigit Adi Prasetyo: Data collection, reference collection and editing the manuscript. Ignatius Riwanto: Supervise, operate the patients and final editing of the manuscript.

#### Conflicts of interest

No Conflicts of Interest.

#### Research registration number

Not required for case report.

#### Patient perspective

The patient did not present his point of view.

#### Provenance and peer review

Not commissioned, externally peer-reviewed.

#### Consent

Written informed consent was obtained from the patient for publication of this case report and accompanying images. A copy of the written consent is available for review by the Editor-in-Chief of this

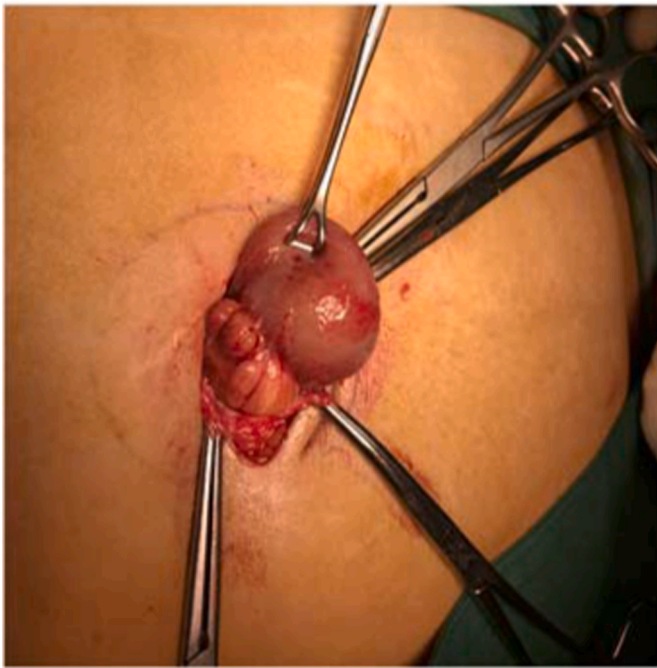

Fig. 4. A vital small bowel loop was found during surgery.

journal on request.

#### Registration of research studies

This is not an original research project involving human participants in an interventional or an observational study but a case report. This registration was not required.

#### Guarantor

Bernadus Parish Budiono.

#### Appendix A. Supplementary data

Supplementary data to this article can be found online at <https://doi.org/10.1016/j.amsu.2022.103311>.

#### References

- [1] R.P.G. Broek, P. Krielen, S. Di Saverio, F. Coccolini, W.L. Biffi, L. Ansaloni, et al., Bologna guidelines for diagnosis and management of adhesive small bowel obstruction (ASBO), *World J. Emerg. Surg.* 13 (2018) 13–24.
- [2] A.H. Coste, S. Jaafar, J.D. Parmely, *Umbilical Hernia*. StatPearls. Treasure Island (FL), StatPearls Publishing, 2021.
- [3] R.A. Agha, T. Franchi, C. Sohrabi, G. Mathew, A. Kerwan, The SCARE 2020 guideline: updating consensus surgical CAse REport (SCARE) guidelines, *Int. J. Surg.* 84 (2020) 226–230, 2020.
- [4] F.E. Muysoms, M. Miserez, F. Berrevoet, G. Campanelli, G.G. Champault, E. Chelala, et al., Classification of primary and incisional abdominal wall hernias, *Hernia* 13 (2009) 407–414, <https://doi.org/10.1007/s10029-009-0518-x>.
- [5] W. Chen, L. Liu, H. Huang, M. Jiang, T. Zhang, A case report of spontaneous umbilical enterocutaneous fistula resulting from an incarcerated Richter's hernia, with a brief literature review, *BMC Surg.* 17 (2017) 1–5, <https://doi.org/10.1186/s12893-017-0216-z>.
- [6] Martis Jjs, K.V. Rajeshwara, M.K. Shridhar, D. Janardhanan, S. Sudarshan, Strangulated Richter's umbilical hernia - a case report, *Indian J. Surg.* 73 (2011) 455–457, <https://doi.org/10.1007/s12262-011-0272-z>.
- [7] M. Bailon-Cuadrado, M. Rodriguez-Lopez, J.I. Blanco-Alvarez, P.L. Rodriguez-Vielba, Incarcerated umbilical Littre's hernia at the trocar site of a previous laparoscopic surgical procedure, *Ann. R. Coll. Surg. Engl.* 98 (2016), <https://doi.org/10.1308/rcsann.2016.0133> e82–3.
- [8] B. Piura, M. Meirovitz, M. Bayme, R. Shaco-Levy, Sister Mary Joseph's nodule originating from endometrial carcinoma incidentally detected during surgery for an umbilical hernia: a case report, *Arch. Gynecol. Obstet.* 274 (2006) 385–388, <https://doi.org/10.1007/s00404-006-0189-0>.
- [9] E. Brătîlă, O.M. Ionescu, D.C. Badiu, C. Berceanu, S. Vlădăreanu, D.M. Pop, et al., Umbilical hernia masking primary umbilical endometriosis - a case report, *Rom. J. Morphol. Embryol.* 57 (2016) 825–829.
- [10] C.P. Schrepel, F. Gallahue, Failure to reduce: small bowel obstruction hidden within a chronic umbilical hernia sac, *Emerg. Med.* 48 (2016) 505–507, <https://doi.org/10.12788/emed.2016.0067>.
- [11] A.V. Moschowitz, The pathogenesis of umbilical hernia, *Ann. Surg.* 61 (1915) 570–581, <https://doi.org/10.1097/00000658-191505000-00006>.