

Acute Fibrinous and Organizing Pneumonia with Myelodysplastic Syndrome: Corticosteroid Monotherapy Led to Successful Ventilator Weaning

Mari Yamamoto, Kengo Murata, Takahiro Kiriu, Yasuji Kouzai and Mikio Takamori

Abstract

A 62-year-old man with myelodysplastic syndrome (MDS) presented to our hospital with a high fever. Although treatment with broad-spectrum antibiotics was initiated, his respiratory status worsened to the point that he required mechanical ventilation. However, he was successfully treated with a corticosteroid without immunosuppression. Sequential transbronchial lung biopsies revealed abundant fibrin exudate in the alveolar spaces, which was subsequently replaced by fibroblasts, showing that acute fibrinous and organizing pneumonia (AFOP) gradually changes into organizing pneumonia. Our case demonstrated both the efficacy of corticosteroid-monotherapy and the histological course of AFOP.

Key words: acute fibrinous and organizing pneumonia, myelodysplastic syndromes, mechanical ventilation, corticosteroid monotherapy

(Intern Med 55: 3155-3159, 2016)

(DOI: 10.2169/internalmedicine.55.6864)

Introduction

Acute fibrinous and organizing pneumonia (AFOP) follows a clinical course of acute or subacute lung injury and has a distinct histological pattern. The prognosis of patients with severe AFOP who require intubation and mechanical ventilation is reported to be poor (1, 4-8), with only a few successfully treated cases on record (2, 3). We herein discuss the case of a patient with severe AFOP who required ventilatory support and who was successfully extubated after corticosteroid monotherapy. We also report our observations of the histological changes of the healing process of AFOP as it changed into organizing pneumonia (OP).

Case Report

A 62-year-old man had been well until 2 weeks before he presented to our hospital with a high fever. Two years before this presentation, he had been diagnosed with myelodysplastic syndrome (MDS) and showed a chromosomal abnormality in 46XY,+1,der(1;7)(q10;p10). The patient had

not previously received any immunosuppressive treatment and had not previously undergone bone marrow transplantation. Although a rapid influenza antigen test was negative, zanamivir and acetaminophen were prescribed due to an ongoing influenza epidemic. The patient revisited our hospital four days after his initial presentation due to a persistent fever. A chest X-ray showed consolidation in the right lower lung field and the patient was admitted to our hospital (Fig. 1A). His vital signs on admission were as follows: temperature, 40.1°C; heart rate, 127/min; blood pressure, 198/119 mmHg; respiratory rate, 28/min; and oxygen saturation on room air, 97%. There were no remarkable physical or laboratory examination findings. No infectious agents were detected in the patient's blood or sputum cultures on admission. The patient was negative for serum autoantibodies, serum antigens against fungi, and urinary antigens against pneumococcus and legionella.

Piperacillin-tazobactam, azithromycin, and voriconazole were initiated from the first day of admission and switched to meropenem, levofloxacin, and amphotericin B on day 4. Peramivir and sulfamethoxazole-trimethoprim were added on days 2 and 3, respectively. In spite of the treatment, the pa-

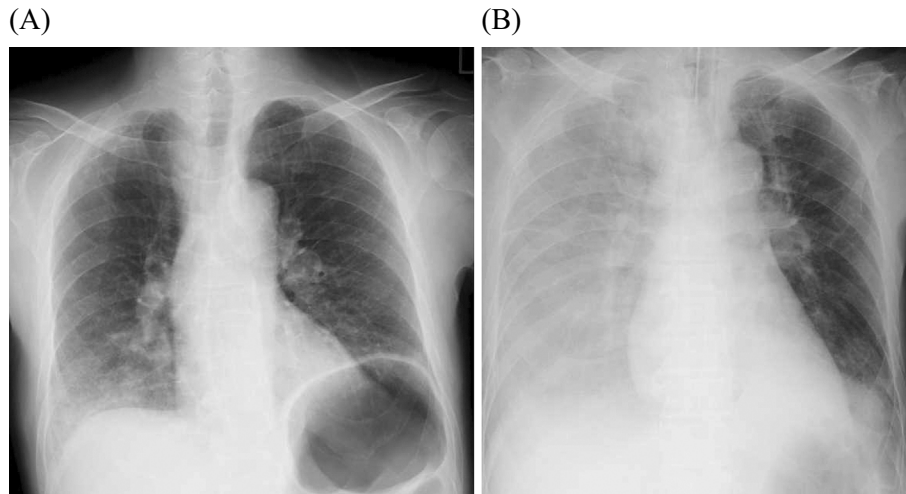


Figure 1. (A) Chest X-ray showed a consolidation in the right lower lung field at the time of admission. (B) The consolidation rapidly worsened and developed in both lungs on Day 4 of hospitalization.

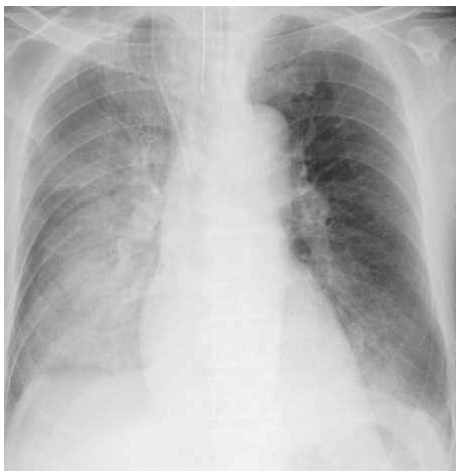

Figure 2. Chest X-ray indicated residue of the consolidation in both lungs on Day 11 of hospitalization, when the patient's respiratory status improved and mechanical ventilation was removed.

tient's respiratory status worsened. On day 4 of hospitalization, his PaO₂ level was 56 mmHg with the administration of 15 L O₂ by a non-rebreather mask and his blood pressure was 68/41 mmHg. He was transferred to the intensive care unit (ICU) with mechanical ventilation (Fig. 1B). After nor-adrenaline therapy proved ineffective against the patient's persistent hypotension, hydrocortisone [200 mg/day (50 mg/day of prednisolone equivalent)] was administered to maintain circulation. His blood pressure subsequently increased to the normal range and his respiratory status showed improvement. The corticosteroid dosage was increased to prednisolone (60 mg/day) on day 9 of hospitalization, and he was successfully weaned from mechanical ventilation on day 11 without additional immunosuppressive agents (Fig. 2).

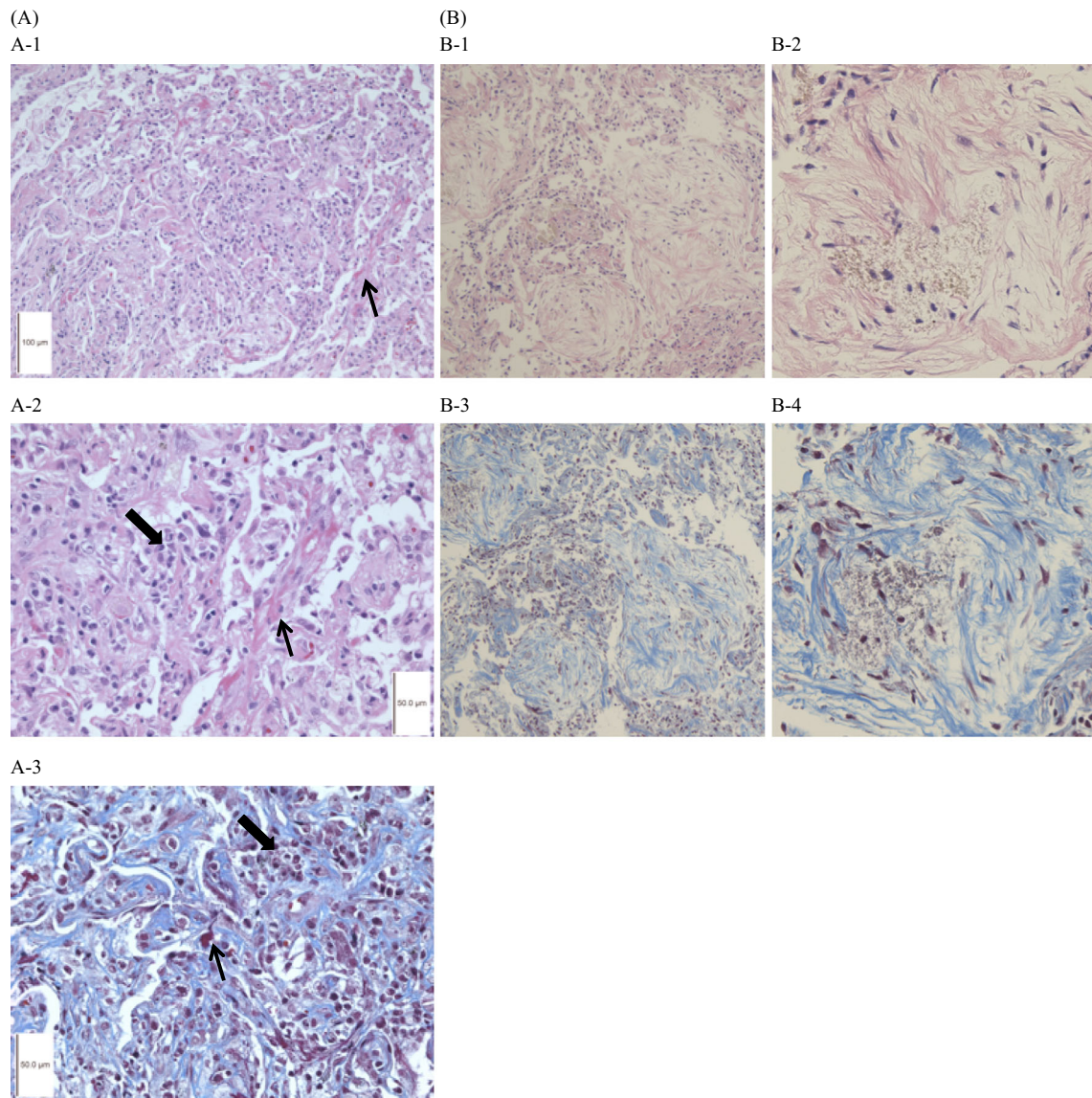
The first TBLB on day 15 of hospitalization revealed the cardinal features of AFOP, namely, abundant fibrin exudate, immature organization in the alveolar spaces, and lym-

phoplasmacytic infiltration in the alveolar septa (Fig. 3A). The consolidation in the right lower lobe persisted, despite prolonged corticosteroid treatment, possibly suggesting another complication such as a fungal infection. A second TBLB performed on day 42 revealed the replacement of these features by fibroblasts and evidence of organization, which are the histological features of OP (Fig. 3B). Neither TBLB revealed any typical fibrin balls, hyaline membranes, eosinophilic infiltration, bleeding, vasculitis or infection. The diagnosis of AFOP and OP was made based on the histological and clinical signs. The dosage of the prednisolone was tapered to 7 mg/day when the patient recovered and was discharged on day 52 of hospitalization (Fig. 4). In spite of four months of azacytidine treatment, which was initiated after hospital discharge, the patient's MDS progressed to leukemia. Thereafter, the patient refused to undergo any additional chemotherapies or hematopoietic stem cell allograft transplantation. The patient died five months after hospital discharge. During the course of the disease, his respiratory status remained good.

Discussion

AFOP was first described by Beasley et al. in 2002 (1) as a histological pattern of acute or subacute lung injury similar to DAD, COP, or EP. In particular, patients with acute and severe AFOP show a clinical course similar to patients with DAD and have a poor prognosis. Beasley et al. reported that the mean survival period in patients with severe acute AFOP was 0.1 years, while all patients on mechanical ventilation died. However, the ideal treatments for AFOP have not been established.

There are two important observations in this case. First, systemic corticosteroid therapy may have improved the survival of a patient with severe AFOP while he was on ventilatory support. Second, in the healing process of AFOP, it histologically changes into OP.



→ : abundant fibrin exudate,
 ➔ : lymphoplasmacytic infiltration

Figure 3. (A) Trans-bronchial lung biopsy on Day 15 showed abundant fibrin exudate, immature organization in the alveolar spaces, and lymphoplasmacytic infiltration in the alveolar septa [A-1: Hematoxylin and Eosin (H&E) staining, original magnification 100×, A-2: H&E staining, original magnification 400×, A-3: Masson, original magnification 400×]. (B) Trans-bronchial lung biopsy on Day 42 of hospitalization showed infiltration of fibroblasts and organization without fibrin exudate (B-1: H&E staining, original magnification 100×, B-2: H&E staining, original magnification 400×, B-3: Masson, original magnification 100×, B-4: Masson, original magnification 400×). Masson: Masson trichrome stain

First, our case demonstrated that acute and severe AFOP patients may be weaned from mechanical ventilation using corticosteroid monotherapy. We performed a PubMed search of cases of acute and severe AFOP involving ventilatory support (Table). Only 2 of the 12 AFOP cases who required mechanical ventilation were reported to have survived (1-8). One of the surviving AFOP patients, who also had HIV, did not receive corticosteroid treatment until ventilatory support was initiated on day 7 after the presentation of the symptoms (2). The other surviving patient received a

combination of immunosuppressive agents and corticosteroids from the onset of presentation (3). In our case, we initiated corticosteroid treatment from day 8 after the onset of the respiratory symptoms, which corresponded to day 1 of intubation. In the six fatal cases corticosteroid therapy was not initiated until 10 or more days after the onset of symptoms (4-6, 8). Patients who began to receive corticosteroids within 10 days of the onset of respiratory symptoms tended to have a better survival rate than those who did not (67% vs. 14%, $p=0.18$; Fisher's exact test. SPSS version 20 was

used to perform the statistical analysis.

Moreover, MDS patients with chromosomal abnormalities (1q:7p) are reported to have immunological abnormalities, such as polyclonal hypergammaglobulinemia and increased numbers of bone marrow plasma cells (9), which may be associated with AFOP and other respiratory disorders requiring corticosteroid therapies. Several factors are hypothesized to be involved in the relationship between MDS and pulmonary involvement, such as the production of superoxide anions by the neutrophils (10) and immunological abnormalities caused by bone marrow eosinophilia (11). More recently, there have been three reported cases of patients with lung injuries and a chromosomal abnormality in 46XY,+1, der(1;7)(q10:p10), which was also seen in our case, (11). This suggests that the chromosomal abnormality is associated with both immunological abnormalities and lung injuries, such as AFOP. In our case, lymphocytopenia was observed as laboratory evidence of an immunological abnormality (12).

There are three reported cases of patients with non-infectious respiratory disorders and MDS with this abnormality who were successfully treated using corticosteroids (13). Two further cases of AFOP with MDS have been reported (14, 15), one of which presented the above-mentioned chromosomal abnormality. Both cases responded favorably to corticosteroids and demonstrated improvement in the respiratory symptoms (15). These reports showed that non-infectious respiratory disorders in MDS patients with a chromosomal abnormality (1q:7p) were associated with a favorable response to corticosteroid therapy.

Second, during the healing process, AFOP histologically changes into OP. AFOP has been described as a distinct histological pattern that is associated with acute lung injury and which differs from the classic histological patterns of DAD, EP, and COP. In our case, the first TBLB showed abundant fibrin exudate in the alveolar spaces. The histological pattern differs from that of DAD in the absence of hyaline membranes, and from eosinophilic pneumonia in the absence of eosinophils. Fibroblastic Masson bodies, which are the dominant finding in COP, were not observed in this case. The diagnosis of AFOP was made based on the clinical and histopathological course. The second TBLB performed after the initial therapy revealed that the fibrin exudate in the alveolar spaces had been replaced by fibroblasts and foamy macrophages. Infiltration by lymphocytes and plasma cells was observed in the alveolar walls, which is a histopathological feature of OP. There was no evidence of alveolar wall thickening, which is characteristic of primary OP. This fibrous organization was therefore considered to be the result of a secondary histological change. This report demonstrated that the histology of the healing process in AFOP involves the absorption of fibrin and the transition to OP.

Infectious diseases should be excluded before the administration of corticosteroids. AFOP was mistakenly diagnosed

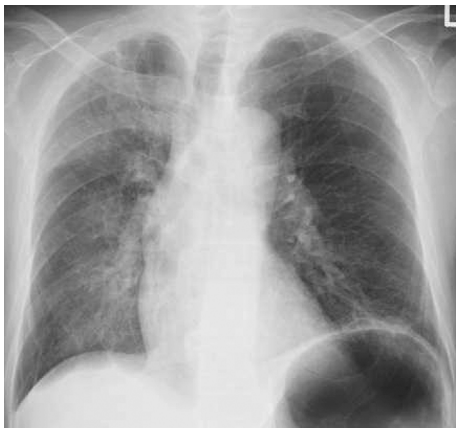

Figure 4. Chest X-ray on 52 day of hospitalization showed that the consolidation in the right lower lung field significantly improved. The patient was discharged from our hospital following these findings.

Table. Previously Published AFOP Cases Requiring Mechanical Ventilation.

Age Sex	Underlying disease	Early steroid administration	Other treatment	Outcome	Reference
74 M	NA	-	Lasix+dopamine	dead	1
39 M	lymphoma	NA	-	dead	
59 F	renal failure	NA	Abx	dead	
36 M	NA	-	-	dead	
66 M	NA	NA	Abx	dead	
49 F	-	-	IVIG+CPA	dead	4
14 F	JDM, mycoplasma	6 days	CPA+CsA	dead	5
39 F	UCTD	-	CPA	dead	6
27 F	MWS	-	Abx	dead	7
66 F	lung transplantation influenza	-	Abx	dead	8
38 M	HIV	1 wk	Abx	survived	2
56 M	COPD	-	MMF	survived	3
62 M	MDS	8 days	Abx	survived	The Present Case

M: male, F: female, NA: not available, Abx: antibiotics, IVIG: intravenous immunoglobulin, CPA: cyclophosphamide, CsA: cyclosporine A, MMF: mycophenolate mofetil, JDM: juvenile dermatomyositis, UCTD: undifferentiated connective tissue disease, MWS: Marden-Walker Syndrome, HIV: human immunodeficiency virus, COPD: chronic obstructive pulmonary disease, MDS: myelodysplastic syndromes

in a patient with tuberculosis (16). When the diagnosis of AFOP is made, the possibility of infection should first be ruled out. Only then should corticosteroid therapy be initiated as soon as possible.

In conclusion, we reported a case of severe AFOP that was successfully treated using corticosteroid monotherapy, and described the histological changes that took place as AFOP transitioned into OP during the healing process. At present it is unknown whether the early initiation of corticosteroid therapy or the favorable chromosomal abnormality associated with the patient's MDS were prognostic factors in the present case. Furthermore, it is not clear whether the histological change from AFOP to OP is universal or whether it was specific to this case. These two points merit further investigation.

The authors state that they have no Conflict of Interest (COI).

Acknowledgement

We are grateful to Tamiko Takemura, MD, at Japanese Red Cross Medical Center, for her pathological advice.

References

1. Beasley MB, Franks TJ, Galvin JR, Gochuico B, Travis WD. Acute fibrinous and organizing pneumonia: a histologic pattern of lung injury and possible variant of diffuse alveolar damage. *Arch Pathol Lab Med* **126**: 1064-1070, 2012.
2. Papaka V, Hussain MA, Niazi M, Diaz-Fuentes G. Severe acute fibrinous and organizing pneumonia causing acute respiratory distress syndrome and shock. *J Bronchol Intervent Pulmonol* **18**: 269-273, 2011.
3. Bhatti S, Hakeem A, Torrealba J, McMahon JP, Meyer KC. Severe acute fibrinous and organizing pneumonia (AFOP) causing ventilator failure: successful treatment with mycophenolate mofetil and corticosteroids. *Respir Med* **103**: 1764-1767, 2009.
4. Kang HJ, Choi SM, Jeong YJ, et al. Severe acute fibrinous and organizing pneumonia with acute respiratory distress syndrome. *Tuberc Respir Dis* **71**: 368-372, 2011.
5. Prahald S, Bohnsack JF, Maloney CG, Leslie KO. Fatal acute fibrinous and organizing pneumonia in a child with juvenile dermatomyositis. *J Pediatr* **146**: 289-292, 2005.
6. Valim V, Rocha RH, Couto RB, Paixão TS, Serrano EV. Acute fibrinous and organizing pneumonia and undifferentiated connective tissue disease: a case report. *Case Rep Rheumatol* **2012**: 549298, 2012.
7. López-Cuenca S, Morales-García S, Martín-Hita A, Frutos-Vivar F, Fernández-Segoviano P, Esteban A. Severe acute respiratory failure secondary to acute fibrinous and organizing pneumonia requiring mechanical ventilation: a case report and literature review. *Respir Care* **57**: 1337-1341, 2012.
8. Otto C, Huzly D, Kemna L, et al. Acute fibrinous and organizing pneumonia associated with influenza A/H1N1 pneumonia after lung transplantation. *BMC Pulm Med* **13**: 30, 2013.
9. Horiike S, Taniwaki M, Misawa S, et al. The unbalanced 1;7 translocation in de novo myelodysplastic syndrome and its clinical implication. *Cancer* **65**: 1350-1354, 1990.
10. Komiya I, Tanoue K, Kakinuma K, et al. Superoxide anion hyperproduction by neutrophils in a case of myelodysplastic syndrome. Association with Sweet's syndrome and interstitial pneumonia. *Cancer* **1**: 67, 1991.
11. Matsushima T, Murakami H, Kim K, et al. Steroid-responsive pulmonary disorders associated with myelodysplastic syndromes with der (1q;7p) chromosomal abnormality. *Am J Hematol* **50**: 2, 1995.
12. Marisavljevic D, Kraguljac N, Rolovic Z. Immunologic abnormalities in myelodysplastic syndromes. *Med Oncol* **23**: 385-391, 2006.
13. Matsushima T, Murakami H, Kim K, et al. Steroid-responsive pulmonary disorders associated with myelodysplastic syndromes with der (1q;7p) chromosomal abnormality. *Am J Hematol* **50**: 110-115, 1995.
14. Vasu TS, Cavallazzi RC, Hirani A, Marik PE. A 64-year-old male with fever and persistent lung infiltrate. *Respir Care* **54**: 1263-1265, 2009.
15. Merrill AL, Smith H. Myelodysplastic syndrome and autoimmunity: a case report of an unusual presentation of myelodysplastic syndrome. *Case Rep Hematol* **2011**: 560106, 2011.
16. Feng AN, Cai HR, Zhou Q, Zhang YF, Meng FQ. Diagnostic problems related to acute fibrinous and organizing pneumonia: misdiagnosis in 2 cases of lung consolidation and occupying lesions. *Int J Clin Exp Pathol* **7**: 4493-4497, 2014.

The Internal Medicine is an Open Access article distributed under the Creative Commons Attribution-NonCommercial-NoDerivatives 4.0 International License. To view the details of this license, please visit (<https://creativecommons.org/licenses/by-nc-nd/4.0/>).