

OTOLOGY

Comparison between linear incision and punch techniques for bone anchored hearing aid surgery

Confronto tra incisione lineare e tecnica punch nella chirurgia degli impianti a conduzione ossea

Sabrina De Stefano¹, Paolo Mochi², Alessandra Murri², Domenico Cuda²

¹ Department of Otorhinolaryngology and Otoneurosurgery, University Hospital of Parma, Parma, Italy; ² Department of Otorhinolaryngology, "Guglielmo da Saliceto" Hospital, Piacenza, Italy

SUMMARY

Objectives. To evaluate mean surgical time, incidence of soft tissue reactions, implant survival and intraoperative complications in both minimally invasive ponto surgery (MIPS) and the linear incision with tissue preservation technique (LT).

Methods. A retrospective review was carried out on 48 bone anchored hearing system (BAHS) patients between 2014 and 2019: 13 patients had undergone LT and formed one group, while 35 patients had undergone MIPS and formed the second group. Mean surgical time, intraoperative complications, implant loss and skin reaction were assessed at each post-operative examination. The Mann-Whitney U test was used for statistical analysis.

Results. The difference in the mean surgical time of 15 mins for MIPS and 36 mins for LT was statistically significant. No intraoperative complications were reported and implant survival was 100% in both groups. The incidence of adverse skin reactions was 7.7% for the LT group and 0% for the MIPS group at first follow-up examination.

Conclusions. Surgical mean time is shorter for MIPS, making this procedure more suitable for local anaesthesia and more cost effective. Moreover, both LT and MIPS demonstrate good surgical outcomes in terms of skin reactions according to Holgers score and equally excellent implant survival.

KEY WORDS: minimally invasive ponto surgery, linear incision technique with tissue preservation, bone anchored hearing system

RIASSUNTO

Obiettivo. Confrontare la tecnica dell'incisione lineare con conservazione del tessuto sottocutaneo (LT) e la tecnica MIPS valutando le differenze nella durata della chirurgia, l'incidenza delle reazioni cutanee avverse, la perdita dell'impianto e le complicanze intraoperatorie.

Metodi. Presso il nostro centro di Audiologia tra il 2014 e 2019 sono stati sottoposti ad intervento chirurgico per l'applicazione di BAHS 48 pazienti: 13 pazienti mediante LT e 35 pazienti mediante MIPS.

Risultati. La durata media della chirurgia è stata di 15 minuti per la tecnica MIPS e 36 minuti per la LT con una differenza statisticamente significativa. Non sono state riscontrate complicanze intraoperatorie, la perdita dell'impianto è stata dello 0% in entrambi i gruppi. L'incidenza di reazioni avverse cutanee è stata del 7,7% per il gruppo LT e dello 0% per il gruppo MIPS alla prima visita post-operatoria.

Conclusioni. La durata dell'intervento chirurgico è più breve per la MIPS rispetto alla tecnica LT, rendendo questa procedura più adatta all'anestesia locale e più vantaggiosa in termini di costi sanitari. Inoltre, sia la LT che la MIPS mostrano buoni risultati chirurgici per quanto riguarda la riduzione delle reazioni cutanee avverse, le complicanze intraoperatorie e la perdita dell'impianto.

PAROLE CHIAVE: chirurgia mininvasiva ponto, incisione lineare, protesi acustica ancorata all'osso

Received: August 12, 2020

Accepted: March 13, 2021

Correspondence

Sabrina De Stefano

Department of Otorhinolaryngology, "Guglielmo da Saliceto" Hospital, via Cantone del Cristo 40, 29121 Piacenza, Italy

E-mail: sbrndestefano@gmail.com

Funding

None.

Conflict of interest

The Authors declare no conflict of interest.

How to cite this article: De Stefano S, Mochi P, Murri A, et al. Comparison between linear incision and punch techniques for bone anchored hearing aid surgery. *Acta Otorhinolaryngol Ital* 2021;41:474-480. <https://doi.org/10.14639/0392-100X-N1048>

© Società Italiana di Otorinolaringoiatria e Chirurgia Cervico-Facciale



OPEN ACCESS

This is an open access article distributed in accordance with the CC-BY-NC-ND (Creative Commons Attribution-NonCommercial-NoDerivatives 4.0 International) license. The article can be used by giving appropriate credit and mentioning the license, but only for non-commercial purposes and only in the original version. For further information: <https://creativecommons.org/licenses/by-nc-nd/4.0/deed.en>

Introduction

Bone anchored hearing systems (BAHS) were introduced for the first time in 1977 and have significantly improved the quality of life and the hearing ability of patients with conductive or mixed hearing loss since then¹. The BAHS consists of a fixture implanted in the temporal bone, an abutment breaching the skin barrier and a sound processor coupled to the abutment. When the osseointegration of the fixture is complete, the vibrations reach the otic capsule through the temporal bone without any soft tissue dampening and evoke basilar membrane and hair cell stereociliary deflections^{2,3}. For many years, different surgical techniques including wide soft tissue reduction around the abutment were considered to be the gold standard. A thin tissue was believed to reduce the related implant mobility and thereby prevent skin overgrowth⁴. However, these skin thinning procedures were related to significant complications such as flap infections, necrosis with healing by second intention and skin overgrowth around the abutment, thus necessitating further tissue reduction procedures⁴. Less invasive surgical techniques without subcutaneous tissue reduction have been developed in recent years. The “*linear incision with tissue preservation*” technique (LT) was first described by Hultcrantz in 2011⁴. The LT results in less scarring, good sensibility around the abutment and better cosmetics compared to previous surgical procedures using skin thinning⁵. More recently, the minimally invasive ponto surgery (MIPS) technique has been introduced. MIPS is an even less traumatic surgery in which only a punch is used to remove tissue where the implant is then placed^{6,7}. The aim of the present study was to compare surgical post-operative outcomes of the LT technique with those of MIPS.

Materials and methods

A retrospective review of all patients referred to the AUSL Piacenza centre who underwent BAHS surgery between 2014 and 2019 was carried out. In total, surgical and follow-up data on 48 patients was collected. Of these, LT was performed in 13 patients between 2014 and 2017 and 35 patients underwent surgery using the MIPS technique between 2017 and 2019. The surgical time was recorded starting from the local anaesthetic infiltration until the placement of healing cup for both procedures. All of the operations were performed in a single stage by two experienced surgeons under local anaesthesia except for two patients who received general anaesthesia because canal wall up tympanoplasty was carried out during the same surgical procedure; only the surgical time for the BAHS implantation procedure was considered in these two cases. The patients from the LT group and from the MIPS group

had their first follow-up examination around 15 days after surgery and the second follow-up examination between 1 to 2 months after surgery, usually coinciding with sound processor loading and activation. Additional data from follow-up visits were included. The mean follow-up time was 42 months for the LT group and 14 months for the MIPS group. The duration of BAHS surgery and intraoperative complications were also evaluated. Furthermore, implant loss and skin reactions grading by Holgers score system⁸ (Tab. I) were assessed at every post-operative examination. The data were then analysed using IBM SPSS Statistics for Windows, Version 20.0. (Armonk, NY: IBM Corp.). The Mann-Whitney U test was used for statistical analysis and a p-value < 0.05 was considered significant. Lastly, the present study was reviewed and approved by the regional ethics committee (Approval number: 361.2018. DISP.AUSLPC).

Linear incision technique

The site of implantation was placed about 55 mm posterior and superior to the external auditory canal and was marked with dye. The skin thickness was measured using a needle and forceps to choose the correct abutment length. Local anaesthetic infiltration was provided, and then a 30 mm long incision deep into the periosteum was made near the dye. The incision was widened using a retractor, and the periosteum was gently detached from the bone. The hole for the fixture was drilled under saline irrigation in the temporal bone after which a punch was used to obtain a soft tissue hole at the dye marker in front of the linear incision through which the fixture was placed without any other surrounding soft tissue removal. Following this, the fixture with pre-mounted abutment was set in place and a healing cap was then placed over the abutment, and finally the skin was sutured.

MIPS technique

The site of implantation as well as the skin thickness measurement are the same as in the previous procedure. After the local anaesthetic injection, a punch was used to cut a cylinder of skin and subcutaneous tissue in a single step

Table I. Holgers classification system for BAHS.

| Grade | Description |
|-------|--|
| 0 | Normal skin around the abutment |
| 1 | Redness around the abutment |
| 2 | Redness, moistness and moderate swelling |
| 3 | Redness, moistness and moderate swelling with tissue granulation around the abutment |
| 4 | Signs of infection resulting in removal of the implant |

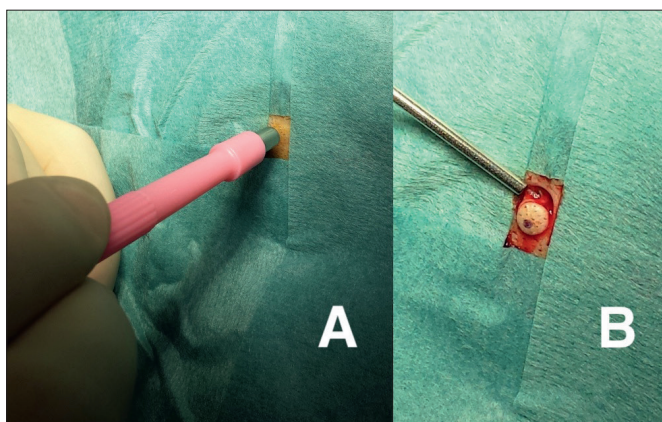


Figure 1A and 1B. The punch is used to cut a cylinder of skin and subcutaneous tissue in a single step.

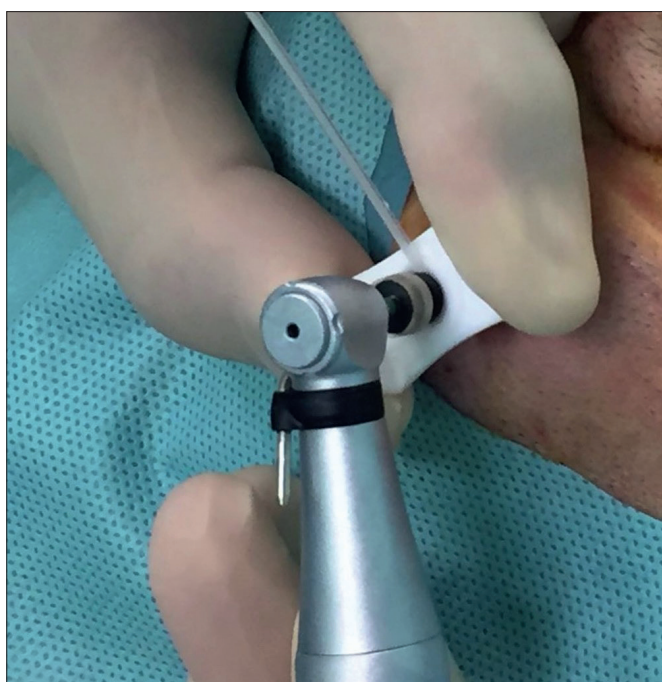

Figure 2. Under copious irrigation the bone drilling is performed using a cannula to protect the surrounding tissue.

(Fig. 1A and 1B). Next, the periosteum was gently dissected and detached from the underlying bone using a periosteal elevator. Following this, the bone was drilled using a cannula under copious irrigation to protect the surrounding tissue and then both the fixture and the abutment were set in place (Fig. 2). Lastly, a healing cap was applied over the abutment.

At the end of both procedures, gauze covered in steroid-antibiotic ointment (0.1% gentamicin + 0.05% betamethasone) was applied around the abutment under the healing cup.

Results

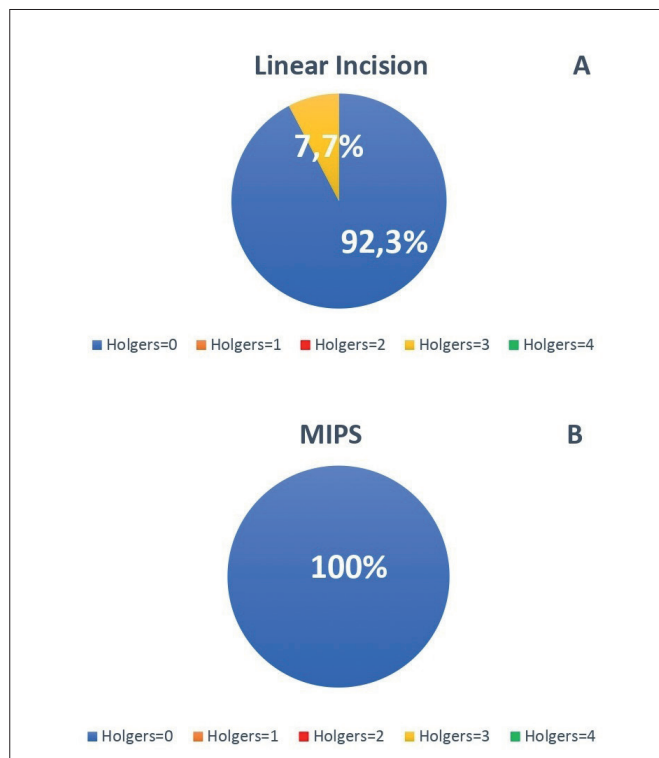
The ages of the cohort ranged from 19 to 81 years, the majority of patients (58.3%) being 51 to 75 years of age with a predominance of women (68.7%) (Tab. II). The implants used were Ponto Wide (N = 38) and Ponto BHX (N = 10) with pre-mounted abutments (all produced by Oticon Medical AB, Askim, Sweden). The skin thickness of patients varied from 3 to 11 mm, making use of all available abutment lengths (Tab. III). The mean surgical time was 15 min for MIPS (SD 6, range 7-25 mins) and 36 mins for LT (SD 10, range 27-62 mins). This difference was statistically significant ($p < 0.001$). No intraoperative complications were reported in either group. The wounds were completely healed (no skin reactions, Holgers = 0) at first follow-up examination in all patients except for one in the LT group (Holgers = 3), which was most likely caused by excessive bandage compression. This patient was successfully treated with oral and topical antibiotics for one week. No skin overgrowth, skin dehiscence or retroauricular pain were detected in either group. Implant survival was 100% in both groups. At first follow-up examination, the incidence of adverse skin reactions was 7.7% for LT and 0% for MIPS (Fig. 3A and 3B, Tab. III). In fact, 98% of the wounds were scored with Holgers = 0. At second and at last follow-up examinations, no adverse skin reactions were reported in either group. As an example, Figure 4 shows the outcome

Table II. Cohort features.

| | Linear incision | MIPS | All |
|----------------------|-----------------|------------|------------|
| Age (N, %) | | | |
| 18-50 years | 1 (7.6%) | 15 (42.8%) | 16 (33.3%) |
| 51-75 years | 11 (84.6%) | 17 (48.5%) | 28 (58.3%) |
| > 75 years | 1 (7.6%) | 3 (8.5%) | 4 (8.3%) |
| Gender (N, %) | | | |
| Men | 2 (15.3%) | 13 (37.1%) | 15 (31.2%) |
| Women | 11 (84.6%) | 22 (62.8%) | 33 (68.7%) |

Table III. Surgical data.

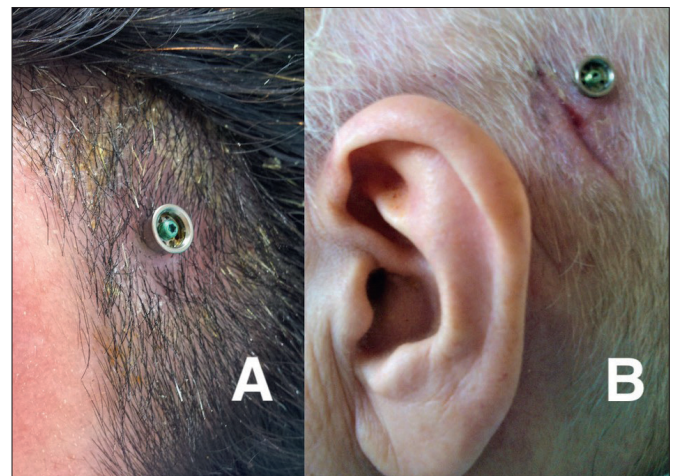
| | Linear incision | MIPS | All |
|-----------------------------------|-----------------|------------|------------|
| Implant (N, %) | | | |
| Wide Ponto | 13 (100%) | 25 (71.4%) | 38 (79.1%) |
| Ponto BHX | - | 10 (28.5%) | 10 (20.8%) |
| Abutment length (N, %) | | | |
| 6 mm | 2 (15.3%) | 4 (11.4%) | 6 (12.5%) |
| 9 mm | 9 (69.2%) | 17 (48.5%) | 26 (54.1%) |
| 12 mm | 2 (15.3%) | 13 (37.1%) | 15 (31.2%) |
| 14 mm | - | 1 (2.8%) | 1 (2%) |
| Surgical duration (min) | 36 min | 15 min | |
| Adverse skin reactions (%) | 7.7% | 0% | |

**Figure 3A and 3B.** Skin reactions scored by Holgers grading scale for LT group and for MIPS group at first follow-up visit.

of the wound and of the area around the abutment from a distance.

Discussion

Since the introduction of BAHS over 40 years ago, the hearing ability and quality of life of patients with conductive or mixed hearing losses have benefitted from the use of implants¹. The surgical technique to place the implants in the temporal bone did not change dramatically for several

**Figure 4A and 4B.** Comparison of healed wound appearance of MIPS and LT.

years and all of the surgical techniques were based on skin thinning procedures to remove subcutaneous tissue in the area around the abutment and either attach a skin graft or a skin flap directly onto the periosteum⁵.

Surgical outcomes of different techniques have varied over the years⁹. The most common complications addressed have been skin infections, flap necrosis and skin overgrowth as well as numbness and poor cosmetic appearance¹⁰. All of these complications can impact the satisfaction and acceptance of the device by patients. Most of the complications were associated with extensive soft tissue reduction around the abutment to reduce the mobility of the implants. The removal of all of the sebaceous glands and hair follicles was thought to reduce the rate of skin infection and inflammation, but previous studies have demonstrated that tissue thinning was only a theoretical benefit^{4,9,11}. The patients of our sample did not require any device explantation due to complications. Barbara et al. described seven subjects

out of 52 with a percutaneous device that needed explantation because of skin complications, delayed osseointegration failure with fixture loss, or decreased bone conduction threshold¹².

During recent years less invasive surgical techniques without subcutaneous tissue reduction have been developed, for example the linear incision with tissue preservation technique was first described by Hulcrantz in 2011⁴. It was shown that after tissue reduction surgery, 43% of patients developed infections at the site of the abutment (Holgers 1-3), whereas only one patient (14%) who underwent LT without skin thinning developed an infection, and this patient got a Holgers score of 2⁴. Moreover, LT with tissue preservation was related to a reduction in numbness around the abutment, better cosmetic outcomes and reduced surgical time, and later became the new gold standard for BAHS surgical treatments. Van Der Stee et al. detected wound dehiscence in 28 implants that had been placed using LT with tissue reduction and 33.7% soft tissue reactions in the same group of patients. In contrast, 27.6% of soft tissue reactions in the LT with tissue preservation group were registered without any wound dehiscence¹³. Furthermore, Badran et al. reported that patient satisfaction with skin appearance after tissue removal was not significantly better compared to the cosmetic impact of common hearing aids^{14,15}. On the other hand, in patients who have benefitted from auditory implantable devices the quality of life improved with respect to wearing conventional hearing aids, but the aesthetic factor was not the most important aspect to consider among BAHS users. In fact, Monini et al. showed that when patients experience less invasive and shorter surgical procedure, they report a greater improvement in quality of life¹⁶.

An interesting hypothesis about histopathologic tissue reactions in the case of excessive skin removal has been proposed. The presence of the abutment breaching the skin barrier causes an inflammatory reaction that eventually leads to the accumulation of immunoreactive cells around it. If a bacterial infection occurs in this area, which has been surgically reduced, the amount of inflamed cells greatly increases resulting in redness, granulation and skin necrosis. On the other hand, if the skin is not thinned, the blood vessels can carry healing agents and the response to the infection is more effective. Therefore, tissue removal can destroy the blood supply and can increase scar formation around the abutment, reducing the chance of skin regeneration^{4,17}. Furthermore, the nerve fibres are also removed during the skin thinning procedure causing a numb sensation at the wound area. In a prospective study, Kruyt et al. compared the sensitivity and subjective numbness around the abutment in tissue preservation and tissue reduction

technique. The tissue cotton swab sensitivity test showed that the tissue preservation group had better sensitivity of the wound area and the difference was statistically significant. In line with this result, 52% of patients in the tissue reduction group experienced numbness compared to 4% of patients in the tissue preservation group¹⁸.

If skin thinning is found to be unnecessary, then the incision can even be avoided. In fact, the punch procedure was developed according to these new considerations, and released⁷. The punch procedure is an even less traumatic surgery for BAHS. This technique does not need any tissue reduction or an incision. It only needs a skin biopsy punch which removes a tissue cylinder down to the periosteum in a single step¹⁹.

An initial criticism of punch surgeries was poor visualisation during the temporal bone drilling which could harm the surrounding soft tissue and make the drilling process more difficult for the surgeon¹⁹. However, if the drill is pointed perpendicularly to the underlying bone and there is copious irrigation, incision is still unnecessary. The drilling step should be as short as possible and under copious cold irrigation to avoid heat damage, and the bone dust should be completely removed before the pre-mounted abutment is set in place. Furthermore, the surgical kit provided by Oticon Medical (MIPS) has a cannula that protects the surrounding tissue from heating and from any other trauma during the drilling²⁰. An important result was that the mean surgical time is shorter for MIPS (15 min, SD 6) compared with the LT (36 mins, SD 10), and this difference was statistically significant ($p < 0.001$). Gordon and Coelho reported a mean surgical time for MIPS of 13.4 mins against 49.2 mins for LT with tissue reduction¹⁹. Dumon et al. compared the surgical time between MIPS and BAHS implantation using an epidermal flap and soft tissue removal (dermatome group) and found that mean duration for MIPS was 15 mins and the surgical mean duration was 30 mins in the dermatome group²¹. In addition, the reported mean surgical time for MIPS in a multicentre study was 16 mins¹⁷. The impressive reduction of surgical time of MIPS compared with other surgical procedures makes this technique more suitable for local anaesthesia and more cost effective^{22,23}. Furthermore, Sardiwalla et al. investigated patient satisfaction using a Surgical Satisfaction Questionnaire (SSQ-8) modified for MIPS and found that patient experiences with MIPS were overwhelmingly positive. Indeed, all patients reported speedy recovery and a short surgical experience²⁴. Limbrick et al. recently described a modified minimally invasive technique (MMIT) consisting of a linear incision performed laterally each side of the soft tissue hole after the punch has been used. In this case, a linear incision allows better visualisation of the surgical field dur-

ing the drilling procedure. The authors evaluated the osseointegration failure rate in MIPS and MMIT. In fact, failure rates were 35% for MIPS and 14.6% for MMIT; all of these cases were early osseointegration failures. The higher failure rate of MIPS was related to the cannula to protect the soft tissue during the drilling procedure. In fact, the cannula can interfere with both the irrigation during the drilling phase and with the evacuation of the bone dust leading to increased temperature in the surrounding bone. Moreover, the same authors eventually abandoned both MIPS and MMIT due to the poor implant survival rate compared with LT with tissue preservation, ruling out tissue trapping as a cause of failure²⁵.

In the present study, no significant difference was found between LT and MIPS in terms of skin reaction graded by Holgers score, even though the mean follow-up duration was longer for the LT group than for the MIPS group. One patient from the LT group had a Holgers score of 3 at the first follow-up examination due to excessive bandage compression. There was mild skin inflammation with tissue granulation around the wound in absence of abutment pathological mobility. This case corroborates the hypothesis that a reduction of blood supply caused by either compression or by skin reduction impacts negatively on the tissue healing process. Nevertheless, after release of pressure and antibiotic treatment, the patient did not present further complications.

Implant survival was 100% in both groups, although two patients with single-sided deafness had their abutments removed, respectively, at 3 months and 2 years after the surgery due to no perceived stimulation benefit. The excellent implant survival rate in the cohort could be related to various factors: all of the patients were adults and all underwent a pre-operative high resolution temporal bone CT scan to evaluate bone thickness. This step is essential in choosing the correct abutment length and avoiding any soft tissue dumping after the surgery, which otherwise could have led to adverse skin reactions and osseointegration failure. All of the BAHS surgeries were performed by two experienced and well-trained surgeons, and it is fundamental to perfectly perform each surgical step to succeed. During surgery, the crucial steps to care about are: not damage the skin, fast drilling phase under copious irrigation and accurate bone dust removal prior to inserting the abutment. In addition, the need for daily skin cleaning around the abutment to reduce the risk of local infection is emphasised at each follow-up examination. Therefore, the patient centred preoperative planning along with correct surgical procedure and accurate postoperative counseling are the main factors that explain the excellent implant survival rate in our cohort.

Although the statistical analysis was carried out retrospec-

tively, the results were in line with previously published studies comparing MIPS and LT with tissue preservation. Moreover, the large sample size increases the statistical power and significance of the results.

Conclusions

LT with soft tissue preservation and MIPS demonstrate similar, good surgical outcomes in terms of skin reaction according to Holgers score during long lasting follow-up as well as equally good implant survival of 100%. Moreover, the present study shows that surgical mean time for MIPS is shorter than the surgical time for LT with tissue preservation.

Acknowledgements

Accepted for poster presentation at the 32nd Politzer Society Meeting/2nd World Congress of Otolaryngology; 28 May-1 June 2019 Warsaw, Poland.

References

- 1 Tjellstrom A, Granstrom G. Long-term follow-up with the bone-anchored hearing-aid: a review of the first 100 patients between 1977 and 1985. *Ear Nose Throat J* 1994;73:112-114.
- 2 Kiringoda R, Lusting LR. A meta-analysis of the complications associated with osseointegrated hearing aids. *Otol Neurotol* 2013; 34:790-794. <https://doi.org/10.1097/MAO.0b013e318291c651>
- 3 Stenfelt S. Implantable bone conduction hearing aids. *Adv Otorhinolaryngol* 2011;71:10-21. <https://doi.org/10.1159/000323574>
- 4 Hultcrantz M. Outcome of the bone-anchored hearing aid procedure without skin thinning: a prospective clinical trial. *Otol Neurotol* 2011;32:1134-1139. <https://doi.org/10.1097/MAO.0b013e31822a1c47>
- 5 Fontaine N, Hemar P, Schultz P, et al. BAHA implant: implantation technique and complications. *Eur Ann Otorhinolaryngol Head Neck Dis* 2014;131:69-74. <https://doi.org/10.1016/j.anorl.2012.10.006>
- 6 Johansson ML, Stokroos RJ, Banga R, et al. Short-term results from seventy-six patients receiving a bone-anchored hearing implant installed with a novel minimally invasive surgery technique. *Clin Otolaryngol* 2017;42:1043-1048. <https://doi.org/10.1111/coa.12803>
- 7 Goldman RA, Georgolios A, Shaia WT. The punch method for bone anchored hearing aid placement. *Otolaryngol Head Neck Surg* 2013;148:878-880. <https://doi.org/10.1177/0194599813476666>
- 8 Holgers KM, Tjellström A, Bjursten LM, et al. Soft tissue reactions around percutaneous implants: a clinical study of soft tissue conditions around skin penetrating titanium implants for bone-anchored hearing aids. *Am J Otol* 1988;9:56-59.
- 9 van de Berg R, Stokroos RJ, Hof JR, et al. Bone-anchored hearing aid: a comparison of surgical techniques. *Otol Neurotol* 2010;31:129-135. <https://doi.org/10.1097/MAO.0b013e3181c29fec>
- 10 Steehler MW, Larner SP, Mintz JS, et al. A comparison of the operative techniques and the postoperative complications for bone-anchored hearing aid implantation. *Int Arch Otorhinolaryngol* 2018;22:368-373. <https://doi.org/10.1055/s-0037-1613685>
- 11 Calon TGA, Johansson ML, de Bruijn AJG et al. Minimally inva-

- sive ponto surgery versus the linear incision technique with soft tissue preservation for bone conduction hearing implants: a multicenter randomized controlled trial. *Otol Neurotol* 2018;39:882-893. <https://doi.org/10.1097/MAO.0000000000001852>
- ¹² Barbara M, Covelli E, Filippi C, et al. Transitions in auditory rehabilitation with bone conduction implants (BCI). *Acta Otolaryngol* 2019;139:379-382. <https://doi.org/10.1080/00016489.2019.1592220>
- ¹³ van der Stee EHH, Strijbos RM, Bom SJH, et al. Percutaneous bone-anchored hearing implant surgery: linear incision technique with tissue preservation versus linear incision technique with tissue reduction. *Eur Arch Otorhinolaryngol* 2018;275:1737-1747. <https://doi.org/10.1007/s00405-018-5005-5>
- ¹⁴ Badran K, Bunstone D, Arya AK, et al. Patient satisfaction with the bone-anchored hearing aid: a 14-year experience. *Otol Neurotol* 2006;27:659-666. <https://doi.org/10.1097/01.mao.0000226300.13457.a6>
- ¹⁵ Shirazi MA, Marzo SJ, Leonetti JP. Perioperative complications with the bone-anchored hearing aid. *Otolaryngol Head Neck Surg* 2006;134:236-239. <https://doi.org/10.1016/j.otohns.2005.10.027>
- ¹⁶ Monini S, Bianchi A, Talamonti R, et al. Patient satisfaction after auditory implant surgery: ten-year experience from a single implanting unit center. *Acta Otolaryngol* 2017;137:389-397. <https://doi.org/10.1080/00016489.2016.1258733>
- ¹⁷ Larsson A, Wigren S, Andersson M, et al. Histologic evaluation of soft tissue integration of experimental abutments for bone anchored hearing implants using surgery without soft tissue reduction. *Otol Neurotol* 2012;33:1445-1451. <https://doi.org/10.1097/MAO.0b013e318268d4e0>
- ¹⁸ Kruyt IJ, Kok H, Bosman A, et al. Three-year clinical and audiological outcomes of percutaneous implants for bone conduction devices: comparison between tissue preservation technique and tissue reduction technique. *Otol Neurotol* 2019;40:335-343. <https://doi.org/10.1097/MAO.0000000000002105>
- ¹⁹ Gordon SA, Coelho DH. Minimally invasive surgery for osseointegrated auditory implants: a comparison of linear versus punch techniques. *Otolaryngol Head Neck Surg* 2015;152:1089-1093. <https://doi.org/10.1177/0194599815571532>
- ²⁰ Kim HHS, Kari E, Copeland BJ, et al. Standardization of the punch technique for the implantation of bone anchored auditory devices: evaluation of the MIPS surgical set. *Otol Neurotol* 2019;40:e631-e635. <https://doi.org/10.1097/MAO.0000000000002291>
- ²¹ Dumon T, Medina M, Sperling NM. Punch and drill: implantation of bone anchored hearing device through a minimal skin punch incision versus implantation with dermatome and soft tissue reduction. *Ann Otol Rhinol Laryngol* 2016;125:199-206. <https://doi.org/10.1177/0003489415606447>
- ²² Sardiwalla Y, Jufas N, Morris DP. Direct cost comparison of minimally invasive punch technique versus traditional approaches for percutaneous bone anchored hearing devices. *J Otolaryngol Head Neck Surg* 2017;46:46. <https://doi.org/10.1186/s40463-017-0222-2>
- ²³ Di Giustino F, Vannucchi P, Pecci R, et al. Bone-anchored hearing implant surgery: our experience with linear incision and punch techniques. *Acta Otorhinolaryngol Ital* 2018;38:257-263. <https://doi.org/10.14639/0392-100X-1694>
- ²⁴ Sardiwalla Y, Jufas N, Morris DP. Long term follow-up demonstrating stability and patient satisfaction of minimally invasive punch technique for percutaneous bone anchored hearing devices. *J Otolaryngol Head Neck Surg* 2018;47:71. <https://doi.org/10.1186/s40463-018-0316-5>
- ²⁵ Limbrick J, Muzaffar J, Kumar R, et al. Novel minimal access bone anchored hearing implant surgery and a new surface modified titanium implant, the Birmingham experience. *Otol Neurotol* 2019;40:1326-1332. <https://doi.org/10.1097/MAO.0000000000002423>