

Letter

A rare rhabdomyolysis appears after transrectal ultrasound guided prostate biopsy



Dear Editor,

Rhabdomyolysis (RM) is a pathophysiological process in which creatine kinase and myoglobin from skeletal muscle cells are released into circulation, leading to lethal acute kidney injury (AKI), hypovolemic shock, electrolyte disturbances and disseminated intravascular coagulation. Although injuries were the first reported and best-known reason for RM, infection currently contributes to approximately 5% of RM [1,2]. Transrectal ultrasound (TRUS)-guided prostate biopsy is the most common and important clinical procedure for diagnosing prostate cancer [3]. After a biopsy, hematuria and hematospermia are common but typically mild and self-limiting [4]. Other unusual complications, such as severe rectal bleeding, prostatic abscess and meningitis, have been reported [5–7]. However, rhabdomyolysis after conventional TRUS biopsy is very rare. We report one such case here.

A 69-year-old man who first underwent screening due to an elevated level of PSA (12.8 mg/L) presented no positive nodule on digital rectal examination. He had a 4-year history of hypertension and denied any alcohol, tobacco or drug use. His body mass index (BMI) was 20.7 kg/m². Further diffusion-weighted magnetic resonance imaging led to the suspicion of prostate cancer (Fig. 1). After the administration of 500 mg of levofloxacin once a day for 3 days and enema preparation, a 12-needle transrectal ultrasound-guided prostate biopsy was conducted in the out patient center. During the procedure, the patient was placed in the left lateral decubitus position without anesthesia. The procedure was performed successfully in 10min. Two days later, the patient returned complaining of obvious myalgia, hypodynamia, and mild to moderate fever and nausea. Laboratory testing indicated an elevated white blood cell count ($12.3 \times 10^9/L$), neutrophil percentage (92.2%), and procalcitonin (PCT) level (38.01 ng/mL). More importantly,

he had extremely high creatinine phosphokinase (13 322 U/L) and myoglobin (7 706.00 ng/mL) levels and an increased creatinine level (174 $\mu\text{mol/L}$) (Table 1). We considered infection-related RM as a possible diagnosis. On admission, the empiric broad-spectrum antibiotics piperacillin and tazobactam were immediately administered, and the administration continued for 15 days until the infection was controlled. Another important treatment was fully intravenous hydration to ensure fluid balance, which was critical for preventing further deterioration of renal function. Additionally, intravenous immunoglobulin therapy and other symptomatic treatments were prescribed. After active treatment, the patient fully recovered. All tissues were histologically confirmed as benign prostatic hyperplasia (Fig. 2), and marked changes in the level of PSA (16.76 mg/L) and the appearance of RM were not noted at the 4-year follow-up visit.

Some serious infections occur after TRUS biopsy, and antibiotic-resistant bacteria and inadequate prophylactic antibiotic administration might be two important reasons [4,8]. Fluoroquinolone-resistant organisms were found to be present in approximately 14%–25% of rectal swab cultures [9], and high-quality enemas prior to biopsy are strongly recommended. The most common symptom of serious infection is septic shock because of the release of secondary endotoxins from gram-negative bacteria. Whenever sepsis is suspected, potent broad-spectrum antibiotics need to be administered even before the blood bacterial culture results are obtained.

In this case, the patient complained of uncommon myalgia and hypodynamia instead of only chills and a fever. Meanwhile, high levels of creatinine phosphokinase and myoglobin also indicated a condition of greater complexity and rarity than just a bacterial infection. RM is a pathophysiological process in which muscle cell constituents are released into the circulation, causing renal dysfunction [10]. In peacetime, a diffuse metastatic infection of muscles during septicemia could be another

Peer review under responsibility of Second Military Medical University.

<https://doi.org/10.1016/j.ajur.2019.10.007>

2214-3882/© 2021 Editorial Office of Asian Journal of Urology. Production and hosting by Elsevier B.V. This is an open access article under the CC BY-NC-ND license (<http://creativecommons.org/licenses/by-nc-nd/4.0/>).

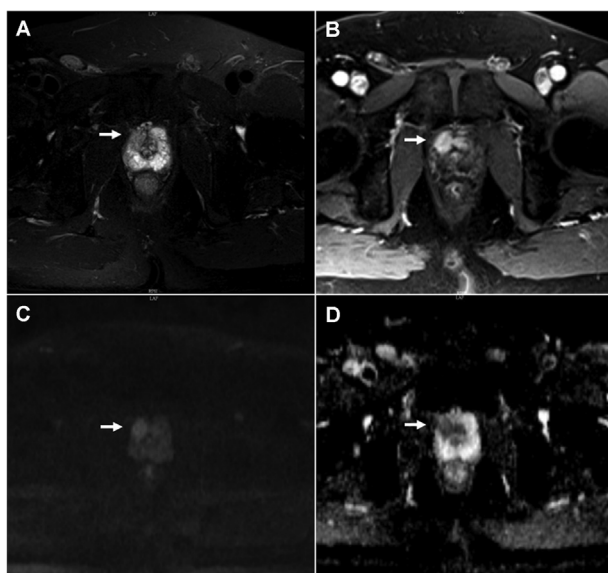


Figure 1 MRI images for the case. (A) Axial T2-weighted magnetic resonance image showing a hypointensity lesion within right peripheral zone (arrow); (B) Post-contrast axial T1-weighted image showing intense enhancement of the lesion; (C and D) Axial diffusion weighted image and apparent diffusion coefficient map showing restricted diffusion.

cause of rhabdomyolysis other than trauma [11]. Gram-negative organisms are more often the cause of bacterial septic rhabdomyolysis than gram-positive organisms [6]. The diagnosis of RM usually depends on whether there is a certain cause of RM, which results in a more than five-fold increase in creatine kinase (CK) in the serum, as well as a high level myoglobin in the serum and urine [12]. Although levofloxacin can lead to RM [13], in our case, laboratory tests (such as white blood cell [WBC],

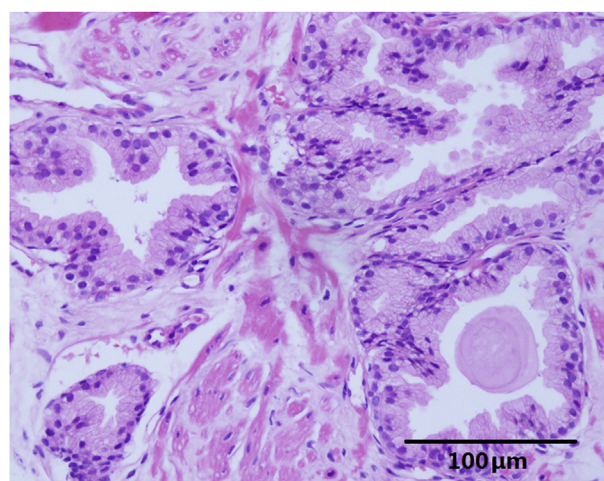


Figure 2 Histopathologic examination revealing benign prostatic hyperplasia.

neutrophil percentage and procalcitonin level) supported the etiology of a bacterial infection. In addition, the patient did not have any similar symptoms when he took levofloxacin before. Therefore, the patient was considered to have secondary RM immediately following bacterial infection. Piperacillin and tazobactam were the first drugs used to treat the sepsis.

On the other hand, the incidence of acute kidney injury (AKI) in patients with RM is approximately 13%–50%, and the mortality rate has been reported to be as high as 20% when rhabdomyolysis is complicated by AKI in traumatic injury cases [14]. In our case, the patient presented with AKI, as represented by the elevated creatinine level. After aggressive administration of intravenous fluids and antibiotics, the patient gradually recovered without renal replacement therapy. Because sepsis can sometimes occur after TRUS biopsy, we need to consider further possibility of

Table 1 Laboratory findings during hospitalization.

Day of admission	1	2	3	5	6	7	8	9	10	12	15	20	Reference range
BUN (mmol/L)	9.7	7.8	6.1	5.1	4.7	4.1	3.9	5.0	4.6	4.9	5.6	8.2	2.9–8.6
Cr ($\mu\text{mol/L}$)	174	160	115	106	101	96	86	97	90	92	92	102	53–115
Na ⁺ (mmol/L)	142	146	143	142	142	143	141	140	139	142	139	139	135–145
K ⁺ (mmol/L)	3.10	3.42	4.33	4.20	4.31	4.60	4.00	4.29	4.24	4.20	4.40	4.78	3.50–5.30
Ca ²⁺ (mmol/L)	2.23	2.01	2.09	2.12	2.00	–	–	–	–	2.21	2.30	2.52	2.10–2.60
Serum albumin (g/L)	34	33.3	31.7	30.4	–	–	30.7	–	–	37.7	38.8	43.5	35–50
Total protein (g/L)	62	55.4	57.4	58.2	–	–	64.9	–	–	69.4	71.3	84.2	64–87
ALT (IU/L)	111	88	88	126	–	–	104	–	–	59	44	34	1–40
AST (IU/L)	346	257	180	181	–	–	55	–	41	29	25	24	1–37
Myoglobin (ng/mL)	7 706	–	2 389	2 045	–	–	–	–	–	–	–	–	25–75
CPK (IU/L)	13 322	7 614	5 536	5 686	–	–	–	–	483	–	–	–	25–200
WBC $\times 10^9/\text{L}$	12.3	–	–	8.5	–	–	–	–	–	6.25	–	10.97	4.00–10.00
PLT $\times 10^9/\text{L}$	113	–	–	165	–	–	–	–	–	440	–	328	100–300
Hb (g/L)	151	–	–	141	–	–	–	–	–	131	–	145	120–160
PCT (ng/mL)	–	38.01	–	4.92	–	–	–	–	–	0.14	–	–	0.00–0.05

BUN, blood urea nitrogen; Cr, creatinine; ALT, alanine aminotransferase; AST, aspartate transaminase; CPK, creatinine phosphokinase; WBC, white blood cell; PLT, platelet; Hb, hemoglobin; PCT, procalcitonin; –, not available.

complications, such as RM and AKI, especially whenever patients complain about uncommon myalgia.

Author contributions

Study design: Wanmei Zhong, Junjie Cen.

Data acquisition: Yu Chen.

Data analysis: Junjie Cen.

Drafting of manuscript: Xu Chen, Junjie Cen.

Critical revision of the manuscript: Xu Chen, Wei Chen, Junhang Luo.

Conflicts of interest

The authors declare no conflict of interest.

Acknowledgements

This study is supported by the Science and Technology Planning Project of Guangdong Province, China (No. 2016A020215235).

References

- [1] Bywaters EG, Beall D. Crush injuries with impairment of renal function. *Br Med J* 1941;1:427–32.
- [2] Veenstra J, Smit WM, Krediet RT, Arisz L. Relationship between elevated creatine phosphokinase and the clinical spectrum of rhabdomyolysis. *Nephrol Dial Transplant* 1994;9:637–41.
- [3] Ren S, Chen R, Sun Y. Prostate cancer research in China. *Asian J Androl* 2013;15:350–3.
- [4] Loeb S, Vellekoop A, Ahmed HU, Catto J, Emberton M, Nam R, et al. Systematic review of complications of prostate biopsy. *Eur Urol* 2013;64:876–92.
- [5] Erdogan H, Ekinci MN, Hoscan MB, Erdogan A, Arslan H. Acute bacterial meningitis after transrectal needle biopsy of the prostate: a case report. *Prostate Cancer Prostatic Dis* 2008;11:207–8.
- [6] Kumar AA, Bhaskar E, Palamaner Subash Shantha G, Swaminathan P, Abraham G. Rhabdomyolysis in community acquired bacterial sepsis—a retrospective cohort study. *PLoS One* 2009;4:e7182. <https://doi.org/10.1371/journal.pone.0007182>.
- [7] Dell’atti L. Prostatic abscess after transrectal ultrasound-guided prostate biopsy. Case report. *G Chir* 2013;34:260–2.
- [8] Maselli G, Tucci G, Mazzaferro D, Ettamimi A, Sbröllini G, Cordari M, et al. Prolonged antibiotic therapy increases risk of infection after transrectal prostate biopsy: a case report after pancreatectomy and review of the literature. *Arch Ital Urol Androl* 2014;86:387–8.
- [9] Miura T, Tanaka K, Shigemura K, Nakano Y, Takenaka A, Fujisawa M. Levofloxacin resistant *Escherichia coli* sepsis following an ultrasound-guided transrectal prostate biopsy: report of four cases and review of the literature. *Int J Urol* 2008;15:457–9.
- [10] Fadila MF, Wool KJ. Rhabdomyolysis secondary to influenza A infection: a case report and review of the literature. *N Am J Med Sci* 2015;7:122–4.
- [11] Khan FY, Al-Ani A, Ali HA. Typhoid rhabdomyolysis with acute renal failure and acute pancreatitis: a case report and review of the literature. *Int J Infect Dis* 2009;13:e282–5. <https://doi.org/10.1016/j.ijid.2008.11.009>.
- [12] Chavez LO, Leon M, Einav S, Varon J. Beyond muscle destruction: a systematic review of rhabdomyolysis for clinical practice. *Crit Care* 2016;20:135.
- [13] John F, Oluronbi R, Pitchumoni CS. Levofloxacin-induced rhabdomyolysis: a case report. *J Med Case Rep* 2016;10:235.
- [14] Huerta-Alardín AL, Varon J, Marik PE. Bench-to bedside review: rhabdomyolysis—an overview for clinicians. *Crit Care* 2005;9:158–69.

Wanmei Zhong¹
 Junjie Cen¹
 Yu Chen
 Wei Chen
 Junhang Luo
 Xu Chen*

Department of Urology, The First Affiliated Hospital of Sun Yat-Sen University, Guangzhou, China

*Corresponding author.

E-mail address: chenxu25@mail.sysu.edu.cn (X. Chen)

25 July 2018

¹ Both authors contributed equally to this work.