

## Total hip replacement for an ochronotic patient: A technical trick

Authors' Contribution:  
Study Design A  
Data Collection B  
Statistical Analysis C  
Data Interpretation D  
Manuscript Preparation E  
Literature Search F  
Funds Collection G

A **Oguz Cebesoy**  
B **Mustafa Isik**  
D **Mehmet Subasi**  
E **Abbas Kaya**  
F **Fethi Bilgin**  
F **Oğuz Kaya**

Department of Orthopedics and Traumatology, Gaziantep University Faculty of Medicine, Gaziantep, Turkey

**Corresponding Author:** Oguz Cebesoy, e-mail: [ocebesoy@yahoo.com](mailto:ocebesoy@yahoo.com) or [ocebesoy@mynet.com](mailto:ocebesoy@mynet.com)

**Patient:** Male, 46  
**Final Diagnosis:** Akkaptonuria  
**Symptoms:** Hip pain  
**Medication:** —  
**Clinical Procedure:** Total hip replacement  
**Specialty:** Orthopedics and Traumatology

**Objective:** Unusual or unexpected effect of treatment





**Background:** Ochronosis is an inherited metabolic disease in which there is an accumulation of excessive amounts of homogentisic acid in the connective tissue. As the disease progresses, the chronic inflammation in the damaged tissue can cause degeneration and osteoarthritis. There is no specific treatment for ochronosis because it is a rare disease and arthroplasty is seldom performed.

**Case Report:** We report the case of a 46-year-old male patient with ochronosis, who underwent an arthroplasty of the right hip due to osteoarthritis. The problems encountered during surgery are reported and discussed.

**Conclusions:** Arthroplasty is a highly effective procedure for ochronotic patients. Particular attention to the surgical step is highly advised.

**MeSH Keywords:** Akkaptonuria • Ochronosis • Orthopedic Procedures • Arthroplasty, Replacement, Hip

**Full-text PDF:** <http://www.amjcaserep.com/download/index/idArt/890008>

 1085  —  4  6

## Background

Ochronosis is an inherited metabolic disease that causes a brownish-black pigmentation of the connective tissue, with a prevalence ranging from 1 case per 1000,000 to 1 case per 250,000 population [1]. Homogentisic acid oxidase enzyme deficiency is known to play a role in the pathogenesis of the disease. As a result of this deficiency, clinically, there is an accumulation of excessive amounts of homogentisic acid in the connective tissue, associated with an increased pigmentation and the attenuation of the connective tissue. As the disease progresses, the chronic inflammation in the damaged tissue can cause degeneration and osteoarthritis [2].

There is currently no specific treatment for ochronosis. Although there are no published series, case reports in the literature indicate that in these patients arthroplastic surgery is as successful as arthroplasties performed in patients with degenerative osteoarthritis [3]. Because it is a peculiar disease and arthroplasty is rarely performed, there is no data in the literature about the special points to be considered during arthroplasty.

In this case report, a 46-year-old male patient with ochronosis is presented, who underwent arthroplasty of the right hip due to osteoarthritis. The problems encountered during surgery are reported and discussed. We obtained the patient's informed written consent for print and electronic publication of this case report.

## Case Report

A 46-year-old male patient, with occasional pain in the right hip pain for 3 years, was admitted to our hospital because the pain that now continued even at rest and did not respond to pain killers. At the initial assessment of the patient, he could walk about 100 meters, but, due to the hip pain, seemed to have extreme difficulty in climbing stairs. The patient had no history of continuous drug use and no chronic disease history. No other family members had similar complaints. On physical examination, painful right hip joint movements and a 2-cm shortening of the right lower extremity were detected. The abduction and the adduction were limited by 10 degrees compared to the other hip. In addition, there was a flexion contracture of 15 degrees in the same hip. The radiographic examination revealed an irregularity of the femoral head, narrowing of the hip joint space, and severe joint degeneration (Figure 1).

Supplementary radiological examination was considered unnecessary, and the patient was diagnosed with idiopathic avascular necrosis with underlying osteoarthritis. A total joint replacement was planned. Informed consent was obtained from the patient. After routine preparations, the patient was taken

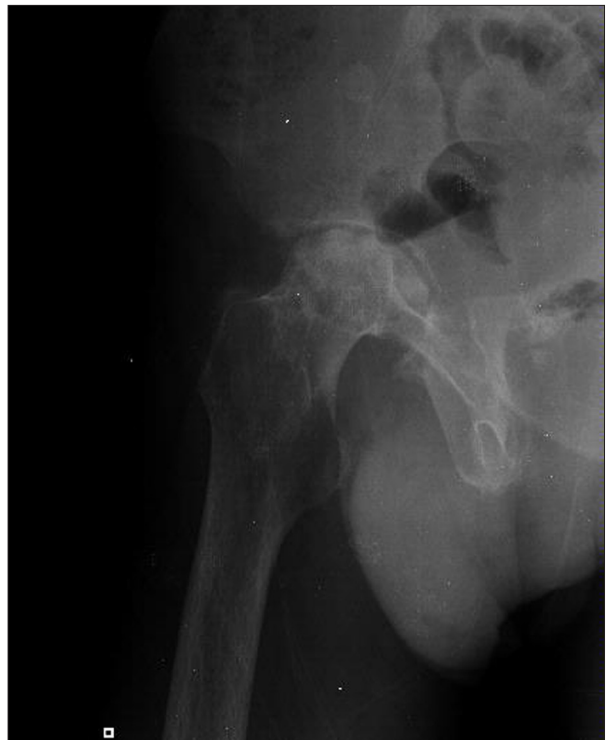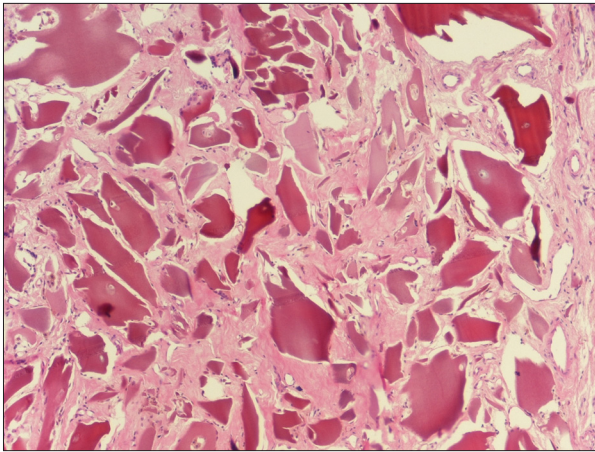


Figure 1. Classic degenerative changes at hip joint.

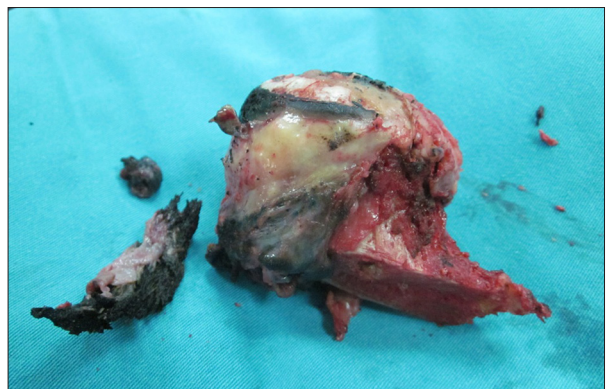

Figure 2. Dark, hard and thickened capsule with femoral head-neck.

to the operating room. Positioned in lateral decubitus position, the right hip was reached via the posterior approach. After incising the skin and the subcutaneous tissue, the external rotator muscles were lifted. The joint capsule was black. In the meantime, it was also noted that the normal consistency of the capsular tissue was lost, and it was very hard and contracted. Although the capsule was completely excised posteriorly, the dislocation of the femoral head was quite difficult (Figure 2). During the acetabular reamerization, the bone seemed to be softer than normal, with degenerative arthritis regardless of the age of the patient and the joint capsule, and there was a rapid deepening of the acetabular reamer. For this reason, the remaining portion of the acetabulum and the femoral medulla

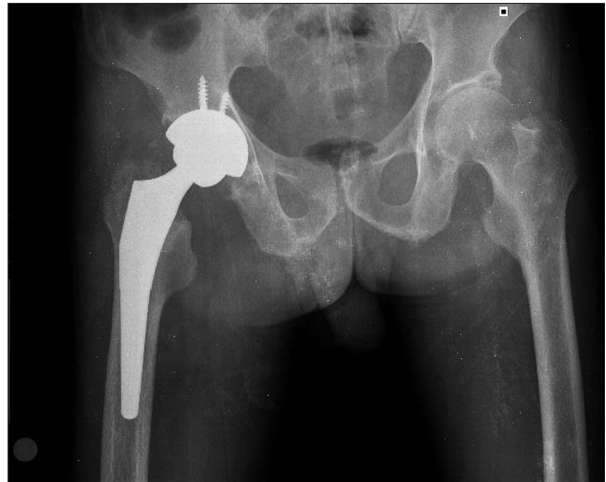

**Figure 3.** Cartilage pigmentation and histiocytic giant cell reaction (HE  $\times 40$ ).

were treated softly, when reamerized. Once the reamerization was done, the total hip replacement was completed using a ceramic acetabular cup of appropriate size and a ceramic femoral head, and the in the hip joint was reduced. During the intraoperative stabilization control, the femoral head appeared to be luxated by a forced flexion and minimal adduction. Due to ochronosis, the anterior portion of the joint capsule was very hard and contracted and was disrupting the movements of the hip joint, thereby causing dislocations. The anterior capsule was removed completely and the reduction of the prosthesis was restored. The wound was closed after placing a hemovac drain. No intraoperative complications were observed. The patient was mobilized full load on the 1<sup>st</sup> postoperative day and was discharged on the 3<sup>rd</sup> day. The histopathological examination of the remains of the bone and soft tissue removed during surgery revealed multiple pigmented areas, reactive giant cells, and thickened and inflamed synovium, which are the classic findings of ochronosis (Figure 3). During the control visit at the end of the 6<sup>th</sup> month, the patient was pain-free, had a fully mobile hip joint, and was extremely satisfied with the result. The radiological evaluation revealed a very good position of the prosthesis components (Zimmer, USA) (Figure 4).

## Discussion

Ochronosis is a musculoskeletal manifestation of alkaptonuria, a rare disease caused by a loss-of-function mutation on chromosome 3q, which leads to a defect in the homogentisate 1, 2-dioxygenase (HGO), or homogentisate 1, 2-dioxygenase enzymes [2]. This enzyme is responsible for the breakdown of homogentisic acid (HGA). The defective enzyme leads to a build-up of HGA in tissues and blood over the years, and polymers of HGA are deposited in the tissues, causing the dark pigmentation encountered in these patients [4–6]. Ochronosis, or the



**Figure 4.** Well integrated and positioned component.

deposition of this pigment, affects the entire body. Alkaptonuria causes progressive ochronotic arthropathy of the large weight-bearing joints [5,6]. The knee is the most frequently affected joint, followed by the hip [6]. The disease is usually asymptomatic until the involvement of the joints. After the development of ochronotic arthropathy, severe joint involvement occurs. The disease leads to degeneration of the joints, especially in the advanced stages. Today there is still no effective treatment to stop the disease completely. In case of the arthropathic changes, which are rarely reported in the literature, extremely good results can be obtained by arthroplasty. During our literature search, we found no comparable problems as in our operation, reported during arthroplasty due to ochronosis. The reason for this may be the very rare occurrence of this disease and therefore the very small number of arthroplasty operations for this indication. It was remarkable that the problems we came across were not mentioned in the few cases reported in the literature. In ochronotic cases, we recommend complete removal of the joint capsule during hip joint replacement surgery, if the diagnosis has been made before the surgery, or it can be made due to the gross appearance of tissue during the surgery. We believe that arthroplasty surgery performed with particular attention to these points will be highly effective in pain control and in preserving the joint mobility in patients with ochronosis.

## Conclusions

Arthroplasty is a highly effective procedure for ochronotic patients. Particular attention to the surgical step is highly advised.

## Statement

The authors have no conflicts of interest.

## References:

---

1. Zatková A, de Bernabé DB, Poláková H et al: High frequency of alkaptonuria in Slovakia: evidence for the appearance of multiple mutations in HGO involving different mutational hot spots. *Am J Hum Genet*, 2000; 67(5): 1333–39
2. Selvi E, Manganelli S, Mannoni A et al: Chronic ochronotic arthritis: clinical, arthroscopic, and pathologic findings. *J Rheumatol*, 2000; 27(9): 2272–74
3. Spencer JM, Gibbons CL, Sharp RJ et al: Arthroplasty for ochronotic arthritis: no failure of 11 replacements in 3 patients followed 6–12 years. *Acta Orthop Scand*, 2004; 75(3): 355–58
4. Fernández-Cañón JM, Granadino B, Beltrán-Valero de Bernabé D et al. The molecular basis of alkaptonuria. *Nat Genet*, 1996; 14(1): 19–24
5. Gaines JJ Jr: The pathology of alkaptonuric ochronosis. *Hum Pathol*, 1989; 20(1): 40–46
6. O'Brien W, La Du BN, Bunim JJ: Biochemical, pathologic and clinical aspects of alcaptonuria, ochronosis, and chronotic arthropathy. *Am J Med*, 1963; 34: 813–38