



Case report

Complete remission of peritonitis in a patient with luteinized thecomas of the type typically associated with sclerosing peritonitis using GnRH agonist and anti-estrogen



Maan Al Halabi^a, Janah El Hassan^b, Selim M. Nasser^{a,*}

^a School of Medicine, Lebanese American University, Lebanon

^b Department of Obstetric Gynecology, Gynecologic Oncology, Clemenceau Medical Center, Beirut, Lebanon

ARTICLE INFO

Article history:

Received 26 August 2015

Received in revised form 13 November 2015

Accepted 19 November 2015

Available online 27 November 2015

Keywords:

Luteinized thecomas

Sclerosing peritonitis

GnRH agonist

Anti-estrogen

1. Case report

A 42-year-old woman presented for recurrent episodes of diffuse abdominal pain and, discomfort with increasing abdominal girth accompanied by heavy menses, urinary frequency and constipation. Her past medical history is significant for systemic lupus erythematosus. CT scan and ultrasound of the abdomen and pelvis revealed bilateral large solid adnexal masses associated with large amounts of free fluid in the abdomen and Douglas pouch. CA 125 antigen level was only slightly elevated.

The patient underwent total hysterectomy with bilateral salpingo-oophorectomy that showed an 11 cm × 8 cm right adnexal mass and a 13 cm × 8 cm left mass, both with smooth bosselated intact surfaces and fibrous white-tan edematous cut surfaces oozing fluid (Fig. 1). Microscopic examination revealed a proliferation of spindled cells with luteinized cells, prominent mitotic activity and entrapped cystic follicles (Fig. 2), diagnostic of luteinizing thecomas of the type typically associated with sclerosing peritonitis (LTSP). Cytologic evaluation of the abdominal fluid revealed reactive mesothelial cells. No omental biopsy was performed.

The post-operative course was marked by worsening of the patient's peritoneal manifestations. A CT scan showed increased peritoneal fluid with multi-loculated fluid collections and the appearance of few small pelvic lymph nodes. Initially these findings were interpreted as signs of infectious peritonitis and antibiotics were administered. However, the patients did not improve with antibiotics and infectious peritonitis was ruled out by culture as well as cytologic examination of aspirated peritoneal fluid, which showed reactive mesothelial cells and no acute inflammation. Another laparotomy was being considered, but the histopathologic examination established the diagnosis of luteinizing thecoma, and highlighted its known association with peritoneal lesions. The diagnosis of sclerosing peritonitis was then considered in this context. Subsequently, the patient was treated with Antiestrogen (Tamoxifen 20 mg PO QD), and GnRH agonist (Goserelin 3.6 mg s/c every 3 weeks for 3 months), Corticosteroids (Prednisone 30 mg PO BID) and Proton Pump inhibitor. She improved significantly and recovered in a 2-month period, despite an episode of pulmonary embolism. The patient was monitored periodically and was last seen in complete remission, five years after her surgery.

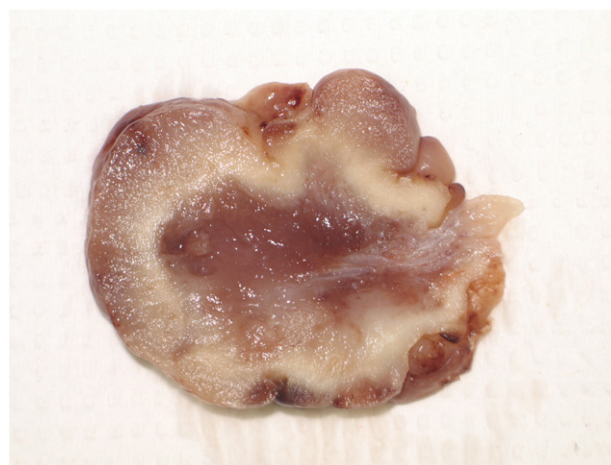


Fig. 1. Ovarian mass with edematous oozing cut surface.

* Corresponding author.

E-mail addresses: maan.alhalabi@lau.edu (M. Al Halabi), Janah.elhassan@gmail.com (J. El Hassan), selim.nasser@lau.edu.lb (S.M. Nasser).

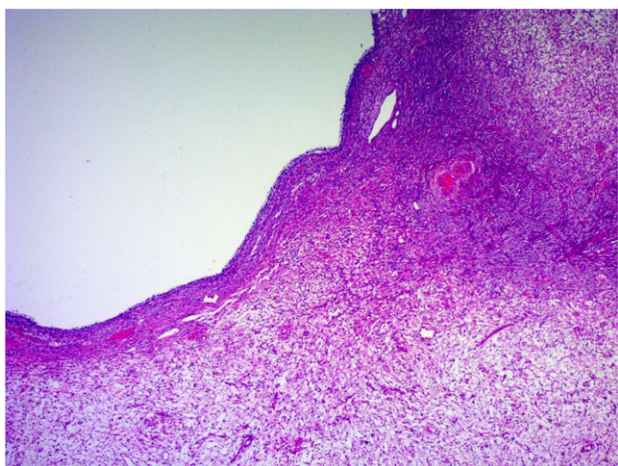


Fig. 2. Part of an entrapped cystic follicle (left upper corner) with cellular and hypocellular areas of the lesion (H&E \times 25).

2. Discussion

Ovarian thecoma is a rare ovarian sex cord stromal tumor. LTSP is a rare variant of ovarian thecoma first described in six patients in 1994 (Staats et al., 2008). Most thecomas are unilateral and range from 5 cm to 10 cm, while LTSP is usually bilateral and larger. Histologically, the ovarian cortex is expanded by a proliferation of bland mitotically active spindle cells with embedded clear to eosinophilic small luteinized cells arranged in cellular areas alternating with edematous areas including small capillaries with microscopic foci of hemorrhage. Typically, the lesion entraps preexisting ovarian follicles (Staats et al., 2008).

Sclerosing peritonitis is a rare form of peritoneal inflammation characterized by fibrous thickening of the peritoneum involving the visceral and parietal surfaces of the abdominal cavity. The most common causes are peritoneal dialysis, certain drugs such as anticonvulsants, and infectious peritonitis. Sclerosing peritonitis associated with luteinizing thecoma has been associated with more complications than the one secondary to other diseases with higher rates of re-laparotomies, intestinal resection and fistula formation (Bianco et al., 2005).

Staats et al. (2008) reported that, in 25 out of 27 patients with LTSP, sclerosing peritonitis was diagnosed either intra-operatively or, in the majority of patients, during follow-up. It has been hypothesized that the ovarian lesion secretes fibrogenic substances that cause sclerosis of the peritoneum such as fibrinogenic cytokines like TGF- β which is believed to induce myofibroblastic transformation of mesothelial cells in peritoneal fibrosis (Staats et al., 2008). However, the peritoneal fibrogenic process continues to progress after bilateral oophorectomy in many of the patients, which make the exact cause of sclerosing peritonitis unknown and not restricted to the factors secreted by the ovarian lesion.

Although this tumor is benign, its outcome may be stern. In the review of Staats et al., out of 27 cases, 3 patients died postoperatively, 10 suffered

postoperative morbidities while the remaining 14 had a favorable outcome. The prognosis of luteinized thecoma seems to be determined by the evolution of the associated sclerosing peritonitis, which in most patients is not resolved with surgical resection of the ovarian tumors and may induce additional surgical interventions that may cause significant complications and morbidities. Kim et al. suggested that the mortality rate of dialysis related sclerosing peritonitis increased from 24%, without treatment, to 60%, with surgical treatment due to surgery-associated complications (Kim et al., 2005).

Due to the low incidence of LTSP, there has been no consensus on the mainstay therapy. However, recent studies reported successful treatment with GnRH agonist, antiestrogen and high doses of corticosteroids. Bianco et al. reported dramatic resolution of sclerosing peritonitis in a 39-year-old patient with LTSP after treatment with a combination of GnRH agonist and antiestrogen (Kim et al., 2005). Mellembakken et al. and Schonman et al. have also reported successful treatment with GnRH agonist and high doses of corticosteroids in two young patients with sclerosing peritonitis associated with LTSP, who became completely asymptomatic with fertility preservation (Mellembakken et al., 2010; Schonman et al., 2008). Administering GnRH to a patient who has undergone oophorectomy is controversial. However, some authors think that luteinized thecoma is a nonneoplastic process induced by an external stimulus that also affects the peritoneum. GnRH agonist may inhibit such a stimulus, which may account for the reported successful treatment of the peritoneal lesions that continue to progress even after oophorectomy.

The clinical presentation of LTSP may be confusing and its diagnosis challenging. Our case emphasizes that the recognition of this rare entity and the awareness that LTSP may be successfully treated medically are essential for the appropriate management of these patients and for avoiding unnecessary and morbid surgeries.

Conflicts of interest and source of funding

None.

References

- Bianco, R., De Rosa, G., Staibano, S., Somma, P., Bianco, A.R., 2005. Ovarian luteinized thecoma with sclerosing peritonitis in an adult woman treated with leuprolide and toremifene in complete remission at 5 years. *Gynecol. Oncol.* 96 (3), 846–849 (March).
- Kim, B.S., Choi, H.Y., Ryu, D.R., Yoo, T.H., Park, H.C., Kang, S.W., et al., 2005. Clinical characteristics of dialysis related sclerosing encapsulating peritonitis: multi-center experience in Korea. *Yonsei Med. J.* 46 (1), 104–111.
- Mellembakken, J.R., Engh, V., Tanbo, T., Czernobilsky, B., Edelstein, E., Lunde, O., et al., 2010. Mitotically active cellular luteinized thecoma of the ovary and luteinized thecomatosis associated with sclerosing peritonitis: case studies, comparison, and review of the literature. *Pathol. Res. Pract.* 206 (11), 744–748.
- Schonman, R., Klein, Z., Edelstein, E., Czernobilsky, B., Fishman, A., 2008. Luteinized thecoma associated with sclerosing peritonitis—conservative surgical approach followed by corticosteroid and GnRH agonist treatment—a case report. *Gynecol. Oncol.* 111 (3), 540–543.
- Staats, P.N., McCluggage, W.G., Clement, P.B., Young, R.H., 2008. Luteinized thecomas (thecomatosis) of the type typically associated with sclerosing peritonitis: a clinical, histopathologic, and immunohistochemical analysis of 27 cases. *Am. J. Surg. Pathol.* 32 (9), 1273–1290.