



Contents lists available at ScienceDirect

International Journal of Surgery Case Reports

journal homepage: www.casereports.com

Microspheres embolization of juvenile nasopharyngeal angiofibroma in an adult



Vevek Parikh*, Charles Hennemeyer

University of Arizona, Department of Medical Imaging, 1501 North Campbell Avenue, Tucson, AZ 85724, United States

ARTICLE INFO

Article history:

Received 30 May 2014

Accepted 7 October 2014

Available online 18 November 2014

Keywords:

Juvenile nasopharyngeal angiofibroma
Embolization
Tumor
Interventional
Radiology
Microsphere

ABSTRACT

INTRODUCTION: Juvenile nasopharyngeal angiofibroma (JNA) is a benign though locally aggressive, highly vascular tumor primarily affecting adolescent males which has traditionally posed a significant intraoperative challenge during its resection due to the high risk of uncontrollable hemorrhage. Pre-operative angiographic embolization of the major feeding vessels to the tumor has become a valuable, even necessary, tool in the surgical treatment of these lesions.

PRESENTATION OF CASE: Our patient was a 32-year-old man with a chief complaint of recurrent left-sided epistaxis for one year, brisk and continuous for ten days prior to presentation, subsequently found to have a 4 cm vascular skull base tumor causing mild expansion of the pterygopalatine fossa. The patient underwent pre-operative embolization utilizing 300–500 micrometer microspheres injected into the ipsilateral maxillary artery. The following day, the patient underwent definite Stereotactical surgical resection of his JNA tumor. Estimated blood loss during the operation was 50 mL, and the patient was discharged the same day.

DISCUSSION: Juvenile nasopharyngeal angiofibromas pose a significant bleeding risk for the surgeon due to their highly vascular nature. Pre-operative embolization of juvenile nasopharyngeal angiofibromas can reduce intraoperative blood loss while lessening the risk of massive hemorrhage, shortening operation times, increasing intra-operative visibility, and allowing for easier resection of lesions.

CONCLUSION: Pre-operative embolization of JNA is a safe, effective method to prevent against the risk of massive, sometimes fatal, hemorrhage that occurs with these highly vascular tumors.

© 2014 The Authors. Published by Elsevier Ltd. on behalf of Surgical Associates Ltd. This is an open access article under the CC BY-NC-ND license (<http://creativecommons.org/licenses/by-nc-nd/3.0/>).

1. Introduction

Juvenile nasopharyngeal angiofibroma is a relatively uncommon, benign tumor of children which accounts for approximately 0.05% of all head and neck tumors.¹ The lesion almost exclusively affects males, usually around the age of adolescence with a range involving boys from ages 7 to 29.¹ Initial symptoms upon presentation include recurrent unilateral epistaxis, nasal obstruction, nasal drainage and a nasopharyngeal mass. Although a benign tumor, lesions may be locally aggressive and erode into the surrounding osseous and soft tissue structures, arising from their usual location in the lateral nasopharynx near the superior border of the sphenopalatine foramen. Histopathologically, the tumor is comprised of haphazardly arranged vascular channels surrounded by dense paucicellular fibroblastic stroma, with the myofibroblast being the principal cell.^{2,3} The bleeding propensity of these tumors is due to the findings that the smaller vessels in the center of the lesion tend to lack muscular elastic lamina, predisposing these

vessels without a muscular surrounding layer that may otherwise assist in vasoconstriction to uncontrolled bleeding.² The blood supply to these lesions is derived from the internal maxillary artery,^{8,9} a branch off the external carotid artery.

Diagnosis of JNA may originally be made on computed tomography (CT) examination or even suspected on the basis of plain radiographs. CT has the benefit of better detailing osseous involvement of tumor. Definitive diagnosis, however, is made on magnetic resonance imaging (MRI) examination. The optimal sequence to identify the anatomy and extent of intracranial extension of JNA involves T1 weighted imaging (T1WI) with gadolinium contrast, utilizing fat-suppression. An MR-angiogram can additionally be valuable in defining the arterial supply to the tumor, of primary importance for pre-embolization planning. Due to the highly vascular nature of JNA, biopsy is contraindicated.¹⁰ Furthermore, careful attention must be paid to the surrounding vascular structures during time of resection accounting for the high risk of potentially fatal bleeding. Specifically, feeding vessels from the internal carotid artery, as well as any arterial supply from the contralateral external carotid artery must be identified prior to attempted resection. Although surgical resection remains definite treatment for these lesions, pre-operative angioembolization is increasingly recommended to minimize the risk of uncontrolled intraoperative

* Corresponding author. Tel.: +1 9045048415.

E-mail addresses: VevekParikh@gmail.com (V. Parikh), Cth@radiology.arizona.edu (C. Hennemeyer).

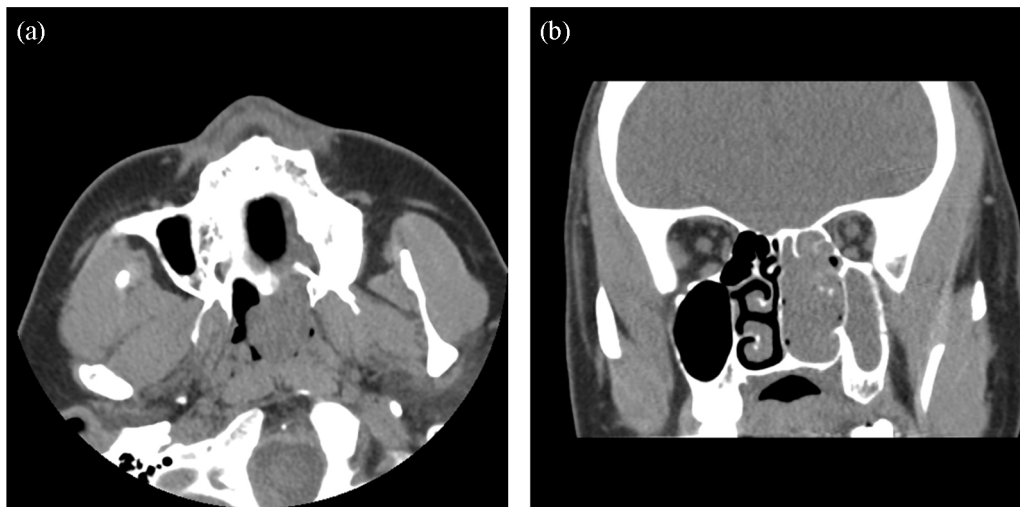


Fig. 1. (a) Axial unenhanced CT image of the face demonstrates a soft tissue mass in the left sphenoid sinus. (b) Coronal CT image of the face demonstrates opacification with a soft tissue mass within the left maxillary sinus and osteomeatal units.

hemorrhage. Previously described treatments including radiation, cryotherapy, electrocoagulation, or hormonal therapy have proven less effective with increased recurrence rate and a greater incidence of side effects.^{3,4}

2. Case report

Our patient was a 32-year-old man with a chief complaint of recurrent left-sided epistaxis for one year, brisk and continuous for ten days prior to presentation. The Otolaryngology (ENT) service was consulted due to uncontrollable epistaxis, and imaging work-up with computed tomography (Fig. 1) followed by contrast enhanced MRI (Fig. 2) revealed a 3–4 cm vascular skull base tumor with mild proximal expansion of the pterygopalatine fossa and extension into the nasopharynx and left pterygoid plate, most consistent with a Radkowski IIA lesion.¹¹ Plans were made for

surgical resection, and the Interventional Radiology service was subsequently consulted by ENT for pre-operative embolization to take place on the day prior to surgical resection.

In the Interventional Suite, the right femoral artery was accessed, and a 5-French Berenstein (Cordis Endovascular, Johnson and Johnson Corp., Miami, FL) was eventually placed to access the common carotid artery. An angiogram of the right common carotid and selective angiogram of the right external carotid artery revealed normal arterial anatomy with no significant tumor blush. Subsequently, an angiogram of the left common carotid artery was performed revealing normal branching of the internal and external carotid arteries with significant tumor blush in the skull base (Fig. 3). A normal left sphenopalatine artery could not be identified, as numerous abnormal vessels had replaced the sphenopalatine artery due to neovascularization (Fig. 4). Selective injections evaluating the occipital and facial

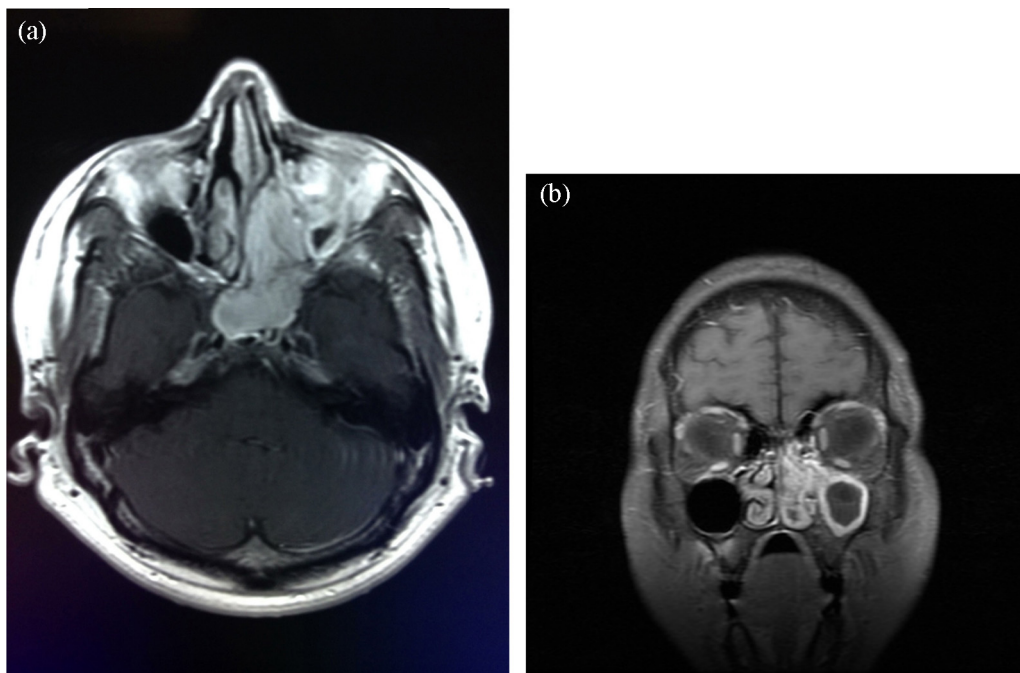


Fig. 2. (a) Axial contrast enhanced MR T1 weighted image demonstrates an enhancing soft tissue mass arising from the skull base and left nasopharynx into the sphenoid sinus, crossing midline. (b) Coronal contrast enhanced MR T1 weighted image demonstrates an enhancing soft tissue mass within the maxillary sinus and osteomeatal units.

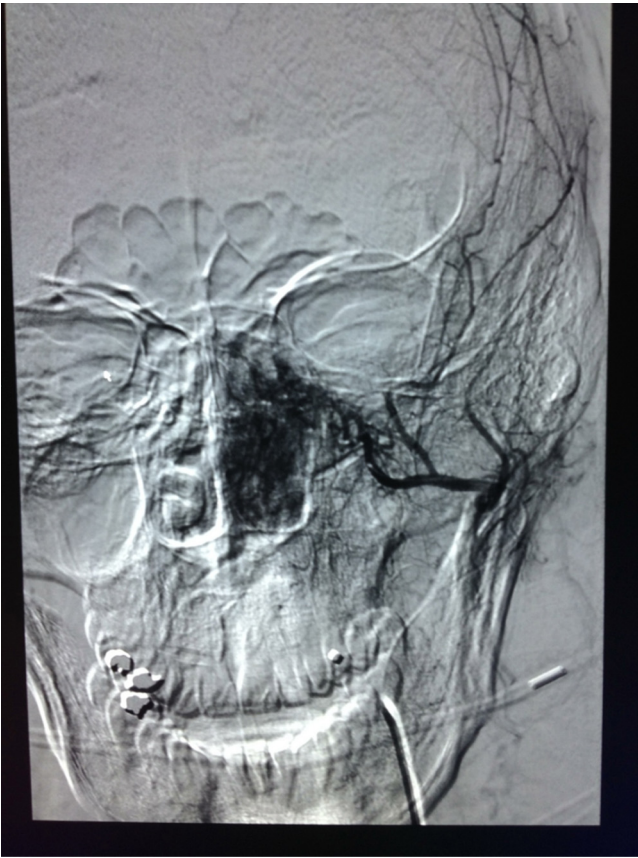

Fig. 3. Angiogram demonstrating neovascularization and characteristic tumor blush in the left nasopharynx. No contribution from the right-sided arterial supply.

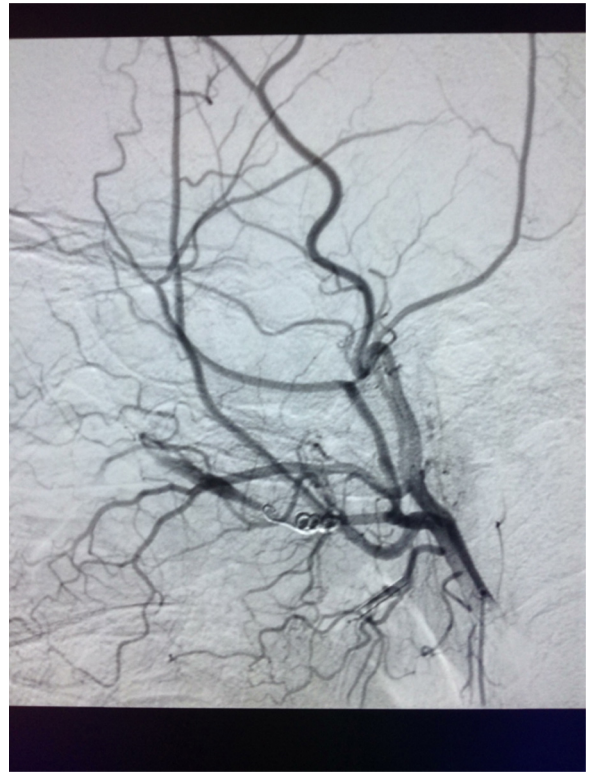


Fig. 5. Post-embolization angiogram demonstrating cessation of flow within the tumor blush following Embosphere administration and embolization of the proximal sphenopalatine artery with a microcoil.

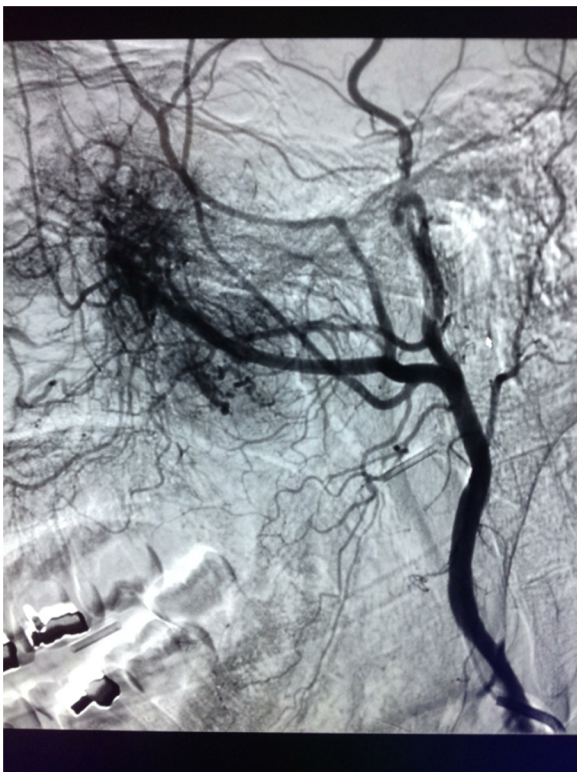


Fig. 4. Replacement of the normal left sphenopalatine artery with tumor neovascularization. No vessels are seen supplying the tumor at the base of the skull.

arteries demonstrated no vessels supplying the tumor at the base of the skull.

The Berenstein catheter was subsequently advanced into the internal maxillary artery, and after diagnostic angiogram revealed no intracranial branches nor branches to the globe, it was deemed safe to proceed with embolization. 300–500 micrometer Embosphere (Merit Medical Systems, South Jordan, UT) microspheres were dispensed in small aliquots until there was stasis within the tumor bed, and a follow-up arteriogram demonstrated cessation of flow with no further tumor blush visualized. Finally, the microcatheter was retracted into the proximal left sphenopalatine artery and a single 3 mm × 6 cm microcoil was placed. A follow-up angiogram demonstrated cessation of flow within the vessel (Fig. 5). Additionally, no new vessels were identified supplying the tumor at the base of the skull. After removal of the catheters and closure of the arteriotomy, the patient was returned to the holding area; no immediate complications were identified.

The following day the patient returned to the operating room with Otolaryngology for definitive resection. Stereotactical surgical navigation and resection was performed, and estimated blood loss during the operation was 50 mL. The patient's operation and post-operative course were uncomplicated, and the patient was discharged home in stable condition the same day following his operation.

3. Discussion

In the past several years, the value of pre-operative embolization prior to surgery has become increasingly known. The risk for intra-operative bleeding is significant, and furthermore as diagnosis is often delayed, these tumors may lie adjacent to several critical neurovascular structures.^{5,6} Pre-operative embolization of juvenile nasopharyngeal angiofibromas can reduce intraoperative

blood loss while lessening the risk of massive hemorrhage, shortening operation times, increasing intra-operative visibility, and allowing for easier resection of lesions. Furthermore, the diagnostic angiogram itself may be a valuable predictor of expected intraoperative blood loss.⁷ Although serious complications are sometimes possible, including stroke or blindness from migration of particles into the middle cerebral artery or ophthalmic artery, these complications are rare and do not outweigh the substantial benefits that embolization confers.⁹ In a study of eight patients that underwent pre-operative embolization of the ipsilateral maxillary artery utilizing absorbable gelfoam, six experienced considerably less bleeding during surgical resection.² A recent systematic analysis of 131 cases within 57 studies over 21 years showed that the average blood loss in patients that underwent pre-operative embolization during purely endoscopic surgical resection averaged 406.7 mL compared to 828.3 mL in non-embolized patient undergoing purely endoscopic resection.¹ Furthermore, in open surgical cases there was less blood loss after preoperative embolization with an average of 685.0 mL compared to an average of 1912.1 mL lost in patients that did not undergo embolization. In light of these findings, it appears that pre-operative embolization is a safe, effective method to prevent against the risk of massive, sometimes fatal, hemorrhage that occurs with these highly vascular tumors. Our case is unique as our

patient presented at the age of 32, while most patients requiring embolization present in late adolescence with a mean age of 17.¹

Conflict of interests

The authors declare that they have no conflict of interest.

Funding

None.

Ethical approval

Written informed consent was obtained from the patient for publication of this case report and accompanying images. A copy of the written consent is available for review by the Editor-in-Chief of this journal on request.

Author contributions

Vevek Parikh – wrote the paper, data collection; Charles Hennemeyer – operating Interventional Radiologist, study design, oversaw writing of the paper.

Key learning points

- Juvenile nasopharyngeal angiofibromas (JNA) are a benign tumor that pose significant challenges upon surgical resection due to risk of excessive bleeding.
- Pre-operative embolization of JNA utilizing microspheres is a valuable pre-operative technique performed by the Interventional Radiologist to diminish risk of intraoperative bleeding.
- Although uncommon, delayed presentation of JNA may occur in an adult and account for lateonset recurrent unilateral epistaxis.
- The ipsilateral internal maxillary artery in the majority of cases comprises the primary vascular supply to JNA.

References

1. Boghani Z, Husain Q, Kanumuri V, Khan MN, Sangvhi S, Liu JK, et al. Juvenile nasopharyngeal angiofibroma: a systematic review and comparison of endoscopic, endoscopic-assisted, and open resection in 1047 cases. *Laryngoscope* 2013;**123**(April).
2. Moorthy PNS, Reddy R, Abdul HQ, Madhira S, Kolloju S. Management of juvenile nasopharyngeal angiofibroma: a five year retrospective study. *Indian J Otolaryngol Head Neck Surg* 2010;**62**(October (4)):390–4.
3. Davis KR. Embolization of epistaxis and juvenile nasopharyngeal angiofibromas. *AJR* 1987;**January (148)**:209–18.
4. Hira A, Chao K. Direct endoscopic intratumoral injection of onyx for the preoperative embolization of a recurrent juvenile nasal angiofibroma. *Interv Neuroradiol* 2011;**17**(December (4)):477–81.
5. Roche PH, Paris J, Régis J, Moulin G, Zanaret M, Thomassin JM, et al. Management of invasive juvenile nasopharyngeal angiofibromas: the role of a multimodality approach. *Neurosurgery* 2007;**61**(October (4)):768–77, discussion 777.
6. Iovanescu G, Ruja S, Cotulbea S. Juvenile nasopharyngeal angiofibroma: Timisoara ENT department's experience. *Int J Pediatr Otorhinolaryngol* 2013;**77**(July (7)):1186–9.
7. Ballah D, Rabinowitz D, Vossough A, Rickert S, Dunham B, Kazahaya K, et al. Preoperative angiography and external carotid artery embolization of juvenile nasopharyngeal angiofibromas in a tertiary referral paediatric centre. *Clin Radiol* 2013;**68**(November (11)):106–97.
8. Panda NK, Gupta G, Sharma S, Gupta A. Nasopharyngeal angiofibroma-changing trends in the management. *Indian J Otolaryngol Head Neck Surg* 2012;**64**(September (3)):233–9.
9. Lv MM, Fan XD, Su LX, Chen D. Preoperative direct puncture embolization of advanced juvenile nasopharyngeal angiofibroma in combination with transarterial embolization: an analysis of 22 consecutive patients. *Cardiovasc Interv Radiol* 2013;**36**(February (1)):111–7.
10. Mishra S, Praveena NM, Panigrahi RG, Gupta YM. Imaging in the diagnosis of juvenile nasopharyngeal angiofibroma. *J Clin Imaging Sci* 2013;**3**(March (Suppl. 1)):1.
11. Radkowski D, McGill T, Healy GB, Ohlms L, Jones DT. Angiofibroma. Changes in staging and treatment. *Arch Otolaryngol Head Neck Surg* 1996;**122**(February (2)):122–9.

Open Access

This article is published Open Access at scimedirect.com. It is distributed under the [IJSCR Supplemental terms and conditions](#), which permits unrestricted non commercial use, distribution, and reproduction in any medium, provided the original authors and source are credited.