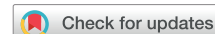

# Esophageal Perforation with Transesophageal Echocardiography in an Elderly Patient with Prominent Vertebral Osteophytes: A Case Report and a Review of the Literature



Olivier Royer, MD, Étienne J. Couture, MD, FRCPC, Frédéric Nicodème, MD, FRCPC, Dimitri Kalavrousiotis, MD, FRCPC, Takumi Codere Maruyama, MD, FRCPC, André Denault, MD, PhD, FRCPC, and Stephan Langevin, MD, FRCPC, *Québec and Montréal, Québec, Canada*

## INTRODUCTION

Iatrogenic esophageal perforation caused by transesophageal echocardiography (TEE) is a rare event with an associated high mortality rate.<sup>1</sup> Compression of the esophagus by vertebral osteophytes is currently not a contraindication to TEE according to practice guidelines.<sup>2</sup> We present the case of an elderly patient who developed an esophageal perforation after TEE secondary to prominent thoracic vertebral osteophytes compressing the esophagus during a transcatheter aortic valve replacement (TAVR) procedure. We suggest that significant anterior vertebral osteophytes that compress the esophagus, particularly in elderly patients under general anesthesia, should be considered a relative contraindication to TEE. Informed consent was obtained from a family member before the publication of this case report.

## CASE PRESENTATION

A 79-year-old man with hypertension and ischemic heart disease was scheduled for elective TAVR for a severe symptomatic aortic stenosis. He had undergone coronary artery bypass graft surgery with mitral valve repair 11 years earlier without any complication. Preprocedural transthoracic echocardiography revealed a severe aortic stenosis (aortic valve area 0.6 cm<sup>2</sup>, transvalvular maximal and mean gradients 61 and 33 mm Hg, respectively) with a left ventricular ejection fraction of 45%. After usual pre-TAVR investigations, a right transcarotid approach using fluoroscopic and transesophageal echocardiographic guidance was planned because of an unfavorable femoral vascular anatomy. After the induction of general anesthesia, a TEE probe (Vivid E95, probe model 6VT-D; GE Healthcare, Little

Chalfont, United Kingdom) using a sterile cover was easily placed. A SAPIEN 3 valve (Edwards Lifesciences, Irvine, California) was deployed without any incident during the 1-hour procedure. Postprocedural TEE showed a prosthesis in good position with no visible paravalvular leak. No trauma or blood was noticed during transesophageal probe insertion or removal, but gastric aspiration with an orogastric tube revealed blood-tinged secretions. The patient was extubated in the operating room by the attending anesthesiologist and transferred to the intensive care unit.

Two hours after surgery, the patient developed progressive chest pain and important shivering. Computed tomography (CT) with intravenous contrast of the neck, thorax, and abdomen was performed. CT revealed a pneumomediastinum and a right hydropneumothorax (Figure 1). An esophageal perforation was strongly suspected, and a right thoracic drain was inserted. Three hundred milliliters of a seroanguinous liquid was drained from the pleural space. Esophagogastroscopy showed a 4-cm vertical perforation of the middle third of the esophagus.

The patient returned to the operating room 7 hours after his initial procedure to undergo a right thoracotomy and repair of an esophageal perforation. After lysis of extensive pleural adhesions, the esophageal laceration site was found approximately 1.5 cm below the arch of the azygous vein. A large vertebral osteophyte was visualized and palpated by the thoracic surgeon at the site of the perforation. The thoracic surgeon performed a primary closure of the esophageal wall in two layers, and an intercostal muscular flap was mobilized to complete the closure. Three thoracic drains were left in place, and the patient was transferred to the intensive care unit. Unfortunately, the postoperative period was complicated by pneumonia, severe delirium, and congestive heart failure with pulmonary edema. Despite 1 month of optimal treatment, the patient died after withdrawal of care.

From the Department of Anesthesiology and Critical Care, Université Laval, Québec, Québec, Canada (O.R.); Department of Anesthesiology and Critical Care (E.J.C., S.L.), Department of Thoracic Surgery (F.N.), Department of Cardiac Surgery (D.K.), and Department of Anesthesiology (T.C.M.), Université Laval, Québec Heart and Lung Institute, Québec, Québec, Canada; and Department of Anesthesiology and Critical Care, Université de Montréal, Montreal Heart Institute, Montréal, Québec, Canada (A.D.).

Keywords: Transesophageal echocardiography, Complication, Perforation, Esophagus, Osteophytes

Conflicts of interest: The authors reported no actual or potential conflicts of interest relative to this document.

Copyright 2020 by the American Society of Echocardiography. Published by Elsevier Inc. This is an open access article under the CC BY-NC-ND license (<http://creativecommons.org/licenses/by-nc-nd/4.0/>).

2468-6441

<https://doi.org/10.1016/j.case.2020.06.006>

## DISCUSSION

Iatrogenic esophageal perforation caused by TEE is a rare event, with an incidence estimated between 0.03% and 0.09% in cardiac surgery.<sup>1-4</sup> Although it is an uncommon complication, esophageal perforation is associated with prolonged hospitalization and a mortality rate of 40%.<sup>1</sup>

Risk factors associated with esophageal perforation include, but are not limited to, preexisting esophageal pathologies such as esophageal stricture, Zenker's diverticulum, fibrosis from prior chest radiation, and ulceration caused by medication. Severe cardiomegaly<sup>5</sup> and large calcified lymph nodes<sup>6</sup> have been reported as rare causes of esophageal perforation. Both conditions increase the mechanical

## VIDEO HIGHLIGHTS

**Video 1:** Preoperative sagittal view of chest CT showing a prominent anterior thoracic osteophyte at T7-T8 (yellow) in close proximity to the esophagus.

**Video 2:** Preoperative axial view of chest CT showing the same thoracic osteophyte in close proximity (5 mm) to the esophagus.

View the video content online at [www.cvcasejournal.com](http://www.cvcasejournal.com).

compression exerted by the probe against the mucosal and muscular fibers of the esophagus.<sup>7</sup> Vertebral osteophytes are common radiologic findings, present in 20% to 30% of the elderly population, and can be generalized in individuals with diffuse idiopathic skeletal hyperostosis.<sup>8</sup> Numerous reports of dysphagia and aspiration related to anterior cervical osteophytes have been described in the literature, particularly in patients with diffuse idiopathic skeletal hyperostosis.<sup>9,10</sup> In the thoracic region, the esophagus is vulnerable to extrinsic compression by anterior osteophytes, particularly at the tracheal bifurcation (T4-T5) and at the diaphragmatic hiatus (T9-T10) because the anatomic space between these structures and the vertebral column is particularly reduced.<sup>8</sup>

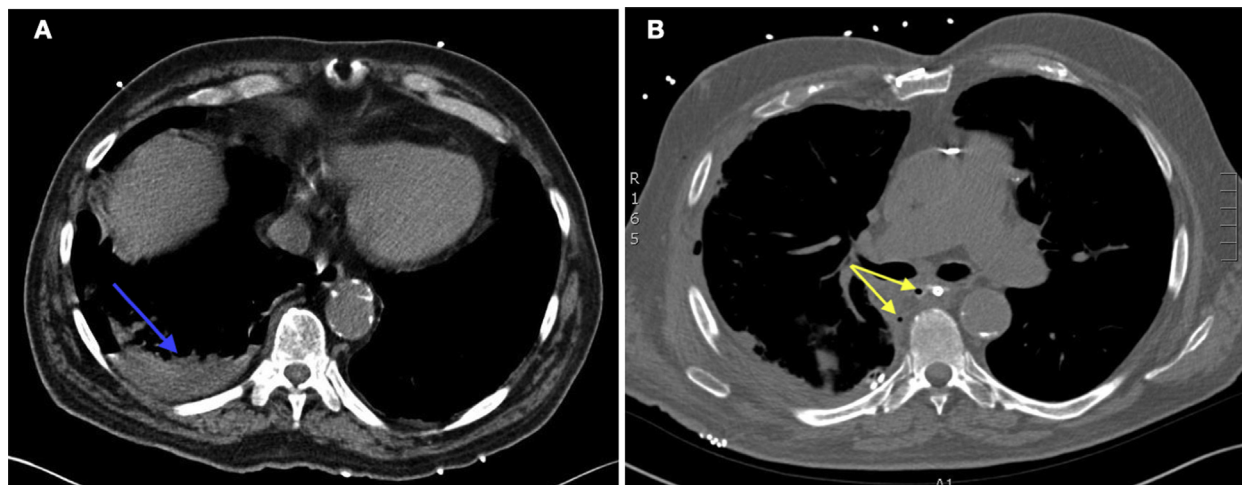
Symptoms of extrinsic esophageal compression at the lower thoracic region can be absent or minimal in the sitting position, as the weight of thoracic organs exerts pressure on the esophagus standing next to the osteophytes predominantly in the supine position.

Before TEE, our patient had no previously mentioned risk factors for esophageal perforation, and no symptoms of dysphagia or odynophagia were reported. However, preoperative pulmonary radiography and CT revealed prominent anterior thoracic osteophytes. CT also clearly demonstrated the anatomic proximity of thoracic osteophytes to the esophagus (Figures 2A and 2B, Videos 1 and 2). Although the procedure was relatively short (1 hour), we think that

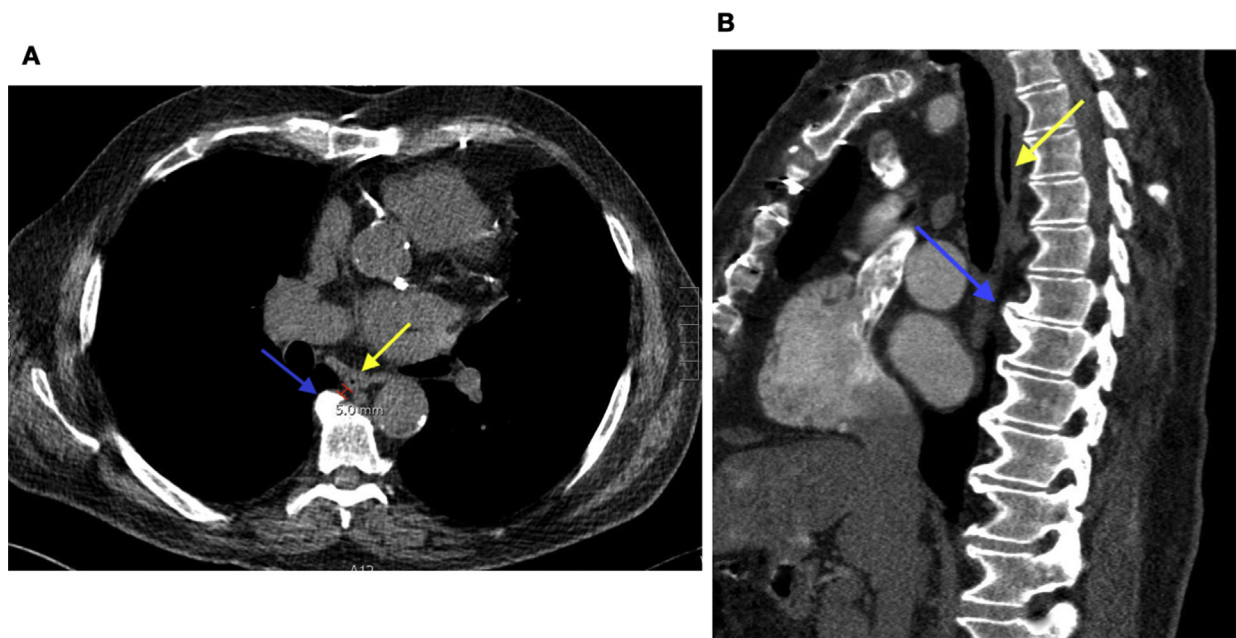
direct pressure applied by the transesophageal probe against the sharp vertebral osteophytes led to esophageal laceration. This mechanism of esophageal perforation induced with a transesophageal probe seems to be underreported in the literature. In fact, in our review of the literature using specific search strategies in three databases (MEDLINE, Embase, and Web of Science), we located only one case of esophageal perforation due to thoracic osteophytes during TEE<sup>11</sup> (Appendix A). Two cases of upper esophageal laceration possibly linked to cervical osteophytes have also been reported in the literature<sup>12,13</sup> (Appendices B and C<sup>11,15,12-14</sup>).

The GE 6VT-D probe for adults that we used has a maximal transverse diameter of 12 to 14 mm and a maximal anteroposterior diameter of 10 to 12 mm (Figures 3A and 3B). The thoracic osteophyte (T7-T8) was at 5 mm of the esophagus, which has a virtual lumen at that site (Figure 2A). With the manipulation of the transesophageal probe into the esophagus and the possibility to move in anteflexion (90°) and retroflexion (30°–45°), as well as laterally (4 cm to each side), we can certainly understand the mechanism of the laceration (Figures 3A and 3B). At T7-T8, for a midesophageal four-chambers view, the desired movement of the probe is retroflexion. It is easily a 3- to 4-cm backward movement of the probe.

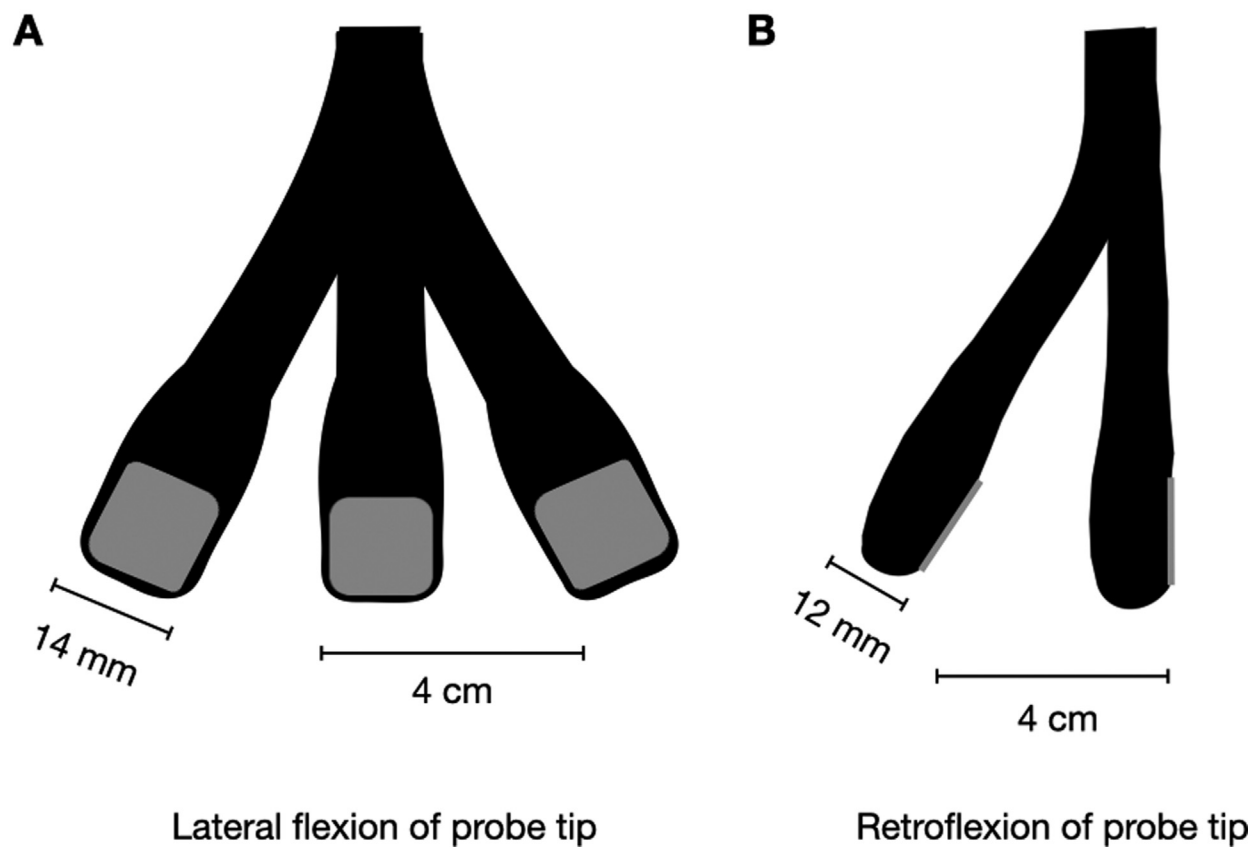
As previously suggested by Chang *et al.*,<sup>15</sup> we recommend that cervical and thoracic vertebral osteophytes noticed on thoracic CT before procedures should be considered a relative contraindication to TEE, particularly in elderly patients who undergo interventional cardiologic procedures under general anesthesia (e.g., MitraClip implantation, left atrial appendage occlusion). In fact, these guide catheter-based procedures entail further probe manipulations, as the probe must be withdrawn during fluoroscopy to produce an unimpeded view. Repeated insertion and withdrawal of the probe usually does not occur during standard cardiac surgery. This repeated motion may well have played a central role in our patient's esophageal injury. Longer procedural duration can also be associated with more extensive transesophageal probe manipulation.<sup>16</sup> However, we do not think that the 1-hour duration of the procedure was a contributing factor in our case.



**Figure 1** (A) Postoperative chest CT showing a new right pleural effusion (blue arrow). (B) Postoperative chest CT showing air bubbles in the mediastinum (yellow arrows).



**Figure 2** (A) Preoperative axial view of chest CT showing a prominent anterior thoracic osteophyte at T7-T8 (blue arrow) in close proximity (5 mm) to the esophagus (yellow arrow). (B) Preoperative sagittal view of chest CT.



**Figure 3** (A) Lateral flexion of the GE 6VT-D probe. The probe can move 4 cm laterally to each side. (B) Retroflexion movement of the GE 6VT-D probe that can reach 4 cm.

## CONCLUSION

---

We suggest that preoperative imaging performed as a routine investigation (chest CT) before TAVR or other cardiac procedures should be carefully reviewed before TEE to determine the presence and severity of vertebral osteophytes. It is important to determine their anatomic relation to the esophagus to safely perform TEE.

## SUPPLEMENTARY DATA

---

Supplementary data related to this article can be found at <https://doi.org/10.1016/j.case.2020.06.006>.

## REFERENCES

---

- Ramalingam G, Choi SW, Agarwal S, Kunst G, Gill R, Fletcher SN, et al. Complications related to peri-operative transoesophageal echocardiography—a one-year prospective national audit by the Association of Cardiothoracic Anaesthesia and Critical Care. *Anaesthesia* 2020;75:21-6.
- Purza R, Ghosh S, Walker C, Hiebert B, Koley L, Mackenzie GS, et al. Transesophageal echocardiography complications in adult cardiac surgery: a retrospective cohort study. *Ann Thorac Surg* 2017;103:795-802.
- Piercy M, McNicol L, Dinh DT, Story DA, Smith JA. Major complications related to the use of transesophageal echocardiography in cardiac surgery. *J Cardiothorac Vasc Anesth* 2009;23:62-5.
- Kallmeyer IJ, Collard CD, Fox JA, Body SC, Sherman SK. The safety of intraoperative transesophageal echocardiography: a case series of 7200 cardiac surgical patients. *Anesth Analg* 2001;92:1126-30.
- Kimura A, Mori T, Kihara Y, Watanabe C, Tanaka K, Yamada T, et al. A case of esophageal perforation after intraoperative transesophageal echocardiography in a patient with a giant left atrium: unexpectedly large distortion of the esophagus revealed on retrospectively constructed three-dimensional imaging. *JA Clin Reports* 2019;5:21.
- Pong M-W, Lin S-M, Kao S-C, Chu C-C, Ting C-K, Tsai S-K. Unusual cause of esophageal perforation during intraoperative transesophageal echocardiography monitoring for cardiac surgery—a case report. *Acta Anaesthesiol Sin* 2003;41:155-8.
- Côté G, Denault A. Transesophageal echocardiography-related complications. *Can J Anesth* 2008;55:622-47.
- Klaassen Z, Tubbs RS, Apaydin N, Hage R, Jordan R, Loukas M. Vertebral spinal osteophytes. *Anat Sci Int* 2011;86:1-9.
- Strasser G, Schima W, Schober E, Pokieser P, Kaider A, Denk DM. Cervical osteophytes impinging on the pharynx: importance of size and concurrent disorders for development of aspiration. *AJR Am J Roentgenol* 2000;174:449-53.
- Kos MP, Van Royen BJ, David EF, Mahieu HF. Anterior cervical osteophytes resulting in severe dysphagia and aspiration: two case reports and literature review. *J Laryngol Otol* 2009;123:1169-73.
- Elsayed H, Shackcloth M. Should cervical and thoracic osteophytes be a contraindication for transesophageal echocardiography in cardiac surgery? *J Cardiothorac Vasc Anesth* 2013;27:319-20.
- Popescu B, Berteşteanu ŞVG, Păun AO, Popescu CR, Băilăău C, Motofei I, et al. Conservative management of pharynx trauma. *Arch Balk Med Union* 2016;51:529-31.
- Bavalia N, Anis A, Benz M, Maldjian P, Bolanowski PJ, Saric M. Esophageal perforation, the most feared complication of TEE: early recognition by multimodality imaging. *Echocardiography* 2011;28:56-60.
- Ferraris VA, Ferraris SP, Moritz DM, Welch S. Oropharyngeal dysphagia after cardiac operations. *Ann Thorac Surg* 2001;71:1792-6.
- Chang K, Barghash M, Donnino R, Freedberg RS, Hagiwara M, Bennett G, et al. Extrinsic esophageal compression by cervical osteophytes in diffuse idiopathic skeletal hyperostosis: a contraindication to transesophageal echocardiography? *Echocardiography* 2016;33:314-6.
- Thys DM, Abel MD, Brooker RF, Cahalan MK, Connis RT, Duke PG, et al. Practice guidelines for perioperative transesophageal echocardiography. *Anesthesiology* 2010;112:1084-96.

## APPENDIX A

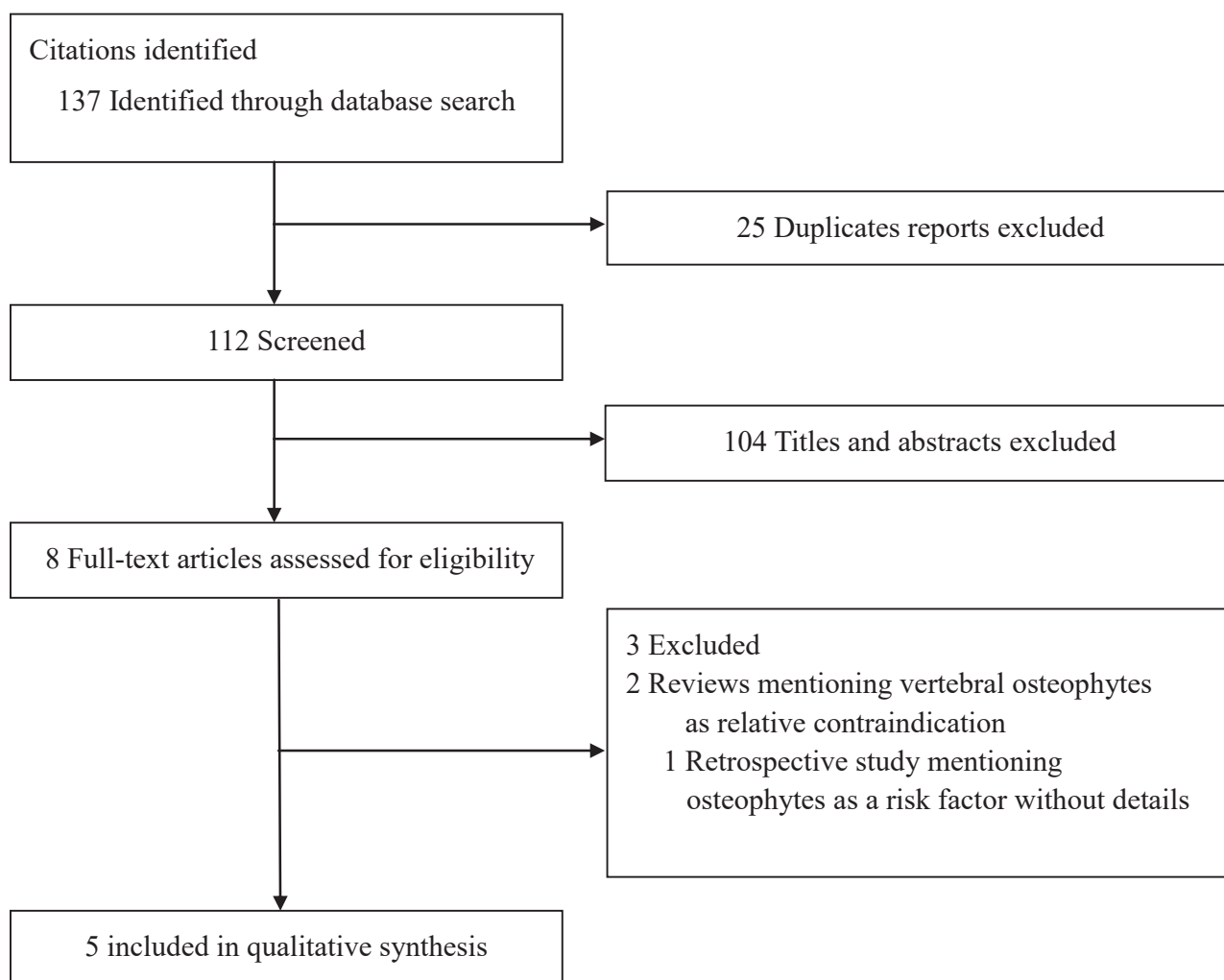
### MEDLINE Search Strategy

#1 "Echocardiography, Transesophageal" [MeSH]  
#2 Transesophageal echocardiogra\*  
#3 #1 OR #2  
#4 Complication\*  
#5 Adverse effect\*  
#6 Adverse event\*  
#7 Laceration\*  
#8 Rupture\*  
#9 Tear  
#10 Injur\*

#11 Perforation\*  
#12 #4 OR #5 OR #6 OR #7 OR #8 OR #9 OR #10  
OR #11  
#13 "Osteophyte" [MeSH]  
#14 Osteophyt\*  
#15 Hyperostosis  
#16 Exostoses  
#17 "Hyperostosis, Diffuse Idiopathic Skeletal" [MeSH]  
#18 Diffuse Idiopathic Skeletal Hyperostosis  
#19 "Spine" [MeSH]  
#20 Vertebral Column  
#21 #13 OR #14 OR #15 OR #16 OR #17 OR #18 OR #19 OR  
#20  
#22 #3 AND #12 AND #21

## APPENDIX B

### Flow Diagram



## APPENDIX C

**Supplemental Table 1** Reported cases of esophageal lesions after TEE in patients with vertebral osteophytes

Author	Year	Age	Sex	TEE indication	Pre-TEE GI symptoms	Comorbidities	Type of lesion	Lesion localization	Diagnosis delay (days)	Presentation	Treatment	Results
Elsayed <i>et al.</i> <sup>11</sup>	2013	81	F	Preoperative	None	NR	Laceration of 1 cm	T9 (site of the thoracic osteophyte)	13	Septic shock	Primary repair of esophagus, intercostal muscular flap, and resection of the osteophyte	Died POD 14 of sepsis and MOF
Chang <i>et al.</i> <sup>15</sup>	2016	81	M	Endocarditis diagnosis	Chocking sensation while eating in the supine position GERD	Candidal esophagitis "Tortuous esophagus" noted on EGD	None, TEE canceled DISH on CT	Cervical osteophytes prominent at C4-C5	—	—	—	—
Popescu <i>et al.</i> <sup>12</sup>	2016	78	M	Routine TEE	NR	NR	Tear on the posterior wall of the hypopharynx	Cervical osteophyte adjacent to the pharynx fistula	1	Pain in the neck, dysphagia, and odynophagia Upper airway edema (day 3)	Conservative	Alive, airway edema resolved at day 8
Bavalia <i>et al.</i> <sup>13</sup>	2011	77	F	Cardiac myxoma diagnosis	NR	Chronic corticotherapy Cervical and thoracic osteophytes	Perforation of 2.5 cm	At the level of the cricopharyngeus muscle	0	Right-sided pleuritic chest pain	Single-layer closure repair	Alive at 6 wk
Ferraris <i>et al.</i> <sup>14</sup>	2001	NR	NR	Preoperative	NR	NR	NR	Cervical osteophyte	NR	Postoperative dysphagia	NR	Alive

*DISH*, Diffuse idiopathic skeletal hyperostosis; *GERD*, gastroesophageal reflux disease; *GI*, gastrointestinal; *MOF*, multiple organ failure; *NR*, not reported; *POD*, postoperative day.