

Available online at www.sciencedirect.com

ScienceDirect

journal homepage: www.elsevier.com/locate/radcr

Case Report

Epiploic appendagitis of the vermiform appendix—An unusual mimic of acute appendicitis[☆]

Salah Aljilly, MD*, Zahoor Ahmed, MD

Department of Clinical Imaging, Hamad General Hospital, Apt 12, Building 15, Haya complex, street 889, zone 37, Doha, Qatar

ARTICLE INFO

Article history:

Received 28 October 2020

Revised 1 December 2020

Accepted 3 December 2020

Keywords:

Epiploic appendagitis of appendix

Epiploic appendage

Vermiform appendix

Right iliac fossa pain

ABSTRACT

Epiploic appendagitis is a condition resulting from ischemia or necrosis involving the appendage epiploica either due to torsion or spontaneous thrombosis of the venous outflow. It is one of the myriad causes of acute abdominal pain and can masquerade clinically as appendicitis, omental infarction, sclerosing mesenteritis and even diverticulitis. Epiploic appendagitis of the vermiform appendix is a rare entity, clinically indistinguishable from appendicitis. We present a 45-year-old male patient with 4-day duration of right iliac fossa pain and tenderness, with strong clinical suspicion of acute appendicitis. CT scan of the abdomen and pelvis demonstrated Epiploic appendagitis of the vermiform appendix, whilst the appendix remained uninflamed. The patient was thus discharged with conservative management without having to go undergo needless surgery, thereby avoiding the potential complications thereof.

© 2020 Published by Elsevier Inc. on behalf of University of Washington.

This is an open access article under the CC BY-NC-ND license

(<http://creativecommons.org/licenses/by-nc-nd/4.0/>)

Case Report

A 45-year-old gentleman with a 4-day duration of right iliac fossa pain and tenderness, not known to have any chronic illness, presented to the Emergency department of the Hospital. There was no history of nausea, vomiting, fever, or change in bowel habit. There was also no history of dysuria or hematuria. His vital signs were as following - temperature

36.8 c, blood pressure 134/87 mm Hg, respiratory rate 18 per minute. Clinical examination revealed rebound tenderness in the right iliac fossa. Based on the history and clinical findings, a provisional diagnosis of acute appendicitis was made and the patient referred to the Clinical Imaging Department for confirmation prior to surgery. Meanwhile, the blood sample was collected for routine analysis, which later revealed normal WBC count (3.7), normal liver enzymes (AST – 23; ALT 36). The CRP was within normal limits (7.7).

[☆] Disclosures: We have no competing interest or financial disclosures to make.

* Corresponding author.

E-mail address: saljilly@hamad.qa (S. Aljilly).

<https://doi.org/10.1016/j.radcr.2020.12.005>

1930-0433/© 2020 Published by Elsevier Inc. on behalf of University of Washington. This is an open access article under the CC BY-NC-ND license (<http://creativecommons.org/licenses/by-nc-nd/4.0/>)

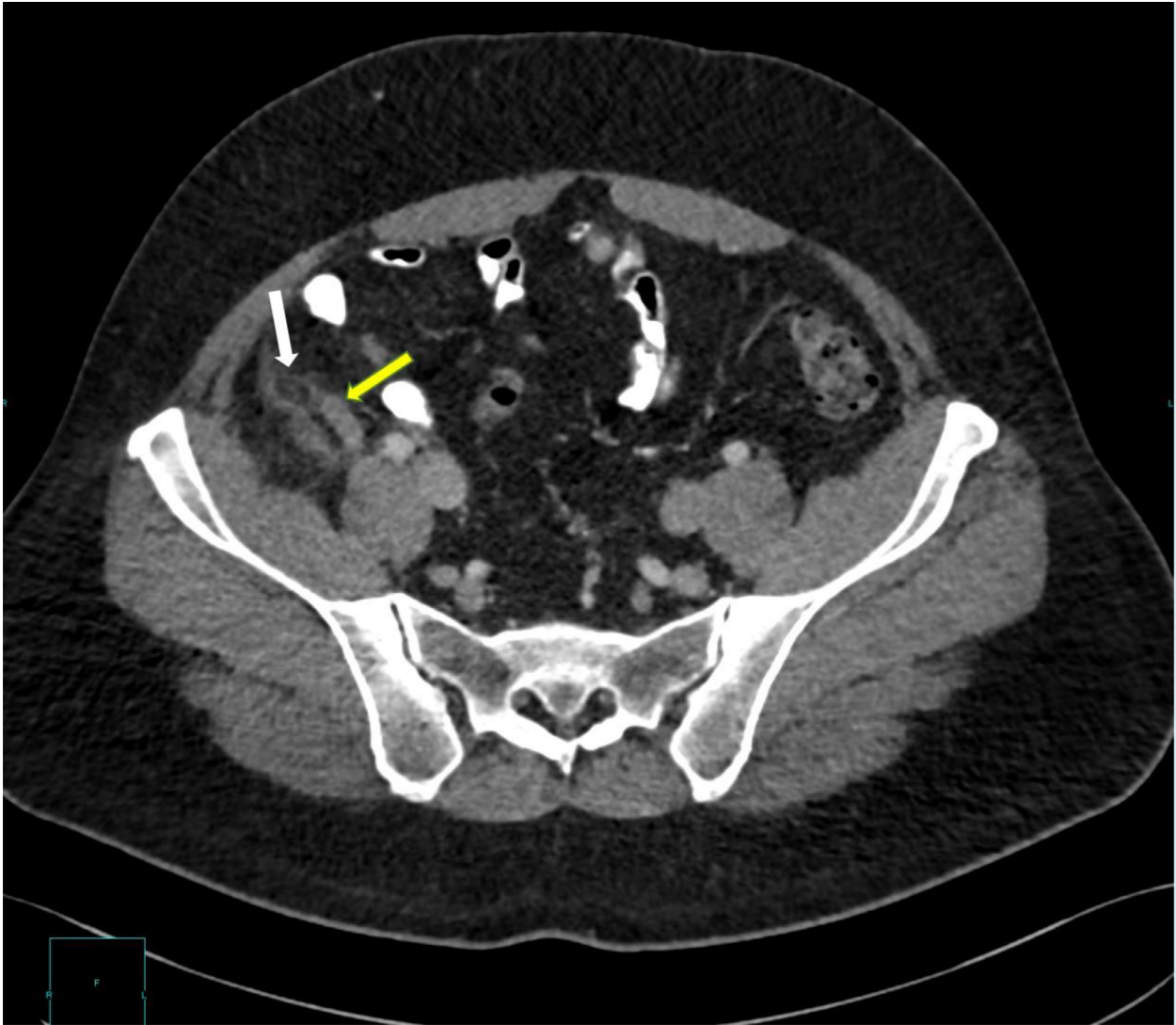


Fig. 1 – Axial CT image of the abdomen in the venous phase demonstrates normal appendix (yellow arrow). A small fat containing ovoid structure (white arrow) with peripheral hyperdense rim and surrounding fat stranding is seen adjacent to the appendix, suggestive of epiploic appendagitis of the appendix.

CT scan of the abdomen and pelvis was performed with oral and intravenous contrast. The CT images demonstrated a normal uninflamed appendix (yellow arrows in Figs. 1, 2, 5). However, there was a small ovoid fat attenuating structure (white arrows in Figs. 1, 3, 4) adjacent to the appendix with a thin high-density rim and surrounding inflammatory fat stranding. There was no wall thickening of the caecum (blue arrows in Figs. 3, 4) or of the terminal ileus (pink arrow Fig. 4). Diagnosis of epiploic appendagitis was made based on these findings. The patient was thus discharged with conservative management without having to go under the Surgeon's knife.

Discussion

Epiploic appendages are small benign outpouchings of visceral peritoneum that contain fat and small blood vessels and arise from the serosal surface adjacent to the tenia

coli in the colon [1,2]. They can arise from any segment of the colon, but are larger and most abundant in the transverse and sigmoid colon. They are usually rudimentary at the base of the appendix [1,3]. Occasionally, an epiploic appendage may undergo torsion or occlusion of its central vessel, resulting in inflammation and, eventually, acute ischemic infarction [4].

Normal epiploic appendages are not seen on CT imaging, unless they are inflamed, surrounded by intraperitoneal fluid (eg, ascites or hemoperitoneum), or calcified [5,6].

Abdominal pain is one of the most common presenting symptoms of patients who present to the emergency department. Imaging is often performed to exclude acute appendicitis, diverticulitis, or other conditions that may need surgical intervention. Epiploic appendagitis and omental infarction are two specific types of fat necrosis that commonly manifest with acute abdominal pain. Correct identification

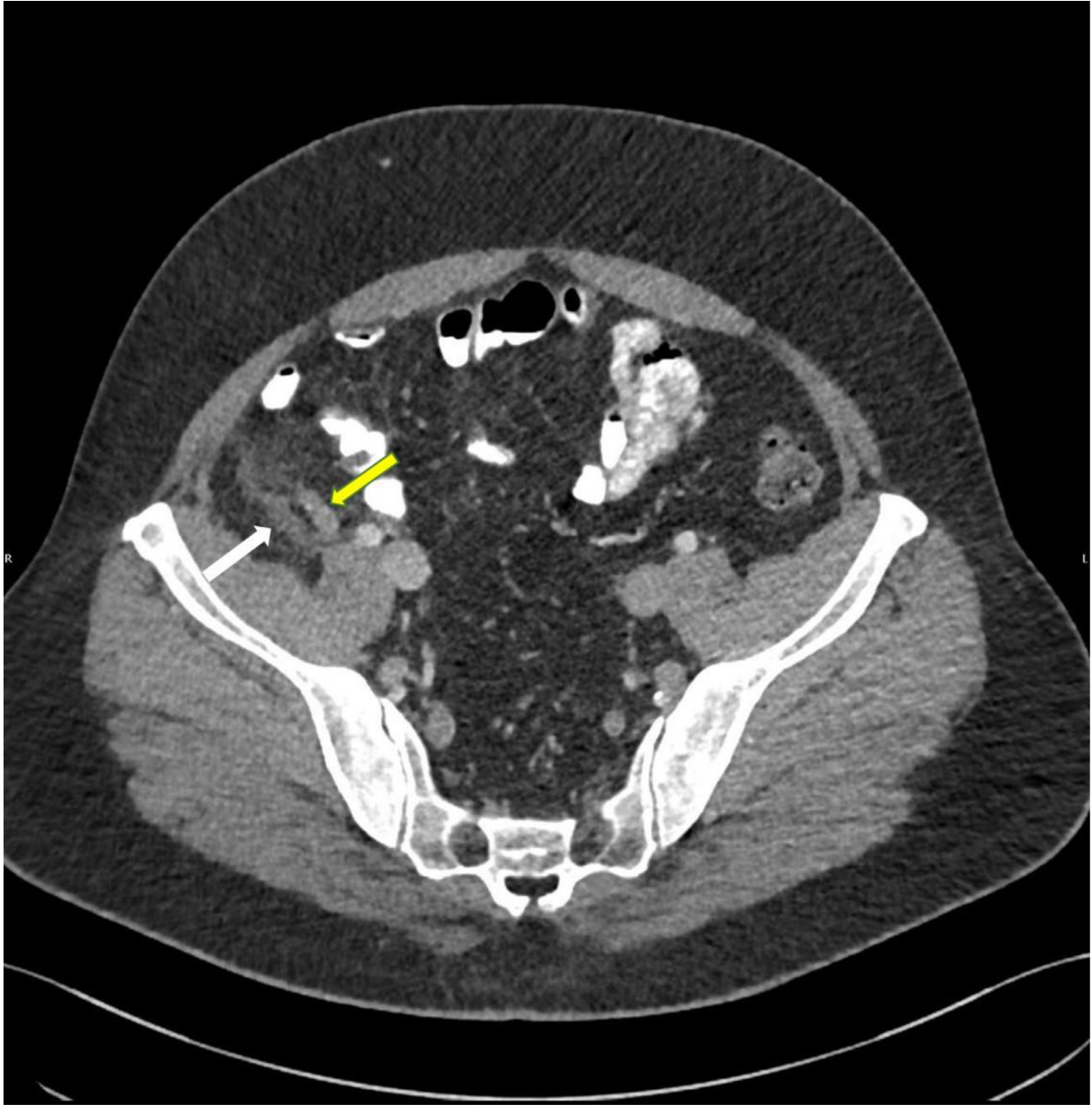


Fig. 2 – Axial contrast CT image of the abdomen in the venous phase demonstrates normal appendix (yellow arrow). Fat stranding (white arrow) is seen adjacent to the appendix.

of these conditions is crucial to avoid unnecessary surgical intervention [4].

Epiploic appendagitis most commonly manifests in the fourth to fifth decades of life, predominantly in men. Acute epiploic appendagitis is often missed when a diagnosis is based purely on clinical manifestations, without the aid of Imaging. Clinically, it manifests with acute onset of abdominal pain, most often in the left lower quadrant, and this symptom often leads to it being mistaken for acute diverticulitis. Similarly, epiploic appendagitis of the appendix presents with pain in the right iliac fossa, mimicking appendicitis. Unlike acute epiploic appendagitis, acute diverticulitis or appendicitis manifest with evenly distributed lower abdominal pain and

are often associated with nausea, fever, and leukocytosis. Although most patients with acute epiploic appendagitis do not report any change in their bowel habits, a minority do experience constipation or diarrhea [7]. Laboratory tests results are nonspecific and hence imaging is imperative for the diagnosis.

Typical CT features of epiploic appendagitis include a small (1.5-3.5 cm), oval area of fat attenuation surrounded by a ring of hyperattenuating inflamed peritoneum, situated usually anterior or anterolateral to the adjacent colon [8]. The hyperattenuating ring of visceral peritoneum surrounding an inflamed epiploic appendage is referred to as the “Hyperattenuating ring sign” [9]. A central hyperdense dot that is, “Central dot sign” may sometimes be seen within the ovoid structure, a

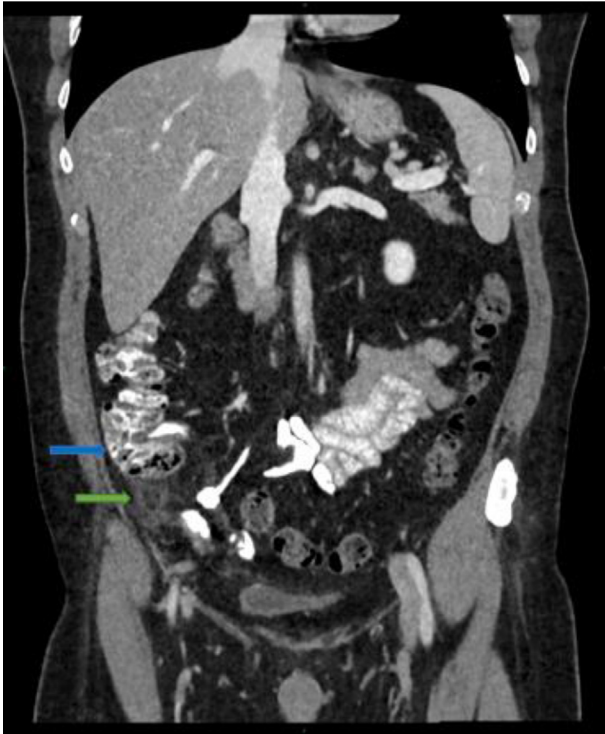


Fig. 3 – Contrast CT of the abdomen, coronal reformation, demonstrates normal caecum (blue arrow) and epiploic appendagitis (green arrow).

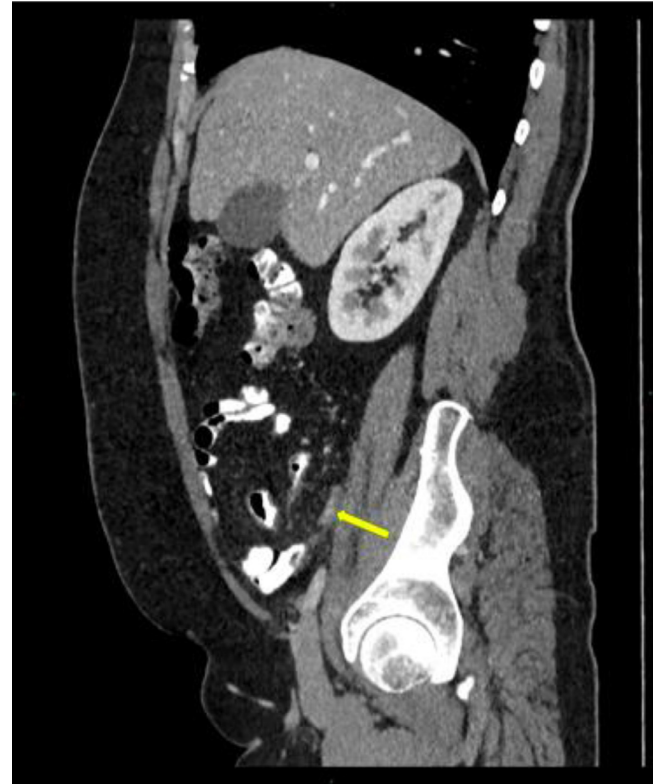

Fig. 5 – Contrast CT of the abdomen, sagittal reformation, demonstrates normal appendix (yellow arrow).

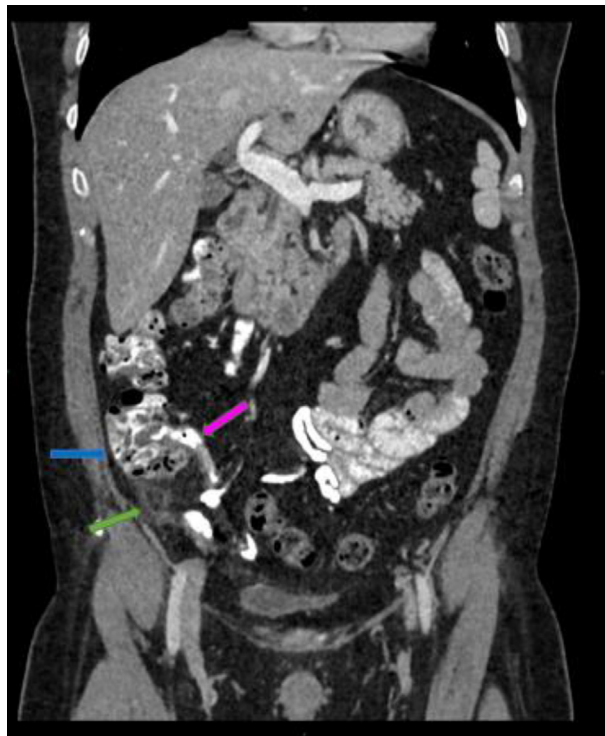

Fig. 4 – Contrast CT of the abdomen, coronal reformation, demonstrates normal caecum (blue arrow), normal ileocecal junction (pink arrow) and epiploic appendagitis (green arrow).

finding that represents a thrombosed vein or internal hemorrhage [10,12]. Adjacent colonic wall thickening is not usually evident, but if present is minimal and the amount of fat inflammation is out of proportional to colonic wall thickening.

At ultrasonography, epiploic appendagitis appears as an echogenic, non-compressible mass with a hypoechoic ring at the point of maximal tenderness. An epiploic appendage may sometimes completely twist off of its pedicle, resulting in a freely mobile mass in the abdominal cavity, referred to as “peritoneal mice” [4,11].

Acute epiploic appendagitis is managed conservatively with oral anti-inflammatory medication, and antibiotics are not routinely indicated. The condition is self-limited, and most patients recover with conservative management in less than 10 days. In contrast, a misdiagnosis of acute epiploic appendagitis without appropriate imaging may result in unnecessary hospital admission, antibiotic therapy, laboratory investigations, and dietary restrictions [7].

In contrast, a misdiagnosis of acute epiploic appendagitis without appropriate imaging may result in unnecessary hospital admission, antibiotic therapy, laboratory investigations, and dietary restrictions [7,6].

Consent

Not applicable as only the CT images are involved.

Human and animal rights

Not applicable.

Teaching Point

Epiploic appendagitis of the vermiform appendix is rare entity, clinically indistinguishable from appendicitis. Radiologists should be aware of this entity and its imaging features to avoid a potential misdiagnosis and the resultant unnecessary surgery.

Acknowledgments

I would like to express my deep gratitude to my colleagues in the Emergency Radiology department for their enthusiastic encouragement, valuable assistance and useful critiques of this work. I would also like to thank Dr. Shatha Al Hilli, the head of our department, for her advice and support. Finally, I wish to thank my wife, Asma Aljilly, for her support and encouragement throughout my study.

REFERENCES

- [1] Pines BR, Beller J. Primary torsion and infarction of the appendices epiploicae. *Arch Surg* 1941;42:775. <https://www.uptodate.com/contents/epiploic-appendagitis/abstract/1,13>.
- [2] Federle MP, Desser TS. Imaging manifestations of abdominal fat necrosis and its mimics aya kamaya. Published Online:Nov 8 2011 <https://doi.org/10.1148/rg.317115046>.
- [3] Patterson DC. Appendices epiploicae and their surgical significance with report of three cases. *N Engl J Med* 1933;209:1255. <https://www.ncbi.nlm.nih.gov/pmc/articles/PMC3939549>.
- [4] Kamaya A, Federle MP, Desser TS. Imaging manifestations of abdominal fat necrosis and its mimics. *RadioGraphics* 2011;31:2021–34. <https://pubs.rsna.org/doi/pdf/10.1148/rg.317115046>.
- [5] Kani KK, Moshiri M, Bhargava P, Kolokythas O. Extrahepatic, nonneoplastic, fat-containing lesions of the abdominopelvic cavity: spectrum of lesions, significance, and typical appearance on multidetector computed tomography. *Curr Probl Diagn Radiol* 2012;41(2):56–72vb. [https://www.radiographyonline.com/article/S1078-8174\(14\)00065-0/fulltext](https://www.radiographyonline.com/article/S1078-8174(14)00065-0/fulltext).
- [6] Elizabeth A, Chu BA, Kaminer E. Epiploic appendagitis: A rare cause of acute abdomen. *Radiol Case Rep* June 2018;13(3):599–601. <https://www.sciencedirect.com/science/article/abs/pii/S1930043318300256>.
- [7] Singh AK, Gervais DA, Hahn PF, et al. Acute epiploic appendagitis and its mimics. *RadioGraphics* 2005;25:1521–34. <https://pubs.rsna.org/doi/full/10.1148/rg.256055030>.
- [8] Rioux M, Langis P. Primary epiploic appendagitis: clinical, US, and CT findings in 14 cases. *Radiology* 1994;191(2):523–6. <https://reference.medscape.com/medline/abstract/8153333>.
- [9] Rao PM, Wittenberg J, Lawrason JN. Primary epiploic appendagitis: evolutionary changes in CT appearance. *Radiology* 1997;204(3):713–17. <https://www.ncbi.nlm.nih.gov/pubmed/9280248>.
- [10] Garg AG, Singh AK. Inflammatory fatty masses of the abdomen. *Semin Ultrasound CT MR* 2008;29(5):378–85. <https://pubs.rsna.org/doi/10.1148/rg.317115046>.
- [11] Gayer G, Petrovitch I, Jeffrey RB. Foreign objects encountered in the abdominal cavity at CT. *RadioGraphics* 2011;31(2):409–28. <https://pubs.rsna.org/doi/10.1148/rg.312105123>.
- [12] Giambelluca D, Dimarco M, Notte MRV, et al. The ‘central dot sign in acute epiploic appendagitis’. *Abdominal Radiol* 2019;44:1606–7. <https://link.springer.com/10.1007/s00261-018-1785-8>.