

¹⁸F-fluoro-2-deoxy-D-glucose positron emission tomography/computed tomography for preoperative planning in a rare case of hyperfunctional bilateral adrenocortical carcinoma and review of literatures

ABSTRACT

Adrenal cortical carcinoma (ACC) is a rare aggressive endocrine tumor with poor prognosis. About 60% of ACC are functional tumors. Bilateral ACC is extremely rare, roughly 2%–10% of cases. Diagnosis and staging of ACC by imaging modalities are crucial for preoperative planning and prognostication. Detection of hyperfunctional bilateral adrenocortical carcinoma by ¹⁸F-fluoro-2-deoxy-D-glucose positron emission tomography/computed tomography (¹⁸F-FDG PET/CT) has never been reported. Herein, we report a male patient who presented with Cushing's syndrome, type II diabetes mellitus due to Cushing's syndrome, and hypogonadism with biopsy confirmed left ACC. He underwent ¹⁸F-FDG PET/CT to evaluate the contralateral adrenal mass and to plan for laparoscopic adrenalectomy, which subsequently confirmed bilateral ACC. Furthermore, ¹⁸F-FDG PET/CT was useful in staging, which revealed paraaortic lymph node and lung metastasis.

Keywords: ¹⁸F-fluoro-2-deoxy-D-glucose positron emission tomography/computed tomography, adrenal cortical carcinoma, bilateral, Cushing's syndrome, laparoscopic adrenalectomy

INTRODUCTION

Adrenal cortical carcinoma (ACC) is a rare aggressive endocrine tumor. The incidence is approximately 1–2 million population/year.^[1] The prognosis is poor, even for patients with early stage. One-third of patients have metastasis at the presentation.^[2] About 60% of ACC are functional (hormone-secreting) tumors that can cause Cushing's syndrome, hyperaldosteronism, virilization, and/or feminization. Bilateral ACC is extremely rare, comprising roughly 2%–10% of cases.^[2] Diagnosis and staging of ACC by imaging modalities are crucial for preoperative planning and prognostication. ¹⁸F-fluoro-2-deoxy-D-glucose positron emission tomography/computed tomography (¹⁸F-FDG PET/CT) is an important imaging modality for lesion characterization based on increased glucose metabolism in tumors as well as for disease staging.^[3] Detection of bilateral ACC by ¹⁸F-FDG PET/CT has never been reported.

CASE REPORT

A 51-year-old male presented with hypertension, palpitation, facial plethora, feminization, and 15 kg of weight gain in 2 years. He had no remarkable medical history. On his physical examination, blood pressure was 190/130 mmHg,

APICHAYA CLAIMON, NGOENTRA TANTRANONT¹, TORPONG CLAIMON²

Departments of Radiology and ¹Pathology, Faculty of Medicine Siriraj Hospital, Mahidol University, ²Department of Radiology, Faculty of Medicine Vajira Hospital, Navamindradhiraj University, Bangkok, Thailand


Address for correspondence: Dr. Torpong Claimon, Department of Radiology, Faculty of Medicine Vajira Hospital, Navamindradhiraj University, Bangkok, Thailand. E-mail: toraman666@gmail.com

Submission: 27-Nov-19, **Accepted:** 10-Feb-20, **Published:** 22-Jul-20

This is an open access journal, and articles are distributed under the terms of the Creative Commons Attribution-NonCommercial-ShareAlike 4.0 License, which allows others to remix, tweak, and build upon the work non-commercially, as long as appropriate credit is given and the new creations are licensed under the identical terms.

For reprints contact: WKHLRPMedknow_reprints@wolterskluwer.com

How to cite this article: Claimon A, Tantranont N, Claimon T. ¹⁸F-fluoro-2-deoxy-D-glucose positron emission tomography/computed tomography for preoperative planning in a rare case of hyperfunctional bilateral adrenocortical carcinoma and review of literatures. World J Nucl Med 2020;19:301-5

Access this article online	
Website: www.wjnm.org	Quick Response Code 
DOI: 10.4103/wjnm.WJNM_86_19	

and Cushingoid features including moon face, truncal obesity, and buffalo hump. Screening abdominal ultrasonography from another hospital found bilateral adrenal masses, 10 cm and 3 cm on the left and right side, respectively. Biochemical workup at our hospital revealed fasting blood sugar 137 mg/dl (normal range: 74–99), hemoglobin A1C 7.6% (normal range: 4.8–5.9), morning cortisol 16.9 µg/dl (normal range: 6.02–18.4), adrenocorticotrophic hormone (ACTH) 5.49 pg/ml (normal range: 10.00–60.00), nonsuppressible cortisol production on both the standard low-dose and high-dose dexamethasone suppression test, 24-h urine corrected free cortisol 320.31 µg/day/g Cr (normal range: 0.00–150.00), testosterone 1.330 ng/ml (normal range: 1.93–7.40), follicle-stimulating hormone 0.36 mIU/ml (normal range: 1.5–12.4), and luteinizing hormone <0.1 mIU/ml (normal range: 1.7–8.6). Serum dehydroepiandrosterone sulfate (DHEA-S), urine metanephrine, and urine normetanephrine were normal. Plasma aldosterone and renin were not tested.

Contrast-enhanced abdominal CT scan of the chest including upper abdomen showed lobulated-enhancing masses with internal calcification and central necrosis, measuring about 12.0 and 3.7 cm in the left and right adrenal glands, respectively. Attenuation value of the left adrenal gland was 37 and 78 Hounsfield Unit (HU) on the unenhanced and enhanced CT, respectively. Differential diagnosis includes adrenal metastasis and primary adrenal tumor. Regarding lack of known primary tumor, the transperitoneal core-needle biopsy was performed from the left adrenal mass. Microscopic examination showed features suspicious for adrenal cortical tumors.

¹⁸F-FDG PET/CT scan was ordered for preoperative planning, which revealed a large heterogeneously enhancing mass with central necrosis and internal calcification at the left adrenal gland (12 cm × 9.2 cm) with intense uptake (maximal standardized uptake value [SUV_{max}] of 12.4) and pressure effect to the left renal vein, and left kidney and spleen. Another hypermetabolic mass was detected at the right adrenal (3.7 cm × 2.7 cm, SUV_{max}: 10.6). These masses showed central photopenic areas which represented the necrotic portion. Also, a 1.1 cm hypermetabolic lymph node was seen in the paraaortic region. The findings were suggestive of bilateral ACC with paraaortic lymph node metastasis. There are multiple scattered small solid nodules at both lungs which did not show FDG avidity but still suggestive of pulmonary metastasis based on CT characterization. Increased FDG uptake (SUV_{max}: 5.1) in a 1.7 cm left thyroid incidentaloma was also detected. Generalized increased uptake at colon resulted from metformin treatment for diabetes mellitus [Figure 1].

Laparoscopic bilateral adrenalectomy was performed. The surgery was completed uneventfully. The left adrenal gland

measured 12.5 cm × 10.7 cm × 6.2 cm and weighed 463 g. The right adrenal gland measured 7 cm × 4.2 cm × 3 cm and weighed 40 g. Cut surfaces of both adrenal glands revealed well-circumscribed soft to rubbery nonhomogeneous fleshy pink to light brown and yellow masses with foci of fibrosis and hemorrhage. Areas of cystic degeneration and necrotic were present in the left adrenal gland. Microscopic examination revealed that the masses had morphology highly suspicious of adrenal cortical tumors with features suggestive of malignant behavior (ACC). Those features were high nuclear Grades (III or IV), clear cell or vacuolated cells <25%, necrosis, diffuse architecture, atypical mitotic figures, capsular, venous, and sinusoidal invasion [Figure 2]. The modified Weiss scores were 7 and 6 for the left and right adrenal glands, respectively. Immunohistochemical staining demonstrated positive staining for melan-A, alpha-inhibin, synaptophysin, Vimentin, and CD56, but negative for CK7, CK20, AE1/AE3, EMA, RCC, hepatocyte marker, calretinin, TTF-1, napsin, and chromogranin. Ki-67/MIB1 labeling index was about 40% [Figure 3].

Thyroid ultrasonography was done for the evaluation of increased FDG uptake in the left thyroid nodule. The study revealed few mixed solid cystic nodules at both thyroid lobes, size from 1.0 cm to 1.4 cm. Fine-needle biopsy from the left thyroid nodule showed atypia of undetermined significance (Bethesda category III).

After the operation, the patient's general condition was stable. He received palliative chemotherapy (etoposide and cisplatin), which was terminated after the 4th cycle due to febrile neutropenia. Serial follow-up abdominal CT imaging revealed a residual tumor at the surgical bed of the left adrenal, 2.3 cm in size with progressive enlargement to 3.4 cm in the follow-up study. Furthermore, there was increase in size (to about 2.3 cm) and number of multiple bilateral pulmonary metastasis. Furthermore, a 6.7 cm pancreatic mass was found and causing obstruction of the pancreatic duct and common bile duct. Endoscopic ultrasonography with fine-needle biopsy of the pancreatic mass was suggested metastatic ACC. His condition was gradually deteriorated and suffered from the upper gastrointestinal tract bleeding from duodenal ulcer and sepsis. He was transferred to another hospital for the best supportive care and loss to follow-up at our hospital for 2 years after his surgery.

DISCUSSION

ACC is a rare malignancy with incidence about 1–2/million population/year.^[1] Approximately 60% of patients presented with adrenal steroid hormone excess, mostly showed

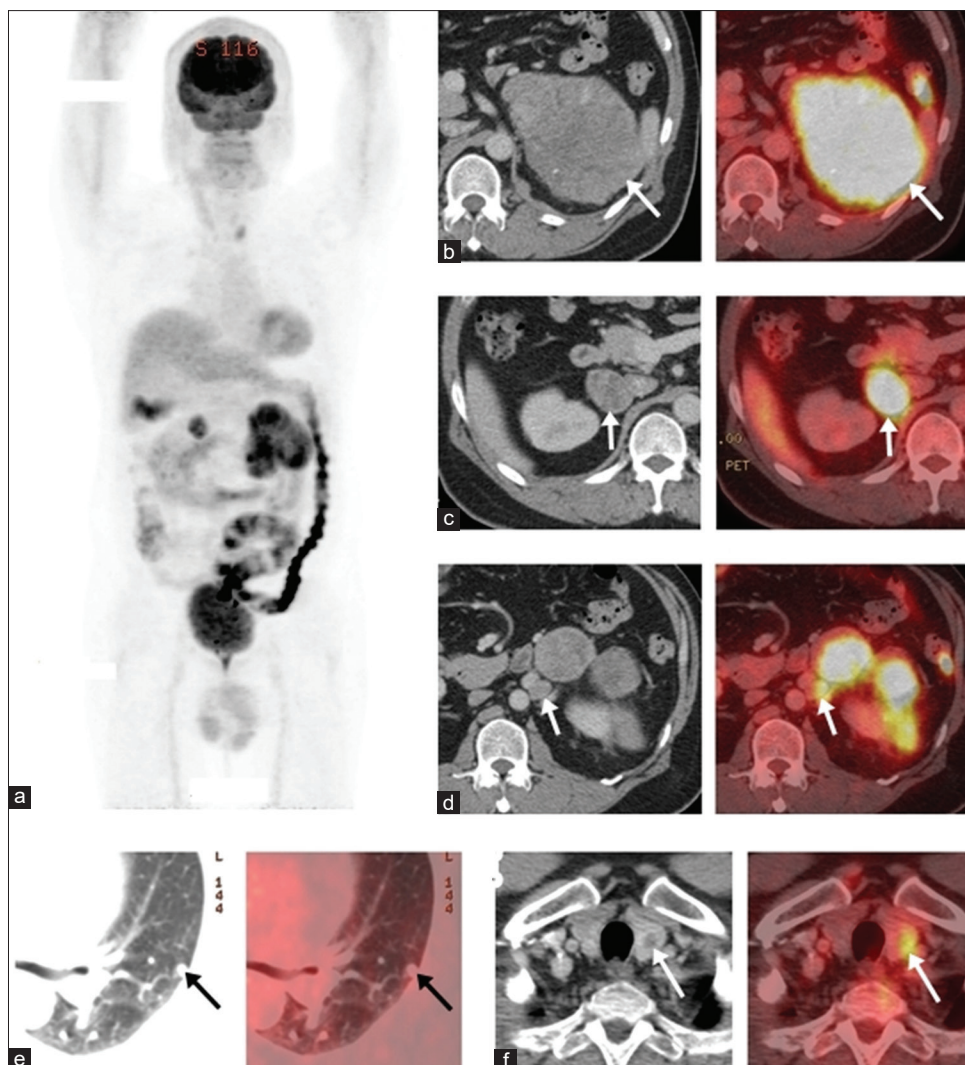


Figure 1: ¹⁸F-fluoro-2-deoxy-D-glucose positron emission tomography/computed tomography for preoperative planning. Maximal intensity projection images (a). Increased metabolism in the left (b) and right adrenal masses (c) that suggestive of bilateral adrenal cortical carcinoma. A 1 cm hypermetabolic paraaortic lymph node metastasis (d). Multiple small scattered nodules at both lungs that suggestive of lung metastasis (e). A 1.7 cm hypermetabolic left thyroid incidentaloma (f)

Cushing's syndrome due to cortisol hypersecretion. Hypersecretion of aldosterone by ACC leads to hypokalemia and hypertension.^[4] Hirsutism and virilization are seen in female with ACC. Feminization including gynecomastia and testicular atrophy are much rarely seen in males, approximately about 2% of ACC cases.^[2] Various laboratory tests are important for the evaluation of functional status of adrenal tumors. Hormonal testing confirmed that our patient had Cushing's syndrome and hypogonadism.

Imaging findings of ACC on CT are usually well-defined mass with size larger than 6 cm and show inhomogeneous density due to internal hemorrhage and necrosis.^[2] Microcalcification or macrocalcification can be seen in about 30% of cases. Contrast enhancement is usually inhomogeneous; however, small lesions may show homogeneous enhancement.

Distinguishing between benign and malignant adrenal masses may be obtained by measuring of HU and contrast washout rate. Unenhanced CT attenuation value of the left adrenal gland in this patient was 37 HU, in which value ≥ 10 HU generally exclude benign adenoma.^[2] Furthermore, there was evidence of central necrosis, internal calcification, inhomogeneous enhancement, and multiple metastasis that raised the likelihood for adrenal malignancy including ACC. However, the patient underwent a CT scan aiming to evaluate lung metastasis, in which the chest CT protocol could not provide contrast washout rate calculation.

When bilateral adrenal lesions are present, distant metastasis from the primary tumor elsewhere is primarily considered. The most common primary site is lung. In our case, the patient had no evidence of other primary tumors, and the

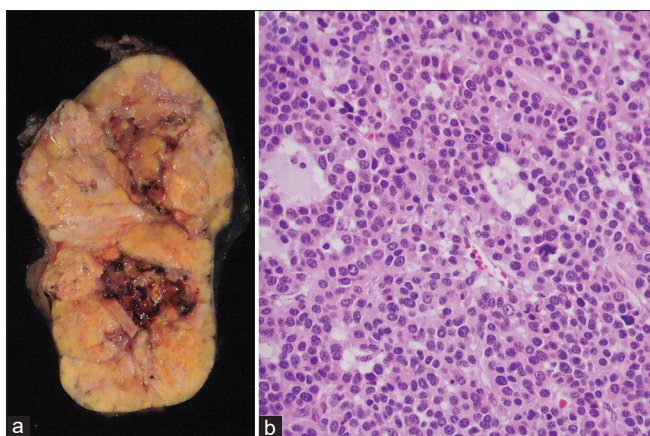


Figure 2: Gross examination revealed well-circumscribed nonhomogeneous yellow and light tan mass with fibrosis, hemorrhage, and necrosis (a). The tumor cells had eosinophilic cytoplasm with high nuclear grade and atypical mitosis (b)

hormonal investigations gave the clue to the diagnosis of functional adrenal tumor rather than metastatic lesion. Thus, tissue biopsy was needed for the final diagnosis. The left-sided ACC was biopsy confirmed. Hence, the right adrenal mass was also suspicious of ACC. Although extremely rare, bilateral ACC was reported in 2%–10% of cases.^[2]

¹⁸F-FDG PET/CT showed better accuracy than contrast-enhanced CT for identifying malignant adrenal mass (82% vs. 65%) and ACC (93.4% vs. 75%).^[3] PET/CT is most useful in identifying distant metastasis, which can be observed in one-third of ACC patients at the presentation.^[5] Our patient was sent for ¹⁸F-FDG PET/CT to evaluate the nature of the right adrenal mass and staging. The results suggested bilateral ACC with paraaortic lymph node and lung metastasis. There were small number of unilateral ACC reports with ¹⁸F-FDG PET/CT studies.^[3,6,7] To the best of our knowledge, ¹⁸F-FDG PET/CT findings of bilateral ACC reported here are probably the first reported in the literature.

Prognosis depends largely on tumor stage. Median survival of ACC with metastatic disease was usually < 12 months.^[1] Tumor debulking may help to control hormone excess and facilitate adjuvant treatment. Open adrenalectomy is the standard surgical approach for ACC, especially for the large size tumor. However, the recent study from Kostianen *et al.* showed that laparoscopic adrenalectomy was successful for the selected cases with tumor size ranging from 6 to 10 cm without local invasion and resulted in shorter hospitalization and showed comparable survival rate with open adrenalectomy.^[8] Our patient demonstrated that laparoscopic adrenalectomy can be safely applied to bilateral ACC with tumor size exceed to 12.5 cm. However,

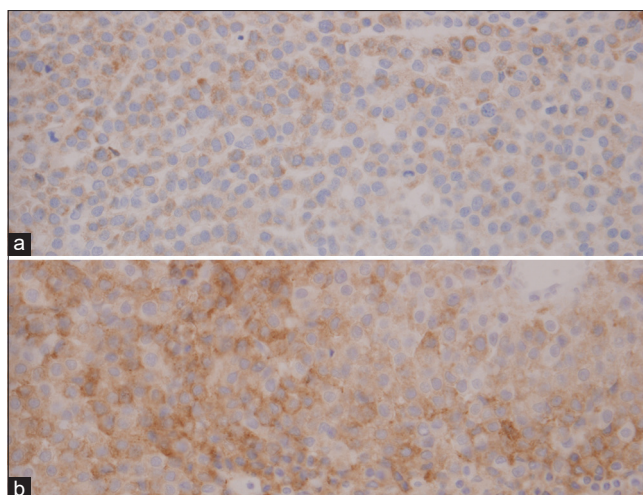


Figure 3: Immunohistochemistry. Positive staining for melan-A (a) and synaptophysin (b)

the 1 cm metastatic paraaortic lymph node that noted on PET/CT images could not be depicted intraoperatively due to its small size.

Adjuvant treatment for ACC after complete surgical resection, including chemotherapy, radiotherapy, radiofrequency ablation, and mitotane therapy, may be utilized to potentially improve cure rates and increased survival.^[1]

CONCLUSION

¹⁸F-FDG PET/CT is a useful imaging modality for preoperative evaluation of disease extent for ACC. While rare, bilateral ACC does occur. Futile intensive investigation of contralateral ACC and metastatic lesions can be avoided based on PET/CT results.

Declaration of patient consent

The authors certify that they have obtained all appropriate patient consent forms. In the form the patient(s) has/have given his/her/their consent for his/her/their images and other clinical information to be reported in the journal. The patients understand that their names and initials will not be published and due efforts will be made to conceal their identity, but anonymity cannot be guaranteed.

Financial support and sponsorship

The research authors (Apichaya Claimon and Ngoentra Tantranont) received a Chalermphrakiat grant from the Faculty of Medicine, Siriraj Hospital, Mahidol University.

Conflicts of interest

There are no conflicts of interest.

REFERENCES

1. Allolio B, Fassnacht M. Clinical review: Adrenocortical carcinoma: Clinical update. *J Clin Endocrinol Metab* 2006;91:2027-37.
2. Bharwani N, Rockall AG, Sahdev A, Gueorguiev M, Drake W, Grossman AB, *et al.* Adrenocortical carcinoma: The range of appearances on CT and MRI. *AJR Am J Roentgenol* 2011;196:W706-14.
3. Cistaro A, Niccoli Asabella A, Coppolino P, Quartuccio N, Altini C, Cucinotta M, *et al.* Diagnostic and prognostic value of ¹⁸F-FDG PET/CT in comparison with morphological imaging in primary adrenal gland malignancies – A multicenter experience. *Hell J Nucl Med* 2015;18:97-102.
4. Daga G, Sharma S, Mittal V. Bilateral aldosterone-producing adrenocortical carcinoma: A rare entity. *Indian J Surg Oncol* 2017;8:88-90.
5. Didolkar MS, Bescher RA, Elias EG, Moore RH. Natural history of adrenal cortical carcinoma: A clinicopathologic study of 42 patients. *Cancer* 1981;47:2153-61.
6. Libé R, Jazeron JF, Louiset E, Groussin L. ¹⁸F-FDG PET reveals an adrenocortical carcinoma in a bilateral adrenal multinodular disease. *Endocrine* 2019;63:188-9.
7. Beom SH, Lee KW, Yang Y, Choi Y, Song KH, Kim YJ, *et al.* Metastatic adrenocortical carcinoma presenting simultaneously with Cushing's and Conn's syndromes: A case report. *Jpn J Clin Oncol* 2011;41:1287-91.
8. Kostianen I, Hakaste L, Kejo P, Parviainen H, Laine T, Löyttyniemi E, *et al.* Adrenocortical carcinoma: Presentation and outcome of a contemporary patient series. *Endocrine* 2019;65:166-74.