

MULTIDISCIPLINARY SYMPOSIUM: BREAST CANCER

Monday 3 October 2005, 08:45–10:45

Screening women at increased risk with MRI

C Boetes and J Veltman

Department of Radiology, University Medical Center Nijmegen, Nijmegen, The Netherlands

Corresponding address: Dr C Boetes, Department of Radiology, 430, University Medical Center Nijmegen, PO Box 9101, 6500 HB Nijmegen, The Netherlands. E-mail: c.boetes@rad.umcn.nl

Abstract

Breast cancer is the most common cancer affecting women. In the screening of women for breast cancer, mammography is the most used imaging modality. Women with an increased risk for getting breast cancer can develop a malignancy at a relatively young age compared to other women. The increased risk for developing breast cancer can usually be found in a positive familial history. This positive familial history is based on a gene mutation in 5–10% of cases. The most common gene mutations are BRCA₁ and BRCA₂. This risk makes it necessary to start screening these women at a young age. Mammography, however, has proven to be less reliable in younger women because its sensitivity is lowered due to the dense breast tissue often present in this group. MRI has a higher sensitivity for detecting breast cancer compared to mammography. MRI is not influenced by the density of the breast tissue. This makes breast MRI the best modality available for the screening of women with an increased risk for developing breast cancer.

Keywords: *Breast; cancer; screening; high risk.*

Introduction

Breast cancer is the most common cancer affecting women and has an enormous impact on their health. The incidence of breast cancer varies between countries with the highest incidence in the United States and Northern Europe. In the United States breast cancer makes up 30% of all cancers in women, while in The Netherlands the lifetime risk for a woman for developing breast cancer is about 11%^[1].

The aetiology of breast cancer is varied: inherited genetic susceptibility, acquired genetic changes, and effects of endogenous and exogenous environment factors. The interactions of all these factors contribute to the development of breast cancer.

There is limited and indirect evidence that self-examination and physical examination can help in decreasing mortality because tumours smaller than 10 mm will not be detected in the majority of the cases^[2].

Most breast cancers are detected with mammography in either a screening situation or by the discovery of a palpable breast mass. The smaller the tumour is at detection, the better the prognosis^[3].

Randomised trials have shown that screening with mammography in the age category of 50–70 years can reduce mortality by about 25%. However, there is no consensus at the moment about the value of screening younger women with mammography. One of the reasons is the lower sensitivity of mammography in women below the age of 50 years. This is because young, pre-menopausal, women have denser breasts compared to post-menopausal women, resulting in an increased chance that a malignancy will be missed on mammography^[4].

In a diagnostic setting, magnetic resonance imaging (MRI) is a very sensitive tool for the detection of breast cancer. Especially for invasive breast cancer, the sensitivity of this imaging technique is reported to be above 95%^[5]. This sensitivity is not influenced in any way by the amount of glandular tissue present in the breast. However the specificity of this modality is only moderate. The role of MRI as a screening modality has not yet been outlined. In the literature, MRI has only been evaluated as a screening tool for women with an increased risk for developing breast cancer^[6–8]. In this paper the role of MRI in the screening of women with an increased risk for developing breast cancer is discussed.

Increased risk for breast cancer

There are two categories of women who have an increased risk for developing breast cancer.

The first group are those with a family history of breast cancer. Approximately 20%–30% of women with breast cancer have a positive family history and about 20% of these individuals have a first degree relative with breast cancer^[9]. Only about 5%–10% of all cases of breast cancer are caused by inherited factors. The most common gene mutations are the BRCA₁ and BRCA₂.

In 1990, Hall and co-workers identified chromosome 17 q 21 as the location of a susceptibility gene for early onset breast cancer, now known as the BRCA₁ gene mutation^[10]. Shortly after that Narod^[11] described a linkage between the genetic marker D17 S 74 on 17 q 21 and ovarian cancer. In two different studies the suggestion has been made that about 3% of all breast cancers are caused by the BRCA₁ gene^[12,13] and about 45% of all hereditary cases of breast cancer are caused by the BRCA₁ mutation. Mutations in the BRCA₁ are most commonly seen in Russia, followed by Israel and Italy^[14]. Women who are carriers of the BRCA₁ gene mutation have a lifetime risk (LTR) for developing breast cancer of approximately 80%. Exogenous hormone and carcinogen exposure are also risk-modifying factors in this group.

Other malignancies suggested to have an increased prevalence in these families are ovarian cancer, prostate and colonic cancer^[12]. BRCA₁ associated breast malignancies tend to have a high malignancy grade and are often oestrogen and progesterone receptor negative. The tumour is also highly proliferative^[15]. Median age of onset of breast cancer in this group is younger than 45 years^[16].

Approximately 35% of all inherited breast cancers are caused by the BRCA₂ mutation, first identified by Wooster *et al.*^[17]. They also described a linkage between BRCA₂ mutation and male breast cancer. The estimated LTR for developing breast cancer in this group is somewhat lower than in the BRCA₁ group. It has been suggested by Ursin^[18] that in this group the use of oral contraceptives also increases the risk for developing breast cancer.

A variety of other malignancies are associated with the BRCA₂ carriers. Non-Hodgkin's lymphoma has been reported and also prostate cancer and bladder cancer^[19,20]. The BRCA₂ mutation is associated with a 6% LTR of male breast cancer^[21], which means a 100-fold increase over the general male population. At the moment little is known about the malignancy grade and receptor status in the BRCA₂ group^[15].

For both the BRCA₁ and BRCA₂ mutation carriers, the LTR for a contralateral breast cancer is about 65%^[15].

There are other more sporadic hereditary diseases with an increased risk for developing breast cancer. The Li-Fraumeni syndrome was first identified in 1969^[22]. It is an autosomal dominant disease causing an increased

risk for developing among others breast cancer, different types of sarcoma and leukaemia. In this group 30% of all malignancies occur before the age of 15. Cowden's disease or multiple hamartoma syndrome showed an increased risk for both benign breast disorders like fibroadenomas and nipple malformations and breast malignancies^[23,24]. Other hereditary diseases such as ataxia telangiectasia and the Peutz-Jeghers syndrome (hamartomatous polyps in the small bowel) and the Muir-Torre syndrome (a variant of hereditary non-polyposis colon cancer) also give an increased risk for breast cancer^[25].

Another group of women with an increased risk for breast cancer consists of women who have an individual risk factor. Patients with a history of lobular carcinoma *in situ* (LCIS) have a somewhat increased incidence of developing an invasive cancer. The National Surgical Adjuvant Breast and Bowel Project (NSABBP) suggested an incidence of 13 invasive malignancies in 1000 women with an LCIS^[26]. In this group there is also a risk for bilateral breast cancer. Ductal carcinoma *in situ* (DCIS) also gives an increased risk for an invasive breast malignancy. About 30% of women not treated postoperatively with irradiation developed an invasive malignancy after a mean interval of 6 years^[27,28]. Invasive lobular carcinoma is characterized by multifocality in the ipsilateral breast and appears to be more often bilateral^[29] than other types of invasive malignancies^[30].

In the updated results of the nurses' Health Study, post- or per-menopausal use of hormones showed an excess risk for developing breast cancer in the group of women with current or recently used hormones^[31]. The risk increased with increasing duration.

Women treated with irradiation of the chest for, for instance, (non-)Hodgkin's lymphoma, also have an increased risk for developing breast cancer. The excess risk in this category of patients is dependent on dose and age at irradiation. The younger the age at time of exposure to irradiation, the younger the onset of breast cancer^[32].

Screening of the breast

Currently there are four possible breast screening modalities: clinical examination, mammography, ultrasound and MRI. The primary goal of breast examinations during screening is the detection of breast cancer at an as early stage as possible in order to reduce mortality.

Clinical examinations of the breasts and self-examination as a screening procedure have been poorly evaluated. There is only limited and indirect evidence that these methods could help in decreasing mortality due to breast cancer^[2]. As mentioned, small malignant lesions (<10 mm) will not be detected by palpation in the majority of cases. Kriege and co-workers showed a sensitivity of only 17.8% of clinical breast examination in a screening setting^[6].

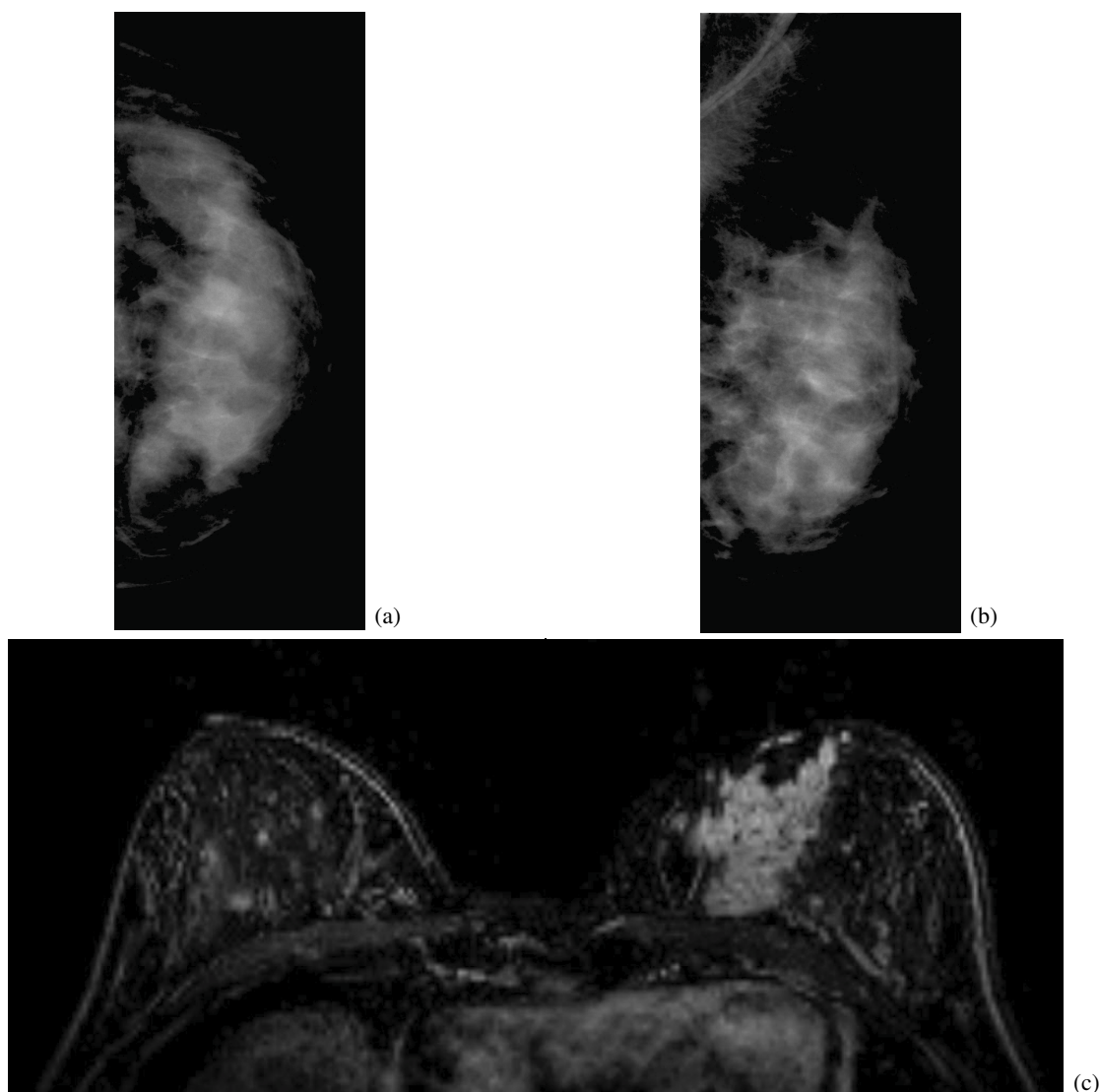


Figure 1 (a), (b) The mammography of a 39-year-old woman obtained during annual screening because of a familial history of breast cancer. No abnormalities were seen. (c) The MRI examination obtained on the same day. Strong irregular enhancement in the medial part of the left breast was detected. Pathology revealed a DCIS grade 3.

The most used imaging tool for screening at the moment is mammography. The sensitivity of mammography increases with the age of the woman. The younger the woman, the more glandular tissue there is, the denser the breasts are, and the lower the sensitivity of mammography. For women in the age group 40–50 sensitivity ranges from about 50% to 80%, while in the age group over 50 the sensitivity ranges from 70% to about 90%^[33]. The sensitivity of mammography in the case of invasive lobular carcinoma (ILC) is lower than in women with invasive ductal carcinoma (IDC)^[30].

In 1973, the breast cancer detection demonstration project (BCDDP) was started. In the subsequent 7 years more than 280 000 women were screened. The screening depicted about half of all breast cancers detected in the screened area. In addition, the distribution of stage was more favourable in the screened population than in a

control group in that area, so overall long-term survival was also better^[34]. In 1998 in the Netherlands a mortality reduction of 13% was reached in the age category 55–74 since the beginning of screening in 1990 with conventional mammography^[35]. Other screening trials like the health insurance plan of New York (HIP-study) showed a mortality reduction of 30% in the screened group compared to the control group. Analysis of age specific mortality reduction indicates that screening for breast cancer has a special benefit in older women above the age of 50 and less in the younger age group. In addition, Tabar *et al.* showed that the likelihood of dedifferentiation of a tumour is much higher in women younger than 40 years^[36]. Survival is also influenced by both tumour grade and the size of the tumour^[36,37].

There is currently no evidence that ultrasound (US) has a role as a screening modality for breast cancer. The two

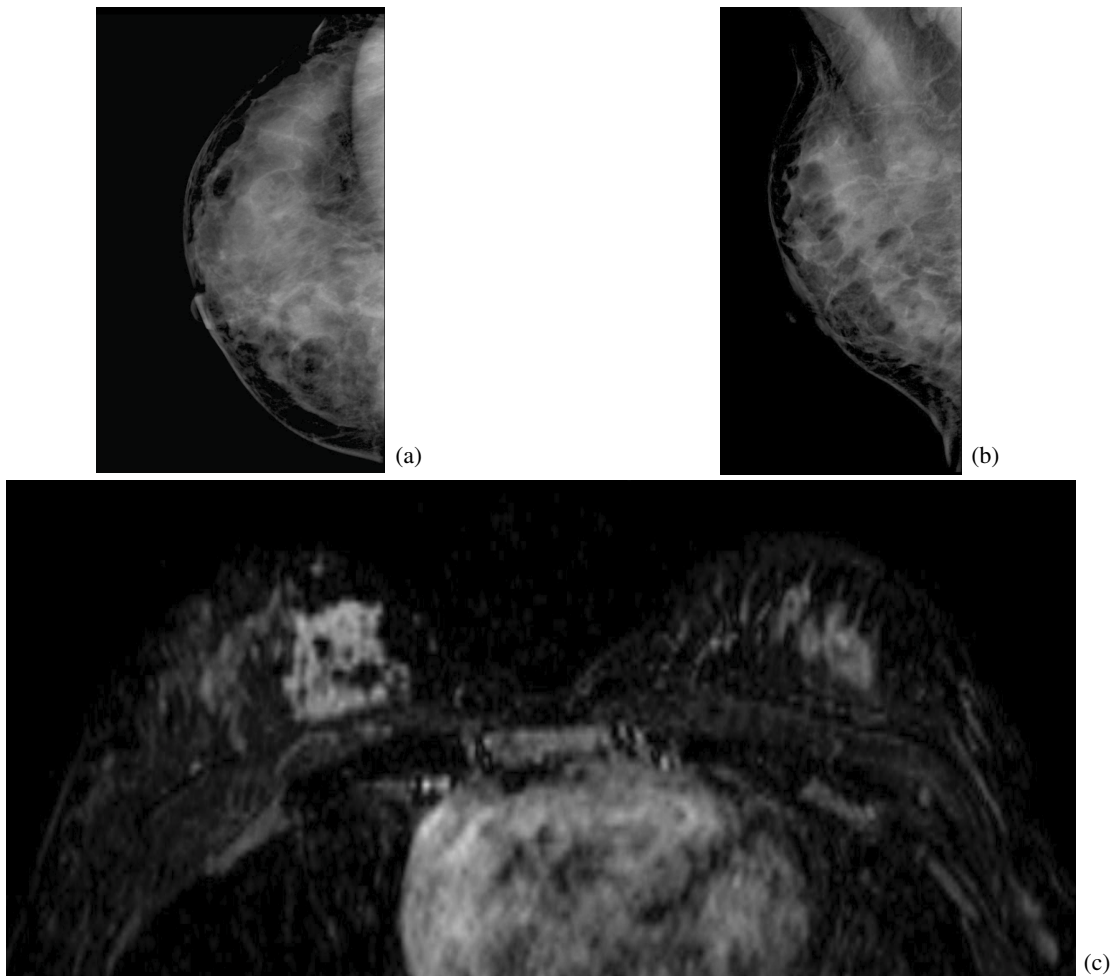


Figure 2 (a), (b) The mammography of a 32-year-old woman obtained during annual screening because of a proven BRCA₂ gene carrier. Very dense glandular tissue was seen on mammography. (c) The MRI from the same day. In the medial part of the right breast an irregular strong enhancing area was seen. Pathology showed an invasive duct carcinoma.

most important roles of US are differentiation between cystic and solid lesions in the breast and US guided biopsy of solid breast lesions.

MRI of the breast is nowadays mostly performed as a dynamic investigation. The most currently used investigation technique is the FLASH 3D technique which includes one series of images pre-contrast and five series of images after intravenous administration of contrast medium containing gadolinium. MR images are evaluated according to morphology and kinetic behaviour of the lesions^[38]. Smoothly outlined round or oval lesions tend more to be benign, while speculated lesions are more suspicious of a malignancy. If a lesion shows a wash out on kinetic behaviour, this is highly suspicious for a malignancy. If there is progress in signal intensity over time this is more characteristic for a benign lesion^[38]. Although the sensitivity of MRI for detecting invasive breast cancer is more than 95%, the value in detecting DCIS, especially DCIS grade I, is lower^[39]. DCIS grade 3 can usually be detected on MRI (Fig. 1).

The sensitivity for DCIS is described by Orel *et al.*^[40] to be in the range of 75%. Three grade I DCIS were missed. This is in comparison to the results of Boetes *et al.*^[41], who also described a sensitivity of about 75% in this group. In a series of 17 patients, they missed four cases of DCIS, 3 grade I and 1 grade III. The problem with screening with MRI is the relatively low specificity, which means a relatively high number of false-positive findings. Almost all women with a genetic predisposition for developing breast cancer are younger than the age of 50. So the value of screening with conventional mammography is doubtful in this group of women.

Especially in young women in a screening situation it is important to diagnose a malignancy as early as possible to increase survival.

Kuhl was the first to describe the results of MRI in a screening situation for women with an increased risk for developing breast cancer^[7]. A group of 192 asymptomatic and six symptomatic women were evaluated. In the symptomatic group, MRI detected all

malignancies. In the asymptomatic group of women, nine malignancies were found. MRI detected all nine, whereas mammography combined with US detected only four.

In the same year Tilanus-Linthorst described an asymptomatic group of 109 women with a 25% or more lifetime risk, in which 12 gene carriers also were included. In this group MRI detected three malignancies occult on mammography^[42]. A retrospective study in 2001 by Stoutjesdijk *et al.*, evaluated 75 women, of whom 20% were proven gene carriers. Thirteen malignancies in this group showed a cancer on MRI while mammography detected five^[43].

In 2003, Morris and co-workers described a group of 367 women, retrospectively. MRI detected 14 more malignancies than mammography^[44].

In 2004, the results of screening a group of 1909 women with both MRI and mammography were described by Kriege *et al.*^[6]. In the LTR group of 15%–30%, the detection rate for cancer was 7.8 per 1000 women, in the LTR of 30%–50% the detection rate was 5.4 per 1000. However, in the group of carriers of BRCA_{1/2} the incidence of malignancy was 26.5 per 1000 women. The overall sensitivity for the detection of breast cancer was 40% for mammography and 71.5% for MRI (Fig. 2). If only the invasive cancers were taken into account the sensitivity of mammography dropped to 33% and of MRI increased to 79%. In the MRISK study group 43% of all invasive malignancies were smaller than 10 mm, but in two selected control groups only, 14 and 12.5%, the tumour was smaller than 10 mm. The negative node status was also better in the MRISK group than in both control groups with 21.4% compared to 52.4 and 56.4%, respectively.

The results for the MRISK study group are confirmed by the MARIBS study^[8]. They evaluated 649 women with a total of 1881 screens both with mammography and MRI. Sensitivity of mammography was 40% and for MRI this was 77%. The combination of both imaging techniques showed a sensitivity of 94%. The difference in sensitivity was especially seen in the gene carrier group. However, as stated by Liberman^[45], any method of screening for breast cancer has the potential for both benefit and harm. Harm are the costs, anxiety, follow-up imaging and benign biopsies. The benefit of screening is especially the detection of a malignancy as early as possible. This may give a mortality reduction. Although prognosis of small breast cancers is better, the detection of a small cancer does not guarantee an improved survival rate. The real value of screening can only be proved by randomized controlled trials with death as an end point. However, this is no longer possible. The data published to date show that screening with MRI has benefit for the group of women at high risk for developing breast cancer. However, if a centre proceeds to screen with MRI it should follow technical and interpretative guidelines and there should be the possibility of performing MR guided biopsies^[46,47].

Conclusion

In the screening of women with an increased risk for developing breast cancer detection needs to be done at a young age. Therefore mammography is of limited value. Because the sensitivity of MRI is high for detecting breast cancer and because this sensitivity is not influenced by the amount of glandular tissue present, as with mammography, MRI is the best modality available at this time for the screening of women with an increased risk for developing breast cancer.

References

- [1] Visser O, Coebergh JWW, van Dijk JAAM *et al.*, eds. Incidence of Cancer in the Netherlands 1998. Utrecht, the Netherlands: Netherlands Cancer Registry, 2002.
- [2] Baines CJ, Miller AB, Bassett AA. Physical examination. Its role as a single screening modality in the Canadian National Breast Screening Study. *Cancer* 1989; 63: 1816–22.
- [3] Chu KC, Tarone RE, Kessler LG *et al.* Recent trends in US breast cancer incidence, survival, and mortality rates. *J Natl Cancer Inst* 1996; 88: 1571–9.
- [4] Nystrom L, Andersson I, Bjurstam N, Frisell J, Nordenskjold B, Rutqvist LE. Long-term effects of mammography screening: updated overview of the Swedish randomised trials. *Lancet* 2002; 359: 909–19.
- [5] Bedrosian I, Schlenker J, Spitz FR *et al.* Magnetic resonance imaging-guided biopsy of mammographically and clinically occult breast lesions. *Ann Surg Oncol* 2002; 9: 457–61.
- [6] Kriege M, Brekelmans CT, Boetes C *et al.* Efficacy of MRI and mammography for breast-cancer screening in women with a familial or genetic predisposition. *N Engl J Med* 2004; 351: 427–37.
- [7] Kuhl CK, Schmutzler RK, Leutner CC *et al.* Breast MR imaging screening in 192 women proved or suspected to be carriers of a breast cancer susceptibility gene: preliminary results. *Radiology* 2000; 215: 267–79.
- [8] Leach MO, Boggis CR, Dixon AK *et al.* Screening with magnetic resonance imaging and mammography of a UK population at high familial risk of breast cancer: a prospective multicentre cohort study (MARIBS). *Lancet* 2005; 365: 1769–78.
- [9] Newman B, Mu H, Butler LM, Millikan RC, Moorman PG, King MC. Frequency of breast cancer attributable to BRCA1 in a population-based series of American women. *JAMA* 1998; 279: 915–21.
- [10] Hall JM, Lee MK, Newman B, Morrow JE, Anderson LA, Huey B, King MC. Linkage of early-onset familial breast cancer to chromosome 17q21. *Science* 1990; 250: 1684–9.
- [11] Narod SA, Feunteun J, Lynch HT *et al.* Familial breast-ovarian cancer locus on chromosome 17q12-q23. *Lancet* 1991; 338: 82–3.
- [12] Struwing JP, Hartge P, Wacholder S *et al.* The risk of cancer associated with specific mutations of BRCA1 and BRCA2 among Ashkenazi Jews. *N Engl J Med* 1997; 336: 1401–8.

- [13] Whittemore AS, Gong G, Itnyre J. Prevalence and contribution of BRCA1 mutations in breast cancer and ovarian cancer: results from three US population-based case-control studies of ovarian cancer. *Am J Hum Genet* 1997; 60: 496–504.
- [14] Szabo CI, King MC. Population genetics of BRCA1 and BRCA2. *Am J Hum Genet* 1997; 60: 1013–20.
- [15] DeMichelle A, Weber BL. Inherited genetic factors. In: Diseases of the Breast. Harris JR, Lippman ME, Morrow M *et al.*, eds. Philadelphia, PA: Lippincott Williams and Wilkins, 1999: 221–36.
- [16] Easton DF, Bishop DT, Ford D, Crockford GP. Genetic linkage analysis in familial breast and ovarian cancer: results from 214 families. The Breast Cancer Linkage Consortium. *Am J Hum Genet* 1993; 52: 678–701.
- [17] Wooster R, Neuhausen SL, Mangion J *et al.* Localization of a breast cancer susceptibility gene, BRCA2, to chromosome 13q12-13. *Science* 1994; 265: 2088–90.
- [18] Ursin G, Henderson BE, Haile RW *et al.* Does oral contraceptive use increase the risk of breast cancer in women with BRCA1/BRCA2 mutations more than in other women? *Cancer Res* 1997; 57: 3678–81.
- [19] Schubert EL, Lee MK, Mefford HC *et al.* BRCA2 in American families with four or more cases of breast or ovarian cancer: recurrent and novel mutations, variable expression, penetrance, and the possibility of families whose cancer is not attributable to BRCA1 or BRCA2. *Am J Hum Genet* 1997; 60: 1031–40.
- [20] Teng DH, Bogden R, Mitchell J *et al.* Low incidence of BRCA2 mutations in breast carcinoma and other cancers. *Nat Genet* 1996; 13: 241–4.
- [21] Wooster R, Bignell G, Lancaster J *et al.* Identification of the breast cancer susceptibility gene BRCA2. *Nature* 1995; 378: 789–92.
- [22] Li FP, Fraumeni Jr JF, Mulvihill JJ *et al.* A cancer family syndrome in twenty-four kindreds. *Cancer Res* 1988; 48: 5358–62.
- [23] Brownstein MH, Wolf M, Bikowski JB. Cowden's disease: a cutaneous marker of breast cancer. *Cancer* 1978; 41: 2393–8.
- [24] Starink TM. Cowden's disease: analysis of fourteen new cases. *J Am Acad Dermatol* 1984; 11: 1127–41.
- [25] Jeghers H, McKusick VA, Katz KH. Generalized intestinal polyposis and melanin spots of the oral mucosa, lips and digits; a syndrome of diagnostic significance. *N Engl J Med* 1949; 241: 993.
- [26] Fisher B, Costantino JP, Wickerham DL *et al.* Tamoxifen for prevention of breast cancer: report of the National Surgical Adjuvant Breast and Bowel Project P-1 Study. *J Natl Cancer Inst* 1998; 90: 1371–88.
- [27] Page DL, Dupont WD, Rogers LW, Landenberger M. Intraductal carcinoma of the breast: follow-up after biopsy only. *Cancer* 1982; 49: 751–8.
- [28] Page DL, Dupont WD, Rogers LW, Jensen RA, Schuyler PA. Continued local recurrence of carcinoma 15–25 years after a diagnosis of low grade ductal carcinoma in situ of the breast treated only by biopsy. *Cancer* 1995; 76: 1197–200.
- [29] Contesso G, Mouriesse H, Friedman S, Genin J, Sarrazin D, Rouesse J. The importance of histologic grade in long-term prognosis of breast cancer: a study of 1010 patients, uniformly treated at the Institut Gustave-Roussy. *J Clin Oncol* 1987; 5: 1378–86.
- [30] Boetes C, Veltman J, van DL, Bult P, Wobbes T, Barentsz JO. The role of MRI in invasive lobular carcinoma. *Breast Cancer Res Treat* 2004; 86: 31–7.
- [31] Colditz GA, Hankinson SE, Hunter DJ *et al.* The use of estrogens and progestins and the risk of breast cancer in postmenopausal women. *N Engl J Med* 1995; 332: 1589–93.
- [32] Hancock SL, Tucker MA, Hoppe RT. Breast cancer after treatment of Hodgkin's disease. *J Natl Cancer Inst* 1993; 85: 25–31.
- [33] Fletcher SW, Black W, Harris R, Rimer BK, Shapiro S. Report of the International Workshop on Screening for Breast Cancer. *J Natl Cancer Inst* 1993; 85: 1644–56.
- [34] Bassett LW, Liu TH, Giuliano AE, Gold RH. The prevalence of carcinoma in palpable vs. impalpable, mammographically detected lesions. *AJR Am J Roentgenol* 1991; 157: 21–4.
- [35] National Evaluation Team for Breast Cancer Screening. Nationwide breast cancer screening fully accomplished; results from the implementation phase 1990–1997. *Ned Tijdschr Geneesk* 2000; 144: 1124–9.
- [36] Tabar L, Duffy SW, Burhenne LW. New Swedish breast cancer detection results for women aged 40–49. *Cancer* 1993; 72(Suppl 4): 1437–48.
- [37] Tabar L, Fagerberg G, Duffy SW, Day NE, Gad A, Grontoft O. Update of the Swedish two-county program of mammographic screening for breast cancer. *Radiol Clin North Am* 1992; 30: 187–210.
- [38] Kuhl CK. MRI of breast tumors. *Eur Radiol* 2000; 10: 46–58.
- [39] Boetes C, Mus RD, Holland R *et al.* Breast tumors: comparative accuracy of MR imaging relative to mammography and US for demonstrating extent. *Radiology* 1995; 197: 743–7.
- [40] Orel SG, Mendonca MH, Reynolds C, Schnell MD, Solin LJ, Sullivan DC. MR imaging of ductal carcinoma in situ. *Radiology* 1997; 202: 413–20.
- [41] Boetes C, Strijk SP, Holland R, Barentsz JO, Van Der Sluis RF, Ruijs JH. False-negative MR imaging of malignant breast tumors. *Eur Radiol* 1997; 7: 1231–4.
- [42] Tilanus-Linthorst MM, Obdeijn IM, Bartels KC, de Koning HJ, Oudkerk M. First experiences in screening women at high risk for breast cancer with MR imaging. *Breast Cancer Res Treat* 2000; 63: 53–60.
- [43] Stoutjesdijk MJ, Boetes C, Jager GJ *et al.* Magnetic resonance imaging and mammography in women with a hereditary risk of breast cancer. *J Natl Cancer Inst* 2001; 93: 1095–102.
- [44] Morris EA, Liberman L, Ballon DJ *et al.* MRI of occult breast carcinoma in a high-risk population. *AJR Am J Roentgenol* 2003; 181: 619–26.
- [45] Liberman L. Breast cancer screening with MRI—what are the data for patients at high risk? *N Engl J Med* 2004; 351: 497–500.
- [46] Veltman J, Boetes C, Wobbes T, Blickman JG, Barentsz JO. Magnetic resonance-guided biopsies and localizations of the breast: initial experiences using an open breast coil and compatible intervention device. *Invest Radiol* 2005; 40: 379–84.
- [47] Viehweg P, Heinig A, Amaya B, Alberich T, Laniado M, Heywang-Kobrunner SH. MR-guided interventional breast procedures considering vacuum biopsy in particular. *Eur J Radiol* 2002; 42: 32–9.