



Case report

VV-ECMO for surgical cure of a critical central airway obstruction

Hassan A. Raza^{a,*}, Brandon T. Nokes^b, Dawn Jaroszewski^c, Ashley Garrett^e, Ramachandra Sista^e, Jeffrey Ross^d, Joseph C. Farmer^e, Philip J. Lyng^{e,**}

^a Department of Medicine, New York Presbyterian Queens, United States

^b Department of Pulmonary and Critical Care Medicine, University of California, San Diego, United States

^c Division of Cardiothoracic Surgery, Mayo Clinic, AZ, United States

^d Department of Radiology, Mayo Clinic, AZ, United States

^e Department of Pulmonary and Critical Care Medicine, Mayo Clinic, AZ, United States

A B S T R A C T

Extracorporeal membrane oxygenation (ECMO) is a form of prolonged cardiopulmonary bypass that has extensively been used in critically ill patients in an intensive care setting. Both veno-venous (VV-) and veno-arterial (VA-) ECMO have been described as a perioperative rescue or replacement of endotracheal intubation in the setting of extrinsic airway compression due to a mediastinal mass. In this paper, we will outline the utility of ECMO in the context of extrinsic airway compression and will use an illustrative case to examine how ECMO can be useful during severe airway obstruction. Our patient successfully underwent surgical resection of the mass while on VV-ECMO. His symptoms resolved quickly and is now back to his baseline quality of life.

1. Introduction

Extracorporeal membrane oxygenation (ECMO), also known as extracorporeal life support (ECLS) is a form of prolonged cardiopulmonary bypass that has extensively been used in critically ill patients in an intensive care setting. Its use has increased dramatically, with nearly 10,000 cases in 2017, compared to < 5000 before 2012 [1]. Its applications are diverse and largely for supportive measures only, typically in the context of severe acute respiratory distress syndrome (ARDS) [2]. However, ECMO by veno-venous route (VV-ECMO) and veno-arterial route (VA-ECMO) have also been extensively described as a perioperative rescue or replacement of endotracheal intubation in the setting of extrinsic airway compression due to a mediastinal mass [3–5]. In this paper, we will outline the utility of ECMO in the context of extrinsic airway compression. We present an illustrative case to examine how ECMO can be useful during severe airway obstruction when endotracheal intubation poses a significant risk of intraoperative airway compromise in this setting.

2. Case report

A 72-year-old man with a history of hypothyroidism on replacement was transferred to our hospital due to concern for impending airway compromise in the setting of a large mediastinal mass. He began to develop 2 days of evolving shortness of breath on exertion with

worsening hoarseness of his voice. His physical exam was only notable for a hoarse voice. A computed tomography (CT) scan of the chest with contrast revealed a large, complex, diffusely hypodense, partially calcified mass of size 9.3 × 9.5 × 7.7 cm in the mediastinum that appeared to originate from the left thyroid lobe. It significantly narrowed the trachea to a maximum diameter of roughly 2 mm and displaced it toward the right (Figs. 1 and 2). Despite the luminal airway compromise, he was normoxicemic and hemodynamically stable. In the weeks that followed, multiple multidisciplinary discussions took place between pulmonary, critical care, and cardiothoracic surgery consultants regarding the safest operative approach to this case.

Nasal bronchoscopy demonstrated difficulty in reaching the distal trachea due to extrinsic obstruction. It was deemed too narrow to pursue standard sedation regimens with endotracheal intubation. Rigid bronchoscopy with ECMO on standby was considered but was also deemed too risky with the dramatically narrow caliber of his airway. Further multidisciplinary discussion yielded a decision to use VV-ECMO to maintain gas exchange during surgery.

Under general anesthesia, the patient was subsequently cannulated for VV-ECMO using (19 and 21 Fr) femoral venous cannulas with the Cardiohelp ECMO system. The mass was then removed surgically via median sternotomy. After surgery, an endotracheal tube was safely placed, the patient was weaned off VV-ECMO, and was extubated the following day. He tolerated the surgery well. Pathology revealed that this presumed goiter was a follicular adenoma. One week after surgery,

* Corresponding author. New York Presbyterian Queens in Flushing, NY, United States.

** Corresponding author. Mayo Clinic, Department of Pulmonary and Critical Care Medicine, 5777 East Mayo Blvd, Phoenix, AZ, 85054, United States.

E-mail addresses: har9042@nyp.org (H.A. Raza), lyng.philip@mayo.edu (P.J. Lyng).

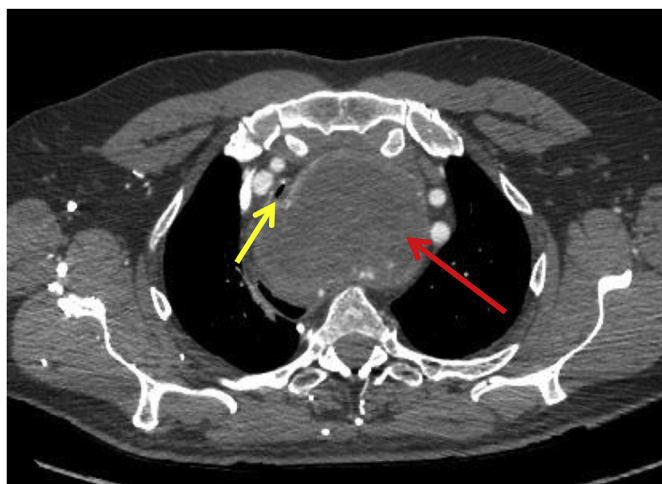


Fig. 1. Axial view: Large mass within the mediastinum (red arrow) arising from the left lobe of the thyroid, displacing and severely narrowing the trachea (yellow arrow). (For interpretation of the references to colour in this figure legend, the reader is referred to the Web version of this article.)

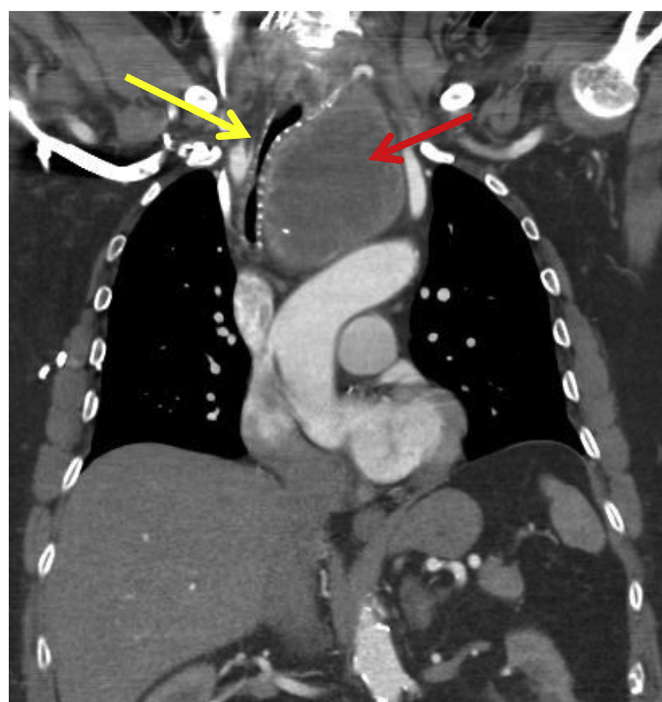


Fig. 2. Coronal view: Large mass within the mediastinum (red arrow) arising from the left lobe of the thyroid, displacing and severely narrowing the trachea (yellow arrow). (For interpretation of the references to colour in this figure legend, the reader is referred to the Web version of this article.)

the patient was discharged from the hospital and has been doing well from a symptomatic standpoint. He is now back to his baseline quality of life, though his hoarseness persists due to recurrent laryngeal nerve

dysfunction.

3. Discussion

As demonstrated by this case, ECMO can be used as a support for gas-exchange intraoperatively when it is deemed too risky to pursue endotracheal intubation. The successful use of ECMO in this setting is widely apparent in the pediatric population, but less so in the adult population, so we feel our case can help to bring attention to a plausible alternative to intubation in such a clinical scenario. In our patient, we successfully used VV-ECMO as replacement with no post-operative complications, and stable findings from a symptomatic standpoint thereafter.

Shao et al., proposed that ECMO brings several advantages over traditional cardiopulmonary bypass which include: allowing a longer duration of use, less heparin use and subsequent bleeding, and less red cell damage [7]. Bechard et al. described the high risk of perioperative life-threatening respiratory complications in patients with significant cardiac and respiratory symptoms at presentation and tracheal compression > 50% [6]. With this in mind, we pursued VV-ECMO as an alternative to endotracheal intubation with sedation.

VA-ECMO, as used by Shao et al., provides both cardiac and pulmonary support and is largely indicated in severe cardiogenic shock, defined by decreased cardiac output and myocardial contractility resulting in tissue hypoperfusion [7,10]. Although use of ECMO in our patient's setting is not part of the list of ECMO indications, it has still been repeatedly demonstrated as a viable option to minimize perioperative respiratory complications due to obstruction of the airway. As our patient showed no evidence of impending cardiac failure, and required largely only pulmonary support, VV-ECMO was chosen over VA-ECMO.

A review of the literature regarding the use of ECMO in other patients used as a replacement for endotracheal intubation when there are concerns of significant extrinsic airway compression from mediastinal masses is warranted [3–8]. The mediastinal masses in these cases were of varying etiologies, including: goiter, plasmacytoma, seminoma, lymphoma, and in our patient, follicular adenoma (Table 1) [3–6]. Shao et al., described severe rheumatoid arthritis as a major influencing factor into their decision to pursue ECMO over endotracheal intubation [7]. This is in addition to the risk of airway compromise from airway compression that was already present from the patient's goiter. It is also interesting to note that Nokes et al., had used ECMO for bronchial stenting rather than for surgery [3]. This was a palliative intervention in a patient with metastatic multiple myeloma. This diverse use of ECMO as a bypass in such settings is truly remarkable, and perhaps there are more scenarios in which ECMO can be used in a similar fashion which have yet to be demonstrated. We strongly believe more clinicians should be aware of this alternative treatment option in the setting of extrinsic airway compression. Given the clinical rarity of this kind of condition, we hope that this case will contribute greatly to the current literature.

Conflicts of interest

None of the authors have any conflicts of interest to disclose.

Table 1

Use of ECMO as a bridge to various procedures/surgeries in the setting of a variety of tumors with mediastinal involvement.

	Tumor type	ECMO type	Surgery/Procedure	Comorbidities	Complication Rates
Shao et al. [7]	Multinodular goiter	VA-ECMO	Subtotal thyroidectomy	Severe rheumatoid arthritis	None reported
Nokes et al. [3]	Plasmacytoma	VV-ECMO	Endobronchial stent placement	Multiple myeloma	None reported
Worku et al. [5]	Diffuse B-cell lymphoma	VA-ECMO	Induction chemotherapy	Crohn's disease	None reported
Lueck et al. [4]	T-lymphoblastic lymphoma	VV-ECMO	Induction chemotherapy	None	None reported

Financial disclosures

None.

Appendix A. Supplementary data

Supplementary data to this article can be found online at <https://doi.org/10.1016/j.rmcr.2019.100890>.

References

- [1] ELSO Registry statistics, <https://www.else.org/Registry/Statistics.aspx>, (2018).
- [2] Medicine SfCC. ECMO Indications and Outcomes.
- [3] B.T. Nokes, L. Vaszar, J. Jahanyar, K.L. Swanson, VV-ECMO-Assisted high-risk endobronchial stenting as rescue for asphyxiating mediastinal mass, *J Bronchology Interv Pulmonol* 25 (2) (APR 2018) 144–147.
- [4] C. Lueck, C. Kuehn, M.M. Hoeper, A. Ganser, M. Eder, G. Beutel, Successful use of extracorporeal membrane oxygenation during induction chemotherapy in a patient with mediastinal tumor mass of a T lymphoblastic lymphoma, *Ann. Hematol.* 95 (2016) 1719–1721.
- [5] B. Worku, W. DeBois, I. Sobol, I. Gulkarov, E.M. Horn, A. Salemi, Extracorporeal membrane oxygenation as a bridge through chemotherapy in B-cell lymphoma, *J Extra Corpor Technol* 47 (2015) 52.
- [6] P. Bechard, L. Letourneau, Y. Lacasse, D. Cote, J.S. Bussieres, Perioperative cardiorespiratory complications in adults with mediastinal mass: incidence and risk factors, *Anesthesiology* 100 (2004) 826–834 discussion 5A.
- [7] Y. Shao, M. Shen, Z. Ding, Y. Liang, S. Zhang, Extracorporeal membrane oxygenation-assisted resection of goiter causing severe extrinsic airway compression, *Ann. Thorac. Surg.* 88 (2009) 659–661.
- [8] S. Takeda, S. Miyoshi, K. Omori, M. Okumura, H. Matsuda, Surgical rescue for life-threatening hypoxemia caused by a mediastinal tumor, *Ann. Thorac. Surg.* 68 (1999) 2324–2326.
- [10] D. Abrams, A. Combes, D. Brodie, et al., Extracorporeal membrane oxygenation in cardiopulmonary disease in adults, *J. Am. Coll. Cardiol.* 63 (2014) 2769–2778.