

CASE REPORT

doi: 10.5455/medarch.2019.73.123-125

MED ARCH. 2019 APR; 73(2): 123-125

RECEIVED: FEB 12, 2019 | ACCEPTED: APR 01, 2019

¹Eye Clinic, University Clinical Centre Tuzla, Tuzla; Bosnia and Herzegovina²Public Health Care Institution Doboju-Jug, Matuzići, Bosnia and Herzegovina³Health Center Tuzla, Tuzla, Bosnia and Herzegovina

Corresponding author: Amra Nadarevic Vodencarevic. Eye Department. Health Center Tuzla. Albina Herljevic 1, 75000 Tuzla, Bosnia and Herzegovina. Phone: +387 61 720 990. E-mail: amra.vodencarevic@gmail.com. ORCID ID: <http://www.orcid.org/0000-0002-4588-8571> :

Simultaneous Penetrating Keratoplasty, Cataract Removal and Intraocular Lens Implantation in Tuzla, Bosnia and Herzegovina

Vahid Jusufovic¹, Emir Cabric, Amra Nadarevic Vodencarevic³**ABSTRACT**

Introduction: It is known that simultaneous penetrating keratoplasty, cataract removal and intraocular lens implantation are always a big challenge to a surgeon, especially in developing countries such as Bosnia and Herzegovina. In these cases there is always a higher rate of different kind of intraoperative complications. Phacoemulsification after penetrating keratoplasty especially in older people may cause significant endothelial injury and also could affect long term graft survival. **Aim:** The aim of this report is to describe one of these challenging cases and the possible ways to manage them in developing countries. **Case report:** In this paper we report a case of a 46 year-old female patient, with a cataract on her right eye with a central corneal leukoma. She reported that when she was 6 years old, she had an eye injury with corn leaf. At the age of 10 year she reported that she had another injury of the same eye with a glass. She reported that she wasn't seeing quite good after that. Three years ago she had a transplantation of amniotic membrane due ulcer on the same eye. She reported also that even after this procedure she wasn't seeing quite good. Now she was admitted to hospital for a triple surgical procedure. At that moment patient has been ophthalmological examined (visual acuity testing, biomicroscopy, tonometry, ultrasound of both eyes with biometry and ophthalmoscopy). At the day of admission to the hospital on slit lamp we found central corneal leukoma, occlusion of pupil and complicated cataract. Before surgery her Uncorrected distance visual acuity (UDVA) on her left eye was light perception. A combined procedure of penetrating keratoplasty (PKP), open-sky cataract extraction, and intraocular lens (IOL) implantation was planned. Thirty days after surgery her visual acuity was 0,5 without correction. It is concluded that cataract surgery in patients after keratoplasty is more complicated. **Conclusion:** Therefore, these patients should be managed with utmost care and operated by an experienced surgeon.

Keywords: open sky, keratoplasty, phacoemulsification.

1. INTRODUCTION

Corneal pathologies which can include different shape scars and opacities may very often coincide with different grades of cataracts. This is very commune in older population. It is well known that corneal eye diseases are the fourth most common cause of blindness (after cataracts, glaucoma and age-related macular degenerations) and affects more than 10 million people worldwide (1).

Good condition of cornea is crucial to achieve good outcome after cataract extraction with intraocular lens implantation. It is very important to have a good corneal clarity. Many times during our praxis we have seen that the corneal opacity and cataract present together. In such cases, performing only penetrating keratoplasty or only cataract surgery does not

give good visual outcome and in the end we have unsatisfied patient and as well unsatisfied surgeon. Actually corneal pathologies needing keratoplasty are often associated with cataract and therefore combined surgery is very often not only necessary, it is more often mandatory. Triple procedure with penetrating keratoplasty and simultaneous cataract extraction with intra ocular lens (IOL) implantation is usually preferred as single step surgery because theoretically visual rehabilitation is more rapid and patients require less postoperative follow ups (2-5).

Combined surgery including penetrating keratoplasty (PK), cataract extraction, and intraocular lens (IOL) implantation (often termed the triple procedure) is a well-established and effective surgical treatment in such

© 2019 Vahid Jusufovic, Emir Cabric, Amra Nadarevic Vodencarevic

This is an Open Access article distributed under the terms of the Creative Commons Attribution Non-Commercial License (<http://creativecommons.org/licenses/by-nc/4.0/>) which permits unrestricted non-commercial use, distribution, and reproduction in any medium, provided the original work is properly cited.

cases worldwide. In Eye Clinic of University Clinic Center Tuzla, Bosnia and Herzegovina with limited ophthalmic instruments and equipment it is possible to manage this very complicated cases. Since several years it is possible to perform open-sky vitrectomy which allows to surgeon better access for surgical instruments, especially to anterior fundus structures. The technique also improves the visibility of intraocular structures.

2. CASE REPORT

We report a case of a 46 year-old female patient, with a cataract on her right eye with a central corneal leukoma. Patient reported during one of the examination prior to the surgery that when she was 6 years old, patient had an eye injury with corn leaf. At the age of 10 year patient reported that she had another injury of the same eye with a glass. Patient also said that she wasn't seeing quite well after that. Patient reported that she wasn't under any medical therapy or that she was wearing contact lenses or glasses. Three years ago patient had a transplantation of amniotic membrane due ulcer on the same eye in different hospital then ours. Now she was admitted to hospital for a triple surgical procedure.

Ocular examination on admission day to hospital revealed patients best uncorrected distance visual acuity (UDVA) to be light perception on patient RE (right eye) and 1.0 with out any correction LE (left eye). Results on patient slit lamp revealed on the right eye corneal edema with a central leukoma, with a complicated cataract and partial seclusion of pupil and no pathological findings on left eye. Patients pupil size were equals. Patient ocular movements were normal in all gazes. Intraocular pressure (IOP) was also normal. Examination of the left eye was normal. The vitreous was quiet and retinal vessels were of normal caliber. Details on the founds of right eye were impossible to asses due the changes in anterior segment. We performed ultrasound examination and we

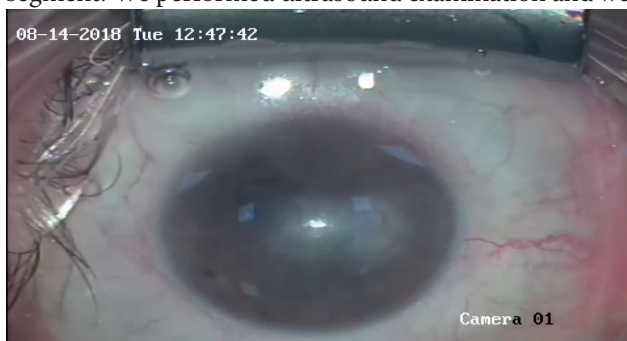

Figure 1. Preoperative anterior segment of the eye

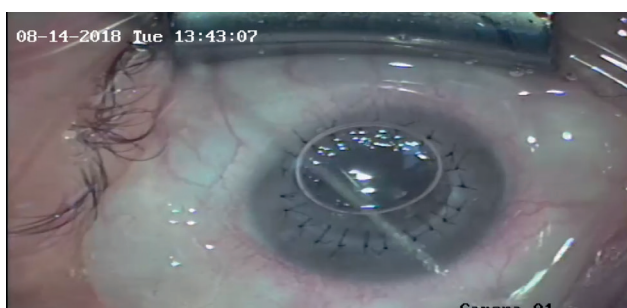


Figure 2. Anterior segment at the end of triple procedure:

performed intraocular lens calculation. Due pathological changes on the right eye we were unable to accurately measure the true corneal power values so we performed intraocular lens calculation for the left eye. Before the surgical procedure patient was treated with Prednisone 80 mg intravenous and as well systematic antibiotics with local corticosteroids and antibiotics (Figure 1). The pupil was dilated preoperatively with tropicamide 1% eye drops. Before surgical procedure a good quality donor cornea was retrieved from a cadaveric transplantation.

After informed consent was obtained, operation was performed in general anesthesia. After excision of the opaque recipient cornea, a cataract was seen. Before the staining of anterior capsule, surgeon performed excision of pupillary membrane and synechiolysis. The anterior capsule was initially stained with VisionBlue (Dutch Ophthalmic, USA). Cataract extraction with IOL implantation (open sky) was performed under operating microscopes Operative Microscope OPMI Visu 150 Carl Zeiss Meditec Inc, Dublin, using Alcon Infiniti® Vision System Fort Worth Texas USA, sodium hyaluronate (Provisc® Alcon) as viscoelastic and surgical instruments Alcon and Geuder AG Heidelberg Germany. After placing four cardinal sutures, the donor button was fixed to the recipient using separate 10/0 nylon sutures. (Figure 2). Follow-up examinations were performed on days 1, 3, 7, and 30 days. Thirty days after surgery her UDVA was 0,5. The patients received topical antibiotic and corticosteroids. Postoperatively, if keratometric astigmatism exceeded 4.0 D, tension of the running sutures was adjusted after 1 to 2 months, and selective removal of separate sutures began after 2 months. Currently patients visual acuity is 0.6 without correction.

3. CONCLUSION

It is very important to remember that triple procedure in ophthalmology can have different meanings. Most ophthalmologist refer triple procedure to be combined penetrating keratoplasty, cataract extraction, and intraocular lens implantation. But sometimes it refers to other ophthalmic surgical combinations. In our case we refer to triple procedure the combined simultaneous penetrating keratoplasty (PK), cataract removal and intraocular lens implantation. The greatest advantage of the this triple procedure is that it can obviate the expense and inconvenience of a second procedure, which is of great benefit for the older patients. Also one main advantage of the triple procedure is the faster visual rehabilitation. After triple procedure, one of disadvantage some postoperative refractive error may be a problem and provide visual limitations after PKP. In very high percentage of cases we have seen high-degree astigmatism and anisometropia (6, 7). In young accommodative patients, these residual refractive errors may be corrected using spectacles, contact lens or even different surgical options (8-15). Also it is very important and essential to accurately predict IOL power, to perform reliable keratometry readings, anterior chamber depth and axial length measurements. In contrast to cataract surgery alone, all of these parameters may alter following the triple procedure, increasing the

risk of unanticipated refractive errors (16). In our opinion triple procedure including cataract extraction via open sky in general anesthesia is the method of choice for combined lens and corneal opacities (17):

- **Author's contribution:** All authors were included in all phases of preparation this case report. Final proof reading was made by the first author.
- **Conflict of interest:** None declared.
- **Financial support:** No specific funding was received for this study.

REFERENCES

1. Wachler BB. Cornea Transplants: What to Expect. Allaboutvision.com website. <http://www.allaboutvision.com/conditions/cornea-transplant.htm>. Accessed: October 25, 2018.
2. Muraine M. Keratoplasty combined with cataract surgery. *J Fr Ophthalmol*. 2012; 35(7): 546-554.
3. Busin M, Arffa RC, McDonald MB, Kaufman HE. Combined penetrating keratoplasty, extracapsular cataract extraction, and posterior chamber intraocular lens implantation. *Ophthalmic Surg*. 1987; 18: 2.
4. Davis EA, Azar DT, Jakobs FM, Stark WJ. Refractive and keratometric results after the triple procedure: experience with early and late suture removal. *Ophthalmology*. 1998; 105: 624-630.
5. Hamill MB. Sequential surgery may be the best approach for the patient. *Arch Ophthalmol*. 2000; 118(3): 415-417.
6. Assil KK, Zarnegar SR, Schanzlin DJ. Visual outcome after penetrating keratoplasty with double continuous or combined interrupted and continuous suture wound closure. *Am J Ophthalmol*. 1992; 114(1): 63-71.
7. Lockington D, Wang EF, Patel DV, Moore SP, McGhee CN. Effectiveness of cataract phacoemulsification with toric intraocular lenses in addressing astigmatism after keratoplasty. *J Cataract Refract Surg*. 2014; 40(12): 2044-2049.
8. Donnenfeld ED, Kornstein HS, Amin A, et al. Laser in situ keratomileusis for correction of myopia and astigmatism after penetrating keratoplasty. *Ophthalmology*. 1999; 106: 1966-1974.
9. Forseto AS, Francesconi CM, Nosé RAM, Nosé W. Laser in situ keratomileusis to correct refractive errors after keratoplasty. *J Cataract Refract Surg*. 1999; 25: 479-485.
10. Kwito S, Marinho DR, Rymer S, Ramos S. Laser in situ keratomileusis after penetrating keratoplasty. *J Cataract Refract Surg*. 2001; 27: 374-379.
11. Malecha MA, Holland EJ. Correction of myopia and astigmatism after penetrating keratoplasty with laser in situ keratomileusis. *Cornea*. 2002; 21: 564-569.
12. Buzard K, Febbraro JL, Fundingsland DR. Laser in situ keratomileusis for the correction of residual ametropia after penetrating keratoplasty. *J Cataract Refract Surg*. 2004; 30: 1006-1013.
13. Gayton JL. Secondary implantation of a double intraocular lens after penetrating keratoplasty. *J Cataract Refract Surg*. 1998; 24: 281-282.
14. Paul RA, Chew HF, Singal N, Rootman DS, Slomovic AR. Piggyback intraocular lens implantation to correct myopic pseudophakic refractive error after penetrating keratoplasty. *J Cataract Refract Surg*. 2004; 30: 821-825.
15. Moshirfar M, Barsam CA, Parker JW. Implantation of an Artisan phakic intraocular lens for the correction of high myopia after penetrating keratoplasty. *J Cataract Refract Surg*. 2004; 30: 1578-1581.
16. Javadi MA, et al. Simultaneous penetrating keratoplasty and cataract surgery. *J Ophthalmic Vis Res*. 2013; 8: 3946.
17. Seitz B, Langenbacher A, et al. Cataract and keratoplasty-simultaneous or sequential surgery? *Klin Monbl Augenheilkd*. 2003 May; 220(5): 326-329.