



## Case report

## 21-year-old silicone breast implants causing recurrent pneumonia, chest pain and coughing

Nina Järvelä Johansen<sup>a,\*</sup>, Ole Hilberg<sup>b</sup>, Anders Løkke<sup>b</sup><sup>a</sup> Department of Internal Medicine, Horsens Regional Hospital, Sundvej 30, 8700, Horsens, Denmark<sup>b</sup> Department of Medicine, Vejle Sygehus, Hospital Little Belt, Beriderbakken 4, 7100, Vejle, Denmark

## ARTICLE INFO

## Keywords:

Breast implants  
 Recurrent pneumonia  
 Smoking  
 Atypical chest pain

## ABSTRACT

A 50-year-old former smoker presented with recurrent pneumonia, fever and atypical chest pain on and off for a year and was treated with antibiotics several times. Meanwhile, her lung function deteriorated with an obstructive pattern and therefore she was treated with inhalation medication without effect. Tests of the heart, bronchoscopy, gastroscopy and a CT-scan of the lungs did not reveal the cause. Finally, an FDG-PET scan showed inflammation of the tissue on the backside of a 21-year-old silicone chest implant, which was intact but encapsulated. The chest implants were removed after which the patient has remained free of infections. However, the lung function impairment did not improve, and a new HRCT-scan demonstrated widespread emphysema.

## 1. Introduction

Persistent cough, atypical chest pain and recurring fever in an ex-smoker are common symptoms and all point towards pathology in the lungs. When malignancy is ruled out and no other obvious diagnoses can be made, it is time for the art of performing medicine.

Silicone breast implants have been used since the 1960s for cosmetic as well as reconstructive breast augmentations. However, tissue exposed to silicone can react and cause multiple adverse events. The complication rate is varying. Some of the most common complications are fibrous capsule contracture, implant rupture, silicone migration and neurologic problems [1]. Breast implants may cause inflammation of the surrounding tissue, which can result in different symptoms. Therefore, implants and other foreign bodies should be considered as the causative agent, if the diagnosis is unclear.

## 1.1. Case report

In September 2015, a 50-year-old woman with recurrent pneumonia, fever, dyspnea, left-sided chest pain and dry cough - on and off for a year - was referred for a second opinion at a specialized Department within Respiratory Medicine in Denmark. The patient had a history of extensive smoking in her younger years but had not smoked for 30 years and had no history of neither asthma nor COPD. 21 years prior to the clinical

presentation she had silicone breast implants for cosmetic purposes and had had no noticeable complications over the years.

The year prior to referral she had recurrent episodes of infection in the lungs and was hospitalized and treated with antibiotics for pneumonia several times. During one of these hospitalizations, she was diagnosed with - and treated for - atrial flutter without effect on the symptoms.

Preliminary investigations included an X-ray of the lungs displaying a high diaphragm on the left side. A CT-scan of the lungs ruled out both lung embolism and malignancy. The patient experienced dyspnea and a lung function test demonstrated obstructively impaired lung function (FEV<sub>1</sub>/FVC 64%, FEV<sub>1</sub> 51%). Approximately one year later the lung function deteriorated even further (FEV<sub>1</sub>/FVC 47%, FEV<sub>1</sub> 40%) which can explain the dyspnea and cough, but not the recurrent infections. However, treatment with inhalation medication had no effect. Immunodeficiency disorders and allergies were ruled out. ECG, coronary enzymes, heart CT-scan as well as echocardiography, both transthoracic and transesophageal, were all normal. Bronchoscopy with bronchoalveolar lavage was normal except for some brownish mucus that gave rise to suspicion of reflux. Gastroscopy was normal, and reflux was ruled out.

Finally, a PET-CT scan revealed increased FDG-absorption on the backside of the left breast implant as well as various enlarged lymph nodes in the circumference. Plastic surgeons removed both breast

\* Corresponding author. Sundvej 30, 8700 Horsens, Denmark.

E-mail address: [n.johansen.md@gmail.com](mailto:n.johansen.md@gmail.com) (N.J. Johansen).

<https://doi.org/10.1016/j.rmcr.2020.101025>

Received 11 January 2020; Received in revised form 8 February 2020; Accepted 8 February 2020

Available online 9 February 2020

2213-0071/© 2020 The Authors.

Published by Elsevier Ltd.

This is an open access article under the CC BY-NC-ND license

(<http://creativecommons.org/licenses/by-nc-nd/4.0/>).

implants. They were both intact but encapsulated and adherent to the underlying tissue. The surgeons were unable to remove all the capsule and had to leave some of it. Pathology tests of the implants showed capsule tissue and soft tissue with moderate mononuclear inflammatory infiltrations. No granulomas or proliferative tissue was found.

After the removal of the breast implants the infections, which was the patient's main problem, stopped, and the chest pain and cough disappeared. The dyspnea and the obstructively impaired lung function, however, did not improve (see Figs. 1 and 2).

## 2. Discussion

Chronic cough, atypical chest pain and recurrent pneumonia in an ex-smoker should always lead to an exploration of the most common causes, such as infection, asthma, COPD, malignancy or gastroesophageal reflux [2].

Pneumonia is a very common condition. A hospitalization for pneumonia can weaken a patient significantly and is associated with both increased mortality and morbidity, especially in elderly people.

Little information on the modifiable factors that are related to recurrent pneumonia is available. An older study found that chronic pulmonary disease together with age were the most important predisposing conditions in these circumstances [3]. A later review suggested that low functional abilities, treatment with acid suppressing drugs (PPI) and inhaled corticosteroids (ICS) may play a predisposing role [4]. Our patient debuted with chronic cough and recurrent pneumonia and was checked for all the above-mentioned conditions without establishing a diagnosis. She was not diagnosed with COPD, nor was she treated with PPI or ICS. Therefore, we had to think alternatively.

It is well known that tissue exposed to silicone can react with multiple adverse events. In 1987, Kossovsky et al. made two studies regarding the bioreactivity of silicone and demonstrated that the physical presence of silicone can induce an immunological mediated chronic inflammation process in human tissue, leading to i.e. fibrous tissue encapsulation and contraction [5,6]. Even though many women experience various complications with breast implants, few previous studies have shown a causality between silicone implants and severe health problems in the lungs, and silicone implants are still mostly considered safe to use [7]. However, several new publications report of silicone breast implant (SBI) related complications and one case-control study found that breast implants are associated with an age-related increased risk of developing anaplastic large-cell lymphoma in the breast (breast-ALCL) [8]. A few of the patients displayed some, but not all, of the same symptoms as our patient.

A review from 2015 investigated how silicone is linked to the autoimmune/inflammatory syndrome induced by adjuvants (ASIA). They

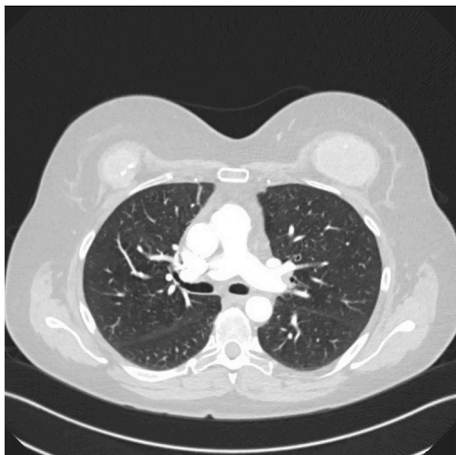


Fig. 1. CT scan of lungs before removal of silicone breast implants.

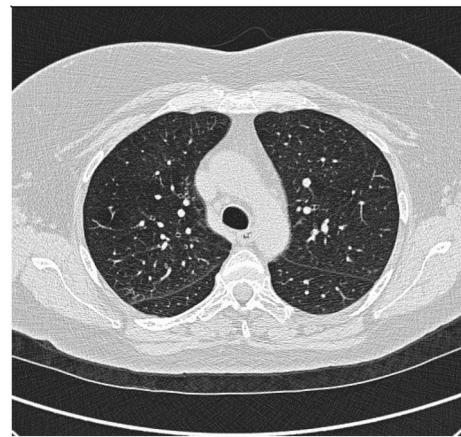


Fig. 2. CT scan of lungs after removal of silicone breast implants.

concluded, that evidence of this link is accumulating and described silicone's ability to directly mediate cellular immune response and thereby cause inflammation and autoimmune diseases. Further they suggested that some patients might have a genetic predisposition for developing autoimmunity, and silicone might be the "missing link" as an environmental trigger [9].

Nesher et al. presented 4 female cases developing systemic symptoms following rupture of silicone implants with thoracic and lymph node infiltrations. They displayed different systemic symptoms including musculoskeletal pain, extreme fatigue, headache, dyspnea, dry cough, mild fever, polyarthralgia and in one case mild diffusion abnormalities in the lungs. All 4 had ruptured implants, 3 had confirmed silicone granulomas in lymph nodes and most had improvement in symptoms upon implant removal. All women met the criteria of ASIA. Nesher et al. also suggest that the chronic stimulation of the immune system may lead to formation of autoantibodies, autoreactive cells and continuous secretion of cytokines and hence to the development of ASIA. They conclude, that although likely a cause-and-effect cannot be ascertained [10].

Two other women had symptoms more similar to those of our patient. A 55-year-old woman developed irritative cough, low-grade fever, pleuritic chest pain and dyspnea due to subacute silicone pneumonitis after rupture of her breast implants [11]. Another woman developed thrombocytosis and bilateral pulmonary infiltrates and was diagnosed with subacute silicone-induced pneumonitis after rupture of the breast implants [12]. In both cases, the women's symptoms disappeared after removal of their breast implants, just like in our patient. These six cases suggest, that systemic symptoms as well as infection in the lungs can be due to inflammation caused by silicone implants. However, in contrast to our patient all 6 patient's implants were ruptured whereas our patient had intact, encapsulated implants and still developed severe symptoms.

A cross-sectional study from 2018 processed data from a big Israeli database regarding silicone implants and the risk of autoimmune/rheumatic disorders. They found significant associations and increased risk between silicone implants and Sjögrens syndrome, systemic sclerosis and sarcoidosis. They did not specify if the women had ruptured breast implants or not, but they stated that silicone can migrate outside the outer shell of an implant both after rupture and through an intact shell – the so-called "gel-bleed". Further they supported the theory of silicone causing dysregulation of the innate and adaptive immune system in those genetically predisposed for autoimmunity [13].

A case report supporting the theory of "gel-bleed" involved a 57-year-old woman with a unilateral left sided silicone implant, who initially experienced tightness of the left breast and later developed arthralgia, fatigue, dry cough and dyspnea. A chest X-ray showed multiple nodular infiltrations and sarcoidosis was suspected. However, sarcoidosis was ruled out and it was concluded that the inflammation

was caused by an autoimmune response secondary to the silicone implant. The implants were intact and were removed in total and the symptoms including dyspnea disappeared [7].

A critical review from 2017 assessed the results of removing silicone breast implants in patients with suspicion of silicone complaints such as arthralgia, myalgia and fatigue and/or autoimmune diseases. They found that removal improved complaints in 75% of patients but did not influence the autoantibody testing, and in patients with autoimmune diseases the improvement was seen in only 16% of the patient without and in 56% with additional immunosuppressive therapy, which indicate that removal alone was not sufficient as an effective resolution of the autoimmunity. They suggested, that prior to removal silicone particles might have migrated to lymph nodes, periprosthetic and other tissue and remained present [14].

Our patient had silicone breast implants with an unproblematic post period of 21 years. After debut of her symptoms, a PET-scan revealed localized inflammation on the backside of the left implant. When the breast implants were removed, the recurrent pneumonia and cough subsided and we drew the conclusion, that inflammation caused by the implants were the reason for these symptoms. This theory is supported by the presented literature, where there is growing evidence that silicone particles, both from ruptured implants and through intact capsule, can migrate to periprosthetic tissue and induce both local and systemic activation of the immune system, thus causing SBI-related complaints. Removal of the implants in our patient cured the recurrent pneumonia, chronic cough and atypical chest pain. The impaired lung function and emphysema, however, did not improve. The theory proposed by de Boer et al., that silicone particles migrate to periprosthetic tissue causing continued activation of the immune system may explain this to some extent [14], but the patients' previous smoking cannot be completely ruled out as a cause of the impaired lung function. It is conspicuous, though, that the decrease in lung function accelerated during the same timespan as the other symptoms appeared and then stagnated after removal of the breast implants.

### 3. Conclusions

Several systemic symptoms, autoimmunity and increased risk of breast-ALCL are all very serious advert events to silicone implants. We present in this case report new symptoms caused by silicone implants: recurrent pneumonia, atypical chest pain and cough. Permanent damage to lung tissue and thus development and/or acceleration of emphysema and permanent decreased lung function may be due to the same inflammation. Permanent damage to the lungs is another possible, yet very serious complication to silicone implants and it is therefore worth

considering if women contemplating getting silicone implant should be informed about this before an operation.

In conclusion, recurrent pneumonia, chronic cough and atypical chest pain are symptoms that should be taken seriously and may have various causes. If the obvious diagnoses are ruled out, and the patient has silicone implants – ruptured or intact - they may be causing chronic inflammation and should always be investigated.

### Funding

This research did not receive any specific grant from funding agencies in the public, commercial, or not-for-profit sectors.

### Declaration of competing interest

None.

### References

- [1] L.B. Lu, et al., Atypical chest pain syndrome in patients with breast implants, *South. Med. J.* 87 (1994) 978–984.
- [2] Jaclyn A. Smith, et al., Chronic cough, *N. Engl. J. Med.* 375 (2016) 1544–1551.
- [3] J. Hedlund, et al., Recurrence of pneumonia in middle-aged and elderly adults after hospital-treated pneumonia. Aetiology and predisposing conditions, *Scand. J. Infect. Dis.* 29 (1997) 387–392.
- [4] T. Dang, et al., Recurrent pneumonia: a review with focus on clinical epidemiology and modifiable risk factors in elderly people, *Drugs Aging* 32 (2015) 13–19.
- [5] N. Kossovsky, et al., The Bioreactivity of silicone, *CRC Crit. Rev. Biochem.* 3 (1987) 53–83.
- [6] N. Kossovsky, et al., Experimental demonstration of the immunogenicity of silicone-protein complexes, *J. Biomed. Mater. Res.* 21 (1987) 1125–1133.
- [7] J. Schierbeck, et al., Silicone implant incompatibility syndrome (SIIS) in a 57-year-old woman with unilateral silicone breast implant, *BMJ Case Rep.* (2017), <https://doi.org/10.1136/bcr-2016-218709>.
- [8] M. De Boer, et al., Breast implants and the risk of anaplastic large-cell lymphoma of the breast, *JAMA Oncol* 1 (4(3)) (Mar 2018) 335–341, <https://doi.org/10.1001/jamaoncol.2017.4510>. Online.
- [9] I. Goren, et al., Autoimmune/inflammatory syndrome induced by adjuvant (ASIA) evolution after silicone implants. Who is at risk? *Clin. Rheumatol.* 34 (2015) 1661–1666.
- [10] G. Neshet, et al., Severe ASIA syndrome associated with lymph node, thoracic, and pulmonary silicone infiltration following breast implant rupture: experience with four cases, *Lupus* 24 (2015) 463–468.
- [11] M.J.G. Hernandez, et al., Neumonitis subaguda por silicona tras la rotura silente de un implante mamario, *Arch. Bronconeumol.* 52 (2016) 397–398.
- [12] S.P. Vila, et al., Pneumonitis caused by silicone gel following breast implant rupture, *Ir. J. Med. Sci.* 179 (2010) 141–145.
- [13] A. Watad, et al., Silicone breast implants and the risk of autoimmune/rheumatic disorders: a real-world analysis, *Int. J. Epidemiol.* (2018) 1846–1854.
- [14] M. De Boer, et al., Is explantation of silicone breast implants useful in patients with complaints? *Immunol. Res.* 65 (2017) 25–36.