



The influence of glenoid component position on scapular notching: a detailed radiographic analysis at midterm follow-up



Nicholas C. Duethman, MD, William R. Aibinder, MD, Ngoc Tram V. Nguyen, BA, Joaquin Sanchez-Sotelo, MD, PhD*

Department of Orthopedic Surgery, Mayo Clinic, Rochester, MN, USA

ARTICLE INFO

Keywords:

Glenoid baseplate position
scapular notching
reverse shoulder arthroplasty
baseplate position
sphere bone overhang distance
glenohumeral arthritis

Level of evidence: Level IV; Case Series;
Treatment Study

Background: Glenoid baseplate and glenosphere positioning may affect scapular notching rates. The purpose of this study was to assess various radiographic parameters and correlate them with scapular notching after primary reverse total shoulder arthroplasty (RTSA) at a minimum follow-up time of 5 years.

Methods: The study sample included 147 primary RTSA with good-quality postoperative radiographs at least 5 years after implantation (mean follow-up 6.1 years, range 5–12 years). The center of rotation (COR) of the glenosphere in reference to the bone-baseplate interface was medialized in 71 and lateralized in 76 shoulders, with a varus polyethylene opening angle in 134 shoulders. Preoperative and immediate postoperative radiographs were measured to determine (1) glenoid baseplate inclination: α , β , and the reverse shoulder arthroplasty (RSA) angles; (2) glenoid component inferiorization—peg glenoid rim distance (PGRD); and (3) sphere bone overhang distance (SBOD). Scapular notching was graded according to the Sirveaux classification.

Results: Scapular notching was noted in 98 shoulders (67%) and classified as grade 1 in 46, grade 2 in 25, grade 3 in 20, and grade 4 in 7. There were statistically significant associations between notching and both medialized glenospheres (91% vs. 45%, $P = .001$) and varus polyethylene angle ($P = .0001$). The mean postoperative RSA angle, PGRD, and SBOD were 6.6 degrees, 23.8 mm, and +2.6 mm, respectively. Preoperative α and postoperative β , RSA, PGRD, and SBOD were all associated with notching ($P < .05$). The rate of reoperation was 2.7% at a minimum of 5 years, with reasons for reoperation related to component failure in only one shoulder.

Conclusion: Scapular notching correlates with glenoid and baseplate inclination, baseplate inferiorization, inferior glenosphere overhang, glenosphere COR, humeral polyethylene angle, and longer clinical follow-up. SBOD is a clinically useful measurement with decreased values associated with notching. It is the superior measurement in implants with eccentric glenospheres. Moderate or severe notching was seen in only approximately 15% of the shoulders. Revision surgery was extremely low in this cohort, and it was not related to notching or instability.

© 2019 The Author(s). Published by Elsevier Inc. on behalf of American Shoulder and Elbow Surgeons. This is an open access article under the CC BY-NC-ND license (<http://creativecommons.org/licenses/by-nc-nd/4.0/>).

Scapular notching is a progressive radiographic finding that may occur to varying degrees following reverse total shoulder arthroplasty (RTSA). Some studies have demonstrated worse clinical outcomes and higher rates of complications in the setting of scapular notching following RTSA.^{10,12,18–21} However, other clinical studies have failed to demonstrate a significant effect of scapular notching on clinical and functional outcomes following RTSA.^{1,3,5}

This study was approved by the Mayo Institutional Review Board (ID no. 17-004953).

* Corresponding author: Joaquin Sanchez-Sotelo, MD, PhD, Department of Orthopedic Surgery, Mayo Clinic, 200 First Street SW, Rochester, MN 55905, USA.

E-mail address: sanchezsotelo.joaquin@mayo.edu (J. Sanchez-Sotelo).

<https://doi.org/10.1016/j.jses.2019.11.004>

2468-6026/© 2019 The Author(s). Published by Elsevier Inc. on behalf of American Shoulder and Elbow Surgeons. This is an open access article under the CC BY-NC-ND license (<http://creativecommons.org/licenses/by-nc-nd/4.0/>).

Early evidence of scapular notching has been correlated with various factors, including scapular anatomy, implant design, and component position.^{2,17} Notching is believed to occur secondary to contact between the polyethylene liner and bone just inferior and medial to the glenoid component. Bone loss occurs as a result of this direct contact and results in polyethylene wear particles that may lead to additional bone loss and potentially aseptic loosening of the glenoid or humeral component.^{13–16,18–20} Aside from changing prosthetic design, some authors have suggested that surgeons should attempt to inferiorize the glenoid baseplate¹⁹ and avoid superior tilt⁸ to minimize the risk of scapular notching. However, a detailed analysis of the relationship between glenoid component position and notching at midterm follow-up is lacking.

Thus, the purpose of the present study was to define the rate of scapular notching at a minimum follow-up of 5 years and to further evaluate the impact of component design and position on scapular notching. To do so, we performed comprehensive measurements using multiple described techniques and also introduce a novel measurement representing the amount of inferiorization of the glenosphere itself.

Patients and methods

After approval from our Institutional Review Board, we identified all patients who underwent a primary RTSA at our institution between 2005 and 2012. Patients with less than 5-year radiographic follow-up were excluded, as were those shoulders without high-quality pre- and postoperative radiographs. This resulted in a study cohort of 147 shoulders with a mean radiographic follow-up of 6.1 years (range, 5–12.3). The mean age was 72 years (range, 31–90). The mean body mass index was 30.4 (range, 18.6–49.0). Indications for RTSA included cuff tear arthropathy or osteoarthritis in 127, proximal humerus fracture in 17, and humeral head avascular necrosis in 3. A medialized glenoid component was used in 71 shoulders and a lateralized glenoid component was used in 76 shoulders (Table I). For lateralized glenospheres, lateralization was the result of the glenosphere design itself (Encore RSP; DJO Surgical, Austin, TX), or the Morse effect taper of the baseplate-glenosphere junction (Biomet, Zimmer-Biomet, Warsaw, IN). The neck-shaft angle was valgus (greater than 135°) in the majority of the shoulders (n = 134).

Radiographic measures

Preoperative and immediate postoperative radiographs were reviewed to assess glenoid baseplate inclination based on the α ,⁶ β ,¹¹ and reverse shoulder arthroplasty (RSA) angles⁴ and the prosthesis scapular neck angle (PSNA) (Fig. 1).¹⁹ Glenoid baseplate inferiorization was quantified based on the peg glenoid rim distance (PGRD) (Fig. 2)¹⁹ and inferiorization of the glenosphere based on a novel measurement, the sphere bone overhang distance (SBOD) (Figs. 3–5). The latter is measured as the distance from a line at the inferolateral edge of the glenoid drawn parallel to the peg, to a parallel line at the most inferior aspect of the glenosphere. As the baseplate translates superiorly in relation to the inferior scapular neck, the PGRD increases. As the glenosphere translates inferiorly in relation to the scapular neck, the SBOD becomes more positive. For example, an overhang of 0 represents a glenosphere that is flush with the inferior scapular neck. The SBOD was introduced to consider the amount of inferiorization of the glenosphere itself as a consequence of different-size glenospheres and glenospheres with options for eccentric position, which is not considered in the PGRD. Radiographs at final follow-up were evaluated, and the notching was graded based on the Nerot-Sirveaux grading system.⁹

Implants evaluated were 3 with a medialized center of rotation (COR) (Tornier Aequalis [Wright Medical, Bloomington, MN], DePuy Delta XTend [DePuy-Synthes, Warsaw, IN], and DePuy Delta III [DePuy-Synthes]), one implant that has a lateralized COR through

the baseplate-glenosphere junction (Biomet Comprehensive; Zimmer-Biomet), and one with a lateralized COR through the glenosphere (Encore RSP) (Table I). The association between implant design and scapular notching were evaluated, focusing on both COR and prosthesis neck-shaft angle.

Statistical methods

Stepwise linear regression model was calculated for each measurement value derived from preoperative radiographs and most recent radiographs independently; the model with the lowest Akaike information criterion (AIC) was reported. Nominal variables were compared using Fisher exact test. Wilcoxon rank-sum test was used to compare nominal and continuous variables. The median value and inner quartile range is reported for all significant values.

Results

Notching

Inferior scapular notching was noted in 98 shoulders and was grade 1 in 46, grade 2 in 25, grade 3 in 20, and grade 4 in 7.

Inclination and inferiorization

Based on the α and β angles, the mean amount of baseplate inclination was 4.1° inferior tilt \pm 10.4° and 4.6° inferior tilt \pm 9.0°, respectively. Based on the postoperative RSA angle, only 4 (2.7%) shoulders had the glenoid baseplate placed superiorly tilted relative to the focal inclination at the level of the baseplate. Relative to the perpendicular of the supraspinatus fossa, the baseplate was tilted inferiorly in 33 (22.4%) shoulders, yet when global glenoid inclination was used as a reference, the baseplate was tilted inferiorly in 103 (70.0%) shoulders. The mean PGRD was 23.8 mm (range, 15.7–37.2), and the mean SBOD was +2.6 mm (range, –13.0 to +10.3). Table II shows the pre- and postoperative radiographic measurements.

Associations with notching

A simple linear regression was calculated to predict scapular notching based on each of the following measurements: preoperative α angle, preoperative β angle, preoperative scapular neck angle (SNA), preoperative RSA angle, postoperative α angle, postoperative β angle, postoperative RSA angle, PGRD, and SBOD. A significant regression equation was found for preoperative α angle, postoperative α angle, postoperative β angle, PGRD, and SBOD (Table III).

To determine the relation between predictor values, derived from their respective image (pre- or postoperative radiograph), and the rate of notching, 2 stepwise linear regression models were calculated: model 1 predicts notching for preoperative α angle, β angle, SNA, RSA angle, and time to most recent follow-up; model 2 predicts notching for postoperative α angle, β angle, RSA angle, PGRD, SBOD, and time to most recent follow-up. Model 1 indicates

Table I
Implant design

Implant	Number of implants	Eccentric positioning	POA	Glenosphere COR
Tornier Aequalis	12	No	155°	Medialized
DePuy Delta XTend	47	No	155°	Medialized
DePuy Delta III	12	No	155°	Medialized
Biomet Comprehensive	64	Yes	147°	Lateralized
Encore RSP	12	No	135°	Lateralized

POA, polyethylene opening angle; COR, center of rotation.

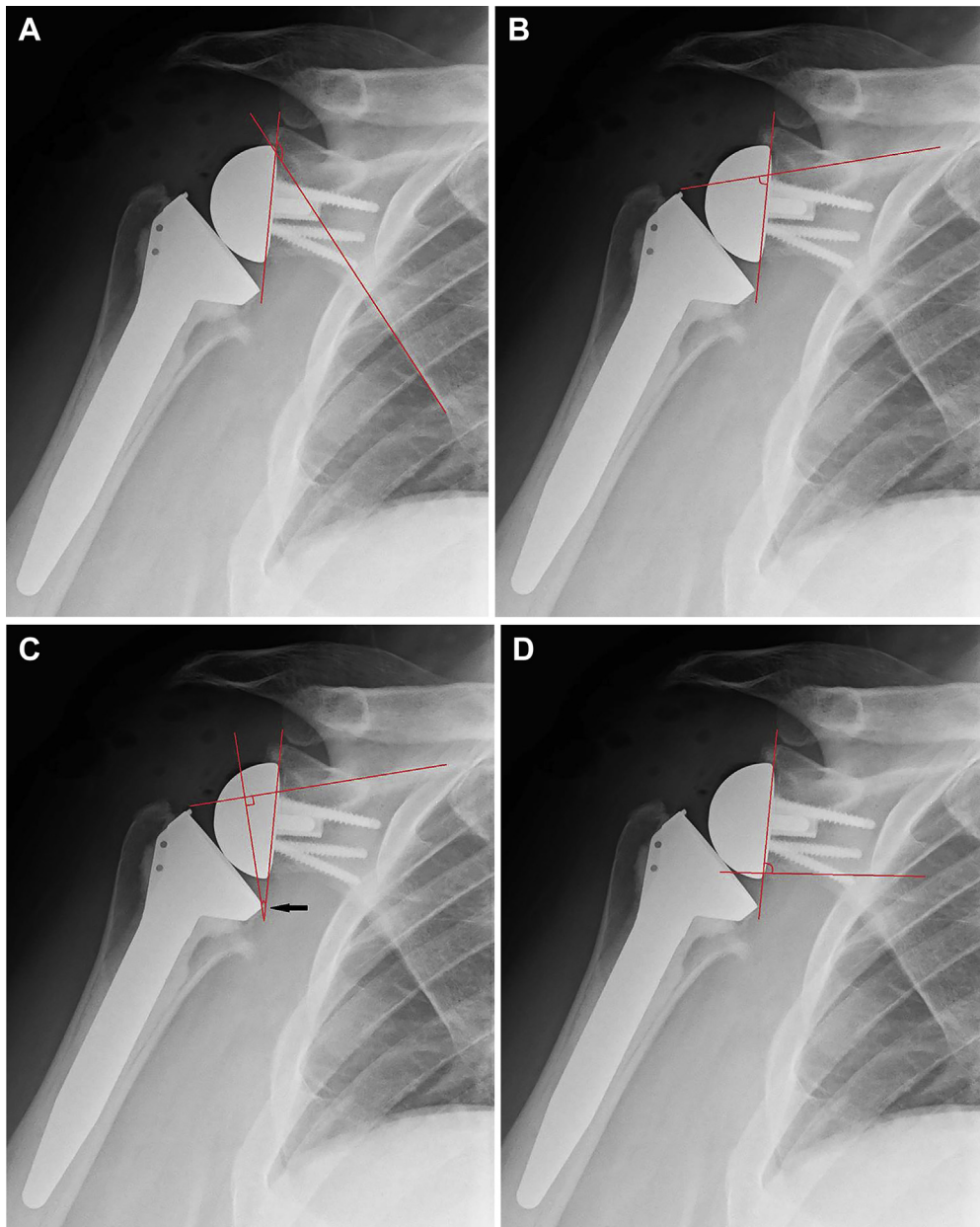


Figure 1 A) The α angle is between a line drawn along the lateral border of the scapula subtending a line drawn along the back of the glenosphere. (B) The β angle is between a line drawn along the supraspinous fossa subtending a line drawn along the back of the glenosphere. (C) The postoperative RSA angle is between a line drawn perpendicular to the floor of the supraspinous fossa subtending a line drawn along the back of the glenosphere. (D) The PSNA is between a line drawn parallel to the inferior scapular neck subtending a line drawn along the back of the glenosphere. \blackleftarrow , The black arrow indicate the site of the angle measurement. RSA, reverse shoulder arthroplasty; PSNA, prosthesis scapular neck angle.

time to follow-up as the only significant predictor of notching (AIC = 468.306; $R^2 = 0.038903$) (Fig. 6). In model 2, postoperative RSA angle, PGRD, and SBOD were significant predictors of notching (AIC = 429.677; $R^2 = 0.2821$); increased RSA angle, decreased PGRD, and decreased SBOD predict greater notching grade (Table IV).

Additionally, a subgroup analysis was conducted to evaluate the predictors of notching for implants with eccentric glenoid sphere position (Biomet). The multivariate stepwise linear regression (AIC = 146.303, $R^2 = 0.251584$) indicates that the only significant postoperative variables associated with notching in eccentric glenoid components were SBOD ($P = .0008$, coefficient = -0.121653) and time to most recent follow-up ($P = .0211$,

coefficient = 0.2575027). PGRD was not significant ($P = .3729$) using univariate analysis in eccentric glenospheres (Biomet).

The rate of scapular notching was also significantly higher in patients with more medialized design (91% vs. 45%) ($P < .0001$). Medialized designed accounts for approximately 50% of grade 2-4 notching (Table V). However, there was no association between medialized components and revision surgery ($P = .695$).

Notching was also significantly higher in patients with a higher polyethylene opening angle (POA) ($P < .0001$) (Table VI). Patients with a POA greater than or equal to 147° accounted for 94% of patients with grade 2 notching or greater. However, there was no

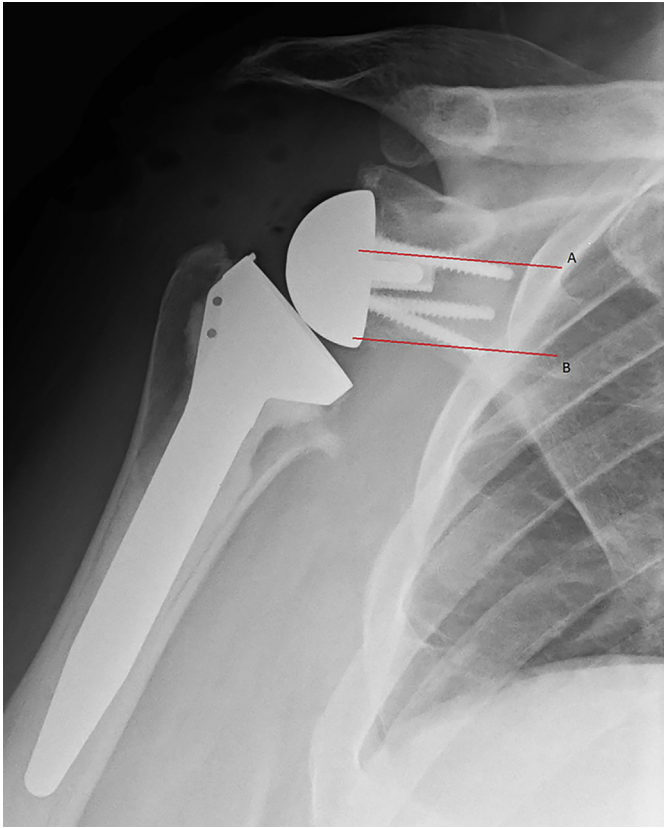


Figure 2 The PGRD is the distance between the superior aspect of the glenoid peg (line A) and the inferior scapular neck (line B). PGRD, peg glenoid rim distance.

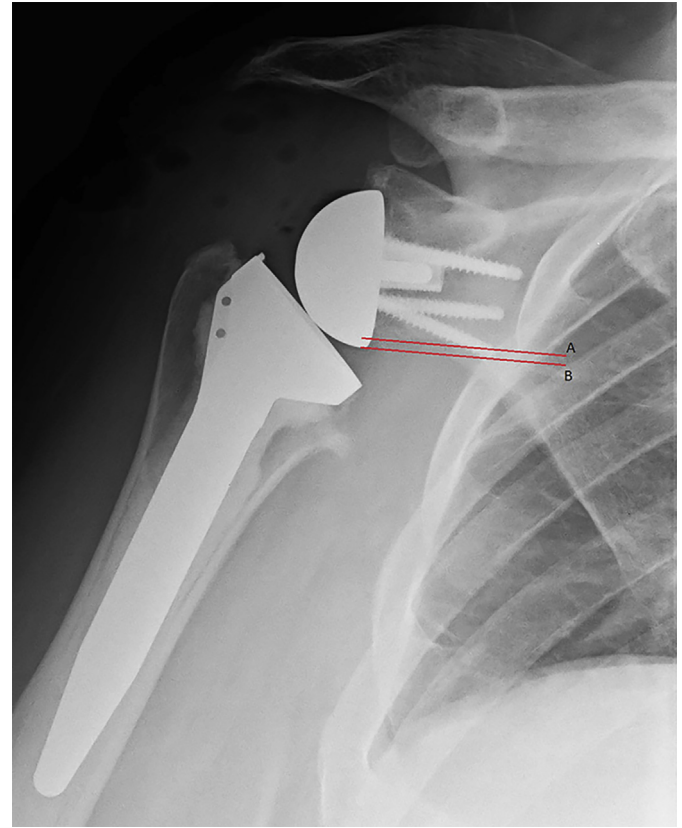


Figure 3 The SBOD is the distance between the inferior scapular neck (line A) and the most inferior aspect of the glenosphere (line B). The Tornier Aequalis implant (medialized center of rotation) is shown. SBOD, sphere bone overhang distance.

statistically significant association between the POA and the rate of revision surgery ($P = .0695$) (Table V).

Revision

Of the 147 shoulders in the study, 4 shoulders underwent revision surgery. One patient received a humeral tray and polyethylene exchange 6 years after primary surgery for an acute *Streptococcus viridians* infection. The patient was treated with 6 weeks of intravenous antibiotics postoperatively followed by chronic oral suppression. Another patient required humeral component revision for a fractured Biomet humeral tray 5.5 years after the index procedure. Two additional patients underwent open reduction and internal fixation for a periprosthetic humeral shaft fracture 4.5 and 6 years after primary RTSA.

Discussion

Scapular notching is a well-known radiographic finding after RSA. Excessive contact between the humeral polyethylene liner and the scapular bone inferior and medial to the glenoid component results in bone loss and polyethylene wear. Resultant osteolysis can potentially aggravate bone loss and may contribute to glenoid or humeral loosening. The results of our study seem to indicate that after a minimum follow-up time of 5 years, two-thirds of the radiographs show evidence of notching to some degree. However, severe notching at 5 years was less common (approximately 15%). Notching rates were influenced by the COR of the glenosphere, the opening angle of the polyethylene liner, as well as the inclination and inferiorization of the glenoid component. Notching rates were also proportional to length of follow-up.

Inclination

Measurements of glenosphere inclination based on plain radiographs include the α , β , postoperative RSA, and prosthesis scapular neck angles. Maurer et al¹¹ report on the variability of the α and β angles based on scapular rotation and interobserver reliability. The β angle showed the least interobserver variation, and the value changed minimally with less than 20° of scapular rotation.

In our cohort, preoperative α angles, postoperative α angles, postoperative β angles, and increased postoperative RSA angles were all associated with notching. Intuitively, as the glenosphere tilts more inferiorly in relation to the suprascapular fossa line (increased RSA) or inferior scapular neck (increased PSNA), the humeral component will more readily impact the inferior aspect of the scapular neck. These measurements do not describe the direct relationship between the inferior aspect of the glenosphere and the scapular neck, which is where notching occurs. Thus, inferiorization, more so than inclination of the baseplate, may be a better indicator of notching.

Inferiorization

The PGRD was developed to describe the amount of glenoid bone stock inferior to the baseplate peg. Simovitch et al¹⁹ described this measurement and combined it with the PSNA, providing intraoperative recommendations for these values. They found that the PGRD was more strongly associated (8 times) with notching compared with the PSNA. The PGRD is useful when the glenosphere abuts the baseplate without adjustability. However, newer designs with glenospheres that allow for eccentricity make this measurement less useful. For instance, 2 shoulders may have the same

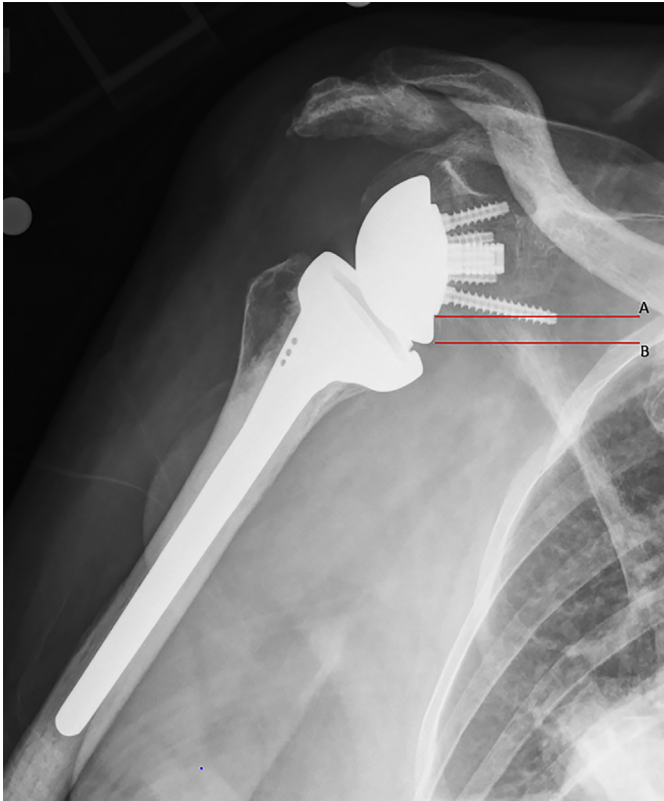


Figure 4 SBOD (distance between line A and line B) with the DePuy Synthes Delta XTend (medialized center of rotation). SBOD, sphere bone overhang distance.

PGRD, but if one uses an eccentric glenosphere, the COR may be translated inferiorly and perhaps help prevent abutment of the humeral polyethylene insert on the scapular neck. These implants are especially helpful in allowing baseplate position in the

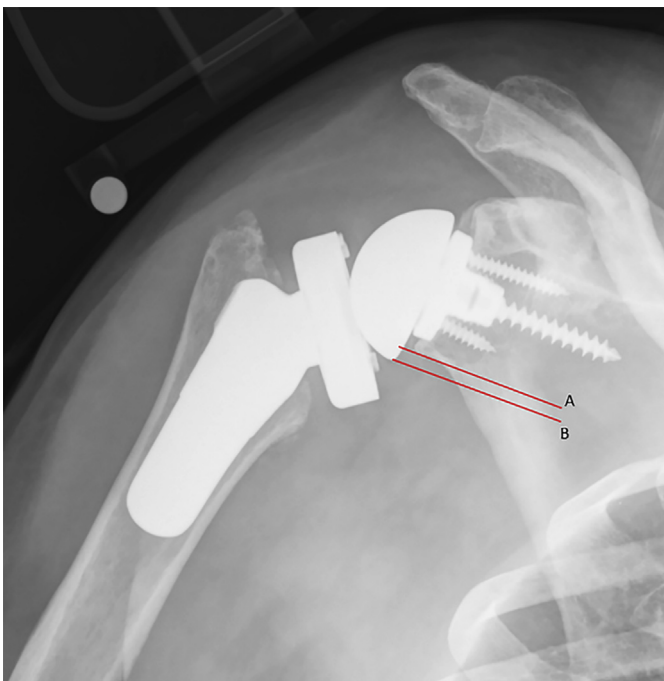


Figure 5 SBOD (distance between line A and line B) with the Biomet Comprehensive (lateralized center of rotation). SBOD, sphere bone overhang distance.

Table II
Radiographic measurements

	Mean (range)	Mean Δ angle (postoperative to preoperative)	P value
Preoperative α angle	139.4° \pm 8.510° (113.7°–188.8°)	4.088° (–63.7° to 33.8°)	<.0001
Postoperative α angle	143.49° \pm 9.78° (115.9°–172.3°)		
Preoperative β angle	78.93° \pm 8.61° (52.30°–103.4°)	4.625° (–14.2° to 44°)	<.0001
Postoperative β angle	83.55° \pm 8.87° (63.60°–103.9°)		
Preoperative RSA angle	32.95° \pm 11.24° (0°–71.00°)	–26.39° (–62.7° to 13.2°)	<.0001
Postoperative RSA angle	6.55° \pm 8.97° (–13.90° to 27.90°)		
SNA	100.48° \pm 16.18° (65.30°–143.00°)	8.029° (–66.2° to 61.4°)	<.0001
PSNA	108.51° \pm 19.98° (36.90°–151.40°)		
PGRD (Biomet excluded)	23.83° \pm 4.044° (15.7°–37.2°)		
SBOD	2.623° \pm 3.222° (–13° to 10.3°)		

RSA, reverse shoulder arthroplasty; SNA, scapular neck angle; PSNA, prosthesis scapular neck angle; PGRD, peg glenoid rim distance; SBOD, sphere bone overhang distance.

Paired *t* test

best-quality bone without completely dictating glenosphere position. Also, as glenosphere size increases, inferior bony coverage is improved, but the relationship between the peg and the inferior scapular neck does not change. Therefore, the PGRD does not account for adjustments in glenosphere size.

This is the rationale for the SBOD, or glenosphere overhang. This measurement allows the surgeon to directly define the relation of the inferior aspect of the glenosphere to the scapular neck. As the glenosphere translates inferiorly in relation to the scapular neck, there is increased space for the humeral component, allowing greater degree of adduction before impingement. This glenosphere translation would be captured by the SBOD, but not the PGRD, because the baseplate is in the same position in relation to the inferior scapular neck. As an additional benefit, this measurement is readily made in the operating room, as opposed to the PGRD, which would require intraoperative radiographs.

In regard to PGRD and SBOD, inferiorization of the baseplate decreases the PGRD, which was associated with notching in our cohort. Inferiorization of the glenosphere relative to the inferior

Table III
Linear regression of radiographic factors, independently

Factor	P value	Estimate coefficient	R ²
Preoperative α angle	.0338*	–0.02455	0.030702*
Preoperative β angle	.05240	0.0073344	0.002805*
SNA	.4689	0.00611	0.003623*
Preoperative RSA angle	.6581	–0.003907	0.001355*
Postoperative α angle	.0045*	–0.028397	0.054198
Postoperative β angle	.0012*	–0.035547	0.069887
PSNA	.9353	–0.000403	4.554E–5
RSA2 angle	.0007*	0.0369376	0.077132
PGRD	.0161*	–0.055226	0.039303*
SBOD	.0002*	–0.113207	0.093512

SNA, scapular neck angle; RSA, reverse shoulder arthroplasty; PSNA, prosthesis scapular neck angle; PGRD, peg glenoid rim distance; SBOD, sphere bone overhang distance.

* Significant difference ($P < .05$).

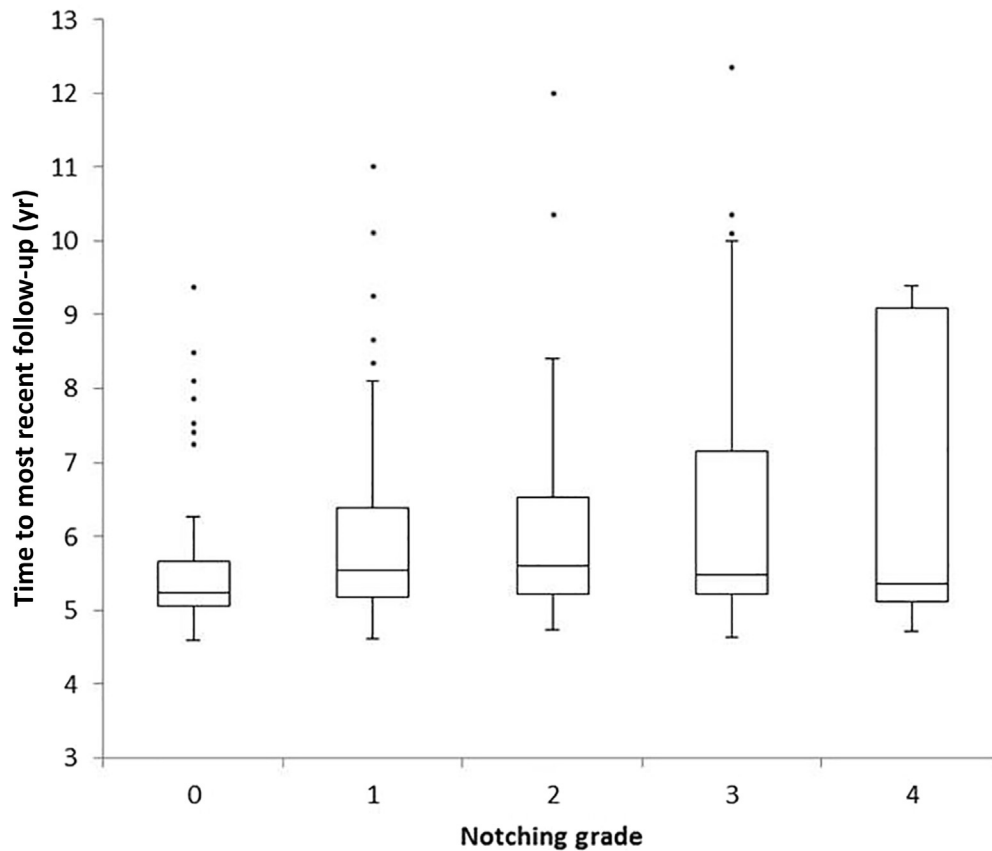


Figure 6 Box-plot diagram showing the distribution of median time to most recent follow-up in each notching grade group.

scapular neck was also associated with decreased notching. This implies that scapular notching is decreased when the baseplate is translated superiorly (increases PGRD) in relation to the glenoid and when the glenosphere is translated inferiorly (increases SBOD).

To explain this contradiction, we analyzed our eccentric implants (Biomet) with both univariate and multivariate analysis and found that the PGRD had no association with notching in this subgroup. However, SBOD was associated with notching in these implants. This further argues the superiority of SBOD use in the prevention of notching; it can be used in RSA systems that do and do not allow glenosphere eccentricity.

Implant design

Scapular notching was significantly higher in implants with a more medialized glenoid COR and with prostheses with higher POAs. There are other potential benefits of using a more lateralized system, especially as it relates to tension of any remaining rotator cuff.⁷

Table IV
Stepwise regression models

Variable	Coefficient (95% CI)	P value
Model 1: Preoperative radiographs		
Time to follow-up	0.149 (0.028, 0.271)	.0166
Model 2: Postoperative radiographs		
SBOD	-0.174 (-0.232, 0.117)	<.0001
PGRD	-0.098 (-0.141, 0.0540)	<.0001
RSA angle	0.033 (0.0139, 0.052)	.0008

SBOD, sphere bone overhang distance; PGRD, peg glenoid rim distance; RSA, reverse shoulder arthroplasty; CI, confidence interval.

Revision

The rate of reoperation in our cohort was 2.7% at a minimum of 5 years, with reasons for reoperation related to component failure in only 1 shoulder. This shoulder was revised for a broken humeral tray and had no notching on most recent radiographs. This is further evidence demonstrating the durability and reliability of RTSA. Despite the notching rate of 66.7%, only 1 of 147 (0.7%) experienced component failure requiring revision surgery. Our cohort demonstrates that at midterm follow-up, scapular notching is associated with glenosphere and baseplate position, but there was no association between scapular notching and revision surgery.

Limitations

Limitations of the study include retrospective design and multiple implants. This was a radiographic study, and therefore it does not include patient-reported outcome measures. Implants included also do not separate the prosthesis neck-shaft angle from the

Table V
Lateralization and prosthesis neck-shaft angle of component and degree of notching

COR	POA	Notching grade					Total
		0	1	2	3	4	
Medialized	155°	7	25	16	17	6	71
Lateralized (Biomet)	147°	36	18	8	2	0	64
Lateralized (Encore)	135°	6	3	1	1	1	12
Total		49	46	25	20	7	147

COR, center of rotation; POA, polyethylene opening angle.

Table VI
Association between baseplate positioning and revision surgery

Factor	Revision		P value
	Yes, median (IQR) (n = 4)	No, median (IQR) (n = 143)	
Preoperative α angle	139.45 (118.9–147.625)	139.4 (134.9–143.4)	.8723
Preoperative β angle	80.2 (59.225–82.65)	79.2 (74.5–84.5)	.7524
SNA	86.85 (69.925–113.9)	100.3 (89–109.1)	.2112
Preoperative RSA angle	30.75 (26–40.525)	32.4 (27.2–40.4)	.7842
Postoperative α angle	136.8 (123.5–158.875)	142.9 (137.1–151)	.6254
Postoperative β angle	88.25 (69.2–95.6)	83.9 (77.2–89.7)	.6212
POA	109.95 (79.85–128.275)	107.6 (94.9–124.7)	.8489
Postoperative RSA angle	1.75 (–5.6 to 20.8)	6.1 (0.4–12.8)	.5921
PGRD	29.85 (23.725–32.675)	25.2 (22.5–28.8)	.1728
SBOD	2.35 (1.925–5.85)	2.4 (0.8–4.8)	.6334

POA, polyethylene opening angle; RSA, reverse shoulder arthroplasty; PGRD, peg glenoid rim distance; SBOD, sphere bone overhang distance; IQR, interquartile range.

amount of lateralization, making it difficult to determine the relative separate effect of prosthesis neck-shaft angle and lateralization. Although including multiple implants is a limitation, it also adds to the strength of this study and allows application of the SBOD to multiple implant designs.

Conclusions

At a minimum follow-up time of 5 years, scapular notching was associated with longer follow-up and influenced by glenoid component position, the COR of the glenosphere, and the opening angle of the polyethylene. Although notching to some extent was visible in two-thirds of the shoulders, moderate or severe notching was seen in only approximately 15% of the shoulders. Revision surgery was extremely low in this cohort, and it was not related to notching or instability. Longer 10-year minimum follow-up will likely be needed to detect any influence of notching on component failure or revision surgery.

Disclaimer

Joaquin Sanchez-Sotelo reports royalties from Stryker. All the other authors, their immediate families, and any research foundations with which they are affiliated have not received any financial payments or other benefits from any commercial entity related to the subject of this article.

References

- Aibinder WR, Clark NJ, Schoch BS, Steinmann SP. Assessing glenosphere position: superior approach versus deltopectoral for reverse shoulder arthroplasty. *J Shoulder Elbow Surg* 2018;27:455–62. <https://doi.org/10.1016/j.jse.2017.10.013>.
- Athwal GS, MacDermid JC, Reddy KM, Marsh JP, Faber KJ, Drosdowech D. Does bony increased-offset reverse shoulder arthroplasty decrease scapular notching? *J Shoulder Elbow Surg* 2015;24:468–73. <https://doi.org/10.1016/j.jse.2014.08.015>.

- Boileau P, Gonzalez JF, Chuinard C, Bicknell R, Walch G. Reverse total shoulder arthroplasty after failed rotator cuff surgery. *J Shoulder Elbow Surg* 2009;18:600–6. <https://doi.org/10.1016/j.jse.2009.03.011>.
- Boileau P, Morin-Salvo N, Gaudi MO, Seeto BL, Chalmers PN, Holzer N, et al. Angled BIO-RSA (bony-increased offset-reverse shoulder arthroplasty): a solution for the management of glenoid bone loss and erosion. *J Shoulder Elbow Surg* 2017;26:2133–42. <https://doi.org/10.1016/j.jse.2017.05.024>.
- Boileau P, Watkinson D, Hatzidakis AM, Hovorka I, Neer Award 2005: The Grammont reverse shoulder prosthesis: results in cuff tear arthritis, fracture sequelae, and revision arthroplasty. *J Shoulder Elbow Surg* 2006;15:527–40. <https://doi.org/10.1016/j.jse.2006.01.003>.
- Bufquin T, Hersan A, Hubert L, Massin P. Reverse shoulder arthroplasty for the treatment of three- and four-part fractures of the proximal humerus in the elderly: a prospective review of 43 cases with a short-term follow-up. *J Bone Joint Surg Br* 2007;89:516–20. <https://doi.org/10.1302/0301-620X.89B4.18435>.
- Frankle M, Siegal S, Pupello D, Saleem A, Mighell M, Vasey M. The reverse shoulder prosthesis for glenohumeral arthritis associated with severe rotator cuff deficiency. A minimum two-year follow-up study of sixty patients. *J Bone Joint Surg Am* 2005;87:1697–705. <https://doi.org/10.2106/JBJS.D.02813>.
- Gutierrez S, Greiwe RM, Frankle MA, Siegal S, Lee WE 3rd. Biomechanical comparison of component position and hardware failure in the reverse shoulder prosthesis. *J Shoulder Elbow Surg* 2007;16:S9–12. <https://doi.org/10.1016/j.jse.2005.11.008>.
- Lévine C, Boileau P, Favard L, Garaud P, Molé D, Sirveaux F, et al. Scapular notching in reverse shoulder arthroplasty. *J Shoulder Elbow Surg* 2008;17:925–35. <https://doi.org/10.1016/j.jse.2008.02.010>.
- Lévine C, Garret J, Boileau P, Alami G, Favard L, Walch G. Scapular notching in reverse shoulder arthroplasty: is it important to avoid it and how? *Clin Orthop Relat Res* 2011;469:2512–20. <https://doi.org/10.1007/s11999-010-1695-8>.
- Maurer A, Fucetese SF, Pfirrmann CW, Wirth SH, Djangiri A, Jost B, et al. Assessment of glenoid inclination on routine clinical radiographs and computed tomography examinations of the shoulder. *J Shoulder Elbow Surg* 2012;21:1096–103. <https://doi.org/10.1016/j.jse.2011.07.010>.
- Mollon B, Mahure SA, Roche CP, Zuckerman JD. Impact of scapular notching on clinical outcomes after reverse total shoulder arthroplasty: an analysis of 476 shoulders. *J Shoulder Elbow Surg* 2017;26:1253–61. <https://doi.org/10.1016/j.jse.2016.11.043>.
- Nam D, Kepler CK, Nho SJ, Craig EV, Warren RF, Wright TM. Observations on retrieved humeral polyethylene components from reverse total shoulder arthroplasty. *J Shoulder Elbow Surg* 2010;19:1003–12. <https://doi.org/10.1016/j.jse.2010.05.014>.
- Roche C, Flurin PH, Wright T, Crosby LA, Mauldin M, Zuckerman JD. An evaluation of the relationships between reverse shoulder design parameters and range of motion, impingement, and stability. *J Shoulder Elbow Surg* 2009;18:734–41. <https://doi.org/10.1016/j.jse.2008.12.008>.
- Roche CP, Marczuk Y, Wright TW, Flurin PH, Grey S, Jones R, et al. Scapular notching and osteophyte formation after reverse shoulder replacement: radiological analysis of implant position in male and female patients. *Bone Joint J* 2013;95-B:530–5. <https://doi.org/10.1302/0301-620X.95B4.30442>.
- Roche CP, Marczuk Y, Wright TW, Flurin PH, Grey SG, Jones RB, et al. Scapular notching in reverse shoulder arthroplasty: validation of a computer impingement model. *Bull Hosp Jt Dis* (2013) 2013;71:278–83.
- Sabesan V, Callanan M, Sharma V, Wiater JM. Assessment of scapular morphology and surgical technique as predictors of notching in reverse shoulder arthroplasty. *Am J Orthop (Belle Mead NJ)* 2015;44:E148–52.
- Sadoghi P, Leithner A, Vavken P, Holzer A, Hochreiter J, Weber G, et al. Intra-glenoidal scapular notching in reverse total shoulder replacement: a prospective series of 60 cases and systematic review of the literature. *BMC Musculoskelet Disord* 2011;12:101. <https://doi.org/10.1186/1471-2474-12-101>.
- Simovitch RW, Zumstein MA, Lohri E, Helmy N, Gerber C. Predictors of scapular notching in patients managed with the Delta III reverse total shoulder replacement. *J Bone Joint Surg Am* 2007;89:588–600. <https://doi.org/10.2106/JBJS.F.00226>.
- Sirveaux F, Favard L, Oudet D, Huquet D, Walch G, Mole D. Grammont inverted total shoulder arthroplasty in the treatment of glenohumeral osteoarthritis with massive rupture of the cuff. Results of a multicentre study of 80 shoulders. *J Bone Joint Surg Br* 2004;86:388–95. <https://doi.org/10.1302/0301-620X.86b3.14024>.
- Torrens C, Santana F, Picazo B, Caceres E. Retrospective study of scapular notches in reverse shoulder arthroplasties. *Am J Orthop (Belle Mead NJ)* 2013;42:362–5.