

# The Healing Effect of Bone Marrow-Derived Stem Cells in Knee Osteoarthritis: A Case Report

Davood Mehrabani<sup>1,2</sup>, Fereidoon Mojtahed Jaberi<sup>3</sup>, Maryam Zakerinia<sup>4</sup>, Mohammad Javad Hadianfard<sup>5</sup>, Reza Jalli<sup>6\*</sup>, Nader Tanideh<sup>1</sup>, Shahrokh Zare<sup>1</sup>

1. Stem Cell and Transgenic Technology Research Center, Shiraz University of Medical Sciences, Shiraz, Iran;
2. Department of Regenerative Medicine, University of Manitoba, Winnipeg, MB, Canada;
3. Bone and Joint Diseases Research Center & Department of Orthopedic Surgery, Shiraz University of Medical Sciences, Shiraz, Iran;
4. Hematology Research Center & Department of Internal Medicine, Shiraz University of Medical Sciences, Shiraz, Iran;
5. Department of Physical Medicine and Rehabilitation, Shiraz University of Medical Sciences, Shiraz, Iran;
6. Medical Imaging Research Center & Department of Radiology, Shiraz University of Medical Sciences, Shiraz, Iran

## \*Co-Corresponding Authors:

Reza Jalli, MD;  
Associate Professor of Department of Radiology,  
Shiraz University of Medical Sciences,  
Shiraz, Iran

**Tel/Fax:** +98-71-32305410

**E-mail:** jalli@sums.ac.ir  
Fereidoon Mojtahed Jaberi, MD,  
Bone and Joint Diseases Research  
Center & Department of Orthopedic  
Surgery,  
Shiraz University of Medical Sciences,  
Shiraz, Iran

**Tel/Fax:** +98-71-32305410

**E-mail:** jaberifm@yahoo.com

**Received:** September 1, 2015

**Revised:** February 21, 2016

**Accepted:** April 10, 2016

## ABSTRACT

Osteoarthritis (OA) is a prevalent chronic disease impacting on quality of life and has societal and economical burden increasing with age. Yet, no confirmed pharmacological, biological or surgical therapy could prevent the progressive destruction of OA joint. Mesenchymal stem cells (MSCs) with immunosuppressive activities emerged a potential therapy. We describe a magnetic resonance images (MRI) approved 47 years old nomad female suffering from a severe right knee OA. After intra-articular injection of  $36 \times 10^6$  passage 2 of bone marrow-derived stem cells (BMSCs), the patient's functional status of the knee, the number of stairs she could climb, the pain on visual analog scale (VAS) and walking distance improved after two months post-transplantation. MRI revealed an extension of the repaired tissue over subchondral bone. So as MSC transplantation is a simple technique, resulted into pain relief, minimized donor-site morbidity, provided a better quality of life, significantly improved cartilage quality with no need to hospitalization or surgery, cell transplantation can be considered as a reliable alternative treatment for chronic knee OA. Therefore these findings can be added to the literature on using BMSCs for treatment of OA.

## KEYWORDS

Osteoarthritis; Knee; Bone Marrow; Mesenchymal Stem Cell; Transplantation

Please cite this paper as:

Mehrabani D, Mojtahed Jaberi F, Zakerinia M, Hadianfard MJ, Jalli R, Tanideh N, Zare Sh. The Healing Effect of Bone Marrow-Derived Stem Cells in Knee Osteoarthritis: A Case Report. *World J Plast Surg* 2016;5(2):168-174.

## INTRODUCTION

Lesions of articular cartilage are debilitating leading to fibrillation and subsequent degradation involving the subchondral bone resulting into development of osteoarthritis (OA).<sup>1</sup> The limiting factor in repair of articular lesions is the low intrinsic regeneration potential of cartilage tissue due to limitations of progenitor cells from the blood and bone marrow to enter the defect and the inability of resident articular chondrocytes to migrate into the lesion to secrete a reparative matrix.<sup>2</sup>

The disease affects the quality of life and has a striking impact

on societal and economic cost and is considered as an important cause of premature death.<sup>3</sup> Knee OA has a high prevalence in Asian countries,<sup>4</sup> especially in Iran<sup>5</sup> while the causes of cartilage degeneration were shown to be trauma, aging process, overweight, overuse, inflammatory, autoimmune, metabolic, and infectious diseases, genetic predisposition, etc.<sup>6</sup>

Autologous chondrocyte implantation (ACI), matrix-induced autologous chondrocyte implantation (MACI), steroidal and non-steroidal anti-inflammatory drugs, visco-supplementation with injections of sodium hyaluronan, nutraceuticals including glucosamine, chondroitin sulphate, omega-3 fatty acids were reported as therapeutic measures to reverse the process, but with controversial findings.<sup>7</sup>

Mesenchymal stem cells (MSCs) are a powerful tool in repair of cartilage tissue as they are able to differentiate into many connective tissues such as fat, cartilage, bone, etc.<sup>8</sup> MSCs have immunomodulatory and anti-inflammatory effects,<sup>9</sup> self-renewal capacity, stemness maintenance, and plasticity allowing their application for allo- and xenotransplantation<sup>10</sup> while transplantation of MSCs is based on the capacity of these cells to home and engraft long-term into the appropriate target tissue<sup>11</sup> such as bone and cartilage in treatment of OA.<sup>2</sup>

Yet, no approved pharmacological intervention, biologic therapy or procedure has prevented the progressive destruction of the OA joint. Here, we describe a case report on the healing effect of bone marrow-derived stem cells in a female with confirmed MRI severe knee osteoarthritis.

## CASE REPORT

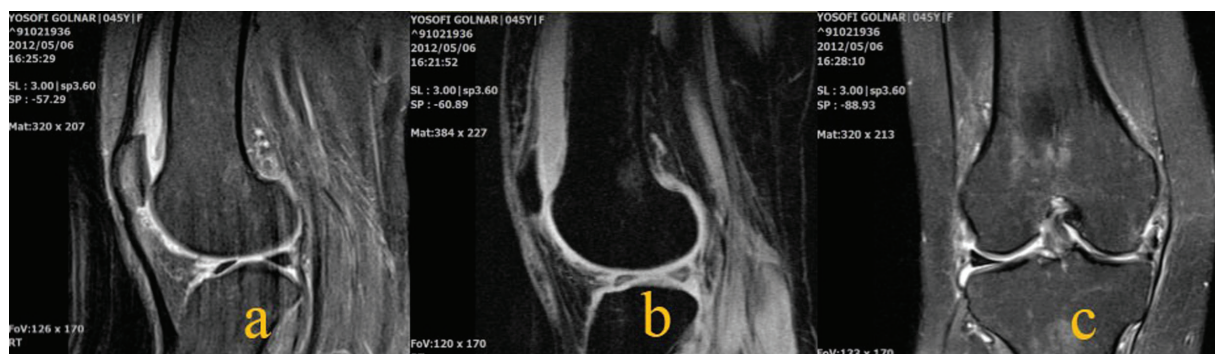
The patient was a 47 years old nomad female

with confirmed magnetic resonance images (MRI) severe right knee OA (classified as stage IV according to the Kellgren and Lawrence classification) (Figure 1). Her BMI was 25 kg/m<sup>2</sup>. She did not respond to corticosteroids, non-steroidal anti-inflammatory drugs (NSAIDs) and glucosamine, chondroitin sulphate or omega-3 fatty acids, while she was asked to stop her medications one month prior and also after enrolling for cell transplantation.

The patient did not have any infection with hepatitis B, C, or HIV, any malignancy, any previous history of allergic reaction to any component of our therapeutic measure, any active cardiac, respiratory, neurologic or endocrine disease necessitating receipt of medication and was not pregnant or in lactating condition. An approval from the Ethics Committee of Shiraz University of Medical Sciences and informed written consent was provided from the patient.

The patient was admitted in Chamran Hospital for physical exam and evaluation of the Western Ontario and McMaster Universities (WOMAC) Osteoarthritis Index, the Visual Analogue Scale (VAS) scoring of the pain intensity, walking ability (distance), the number of stairs to climb for the pain to appear, the time till the appearance of gelling, the knee flexion, and the patellar crepitus before and after cell transplantation. Before and after cell transplantation, MRI was undertaken for the affected knee in Faghihi Hospital. MRI of the affected knee was provided preoperatively, 3, 6 and 12 months after treatment on a Seimens 1.5 T MR system in the sagittal, coronal and axial planes.

For bone marrow aspiration, the patient was admitted in Nemazee Hospital. She was placed in prone position and was locally anesthetized with 1% lidocaine and about 60 ml of bone marrow was provided from iliac crest. Cell isolation was undertaken in the clean room of Mother



**Fig. 1:** MR images through the right knee joint before stem cell therapy. Proton density (a,b) and T1W gradient echo © sections.

and Child Hospital. Fifty milliliter of phosphate buffer saline (PBS, Clinimax, Germany) was added to the sample, loaded onto a lymphodex (Inno-Train, Germany) and was centrifuged at 1500 g for 20 minutes to collect mononuclear cells. PBS was used to wash the mononuclear cells and they were plated into 150-cm<sup>2</sup> culture flasks containing 15 ml of alpha modified eagle medium (alpha MEM, Gibco, Germany) supplemented with 10% hyclon serum (Thermo Scientific, USA) and 100 IU penicillin and 100 IU streptomycin (Gibco, Germany).

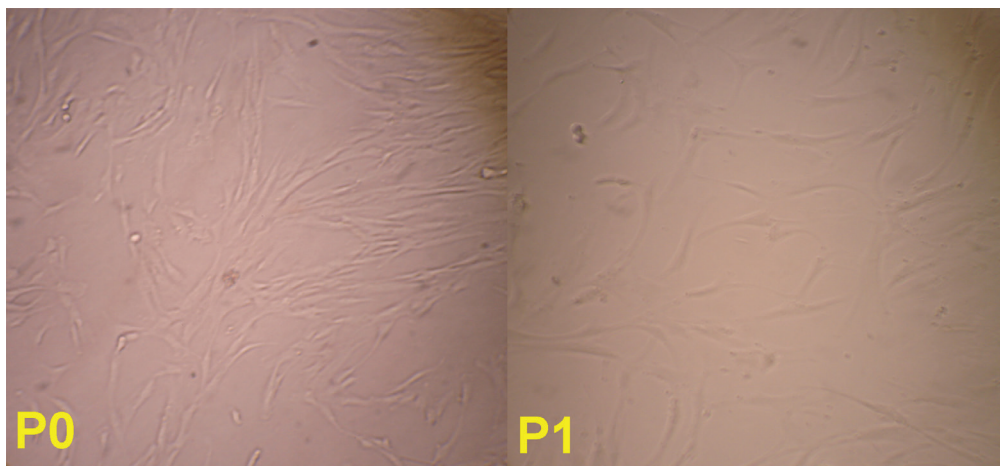
A sample was provided to test for presence of any possible microbial contamination. Cell expansion was taken place by subcultures and passaged-2 cells were provided for cell injection. Four weeks after plating of cells and in passage-2, they were washed with PBS and trypsinized with 0.2% trypsin/EDTA and cell counting was performed using a nucleocounter (Chemometec, USA). A total of  $36 \times 10^6$  cells were provided and under a controlled condition, they were transferred in 2 ml of the media to the operating room for cell transplantation into the knee joint.

Again a sample was provided to check any microbial contamination before injection into the knee. The adhered cells to the flasks were

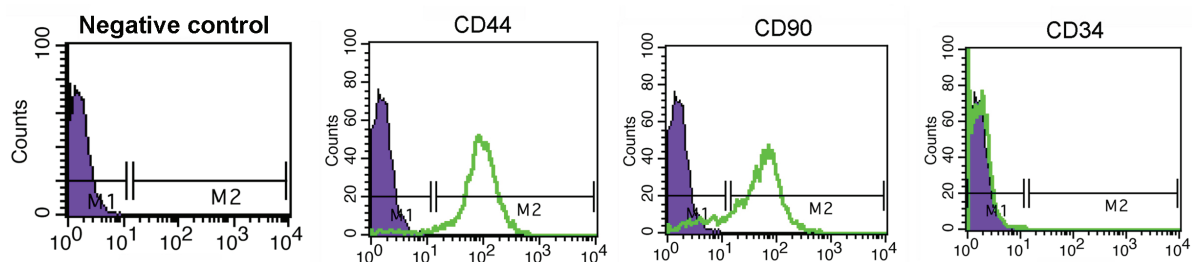
evaluated morphologically under inverted microscopy. Expression of surface markers in the patient's BM-MSCs was evaluated by flow cytometry to evaluate the positive surface biomarkers expression of CD44 and CD90 and absence of CD34 expression.

Cell morphology revealed fibroblastic like adherent cells in all culture flasks (Figure 2). No contamination was visible in the cell transplantation sample. Flow cytometric findings denoted to expression of CD44 and expression of CD90 (mesenchymal stem cell markers) and negative expression for CD34 (hematopoietic cell marker) (Figure 3). During the follow-up, no local or systemic adverse events were observed and the patient was satisfied with the therapy after two months with an increasing trend by passing time.

Twelve months after cell transplantation, the WOMAC changed from 3 to 2, and the VAS from 80 mm to 11 mm. This modification for walking ability was 170 m before and 700 m after treatment and for the number of stairs to climb for the pain to appear was 5 stairs before and 50 stairs after therapy. The time till the appearance of gelling was 8 min and reached to 30 min and the knee flexion was 100° and improved to 120° twelve months after cell transplantation.



**Fig. 2:** Emerging of adherent cells with fibroblastic morphology 3 days after culture initiation of the patient's BM-MSCs (P0=primary culture and P1=first passage).



**Fig. 3:** Expression of surface markers in patient's BM-MSCs. There were positive surface biomarkers expression of CD44 and CD90 and lack of CD34 expression.



The patellar crepitus was 3 before and 2 after therapy. After 6 months, the MRI of the right knee revealed an increase in thickness of the covering cartilage in distal condyle of the femur and the proximal part of the tibia (Figure 4A-C). These changes were much more significant after 12 months follow up (Figure 4D-F).

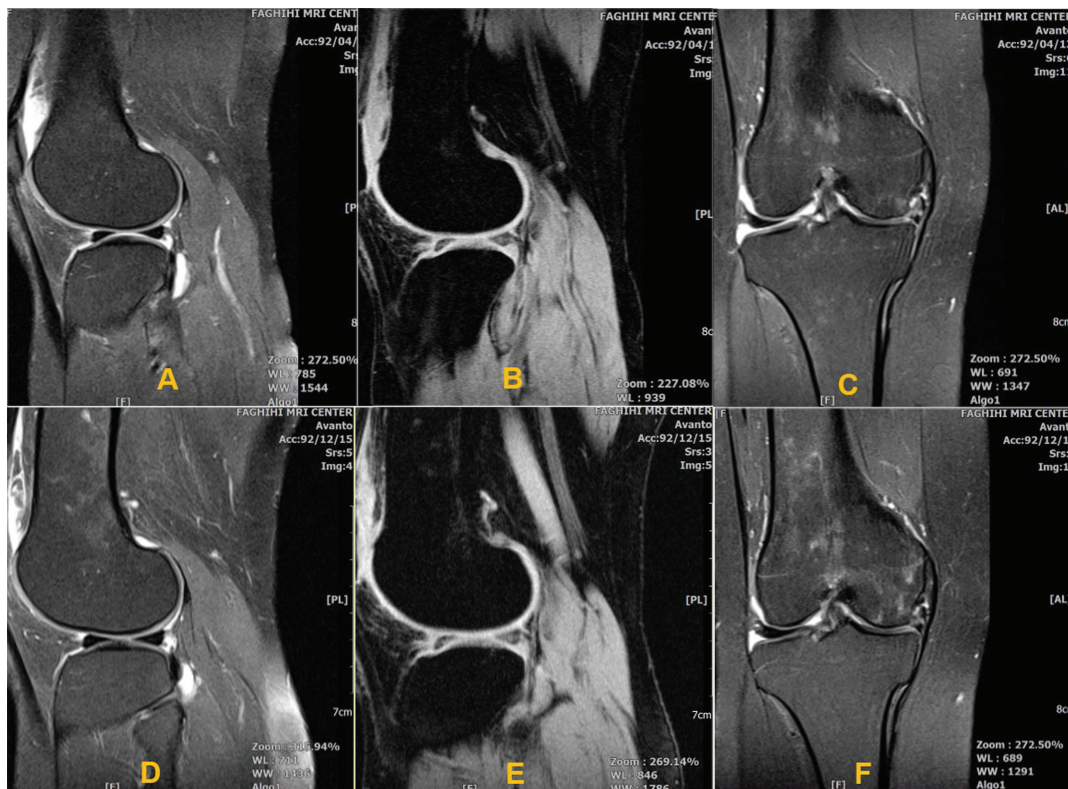
## DISCUSSION

Consistent with our findings, positive therapeutic effects of MSCs in human models were previously shown in different studies. In Jo et al.'s study, patients with knee OA of the knee were transplanted with  $1.0 \times 10^7$ ,  $5.0 \times 10^7$  and  $1.0 \times 10^8$  adipose-derived stem cells (AdSCs) into the knee. There was no adverse event and the WOMAC score improved at 6 months after injection and thick, hyaline-like cartilage regeneration was visible.<sup>12</sup> Orozco et al. in patients with knee OA treated with intra-articular injection of  $40 \times 10$  autologous bone marrow-derived stem cells (BM-SCs) observed that the patients demonstrated rapid and progressive improvement of algofunctional indices by 1 year

and also showed a highly significant decrease of poor cartilage areas with improvement of cartilage quality.<sup>13</sup>

Injection of BM-SCs in knee OA was shown to improve pain, functional status of the knee, and walking distance without any adverse events. An increase in cartilage thickness and a considerable decrease in the size of edematous subchondral bone were noticed.<sup>14</sup> Davatchi et al. performed single intra-articular BM-SCs injection in OA knees and described a marked clinical improvement in subjective parameters, although physical parameters improved much less.<sup>15</sup> Kasemkijwattana et al. showed a good defect filling and repair of tissue with BM-SCs in patients with knee OA and a significant clinical improvement.<sup>16</sup> Gigante et al. reported that BMSCs in patients with medial femoral condyle lesions, could result into normal arthroscopic appearance.<sup>17</sup>

Nejadnik et al. compared the first-generation ACI technique with implantation of BM-SCs and showed a similar pattern of clinical and subjective improvement up to 2 years postoperatively.<sup>18</sup> Haalem et al. used BM-SCs for treatment of articular knee cartilage defects and showed that



**Fig. 4:** MR images through the right knee joint six months after stem cell therapy. Proton density (A&C) and T1W gradient echo (B) sections revealed thickness of covering cartilage in distal condyle of femur and proximal part of tibia. MR images through the right knee joint twelve months after stem cell therapy. Proton density (D&F) and T1W gradient echo (E) sections revealed thickness of covering cartilage in distal condyle of femur and proximal part of tibia.

symptoms improved after 12 months, and MRI revealed complete defect filling and complete surface congruity with cartilage tissue.<sup>19</sup>

Centeno et al. showed encouraging results after treating a knee cartilage lesion by intra-articular injection of BM-SCs with an increase in cartilage and meniscus volume, and an improvement in range of motion and pain score.<sup>20</sup> Wakitani et al. described results after the treatment of patello-femoral cartilage defects with BM-SCs and improvement in clinical symptoms at 6 months, which was maintained over 17–27 months.<sup>21</sup> Adachi et al. in a large osteochondral knee defect treated with cultured BM-SCs noted a good cartilage and bone regeneration.<sup>22</sup>

Wakitani et al. described the use of BM-SCs in knee OA reported clinical improvement by arthroscopic and histological scoring.<sup>23</sup> They found clinical improvement in patients with full-thickness knee cartilage defects treated with BM-SCs after 6 months, which remained stable 5 years after treatment.<sup>24</sup> Buda et al. showed good subchondral bone and cartilage tissue regeneration after arthroscopic implantation of BMSCs in osteochondral knee defects.<sup>25</sup> Giannini et al. in patients with OA found that one-step BMSC transplantation could lead to a good restoration of the cartilaginous layer.<sup>26</sup>

Varma et al. reported an improvement in symptoms, with shortened hospital stay and better quality of life after BMSCs injection in patients with knee OA.<sup>27</sup> Giannini et al. in treatment of osteochondral talar dome lesions with BMSCs showed newly formed tissue that were well integrated with the surrounding tissue with an improvement in clinical scores.<sup>28</sup>

The immunomodulatory properties of AdSCs in patients with OA was previously shown<sup>29</sup> which explain the healing effect of the cells in affected joint. These cells in knee cartilage defects were shown to improve pain and the quality-of-life.<sup>30</sup> Kim et al. evaluated clinical and MRI outcomes after mesenchymal stem cell implantation in patients with knee osteoarthritis and showed encouraging clinical and MRI outcomes and repairing cartilage lesions in OA knees.<sup>31</sup> Emadedin et al. in their long-term follow-up of intra-articular injection of autologous mesenchymal stem cells in patients with knee, ankle, or hip osteoarthritis revealed that in affected joints, they are safe and therapeutically beneficial.<sup>32</sup> Davatchi et al.

in their 5 years follow-up of mesenchymal stem cell therapy for knee osteoarthritis reported that transplant knees were all in a rather advanced stage of OA. Earlier transplantation may give better results in long-term follow-up.<sup>33</sup>

Similar to above-mentioned studies, in our patient with severe knee OA and one year follow up after cell transplantation, the findings were satisfactory. The functional status of the knee, the number of stairs they could climb, the pain on visual analog scale and walking distance improved in our patient two months post-injection. Magnetic resonance images (MRI) at baseline, and post-stem cell injection revealed an extension of the repair tissue over subchondral bone. So as MSC transplantation is a simple technique, resulted into pain relief, minimized donor-site morbidity, provided a better quality of life, significantly improved cartilage quality with no need to hospitalization or surgery, cell transplantation can be considered as a reliable alternative treatment for chronic knee OA. These findings can be added to the literature on using MSCs for treatment of OA while we have compared our results completely with previous available studies chronologically.

## ACKNOWLEDGEMENT

The authors would like to appreciate the Office of Vice Chancellor for Research of Presidency Office for financial support and the personnel of Mother and Child Hospital for their kind cooperation. A written informed consent was obtained from the patient.

## CONFLICT OF INTEREST

The authors declare no conflict of interest.

## REFERENCES

- 1 Tanideh N, Dehghani Nazhvani S, Mojtahed Jaber F, Mehrabani D, Rezazadeh S, Pakbaz S, Tamadon A, Nikahval B. The healing effect of biogluce in articular cartilage defect of femoral condyle in experimental rabbit model. *Iran Red Crescent Med J* 2011;**13**:629-36.
- 2 Mehrabani D, Babazadeh M, Tanideh N, Zare S, Hoseinzadeh S, Torabinejad S, Koochi-Hosseiniabadi O. The Healing Effect of Adipose-Derived Mesenchymal Stem Cells in Full-thickness Femoral Articular Cartilage

- Defects of Rabbit. *Int J Organ Transplant Med* 2015;**6**:165-75.
- 3 Michaud CM, McKenna MT, Begg S, Tomijima N, Majmudar M, Bulzacchelli MT, Ebrahim S, Ezzati M, Salomon JA, Kreiser JG, Hogan M, Murray CJ. The burden of disease and injury in the United States 1996. *Popul Health Metr* 2006;**4**:11.
  - 4 Davatchi F. Rheumatic diseases in the APLAR region. *APLAR J Rheumatol* 2006;**9**:5-10.
  - 5 Davatchi F, Tehrani Banihashemi A, Gholami J, Faezi ST, Forouzanfar MH, Salesi M, Karimifar M, Essalatmanesh K, Barghamdi M, Noorolahzadeh E, Dahaghin S, Rasker JJ. The prevalence of musculoskeletal complaints in a rural area in Iran: a WHO-ILAR COPCORD study (stage 1, rural study) in Iran. *Clin Rheumatol* 2009;**28**:1267-74.
  - 6 Haq SA, Davatchi F, Dahaghin S, Islam N, Ghose A, Darmawan J, Chopra A, Yu ZQ, Dans LF, Rasker JJ. Development of a questionnaire for identification of the risk factors for osteoarthritis of the knees in developing countries. A pilot study in Iran and Bangladesh. An ILAR-COPCORD phase III study. *Int J Rheum Dis* 2010;**13**:203-14.
  - 7 Kon E, Filardo G, Roffi A, Andriolo L, Marcacci M. New trends for knee cartilage regeneration: from cell-free scaffolds to mesenchymal stem cells. *Curr Rev Musculoskelet Med* 2012;**5**:236-43.
  - 8 Hosseinkhani M, Mehrabani D, Karimfar MH, Bakhtiyari S, Manfi A, Shirazi R. Tissue engineered scaffolds in regenerative medicine. *World J Plast Surg* 2014;**3**:3-7.
  - 9 Ai J, Ebrahimi S, Khoshzaban A, Jafarzadeh Kashi TS, Mehrabani D. Tissue engineering using human mineralized bone xenograft and bone marrow mesenchymal stem cells allograft in healing of tibial fracture of experimental rabbit model. *Iran Red Crescent Med J* 2012;**14**:95-102.
  - 10 Mehrabani D, Mehrabani G, Zare S, Manafi A. Adipose-derived stem cells (ADSC) and aesthetic surgery: a mini review. *World J Plast Surg* 2013;**2**:65-70.
  - 11 Ghobadi F, Mehrabani D, Mehrabani G. Regenerative potential of endometrial stem cells: a mini review. *World J Plast Surg* 2015;**4**:3-8.
  - 12 Jo CH, Lee YG, Shin WH, Kim H, Chai JW, Jeong EC, Kim JE, Shim H, Shin JS, Shin IS, Ra JC, Oh S, Yoon KS. Intra-articular injection of mesenchymal stem cells for the treatment of osteoarthritis of the knee: A proof-of-concept clinical trial. *Stem Cells* 2014;**32**:1254-66.
  - 13 Orozco L, Munar A, Soler R, Alberca M, Soler F, Huguet M, Sentis J, Sánchez A, García-Sancho J. Treatment of knee osteoarthritis with autologous mesenchymal stem cells: a pilot study. *Transplantation* 2013;**95**:1535-41.
  - 14 Emadedin M, Fazeli R, Farjad R. Intra-articular injection of autologous mesenchymal stem cells in six patients with knee osteoarthritis. *Arch Iran Med* 2012;**15**:422.
  - 15 Davatchi F, Abdollahi BS, Mohyeddin M, Shahram F, Nikbin B. Mesenchymal stem cell therapy for knee osteoarthritis. Preliminary report of four patients. *Int J Rheum Dis* 2011;**14**:211-15.
  - 16 Kasemkijwattana C, Hongeng S, Kesprayura S, Rungsinaporn V, Chaipinyo K, Chansiri K. Autologous bone marrow mesenchymal stem cells implantation for cartilage defects: two cases report. *J Med Assoc Thai* 2011;**94**:395-400.
  - 17 Gigante A, Calcagno S, Cecconi S, Ramazzotti D, Manzotti S, Enea D. Use of collagen scaffold and autologous bone marrow concentrate as a one-step cartilage repair in the knee: histological results of second-look biopsies at 1 year follow-up. *Int J Immunopathol Pharmacol* 2011;**24**:69-72.
  - 18 Nejadnik H, Hui JH, Choong EPF, Tai B-C, Lee EH. Autologous bone marrow-derived mesenchymal stem cells versus autologous chondrocyte implantation: an observational cohort study. *Am J Sports Med* 2010;**38**:1110-16.
  - 19 Haleem AM, El Singergy AA, Sabry D, Atta HM, Rashed LA, Chu CR, El Shewy MT, Azzam A, Abdel Aziz MT. The clinical use of human culture-expanded autologous bone marrow mesenchymal stem cells transplanted on platelet-rich fibrin glue in the treatment of articular cartilage defects: a pilot study and preliminary results. *Cartilage* 2010;**1**:253-61.
  - 20 Centeno CJ, Busse D, Kisiday J, Keohan C, Freeman M, Karli D. Increased knee cartilage volume in degenerative joint disease using percutaneously implanted, autologous mesenchymal stem cells. *Pain Physician* 2008;**11**:343-53.
  - 21 Wakitani S, Nawata M, Tensho K, Okabe T, Machida H, Ohgushi H. Repair of articular cartilage defects in the patello-femoral joint



- with autologous bone marrow mesenchymal cell transplantation: three case reports involving nine defects in five knees. *J Tissue Eng Regen Med* 2007;**1**:74-9.
- 22 Adachi N, Ochi M, Deie M, Ito Y. Transplant of mesenchymal stem cells and hydroxyapatite ceramics to treat severe osteochondral damage after septic arthritis of the knee. *J Rheumatol* 2005;**32**:1615-18.
- 23 Wakitani S, Imoto K, Yamamoto T, Saito M, Murata N, Yoneda M. Human autologous culture expanded bone marrow mesenchymal cell transplantation for repair of cartilage defects in osteoarthritic knees. *Osteoarthritis Cartilage* 2002;**10**:199-206.
- 24 Wakitani S, Mitsuoka T, Nakamura N, Toritsuka Y, Nakamura Y, Horibe S. Autologous bone marrow stromal cell transplantation for repair of full-thickness articular cartilage defects in human patellae: two case reports. *Cell Transplant* 2004;**13**:595-600.
- 25 Buda R, Vannini F, Cavallo M, Grigolo B, Cenacchi A, Giannini S. Osteochondral lesions of the knee: a new one-step repair technique with bone-marrow-derived cells. *J Bone Joint Surg Am* 2010;**92**:2-11.
- 26 Giannini S, Buda R, Cavallo M, Ruffilli A, Cenacchi A, Cavallo C, Vannini F. Cartilage repair evolution in post-traumatic osteochondral lesions of the talus: from open field autologous chondrocyte to bone-marrow-derived cells transplantation. *Injury* 2010;**41**:1196-1203.
- 27 Varma HS, Dadarya B, Vidyarthi A. The new avenues in the management of osteoarthritis of knee-stem cells. *J Indian Med Assoc* 2010;**108**:583-5.
- 28 Giannini S, Buda R, Vannini F, Cavallo M, Grigolo B. One-step bone marrow-derived cell transplantation in talar osteochondral lesions. *Clin Orthop Relat Res* 2009;**467**:3307-20.
- 29 Skalska U, Kontny E. Adipose-derived mesenchymal stem cells from infrapatellar fat pad of patients with rheumatoid arthritis and osteoarthritis have comparable immunomodulatory properties. *Autoimmunity* 2016;**49**:124-31.
- 30 Koh YG, Kwon OR, Kim YS, Choi YJ, Tak DH. Adipose-Derived Mesenchymal Stem Cells With Microfracture Versus Microfracture Alone: 2-Year Follow-up of a Prospective Randomized Trial. *Arthroscopy* 2016;**32**:97-109.
- 31 Kim YS, Choi YJ, Lee SW, Kwon OR, Suh DS, Heo DB, Koh YG. Assessment of clinical and MRI outcomes after mesenchymal stem cell implantation in patients with knee osteoarthritis: a prospective study. *Osteoarthritis Cartilage* 2016;**24**:237-45.
- 32 Emadedin M, Ghorbani Liastani M, Fazeli R, Mohseni F, Moghadasali R, Mardpour S, Hosseini SE, Niknejadi M, Moeinia F, Aghahosseini Fanni A, Baghban Eslaminejhad R, Vosough Dizaji A, Labibzadeh N, Mirazimi Bafghi A, Baharvand H, Aghdami N. Long-Term Follow-up of Intra-articular Injection of Autologous Mesenchymal Stem Cells in Patients with Knee, Ankle, or Hip Osteoarthritis. *Arch Iran Med* 2015;**18**:336-44.
- 33 Davatchi F, Sadeghi Abdollahi B, Mohyeddin M, Nikbin B. Mesenchymal stem cell therapy for knee osteoarthritis: 5 years follow-up of three patients. *Int J Rheum Dis* 2016;**19**:219-25.