



Sinus floor elevation and simultaneous implant placement in fresh extraction sockets: a systematic review of clinical data

Mehdi Ekhlasmandkermani¹, Reza Amid^{1,2}, Mahdi Kadkhodazadeh^{1,2},
Farhad Hajizadeh¹, Pooria Fallah Abed³, Lida Kheiri⁴, Aida Kheiri⁵

¹Department of Periodontics, School of Dentistry, Shahid Beheshti University of Medical Sciences,

²Dental Research Center, Research Institute of Dental Sciences, School of Dentistry, Shahid Beheshti University of Medical Sciences, Tehran, Iran,

³Department of Periodontology, Texas A and M College of Dentistry, Dallas, TX, USA,

⁴Department of Oral and Maxillofacial Surgery, School of Dentistry, Isfahan (Khorasgan) Branch, Islamic Azad University, Isfahan,

⁵Student Research Committee, School of Dentistry, Shahid Beheshti University of Medical Sciences, Tehran, Iran

Abstract (J Korean Assoc Oral Maxillofac Surg 2021;47:411-426)

Combining different procedures to reduce the number of surgical sessions and patient discomfort in implant placement and sinus floor elevation has been recommended, and evidence supports good outcomes. The aim of this study was to review the results of clinical studies on sinus floor elevation through extraction sockets and simultaneous immediate posterior implant placement. An electronic search was carried out in PubMed, Scopus, and Web of Science to find English articles published in or before August 2020. A manual search was also performed. Titles, abstracts, and the full-text of the retrieved articles were studied. Thirteen studies met our eligibility criteria: 6 retrospective case series, 3 case reports, 2 prospective cohort case-series, 1 prospective case series, and 1 randomized controlled trial. Overall, 306 implants were placed; 2 studies reported implant survival rates of 91.7% and 98.57%. The others either did not report the survival rate or reported 100% survival. Sinus floor elevation through a fresh extraction socket and simultaneous immediate implant placement appears to be a predictable modality with a high success rate. However, proper case selection and the expertise of the clinician play fundamental roles in the success of such complex procedures.

Key words: Sinus floor augmentation, Sinus augmentation, Immediate dental implant, Sinus lift, Dental implantation

[paper submitted 2020. 11. 20 / revised 2021. 1. 6 / accepted 2021. 1. 21]

I. Introduction

Maxillary sinus floor pneumatization occurring after posterior maxillary tooth extraction can jeopardize straightforward implant placement¹. Following tooth extraction and discontinuation of the blood supply provided by the periodontal ligament (PDL), the alveolar ridge undergoes resorption². The physiological process of ridge resorption during the bone healing and remodeling phase³ and pneumatization of the maxillary sinus⁴ are important factors that affect the amount

of residual bone in the posterior maxilla. Both the quantity and quality of bone reflect the low density of bone in this region⁴, and any combination of the aforementioned factors can complicate dental implant placement in the posterior maxilla. Several approaches have been suggested to solve those problems⁵. Sinus floor elevation can be performed via the crestal and lateral approaches⁶⁻⁸. In 1976, Tatum was the first to describe the sinus floor elevation technique⁶, and the surgical approach for sinus floor elevation was published by Boyne and James in 1980⁷. Because the lateral approach is an invasive technique associated with significant postoperative discomfort, Summers⁸ proposed the use of osteotomes and the crestal approach in 1994, claiming that that approach solved the problems of limited bone quality and quantity in the posterior maxilla.

Accessing the Schneiderian membrane via the crestal approach and elevating it after entering the sinus cavity were modifications made over time, and in 2017, Pawar et al.⁹ discussed their efficacy.

Reza Amid

Department of Periodontics, School of Dentistry, Shahid Beheshti University of Medical Sciences, Daneshjou Boulevard, Evin, Tehran 1983969411, Iran
TEL: +98-09124660495

E-mail: reza_amid@yahoo.com

ORCID: <https://orcid.org/0000-0002-8053-3928>

© This is an open-access article distributed under the terms of the Creative Commons Attribution Non-Commercial License (<http://creativecommons.org/licenses/by-nc/4.0/>), which permits unrestricted non-commercial use, distribution, and reproduction in any medium, provided the original work is properly cited.

Copyright © 2021 The Korean Association of Oral and Maxillofacial Surgeons.

In the crestal approach for dental implant placement, the remaining bone height is what matters most in achieving primary stability¹⁰. Moraschini et al.¹¹, in a comprehensive review in 2017, concluded that the remaining bone height is more important than the use or omission of graft materials and bone substitutes beneath the sinus membrane in the process of sinus lifting. Achieving primary implant stability is a common requirement of two of the most common implant surgeries: sinus floor elevation simultaneous with implant placement and immediate implant placement in fresh extraction sockets¹².

The history of immediate implant placement in fresh extraction sockets dates back to 1976, when Schulte and Heimke¹³ suggested the approach as a strategy to save time. Alveolar bone remodeling starts immediately after tooth extraction. Evidence shows that the process of bone resorption begins 14 days after tooth extraction and can involve more than 20% of the buccal cortical bone². Thus, immediate implant placement saves time, eliminates the need for a second surgical procedure, and decreases patient discomfort and the cost of treatment^{14,15}. Previous studies claimed that immediate implant placement could prevent alveolar bone collapse¹⁶, but recent investigations have shown that it only limits bone remodeling and can even result in more bone loss compared with early implant placement^{17,18}. Immediately placed implants have lower survival and success rates than delayed implant placements¹⁹, and marginal bone loss and peri-implant soft tissue changes are mentioned as shortcomings of immediate implant placement; however, there is a lack of data about the success/survival rate and marginal bone loss of delayed implant placements²⁰.

In general, the posterior maxillary bone has a lower density than other parts of the jaw. Thus, achieving primary stability is more difficult, which could explain the lower success rate of immediate implants placed in the posterior maxilla compared with the mandible^{4,21}. Given that the goal of implant treatment is functional reconstruction of the posterior maxilla, the treatment plan can include the extraction of hopeless teeth, time allocated for healing the extraction sockets, sinus floor elevation in a separate session via the lateral or crestal approach to increase bone height, and eventual implant placement. Alternatively, a treatment plan that condenses all of those procedures into a single session would be ideal for patients, with the benefit of a short course of treatment and fewer surgical procedures¹⁵.

Therefore, we extracted and reviewed the results of clinical studies about sinus floor elevation through the extraction

socket and simultaneous, immediate implant placement.

II. Materials and Methods

This systematic review was conducted by following the principles of the PRISMA (Preferred Reporting Items for Systematic Reviews and Meta-Analyses) statement.

1. Focused question (PICO)

The focused question was: What are the differences among techniques presented for simultaneous closed sinus floor elevation with implant placement in fresh extraction sockets?

2. Type of studies

We included all human clinical studies of the immediate placement of implants in fresh extraction sockets in the posterior maxilla with sinus floor elevation via the same extraction sockets. The search was limited to English-language studies. Abstracts, letters, and reviews were excluded.

3. Type of participants

All patients who needed the extraction of a tooth/teeth in the posterior maxillary region, sinus floor elevation through the extraction socket(s), and immediate implant placement in the fresh socket(s) were included.

4. Type of intervention

Studies were included if they mentioned simultaneous closed sinus floor elevation with implant placement in fresh extraction sockets in the posterior maxillary region. Studies that did not perform sinus floor elevation through a fresh socket in the posterior maxilla or did not place implants immediately were excluded.

5. Type of outcome measures

The primary outcome was the survival/success rate of the installed implants with a minimum of six months of follow-up. The survival rate represents the persistence of implants, with no implant removal during follow-up, whereas the success rate represents criteria such as soft/hard tissue level, probing pocket depth, and bleeding on probing²². Also, the following variables were mentioned in some studies:

- Healing time between the surgical and prosthetic phases
- Detailed surgical protocols/materials

6. Information sources

The information source were PubMed, Web of Science, and Scopus databases. The search was limited to English-language studies published before the end of August 2020. Hand searching was also conducted.

7. Search strategy

An electronic search was performed using the following keywords: Maxillary sinus AND (augmentation OR lift OR elevation) AND extraction, Maxillary sinus AND (augmentation OR lift OR elevation) AND osteotome sinus, Maxillary sinus AND (augmentation OR lift OR elevation) AND immediate implant placement.

8. Study selection

Two reviewers conducted the search using those keywords and then performed an initial screening of the titles and abstracts they found. Any disagreements between the reviewers were resolved by discussion. The reviewers then reviewed the full-text of the selected articles.

9. Data items

Data were extracted from the full-text of the articles and tabulated for comparison. The following variables were evaluated: technique of tooth extraction, extraction with/without elevating a flap, distance from the tooth apex to the sinus floor, instrument and technique for elevating the sinus floor, magnitude of the elevation of the sinus membrane, use or no use of graft materials and bone substitutes, implant height, method of wound closure in the coronal implant region, success rate and survival of implants, and the duration of follow-up.

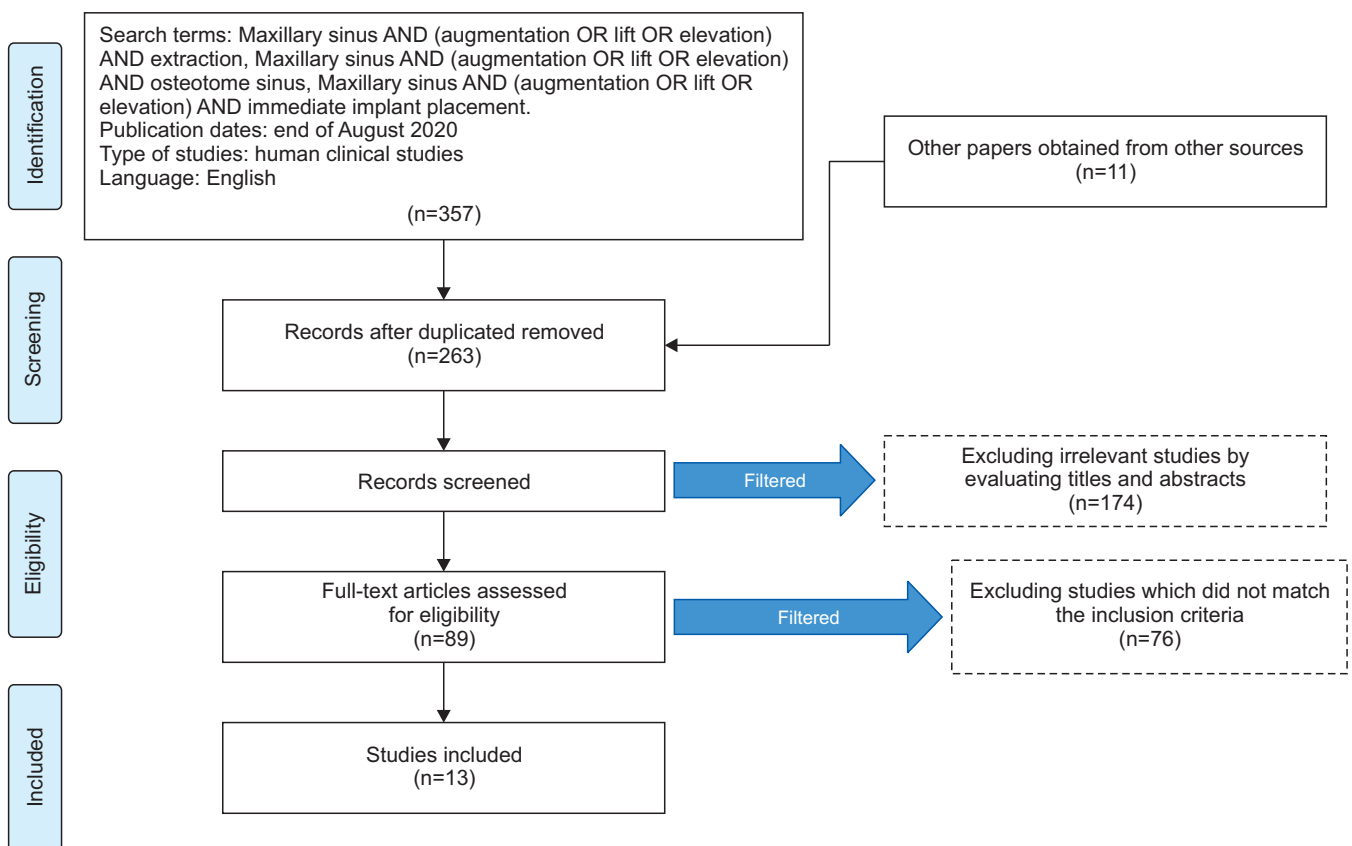


Fig. 1. Search strategy flowchart.

Mehdi Ekhlasmandkermani et al: Sinus floor elevation and simultaneous implant placement in fresh extraction sockets: a systematic review of clinical data. *J Korean Assoc Oral Maxillofac Surg* 2021

10. Data selection process

Review and data extraction were performed according to the PRISMA flow diagrams. After the full-text of the selected articles were reviewed, data were extracted and tabulated. Disagreements between reviewers were resolved by consensus.

11. Quality assessment

The quality of the methodologies used in all the included studies was assessed. The criteria used were based on the ROBINS-I tool²³: bias due to confounding, bias in selecting participants, bias in classifying interventions, bias due to deviation from the intended intervention, bias due to missing data, bias in outcome measurements, and bias in selecting the reported results. The criteria used for the one randomized controlled trial were obtained from the Cochrane Center: selection bias, performance bias, detection bias, attrition bias, and reporting bias. The degree of bias was categorized as low risk, moderate risk, and serious risk. In cases with no data about a criterion, 'no information' is stated. Two individual investigators (L.K. and A.K.) performed the assessment and resolved conflicts through discussion.

III. Results

The initial search found 368 articles. After removing duplications and irrelevant studies, 89 studies were screened, which excluded 76 more articles because they did not perform sinus floor elevation through the socket of an extracted tooth or they did not place implants immediately after tooth extraction and sinus floor elevation. Therefore, 13 articles are described in this review.(Fig. 1) The results are reported in the form of questions and answers and presented in Tables 1 to 6.

1. What types of study designs were used by the authors?

Of the 13 articles reviewed, six were retrospective case series^{12,24-28}, three were case reports^{21,29,30}, two were prospective cohorts in the form of case series^{31,32}, one was a prospective case series³³, and one was a randomized controlled trial with one year of follow-up¹⁵.

2. What demographic information was given for the patients enrolled?

Of the 13 articles reviewed, 12 provided the number of patients evaluated^{12,15,21,24-27,29-33}, and one did not²⁸. A total of 245

Table 1. Properties of the reviewed studies

Study	Keywords related to sinus lift through a fresh socket in the title	Study design	No. of patients	No. of implants with sinus lift
Artzi et al. ³³ (2003)	Internal sinus membrane elevation in immediate post-extraction phase	Prospective case series	10	10
Barone et al. ²⁵ (2008)	Fresh extraction socket and osteotome sinus floor elevation	Retrospective case series	12	12
Kolhatkar et al. ¹² (2011)	Sinus floor elevation via extraction socket	Retrospective case series	5	5
Bruschi et al. ²⁴ (2013)	Localized management of sinus floor technique in fresh socket	Retrospective case series	53	68
Taschieri and Del Fabbro ³¹ (2011)	Post-extraction osteotome sinus floor elevation using PRGF	Prospective single cohort case series	15	15
McCrea ²⁶ (2012)	Trans-socket elevation/fracture/perforation of sinus floor	Retrospective case series	10	10
Mandelli et al. ²⁹ (2013)	Sinus floor elevation and immediately loaded post-extraction implant	Case report	1	2
Crespi et al. ²⁷ (2013)	Electrical mallet and osteotome sinus floor elevation	Retrospective case series	32	70
Ebenezer et al. ²⁸ (2015)	Indirect sinus lift in immediate implant	Retrospective case series	NM	NM
Falcón ³⁰ (2015)	Post-extraction implant with internal sinus floor elevation	Case report	1	1
Chen et al. ³² (2017)	Transcrestal sinus floor augmentation in fresh extraction socket	Prospective cohort case series	37	37
Liu et al. ¹⁵ (2019)	Sinus floor elevation using the trans-alveolar approach	Randomized controlled trial	68	75
Sun et al. ²¹ (2019)	NM	Case report	1	1

(PRGF: plasma rich in growth factors, NM: not mentioned)

Mehdi Ekhlasmandkermani et al: Sinus floor elevation and simultaneous implant placement in fresh extraction sockets: a systematic review of clinical data. J Korean Assoc Oral Maxillofac Surg 2021

Table 2. Comparison of the reviewed studies regarding the target site, method of tooth extraction, flap/flapless technique, sinus lifting tool, and type of graft material

Study	Target site	Method of tooth extraction	Flap/flapless	Sinus lifting tool	Graft material used
Artzi et al. ³³ (2003)	Molar	Root hemisection, elevator, forceps	Flap	Osteotome	Synthetic beta-tricalcium phosphate xenograft
Barone et al. ²⁵ (2008)	Premolar	NM	Full thickness with vertical release	Osteotome	Mixture of collagen gel and porcine bone particles
Kolhatkar et al. ¹² (2011)	Premolar	Periotome and straight elevator	Flap	Osteotome	4 allografts and 1 xenograft
Bruschi et al. ²⁴ (2013)	Molar	Root hemisection	Flapless	Bone expander and mallet	Collagen sheet
Taschieri and Del Fabbro ³¹ (2011)	Premolar	Elevator and forceps	Full-thickness flap	Piezosurgery and osteotome	PRGF
McCrea ²⁶ (2012)	Canine and premolar	Periotome	Full-thickness flap	Osteotome	None
Mandelli et al. ²⁹ (2013)	Premolar	NM	Flapless	Osteotome	Xenograft
Crespi et al. ²⁷ (2013)	36 molars and 34 premolars	Molar hemisection	Flapless or partial flap to mobilize, if necessary	Osteotome and electrical mallet	NM
Ebenezer et al. ²⁸ (2015)	NM	NM	NM	Osteotome	NM
Falcón ³⁰ (2015)	Premolar	Periotome and elevator	Flapless	Osteotome	
Chen et al. ³² (2017)	Molar	Root hemisection and intra-radicular drilling	Flapless	Specific membrane separating instruments and evaluation with endoscope-guided technique	Gelatin sponge and bone powder
Liu et al. ¹⁵ (2019)	Molar	NM	Full thickness with vertical release	Osteotome	None
Sun et al. ²¹ (2019)	Molar	NM	Flapless	NM	Bio-Oss collagen with PRF

(NM: not mentioned, PRGF: plasma rich in growth factors, PRF: platelet-rich fibrin)

Mehdi Ekhlasmankhaneh et al: Sinus floor elevation and simultaneous implant placement in fresh extraction sockets: a systematic review of clinical data. *J Korean Assoc Oral Maxillofac Surg* 2021

patients were evaluated. Six studies reported the mean age of the patients^{15,24,27,31-33}. Four studies mentioned only the age range of patients (youngest and oldest)^{12,25,26,28}. Three studies evaluated only one patient and provided their exact age^{21,29,30}. In the 13 reviewed studies, the youngest patient was 18 years, and the oldest was 74 years.

3. How many implants were placed in extraction sockets using immediate implant placement and simultaneous sinus lifting?

Overall, 306 implant fixtures were placed in 245 patients. The number of patients matched the number of inserted implants in eight studies^{12,21,25,26,30-33}. In one study³³, 10 implants were placed for 10 patients; out of which 8 were considered to be fresh socket implant placements simultaneous with sinus floor elevation, whereas in 2 cases, radiographs revealed that (in contrast to the researcher's belief at the time of surgery) the sinus membrane had not actually been elevated.

In four studies, the number of implants placed was greater than the number of patients^{15,24,27,29}. In one of those studies²⁹, despite the immediate placement of two implants in one patient, only one was accompanied by sinus lifting. Another study did not report the number of implants placed²⁸. In one study²⁷, both premolar and molar sites underwent sinus lifting. Four studies^{15,24,32,33} evaluated only molar sites, and four studies^{12,29-31} evaluated only premolar sites. In the randomized controlled trial, implant placement was performed for 33 patients immediately after tooth extraction and sinus lifting (test group), whereas the other 35 patients received implant placement and sinus lifting three months after tooth extraction (control group)¹⁵. Even though sinus floor elevation is more commonly performed in the premolar and molar regions, one study reported performing sinus floor elevation at the canine site, in addition to the premolar site²⁶.

Table 3. Comparison of the reviewed studies regarding the method of coronal coverage of the socket, pre- and postoperative complications, healing period, two-stage or one-stage surgery, and frequency of failure

Study	Method of coronal coverage of the socket	Pre- and postoperative complications	Healing period (mo)	Two-stage/one stage	Frequency of failure
Artzi et al. ³³ (2003)	Healing abutment and coronal repositioning of flap around its neck	Epistaxis in 2 patients, micro-perforation of the sinus during surgery	6	One stage	None
Barone et al. ²⁵ (2008)	Release of periosteum and suturing the flap around the implant neck	Pain and swelling	6	2 stage	1 early failure 6 wk postoperatively
Kolhatkar et al. ¹² (2011)	2 cases of healing abutment, 3 cases of suturing	None	5-6	One stage in 2 patients and two-stage in 3 patients	None
Bruschi et al. ²⁴ (2013)	Collagen sheet	Pain, swelling, and epistaxis (resolved after 24 to 48 hr)	5	Two stage	None
Taschieri and Del Fabbro ³¹ (2011)	Mucous membrane or PRGF	None	3-4	Two stage	None
McCrea ²⁶ (2012)	Coronal repositioning of flap, healing abutment, adhesive bridge	None	6	One stage in 2 patients and two-stage in 8 patients	None
Mandelli et al. ²⁹ (2013)	Temporary restoration, leaving it out of occlusion	None	5	One stage (temporary restoration)	None
Crespi et al. ²⁷ (2013)	Suturing the collagen piece and tissue covering the implant	Pain, swelling, and epistaxis (resolved after 24 to 48 hr)	5	Two stage	1 early failure 1 mo postoperatively
Ebenezer et al. ²⁸ (2015)	Immediate temporary restoration and immediate loading	NM	4	One stage	None
Falcón ³⁰ (2015)	Suturing	None	6	Two stage	None
Chen et al. ³² (2017)	Palatal slipping flap or ultra-wide healing abutment	1 patient in Group 1: mild rhinosinusitis and cough for 3 days 1 patient in Group 2: fatigue 1 patient in Group 3: fatigue Other patients: toothache	6	One/two stage	None
Liu et al. ¹⁵ (2019)	Healing abutment and suturing	Perforation of the sinus during surgery in two patients in test group and one patient in control group	6	One stage	None
Sun et al. ²¹ (2019)	Healing abutment, loose suturing with PRF coverage	None	6	Two stage	None

(PRGF: plasma rich in growth factors, NM: not mentioned, PRF: platelet-rich fibrin)

Group 1: no contact of tooth apex with the sinus floor, Group 2: at least one tooth root was in contact with the sinus floor without perforating it, Group 3: at least one tooth root inside the sinus cavity.

Mehdi Ekhlasmandkermani et al: Sinus floor elevation and simultaneous implant placement in fresh extraction sockets: a systematic review of clinical data. J Korean Assoc Oral Maxillofac Surg 2021

4. Did the existence of an infected tooth have any effect on the treatment outcomes?

Six articles did not mention the probable existence of infection in the sockets^{15,21,25,28,30,31}; four articles did not have any infected teeth in their patients^{15,21,24,29}, and three studies excluded infected cases^{15,32,33}. In three studies, prophylactic antibiotics were recommended^{12,15,27}. In the two of them that included periapical radiolucencies or endodontal lesions, the survival rates were similar in infected and non-infected sites¹². Among the 70 dental implants installed in patients

with a possible history of endo/periodontal disease, one fixture failed, but the exact etiology of that failure was not mentioned²⁷.

5. Was flap surgery or the flapless technique adopted for tooth extraction and accessing the site of sinus lifting?

Three studies reported using a Periotome for atraumatic tooth extraction^{12,27,30}. Four studies did not mention the instruments used for tooth extraction^{21,25,28,29}. Routine instruments available for tooth extraction, such as elevators and forceps,

Table 4. Comparison of the reviewed studies regarding the follow-up period, method of measuring bone changes, baseline alveolar bone height, distance from the tooth apex to sinus floor, and magnitude of surgical sinus floor elevation

Study	Follow-up period	Method of measuring bone changes	Mean baseline alveolar bone height (mm)	Distance from tooth apex to sinus floor (mm)	Magnitude of surgical sinus floor elevation (mm)
Artzi et al. ³³ (2003)	2 yr	PA with surgical template	7.8 (6-9)	NM	NM
Barone et al. ²⁵ (2008)	18 mo	PA with occlusal stent	7.8±1.9	Minimum of 2	Distance from sinus floor to implant apex: 4.2±1.4
Kolhatkar et al. ¹² (2011)	6-12 mo	PA or panoramic radiography	NM	<1 or 2	NM
Bruschi et al. ²⁴ (2013)	9.76±5.27 yr	PPA with occlusal template and reference point	6.02±0.75	NM	NM
Taschieri and Del Fabbro ³¹ (2011)	35.6 mo (24-50 mo)	PA	Minimum of 7	NM	2.9±0.8
McCrea ²⁶ (2012)	12-36 mo	PA	NM	NM	NM
Mandelli et al. ²⁹ (2013)	4 yr	PA	5	NM	NM
Crespi et al. ²⁷ (2013)	2 yr	PPA with occlusal template	6.55±1.34	NM	NM
Ebenezer et al. ²⁸ (2015)	NM	-	NM	NM	NM
Falcón ³⁰ (2015)	12 mo	PA	NM	2	NM
Chen et al. ³² (2017)	12 mo	PA and CBCT	Distance from coronal inter-radiaricular crest to sinus floor: Group 1: 6.60±1.01 Group 2: 5.33±0.63 Group 3: 4.54±0.64	NM	NM
Liu et al. ¹⁵ (2019)	12 mo	CBCT	4.7±0.52 (test group) 4.9±0.63 (control group)	NM	NM
Sun et al. ²¹ (2019)	None	PPA	6	4	NM

(PA: periapical radiography, NM: not mentioned, PPA: parallel periapical radiography, CBCT: cone-beam computed tomography)

Group 1: no contact of tooth apex with the sinus floor, Group 2: at least one tooth root was in contact with the sinus floor without perforating it, Group 3: at least one tooth root was inside the sinus cavity.

Values are presented as mean (range) or mean±standard deviation.

Mehdi Ekhlasmankhermani et al: Sinus floor elevation and simultaneous implant placement in fresh extraction sockets: a systematic review of clinical data. *J Korean Assoc Oral Maxillofac Surg* 2021

were used in the remaining studies. Among the 13 studies, one did not provide any information about the type of flap²⁸, and 6 studies adopted the flapless technique^{21,24,27,29,30,32}. In the six other studies, a full-thickness flap was elevated^{12,15,25,26,31,33}.

6. What instrument was used for sinus floor elevation?

An osteotome with a hand mallet was used for sinus floor elevation in nine studies^{12,15,25,26,28,29,30,31,33}. However, in one study, piezosurgery was performed first to reach the Schneiderian membrane, and then the sinus membrane was elevated using an osteotome³¹. In another study, an osteotome was used with an electrical mallet to control the force²⁷. In one study, a bone expander was used with a mallet, which was believed to be similar to traditional osteotomes²⁴. However, in two studies, rounded drills were used to reach the intact sinus membrane, and then various instruments were used to detach and elevate it^{15,32}.

7. Were graft materials or bone substitutes used for sinus floor elevation or to fill the gap between the implant and bony socket walls?

Three of the 13 studies did not mention whether or not they used grafts or biomaterials^{27,28,30}. Of the remaining 10 articles, two studies reported placing no graft material beneath the sinus membrane^{15,26}. One study used plasma rich in growth factors (PRGF) as an autograft for sinus membrane elevation³¹. One study placed a collagen sheet beneath the sinus membrane²⁴, and two studies used collagen compounds along with a xenograft^{25,32}. One study used only a xenograft²⁹. Another study used a xenograft or synthetic beta-tricalcium phosphates³³, whereas another article reported using a xenograft in some cases and an allograft in others¹². Only one article placed a xenograft with platelet rich fibrin (PRF) in the space between the implant and the socket walls²¹.

Table 5. Comparison of the reviewed studies regarding the implant height and bone height/bone gain and bone loss after the healing period and during the follow-up period

Study	Implant height (mm)	Mean bone height/ bone gain after the healing period (mm)	Bone height/bone gain during the follow-up period after prosthesis delivery (mm)	Bone loss after the healing period (mm)	Bone loss during the follow-up period after prosthesis delivery (mm)
Artzi et al. ³³ (2003)	10 or 13	4.3 (2.5-6)	NM	NM	NM
Barone et al. ²⁵ (2008)	10, 11.5, 13	NM	4.2±1.4	No significant bone loss	NM
Kolhatkar et al. ¹² (2011)	12, 13	1-4	NM	No crestal bone loss around implant neck	NM
Bruschi et al. ²⁴ (2013)	13, 15	Mean height of 7.99±1.16	Mean height at 1 yr: 8.05±1.58 Mean height at 2 yr: 8.03±1.49 In long-term: 8.01±1.46	NM	NM
Taschieri and Del Fabbro ³¹ (2011)	NM	NM	NM	NM	At 12 mo: 0.36±0.19
McCrea ²⁶ (2012)	NM	No change was noted in sinus floor bone	NM	NM	NM
Mandelli et al. ²⁹ (2013)	NM	NM	NM	NM	NM
Crespi et al. ²⁷ (2013)	10, 13	At 70 days: 2.63±1.01 At 1 yr: 4.03±1.18 At 2 yr: 4.08±1.25	NM	NM	NM
Ebenezer et al. ²⁸ (2015)	NM	NM	NM	NM	NM
Falcón ³⁰ (2015)	13	Gain: 4.5	NM	NM	NM
Chen et al. ³² (2017)	NM	NM	NM	Mean marginal bone height: 0.63 and 0.73	
Liu et al. ¹⁵ (2019)	NM	NM	NM	Test group: 0.65±0.12 (alveolar bone shrinkage on buccal side) 0.3±0.10 (alveolar bone shrinkage on palatal side) 0.60±0.18 (bone loss in vertical direction on buccal side) 0.24±0.12 (bone loss in vertical direction on palatal side)	Test group: 0.21±0.12 (alveolar bone shrinkage on buccal side) 0.12±0.09 (alveolar bone shrinkage on palatal side) 0.21±0.11 (bone loss in vertical direction on buccal side) 0.15±0.08 (bone loss in vertical direction on palatal side)
Sun et al. ²¹ (2019)	10	NM	NM		NM

(NM: not mentioned)

Values are presented as mean (range) or mean±standard deviation.

Mehdi Ekhlasmandkermani et al: Sinus floor elevation and simultaneous implant placement in fresh extraction sockets: a systematic review of clinical data. J Korean Assoc Oral Maxillofac Surg 2021

8. What was the method of measuring bone and its subsequent changes?

Five of the 13 articles used periapical radiography^{21,26,29,30,31}, and four used periapical radiography along with an occlusal or surgical template to increase the accuracy of measurements^{24,25,27,33}. One study used periapical or panoramic radiography¹². One study used cone-beam computed tomography (CBCT)¹⁵, and another one used both CBCT and periapical radiography³². In one study, one patient had a panoramic radiograph in his records, but the type of radiography used for the other patients was not specified²⁸.

9. What was the alveolar bone height and distance from the tooth apex to the sinus floor at baseline?

Four studies did not specify the primary bone height at baseline^{12,26,28,30}. Table 4 shows the mean primary bone height at baseline in the other studies.

10. What was the magnitude of sinus floor elevation and what implant height was used?

Three studies mentioned the magnitude of sinus floor elevation^{15,25,31}, of which two measured it directly and reported that it was approximately 2.9 mm²⁵, 3.6 mm (case group),

Table 6. Comparison of the reviewed studies regarding the implant survival rate and their conclusions

Study	Survival/ Success rate	Conclusion
Artzi et al. ³³ (2003)	Survival: 100%	A combination of these two techniques as one single procedure yields results comparable to each of the techniques alone in the short-term, decreases the treatment time and cost, and enhances the prosthetic rehabilitation of the posterior maxilla.
Barone et al. ²⁵ (2008)	Success: 91.7%	This technique yields predictable results and enables horizontal and vertical expansion.
Kolhatkar et al. ¹² (2011)	Survival: 100%	Authors provided a decision-making flowchart for clinicians wanting to use the combined technique. This technique shortens the treatment time and is flexible for placement of longer implants close to the sinus.
Bruschi et al. ²⁴ (2013)	Survival: 100%	This technique enables horizontal and vertical expansion and allows for placement of implants with a larger diameter in the maxillary molar area with 100% successful osseointegration that can well tolerate occlusal loads.
Taschieri and Del Fabbro ³¹ (2011)	Success: 100%	This technique can enable safe and efficient sinus floor elevation along with immediate implant placement. Use of PRGF in this technique can stimulate bone regeneration and soft tissue healing and enhance treatment acceptance by patients.
McCrea ²⁶ (2012)	Success: 100%	Same socket/osteotomies can be used as a conduit for modified sinus floor penetration/elevation without the use of an autograft, allograft, or xenograft. This technique significantly shortens the treatment time and decreases the need for further surgical interventions.
Mandelli et al. ²⁹ (2013)	Success and survival: 100%	Sinus lifting simultaneous with fresh socket implant placement decreases the treatment time. The success of this procedure depends on the primary stability of the implant. Splinting two adjacent implants results in predictable osseointegration.
Crespi et al. ²⁷ (2013)	Survival: 98.57%	Use of an electrical mallet for bone condensation is fast, accurate, and cost-effective, and it seems to be a suitable instrument for preparing the upper parts of the socket for simultaneous sinus lifting and implant placement.
Ebenezer et al. ²⁸ (2015)	NM	Indirect sinus lifting with the crestal approach using an osteotome is simple, non-invasive, and fast. The apical bone pushed into the sinus can serve as a bone graft and tent for the sinus membrane. Also, the bone at the sinus floor can increase the primary stability of the implant.
Falcón ³⁰ (2015)	NM	The flapless technique is less invasive and further decreases the treatment time and postoperative patient discomfort.
Chen et al. ³² (2017)	Survival: 100%	The combination of these two techniques yields predictable results, especially when inter-radicular bone is used. The relationship between the molar root and sinus can have an inverse correlation with the radicular bone height and a direct correlation with the sinus floor thickness. Normally, the sinus membrane thickness increases postoperatively due to the formation of a blood clot and the infiltration of goblet cells, which returns to normal after the healing period. Root infection is an odontogenic factor responsible for increased membrane thickness. Eliminating the infected root allows the membrane to become thin again.
Liu et al. ¹⁵ (2019)	Survival: 100%	Immediate implant placement combined with maxillary sinus floor elevation using the trans-alveolar approach and non-submerged healing is feasible for the maxillary molar area, and the clinical effect is satisfactory.
Sun et al. ²¹ (2019)	NM	Flapless, immediate implant placement into a fresh molar socket with PRF is a feasible procedure. PRF promotes bone and soft tissue regeneration and has anti-inflammatory properties. In addition, the procedure involves a minimally invasive technique that reduces surgical complexity.

(PRGF: plasma rich in growth factors, NM: not mentioned, PRF: platelet-rich fibrin)

Mehdi Ekhlasmandkermani et al: Sinus floor elevation and simultaneous implant placement in fresh extraction sockets: a systematic review of clinical data. *J Korean Assoc Oral Maxillofac Surg* 2021

and 3.4 mm (control group)¹⁵. The other study³¹ estimated the magnitude of sinus floor elevation to be 4.2 mm by measuring the approximate distance from the implant apex to the sinus floor. Seven studies mentioned the implant height^{12,21,24,25,27,30,33}. The most common implant height in all the reviewed studies was 13 mm; the shortest implant was 10 mm, and the longest was 15 mm.

11. What were the changes in bone height, both bone gain and bone loss, during the healing phase and follow-up periods?

Six studies evaluated the effect of using or not using bone grafts on the amount of bone gain, and their results can be categorized into two groups^{12,24,25,31-33}. The first group, which reported bone gain, included the following studies. A study that used collagen sponges alone²⁴ and reported that the mean bone height at baseline (time of surgery) was 6.02±0.75 mm, which increased to 8.05±1.58 mm at the one-year follow-up and remained constant at 8.01±1.46 mm thereafter. An-

other study used a combination of collagen and xenograft bone powder²⁵ and reported 4.2±1.4 mm of bone gain at the 18-month follow-up. One study used an allograft in 4 out of 5 patients, and the remaining patient received a xenograft. The amount of bone gain was reported to be 1-4 mm at the 6- and 12-month follow-ups¹². Another study used xenograft or beta tricalcium phosphate, and postoperative radiographs showed 2.5-6 mm of bone gain, with a mean value of 4.3 mm. Those patients showed optimal clinical stability and support of the prosthesis at their 2-year follow-up visits³³.

The second group evaluated crestal bone loss. In 2008, Barone et al.²⁵ reported no significant bone resorption after the placement of 12 implants despite elevating a full-thickness flap. Artzi et al.³³ performed flap surgery for the placement of 12 implants in 2003 and reported no crestal bone resorption around the implant neck. In 2017, Chen et al.³² used the flapless technique to place 37 implants and comprehensively evaluated marginal bone resorption at the 6- and 12-month follow-ups. The mean crestal bone loss was 0.63 and 0.73 mm at the 6- and 12-month follow-ups, respectively³². Taschieri and Del Fabbro³¹ evaluated crestal bone loss in 2011 and reported that the peri-implant bone loss averaged 0.36±0.19 mm at the 12-month follow-up.

12. Is there a suggested treatment plan for covering the coronal area of the socket following implant placement?

In two studies, the presented cases immediately received a temporary prosthesis that sealed the socket opening^{28,29}. Two other studies used collagen sponges as appropriate closures for the socket opening^{27,32}. One study comprehensively discussed the coronal seal²⁶ and used three methods for this purpose: (A) providing mucosal coverage by elevating a flap, (B) using an adhesive bridge, and (C) placing a healing abutment. In some cases, a combination of those techniques (A and B or B and C) was used. In the study that used PRGF³¹, all implants were semi-submerged in mucosal tissue with/without PRGF. In another article, the wound was covered with a PRF membrane and loose sutures²¹. In the remaining cases^{12,15,25,26,30,32,33}, the socket was partially sealed by suturing or the use of healing abutments. Of the studies that used sutures, one study reported using the palatal slipping flap technique for coronal coverage of the socket in some cases³². Another study released the flap and sutured it at the coronal part of the socket and then fabricated a temporary fixed prosthesis to prevent trauma to the surgical site; after 2 to 3 weeks, it was replaced with a removable prosthesis²⁵.

13. Was there any complication during or after the surgical procedure?

Seven studies did not report any peri- or postoperative complications^{12,21,26,28-31}. One study divided patients into three groups according to the distance from the apex to the sinus floor³² and reported that one patient in group 1 developed mild rhinosinusitis and cough in the first three days postoperatively, one patient from group 2 and one patient from group 3 developed fatigue, and other patients reported dental pain. Two studies reported sinus membrane perforation during the surgical procedure in two (test group) and one (control group)¹⁵ and three³³ patients. Nasal bleeding was also reported in two patients in the same study³³. Two other studies reported pain and swelling as well as nasal bleeding postoperatively^{24,27}, but they also reported that those symptoms resolved within 24 to 48 hours without significant complication. Another study reported only pain and swelling postoperatively²⁵.

14. How long was the healing period and prosthetic phase until the delivery of final restoration?

Nine studies did not attach a temporary prosthesis to the implant platform before delivery of the final restoration^{12,15,21,25,26,30-33}. Two studies by a single group of researchers^{25,27} fabricated a temporary prosthesis 70 days after implant placement and then delivered the final prosthesis 2 to 3 months after that. In two other studies, the treatment was accomplished by immediate delivery of a fixed prosthesis temporarily connected to the implant^{28,29}. In one of them, the crown was out of the occlusion²⁹ and in the other, it was loaded immediately²⁸. In terms of time lapse until restoration, one study reported 3 to 4 months³¹, another indicated 4 months²⁸, three studies mentioned 5 months^{24,28,29}, seven studies^{15,21,25,26,30,32,33} reported 6 months, and one study¹² reported 5 to 6 months between the surgical procedure and final restoration.

15. How many implants failed during the healing or follow-up period and what was the survival rate or success rate of implants during the follow-up period?

In 10 articles, all the implants were stable during the healing and follow-up periods with no failures^{12,15,21,24,26,29-33}. One study did not specify the number of patients or implants and only mentioned the successful management of the cases²⁸.

Failures were reported in two studies^{25,27}, which were both case-series. One of them reported the failure of 1 out of 12 implants due to infection and abscess²⁵ that occurred 6 weeks after the surgical procedure and was categorized as an early failure. In the other study²⁷, 1 out of 70 implants failed one month after placement, and it was successfully replaced with another implant after 6 months. Thus, those two studies reported a 91.7% success rate²⁵ and 98.57% survival rate²⁷ for the implants. In other studies, both those rates were 100%^{12,15,21,24,26,29,31-33} or no information about the survival or success rate was given^{28,30}.

16. What was the duration of follow-up and the frequency of recall sessions after the primary healing period, and what was the frequency of repeated radiographs until manuscript submission?

Two studies reported regular recall sessions from the time of surgery until delivery of the final prosthesis^{12,25}. In one of them²⁵, the postoperative patients were followed up monthly for up to 6 months for prophylaxis. After delivery of the final prosthesis, all patients showed up for regular recall sessions after 2 to 4 months. The duration of follow-up was 18 months, and radiographic examinations were carried out at 6 and 18 months postoperatively. In the second study¹², the recall sessions were scheduled at 2 weeks, 2 months, and 5 months during the healing period. The final prosthesis was delivered 6 to 14 months postoperatively. After that, all patients were followed up at 6 and 12 months. One study mentioned only the time of delivery of the final prosthesis at 4 months postoperatively²⁸ and did not mention the tim-

ing of the other follow-up sessions. Three studies followed up with patients at 12 months^{15,30,32} without mentioning the frequency of recall sessions during that time period. Two other studies reported a final follow-up visit with patients at 2 years^{27,33} but did not mention recall sessions during that period. In two studies conducted by a single group of researchers^{24,27}, the recall sessions and radiographic examinations were scheduled at 70 days postoperatively. In one of them²⁷, follow-up and radiographic examinations were scheduled 1 and 2 years later, but in the second study²⁴, the follow-up sessions were scheduled annually after prosthesis delivery for a mean of 9.76 ± 5.27 years (range, 4-17 years). In one study, radiography was performed at the time of prosthesis delivery. Of the 10 patients in that study, 1 was followed up at 12 months, 2 were followed up at 18 months, 4 were followed up at 24 months, 1 was followed up at 30 months, and 2 were followed up at 36 months²⁶. One study reported 4 years of follow-up but did not mention the time interval between recall sessions²⁹. In another study, the prosthesis was delivered 4 months postoperatively, and recall sessions were then scheduled 6 and 12 months after that and continued annually, with a mean follow-up time of 35.6 months (range, 24-50 months)³¹. In only one study, there were no recall sessions after definitive restoration delivery²¹.

17. Quality assessment

Our assessment of the risk of bias is presented in Fig. 2. Most of the 11 non-randomized studies reported a low risk of bias in confounding. The three highest values with a moderate risk of bias were for deviation from the intended inter-

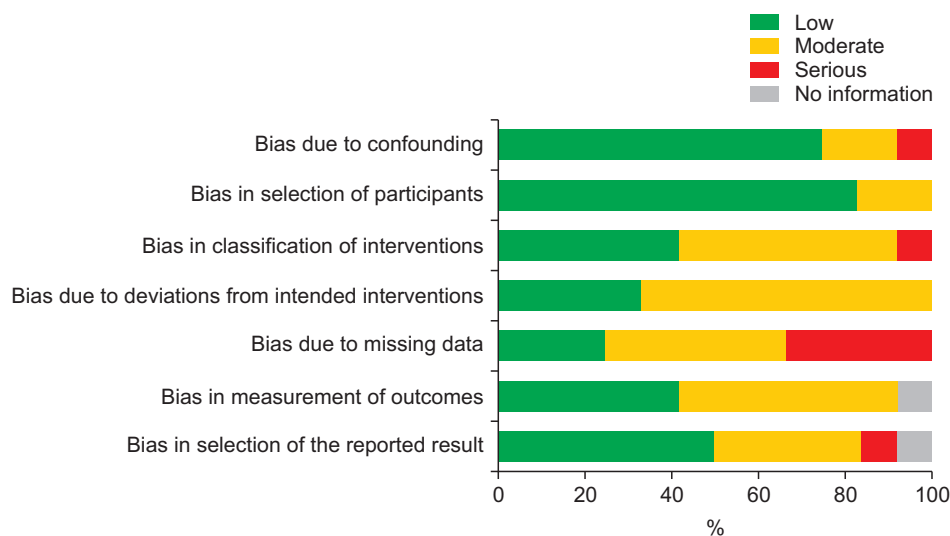


Fig. 2. Risk of bias assessment in non-randomized clinical studies. Mehdi Ekhlasmandkermani et al: Sinus floor elevation and simultaneous implant placement in fresh extraction sockets: a systematic review of clinical data. J Korean Assoc Oral Maxillofac Surg 2021

vention (67%), classification of intervention and outcome measurements (50%), and missing data (42%). For the only randomized controlled trial, blinding of the outcome assessment was evaluated as high risk. Besides randomization bias, which presented a low risk, other criteria were reported to carry a moderate risk of bias. Considering all the values related to the risk of bias assessment, the studies included were categorized as being of moderate quality.

IV. Discussion

Sinus floor elevation with a crestal approach can be performed through the site of a healed extraction socket in an edentulous posterior maxilla (Summers' technique) or through a fresh extraction socket as explained by Fugazzotto³⁴ in 1999. Immediate implant placement in a fresh extraction socket at the same time as sinus floor elevation through that socket has been attempted only since 2000³³.

This relatively new approach has combined tooth extraction, socket healing, sinus floor elevation to increase bone height, and implant osseointegration into a single procedure¹⁵. Analyzing all the documented data collected in different studies on this topic can enhance our understanding of this technique.

The characteristics required for the success of immediate implant placement in the clinical setting include (I) atraumatic tooth extraction, (II) sterile and minimally invasive surgical procedures, and (III) adequate primary stability of the implant^{35,36}. Of those three parameters, atraumatic tooth extraction is an important starting point because preservation of the bony socket walls is critical for achieving maximum bone formation around an implant placed in a fresh extraction socket. What matters most during tooth extraction is the precision needed to prevent traumatization of the socket.

Our aim in this systematic review was to review different techniques and determine their advantages and disadvantages for immediate implant placement and sinus floor elevation through a fresh extraction socket in the posterior maxilla.

1. Flap versus flapless approach

The elevation of a full-thickness flap can be associated with a higher risk of crestal bone resorption³⁷. On the other hand, flapless surgery can cause errors in correct implant placement due to inadequate visualization of the surgical site³⁸. Three sources, the PDL, bone marrow, and external periosteum, provide blood supply to the buccal bone around

the teeth^{39,40}. Following tooth extraction, the blood supply provided by the PDL is no longer available. A thin buccal plate is mainly composed of cortical bone, so in those cases, the periosteum would be the only source of blood supply to the buccal bone plate⁴¹. Therefore, elevating a flap can impair the blood supply to the buccal bone plate provided by the periosteum³⁷, which can aggravate resorption of the buccal bone plate following tooth extraction⁴¹. Faster soft-tissue healing, decreased perioperative hemorrhaging, shorter surgical time, and less patient discomfort postoperatively are other advantages of flapless surgery. On the other hand, the surgical procedure in flapless surgery is performed blindly, which can lead to fenestration of the osteotomy site and implant mispositioning^{42,43}. A meta-analysis conducted in 2014 compared the flap and flapless surgical procedures for implant placement in healed extraction sockets and indicated that the risk of implant failure was higher in flapless surgery in most of the reviewed studies³⁸. It should be noted that in immediate implant placement, the coronal part of the socket allows adequate visualization of implant placement in the alveolar housing, and the soft and hard tissue conditions are favorable, so there would be no need to elevate a flap unless the surgeon wanted to reposition the flap coronally to cover the coronal part of the socket. In that case, there would be no need to elevate a full-thickness flap because a partial-thickness flap would serve that purpose. Therefore, it seems that crestal bone resorption following flap elevation in immediate implant placement is a more important issue than mispositioning of the implant.

In this review, an equal number of studies used the flap technique^{12,15,25,26,31,33} and flapless surgery^{21,24,27,29,30,32}, although more implants were placed with the flapless technique (173 implants) than via flap surgery (125 implants). Implant failure occurred with both techniques.

The correlation between crestal bone resorption and flap/flapless surgery was also previously reviewed⁴⁴. Those results showed that the mean magnitude of resorption was less than 1 mm or not significant^{25,31-33}. According to the implant success criteria, that amount of resorption is within the clinically acceptable range⁴⁵. Moreover, a study conducted in 2017 found no significant difference in ridge resorption following immediate implant placement with the flap or flapless technique⁴¹, which is in agreement with our findings.

2. Sinus lifting techniques

Since the introduction of the closed sinus lift technique

with the crestal approach⁸, osteotomes have been conventionally used for this purpose. In 2005, a meta-analysis reported 95.7% and 96% success/survival rates at 24 and 36 months, respectively, following implant placement with the osteotome technique, and those rates were similar to those with conventional implant placement in a partially edentulous posterior maxilla⁴⁶. However, another study reported that the risk of membrane perforation posed by techniques such as the hydraulic sinus lift procedure at the crestal site was less than that with the conventional use of osteotomes⁹.

Osteotome use can be accompanied by some complications. The mallet strokes used in the original crestal technique to create a “green stick” fracture and access the sinus membrane can cause discomfort and complications for patients⁴⁷. However, osteotomes are still popular for crestal sinus lifting, such that in 10 out of the 13 studies reviewed here, an osteotome was the main instrument used for sinus floor elevation^{12,15,25-31,33}. One study used an electrical mallet instead of a hand mallet because the authors believed that it enabled better control of the force applied to the osteotome and decreased postoperative patient discomfort by decreasing trauma to the bone and craniofacial structures²⁷. The authors in one of the reviewed studies used specific separating instruments to elevate the sinus membrane and reported no sign of membrane perforation during surgery³². Only two studies mentioned perforation of the sinus membrane during surgery, but they also reported that it caused no implant failure during one-year¹⁵ and two-years of follow-up¹². According to the available evidence, particularly a systematic review conducted in 2016, membrane perforation is the most common complication of sinus lifting, but no significant association has been found between the implant success rate and sinus membrane perforation⁴⁸. Therefore, use of osteotomes is still the gold standard for the crestal approach.

In 1994, Summers⁸ suggested that a minimum of 5-6 mm of residual bone height is required to ensure primary stability of the implant. Measuring the primary bone height beneath the sinus floor is easier in a healed edentulous ridge than in a fresh extraction socket. The references used for such measurements might be different in fresh extraction sockets, which is one of the limitations to accurately measuring bone changes when performing sinus lifting through an extraction socket. Our data indicate that the minimum residual bone height relative to the inter-radicular crest (as reference) was 4.54 ± 0.64 mm³². That value was 5 mm when the interproximal crest served as the reference²⁹. Neither of those studies reported any implant failures. A systematic review in 2014

reported that a bone height less than 4 mm was associated with a lower success rate with the osteotome technique¹⁰. In contrast, a meta-analysis conducted in 2018 showed that the survival rate of implants placed in residual bone with ≤ 4 mm of height was only slightly lower than that of implants placed in residual bone with >4 mm of height⁴⁹. It seems that the amount of residual bone between the apex and the sinus floor and the amount of inter-radicular bone are more important to primary implant stability and the failure rate than the proximal bone level. Implant failure was reported in only two cases in the articles reviewed here. In one of the failed cases²⁵, the minimum bone thickness between the tooth apex and sinus floor was only 2 mm but was deemed adequate for primary stability of the implant, and the reason for failure after six weeks was infection and abscess, not inadequate primary stability. The other study that reported a failed case mentioned nothing about the distance from the tooth apex to the sinus floor, nor did it specify the reason for implant failure²⁷. However, it should be noted that in our study, similar to the meta-analysis conducted in 2018⁴⁹, measurements were made on periapical or panoramic radiographs; only one study used CBCT with periapical radiography for that purpose³², which could limit the accuracy of the reviewed results.

For vertical and horizontal bone expansion, osteotomes²⁵, bone expanders and mallets²⁴, and expander screws⁵⁰ were applied in premolar, molar, and both premolar and molar sites, respectively. The overall results with these methods showed survival and success rates comparable to those of standard surgery, ranging from 95% to 100%, indicating that the choice of devices does not have a notable effect on the outcomes. Also, a recent study showed that transcresal sinus floor elevation has no negative effect on the long-term survival rate of implants⁵¹.

3. Graft materials

The application of graft materials below the sinus membrane following its elevation is a challenging topic in sinus lifting with the crestal approach⁵². Some of the studies reviewed here evaluated how using or not using graft materials affected bone gain, bone loss, and the survival and success rates of implants^{48,53}.

Two reasons have been suggested for new bone formation in a sinus cavity that has undergone sinus floor elevation using an osteotome: osteogenic activity after a mini-fracture of bone at the sinus floor and the role of mesenchymal cells present in the Schneiderian membrane⁵⁴. Therefore, maintain-

ing the sinus membrane in an elevated position, either with graft materials and bone substitutes or by the implant apex, can trigger new bone formation beneath the membrane so long as the blood clot is preserved¹¹. A randomized clinical trial in 2013 evaluated the survival rates of implants with and without grafting and reported similar residual bone heights and survival rates of 95.2% and 95%, respectively⁵⁴. The marginal bone loss did not differ significantly between the two groups after 3 years, but the amount of bone gain in the graft group was significantly higher than that in the no graft group after 6 months. However, bone gain significantly decreased after 3 years in the graft group, whereas it continued to grow slowly in no-graft group. At the 3-year follow-up, the final volume of bone within the sinus was equal in the two groups (around 3 mm)⁵⁴. Nonetheless, a meta-analysis conducted in 2018⁴⁹ reported that the results of studies about bone gain supported the use of graft materials beneath the sinus membrane. In this meta-analysis⁴⁹, the amount of marginal bone loss in the bone graft group was slightly higher than that in the no-graft group, but that difference was not significant. However, the amount of bone gain did differ significantly between the groups. No significant difference was found in the implant survival rate with the use and non-use of a bone graft beneath the sinus membrane, which was in agreement with the findings of a meta-analysis conducted in 2017¹¹. In this review, we evaluated studies that performed sinus lifting with and without the placement of bone grafts, but more studies used an autogenous bone graft²⁹, bone substitute^{12,21,25,29,32,33}, or collagen sponges²⁴ than did not place any biomaterial beneath the sinus membrane²⁶. All studies that reported bone gain used some sort of collagen material or bone substitute beneath the sinus membrane. However, it is noteworthy that in the only study that used PRGF to keep the sinus membrane elevated, the elevation averaged 2.9±0.8 mm, but the amount of bone gain was not mentioned at the time of prosthesis delivery or the follow-up sessions³¹. Therefore, our results are in line with the findings of a recent meta-analysis⁴⁹ that showed that greater increase in bone height can be expected when using bone grafts.

V. Conclusion

Sinus floor elevation through a fresh extraction socket and simultaneous immediate implant placement seems to be a proper treatment choice and has noticeably high success. Nevertheless, case selection and the capability of the clinician are important factors.

1. Clinical recommendations

Controlled clinical trials are seriously lacking on this topic and are therefore recommended. Calculating important data, including initial bone height, amount of sinus lifting, clinical and radiographic criteria pertaining to the success of implants, follow-up to the prosthetic and loading phases, and split mouth designs, are suggested for further studies. Also, some important factors such as patient-oriented outcomes, digital workflow, and presence of sinus septa in the apical socket should be emphasized in further research.

ORCID

Mehdi Ekhlasmandkermani, <https://orcid.org/0000-0002-0456-1740>

Reza Amid, <https://orcid.org/0000-0002-8053-3928>

Mahdi Kadkhodazadeh, <https://orcid.org/0000-0002-6131-2791>

Farhad Hajizadeh, <https://orcid.org/0000-0003-0608-6100>

Pooria Fallah Abed, <https://orcid.org/0000-0003-0219-7559>

Lida Kheiri, <https://orcid.org/0000-0001-9471-9902>

Aida Kheiri, <https://orcid.org/0000-0002-5311-1260>

Authors' Contributions

All authors have participated in the study. The concept and study design were done by M.E. L.K. and A.K. participated in data collection and wrote the manuscript. F.H. and P.F.A. participated in data analysis. The study was revised critically by M.K. The final approval was performed by R.A.

Acknowledgements

This research did not receive any specific grant from any funding agency in the public, commercial, or not-for-profit sector.

Conflict of Interest

No potential conflict of interest relevant to this article was reported.

References

1. Valiense H, Barreto M, Resende RF, Alves AT, Rossi AM, Ma-

- vropoulos E, et al. In vitro and in vivo evaluation of strontium-containing nanostructured carbonated hydroxyapatite/sodium alginate for sinus lift in rabbits. *J Biomed Mater Res B Appl Biomater* 2016;104:274-82. <https://doi.org/10.1002/jbm.b.33392>
2. Al-Shabeeb MS, Al-Askar M, Al-Rasheed A, Babay N, Javed F, Wang HL, et al. Alveolar bone remodeling around immediate implants placed in accordance with the extraction socket classification: a three-dimensional microcomputed tomography analysis. *J Periodontol* 2012;83:981-7. <https://doi.org/10.1902/jop.2011.110569>
 3. Johnson K. A study of the dimensional changes occurring in the maxilla following tooth extraction. *Aust Dent J* 1969;14:241-4. <https://doi.org/10.1111/j.1834-7819.1969.tb06001.x>
 4. Fugazzotto PA, Wheeler SL, Lindsay JA. Success and failure rates of cylinder implants in type IV bone. *J Periodontol* 1993;64:1085-7. <https://doi.org/10.1902/jop.1993.64.11.1085>
 5. das Neves FD, Fones D, Bernardes SR, do Prado CJ, Neto AJ. Short implants—an analysis of longitudinal studies. *Int J Oral Maxillofac Implants* 2006;21:86-93.
 6. Riben C, Thor A. The maxillary sinus membrane elevation procedure: augmentation of bone around dental implants without grafts - a review of a surgical technique. *Int J Dent* 2012;2012:105483. <https://doi.org/10.1155/2012/105483>
 7. Boyne PJ, James RA. Grafting of the maxillary sinus floor with autogenous marrow and bone. *J Oral Surg* 1980;38:613-6.
 8. Summers RB. A new concept in maxillary implant surgery: the osteotome technique. *Compendium* 1994;15:152, 154-6, 158 passim; quiz 162.
 9. Pawar SK, Pawar HS, Sapra N, Ghangas P, Sangwan R, Chawla R. Maxillary sinus floor elevation techniques with recent advances: a literature review. *Asian Pac J Health Sci* 2017;4:112-29. <https://doi.org/10.21276/apjhs.2017.4.1.20>
 10. Călin C, Petre A, Drafta S. Osteotome-mediated sinus floor elevation: a systematic review and meta-analysis. *Int J Oral Maxillofac Implants* 2014;29:558-76. <https://doi.org/10.11607/jomi.3206>
 11. Moraschini V, Uzeda MG, Sartoretto SC, Calasans-Maia MD. Maxillary sinus floor elevation with simultaneous implant placement without grafting materials: a systematic review and meta-analysis. *Int J Oral Maxillofac Surg* 2017;46:636-47. <https://doi.org/10.1016/j.ijom.2017.01.021>
 12. Kolhatkar S, Bholia M, Thompson-Sloan TN. Sinus floor elevation via the maxillary premolar extraction socket with immediate implant placement: a case series. *J Periodontol* 2011;82:820-8. <https://doi.org/10.1902/jop.2010.100557>
 13. Schulte W, Heimke G. [The Tübinger immediate implant]. *Quintessenz* 1976;27:17-23. German.
 14. Paolantonio M, Dolci M, Scarano A, d'Archivio D, di Placido G, Tumini V, et al. Immediate implantation in fresh extraction sockets. A controlled clinical and histological study in man. *J Periodontol* 2001;72:1560-71. <https://doi.org/10.1902/jop.2001.72.11.1560>
 15. Liu H, Liu R, Wang M, Yang J. Immediate implant placement combined with maxillary sinus floor elevation utilizing the transalveolar approach and nonsubmerged healing for failing teeth in the maxillary molar area: a randomized controlled trial clinical study with one-year follow-up. *Clin Implant Dent Relat Res* 2019;21:462-72. <https://doi.org/10.1111/cid.12783>
 16. Covani U, Cornelini R, Barone A. Bucco-lingual bone remodeling around implants placed into immediate extraction sockets: a case series. *J Periodontol* 2003;74:268-73. <https://doi.org/10.1902/jop.2003.74.2.268>
 17. Bassir SH, El Kholy K, Chen CY, Lee KH, Intini G. Outcome of early dental implant placement versus other dental implant placement protocols: a systematic review and meta-analysis. *J Periodontol* 2019;90:493-506. <https://doi.org/10.1002/JPER.18-0338>
 18. Mello CC, Lemos CAA, Verri FR, Dos Santos DM, Goiato MC, Pellizzer EP. Immediate implant placement into fresh extraction sockets versus delayed implants into healed sockets: a systematic review and meta-analysis. *Int J Oral Maxillofac Surg* 2017;46:1162-77. <https://doi.org/10.1016/j.ijom.2017.03.016>
 19. Deng F, Zhang H, Zhang H, Shao H, He Q, Zhang P. A comparison of clinical outcomes for implants placed in fresh extraction sockets versus healed sites in periodontally compromised patients: a 1-year follow-up report. *Int J Oral Maxillofac Implants* 2010;25:1036-40.
 20. Grandi T, Guazzi P, Samarani R, Grandi G. Immediate provision-alisation of single post-extractive implants versus implants placed in healed sites in the anterior maxilla: 1-year results from a multi-centre controlled cohort study. *Eur J Oral Implantol* 2013;6:285-95.
 21. Sun XL, Mudalal M, Qi ML, Sun Y, Du LY, Wang ZQ, et al. Flap-less immediate implant placement into fresh molar extraction socket using platelet-rich fibrin: a case report. *World J Clin Cases* 2019;7:3153-9. <https://doi.org/10.12998/wjcc.v7.i19.3153>
 22. Kadkhodazadeh M, Amid R. Implant success index (ISI): a new scoring system to evaluate the clinical outcomes of dental implants. *J Clin Periodontol* 2012;39(Suppl 13):209. <https://doi.org/10.1111/j.1600-051x-2012.01891.x>
 23. Sterne JA, Hernán MA, Reeves BC, Savović J, Berkman ND, Viswanathan M, et al. ROBINS-I: a tool for assessing risk of bias in non-randomised studies of interventions. *BMJ* 2016;355:i4919.
 24. Bruschi GB, Crespi R, Cappare P, Bravi F, Bruschi E, Gherlone E. Localized management of sinus floor technique for implant placement in fresh molar sockets. *Clin Implant Dent Relat Res* 2013;15:243-50. <https://doi.org/10.1111/j.1708-8208.2011.00348.x>
 25. Barone A, Cornelini R, Ciaglia R, Covani U. Implant placement in fresh extraction sockets and simultaneous osteotome sinus floor elevation: a case series. *Int J Periodontics Restorative Dent* 2008;28:283-9.
 26. McCrea SJ. Trans-socket elevation/fracture/perforation of the sinus floor through the "infected" maxillary tooth socket to facilitate bicortical fixation of dental implants. *Clin Adv Periodontics* 2012;2:80-7. <https://doi.org/10.1902/cap.2012.110025>
 27. Crespi R, Cappare P, Gherlone EF. Electrical mallet in implants placed in fresh extraction sockets with simultaneous osteotome sinus floor elevation. *Int J Oral Maxillofac Implants* 2013;28:869-74. <https://doi.org/10.11607/jomi.2679>
 28. Ebenezer V, Balakrishnan R, Nathan S. Indirect sinus lift in immediate placement of implant – a case report. *Biomed Pharmacol J* 2015;8:499-502. <https://doi.org/10.13005/bpj/733>
 29. Mandelli F, Ghensi P, Vinci R, Mandelli G. Sinus floor elevation with crestal approach and immediately loaded post-extraction implants. *J Indiana Dent Assoc* 2013;92:22-4; quiz 25.
 30. Falcón B. Treatment of post-extraction implant with internal sinus floor elevation: a case report. *J Implant Adv Clin Dent* 2015;7:11-5.
 31. Taschieri S, Del Fabbro M. Postextraction osteotome sinus floor elevation technique using plasma-rich growth factors. *Implant Dent* 2011;20:418-24. <https://doi.org/10.1097/ID.0b013e3182354063>
 32. Chen Y, Yuan S, Zhou N, Man Y. Transcrestal sinus floor augmentation with immediate implant placement applied in three types of fresh extraction sockets: a clinical prospective study with 1-year follow-up. *Clin Implant Dent Relat Res* 2017;19:1034-43. <https://doi.org/10.1111/cid.12529>
 33. Artzi Z, Parson A, Nemcovsky CE. Wide-diameter implant placement and internal sinus membrane elevation in the immediate postextraction phase: clinical and radiographic observations in 12 consecutive molar sites. *Int J Oral Maxillofac Implants* 2003;18:242-9.
 34. Fugazzotto PA. Sinus floor augmentation at the time of maxillary molar extraction: technique and report of preliminary results. *Int J Oral Maxillofac Implants* 1999;14:536-42.
 35. Canullo L, Iurlaro G, Iannello G. Double-blind randomized controlled trial study on post-extraction immediately restored implants using the switching platform concept: soft tissue response. Preliminary report. *Clin Oral Implants Res* 2009;20:414-20. <https://doi.org/10.1111/j.1600-0501.2008.01660.x>

36. Ribeiro FS, Pontes AE, Marcantonio E, Piattelli A, Neto RJ, Marcantonio E Jr. Success rate of immediate nonfunctional loaded single-tooth implants: immediate versus delayed implantation. *Implant Dent* 2008;17:109-17. <https://doi.org/10.1097/ID.0b013e318166cb84>
37. Wood DL, Hoag PM, Donnenfeld OW, Rosenfeld LD. Alveolar crest reduction following full and partial thickness flaps. *J Periodontol* 1972;43:141-4. <https://doi.org/10.1902/jop.1972.43.3.141>
38. Chrcanovic BR, Albrektsson T, Wennerberg A. Flapless versus conventional flapped dental implant surgery: a meta-analysis. *PLoS One* 2014;9:e100624. <https://doi.org/10.1371/journal.pone.0100624>
39. Carranza FA Jr, Itoiz ME, Cabrini RL, Dotto CA. A study of periodontal vascularization in different laboratory animals. *J Periodontal Res* 1966;1:120-8. <https://doi.org/10.1111/j.1600-0765.1966.tb01851.x>
40. Divakar TK, Gidean Arularasan S, Baskaran M, Packiaraj I, Dhineksh Kumar N. Clinical evaluation of placement of implant by flapless technique over conventional flap technique. *J Maxillofac Oral Surg* 2020;19:74-84. <https://doi.org/10.1007/s12663-019-01218-9>
41. Mazzocco F, Jimenez D, Barallat L, Paniz G, Del Fabbro M, Nart J. Bone volume changes after immediate implant placement with or without flap elevation. *Clin Oral Implants Res* 2017;28:495-501. <https://doi.org/10.1111/clr.12826>
42. Campelo LD, Camara JR. Flapless implant surgery: a 10-year clinical retrospective analysis. *Int J Oral Maxillofac Implants* 2002;17:271-6.
43. Cai H, Liang X, Sun DY, Chen JY. Long-term clinical performance of flapless implant surgery compared to the conventional approach with flap elevation: a systematic review and meta-analysis. *World J Clin Cases* 2020;8:1087-103. <https://doi.org/10.12998/wjcc.v8.i6.1087>
44. Romero-Ruiz MM, Mosquera-Perez R, Gutierrez-Perez JL, Torres-Lagares D. Flapless implant surgery: a review of the literature and 3 case reports. *J Clin Exp Dent* 2015;7:e146-52. <https://doi.org/10.4317/jced.51985>
45. Albrektsson T, Isidor F. Consensus report of session IV. In: Lang NP, Karring T, eds. *Proceedings of the 1st European Workshop on Periodontology*. Batavia (IL): Quintessence Publishing; 1994:365-9.
46. Emmerich D, Att W, Stappert C. Sinus floor elevation using osteotomes: a systematic review and meta-analysis. *J Periodontol* 2005;76:1237-51. <https://doi.org/10.1902/jop.2005.76.8.1237>
47. Chiarella G, Leopardi G, De Fazio L, Chiarella R, Cassandro C, Cassandro E. Iatrogenic benign paroxysmal positional vertigo: review and personal experience in dental and maxillo-facial surgery. *Acta Otorhinolaryngol Ital* 2007;27:126-8.
48. Silva LD, de Lima VN, Faverani LP, de Mendonça MR, Okamoto R, Pellizzer EP. Maxillary sinus lift surgery-with or without graft material? A systematic review. *Int J Oral Maxillofac Surg* 2016;45:1570-6. <https://doi.org/10.1016/j.ijom.2016.09.023>
49. Yan M, Liu R, Bai S, Wang M, Xia H, Chen J. Transalveolar sinus floor lift without bone grafting in atrophic maxilla: a meta-analysis. *Sci Rep* 2018;8:1451. <https://doi.org/10.1038/s41598-018-19515-7>
50. Kadkhodazadeh M, Moscovichi A, Zamani Z, Amid R. Clinical and radiographic outcomes of a novel transalveolar sinus floor elevation technique. *J Maxillofac Oral Surg* 2020. <https://doi.org/10.1007/s12663-020-01439-3> [Epub ahead of print]
51. Rammelsberg P, Kilian S, Büsch C, Kappel S. The effect of transcrestal sinus-floor elevation without graft on the long-term prognosis of maxillary implants. *J Clin Periodontol* 2020;47:640-8. <https://doi.org/10.1111/jcpe.13278>
52. Parra M, Olate S, Cantín M. Clinical and biological analysis in graftless maxillary sinus lift. *J Korean Assoc Oral Maxillofac Surg* 2017;43:214-20. <https://doi.org/10.5125/jkaoms.2017.43.4.214>
53. Duan DH, Fu JH, Qi W, Du Y, Pan J, Wang HL. Graft-free maxillary sinus floor elevation: a systematic review and meta-analysis. *J Periodontol* 2017;88:550-64. <https://doi.org/10.1902/jop.2017.160665>
54. Si MS, Zhuang LF, Gu YX, Mo JJ, Qiao SC, Lai HC. Osteotome sinus floor elevation with or without grafting: a 3-year randomized controlled clinical trial. *J Clin Periodontol* 2013;40:396-403. <https://doi.org/10.1111/jcpe.12066>

How to cite this article: Ekhlasmandkermani M, Amid R, Kadkhodazadeh M, Hajizadeh F, Abed PF, Kheiri L, et al. Sinus floor elevation and simultaneous implant placement in fresh extraction sockets: a systematic review of clinical data. *J Korean Assoc Oral Maxillofac Surg* 2021;47:411-426. <https://doi.org/10.5125/jkaoms.2021.47.6.411>