

# Fractured osteochondroma presenting with popliteal pseudoaneurysm: Case report and review of literature

Reuben Jian-Yuan Chen, MBBS, MSc,<sup>a</sup> Sara Dawen Qi, MBBS, FRACS,<sup>a</sup> Roel H. D. Vaes, MD, PhD, FEVBS,<sup>a</sup> Claudia Di Bella, MD, PhD, FRACS,<sup>b</sup> and Raoul Mayer, MBBS, FRACS,<sup>a</sup> Melbourne, Victoria, Australia

## ABSTRACT

Osteochondroma, the most common tumor of bone, is usually asymptomatic. Vascular complications are an atypical presentation and include true or false aneurysm formation, deep venous thrombosis, and arterial insufficiency. A review of the English literature identified 130 cases of osteochondroma-related vascular complications. We describe the case of a 38-year-old man presenting with left calf pain and swelling who was diagnosed with the rare constellation of a popliteal pseudoaneurysm and incidental peroneal vein thrombosis secondary to a fractured femoral sessile osteochondroma. This was treated with resection of the osteochondroma, excision of the aneurysm, and primary end-to-end anastomosis of the artery. (*J Vasc Surg Cases and Innovative Techniques* 2020;6:96-100.)

**Keywords:** Osteochondroma; Pseudoaneurysm; Deep venous thrombosis; Popliteal artery; Peroneal vein

Osteochondromas are the most common bone tumors, representing 10% to 15% with an incidence of 3% in the population.<sup>1,2</sup> Most are asymptomatic and discovered incidentally. Rarely, they are manifested with fracture or complications related to compression into adjacent soft tissue.<sup>1,3</sup> Vascular complications are an atypical presentation of osteochondromas and include true or false aneurysms, vascular compression, arterial ischemia, and venous thrombosis.<sup>4</sup> We reviewed the English literature and describe a case of a fractured sessile osteochondroma presenting with a popliteal pseudoaneurysm and incidental peroneal deep venous thrombosis.

## CASE REPORT

A 38-year-old man presented to his local physician with 1 week of pain and swelling of the left thigh and calf. Clinical examination demonstrated a pulsatile expansile mass on the distal medial thigh with intact pedal pulses. The patient had no significant past medical history other than smoking electronic cigarettes and worked as an electrician. An arterial and venous Doppler ultrasound examination demonstrated a large popliteal pseudoaneurysm. Incidentally, a peroneal deep venous thrombus was observed, probably due to local compression and mass effect from the adjacent pseudoaneurysm. The patient was prescribed rivaroxaban for deep venous thrombosis and underwent further investigation with computed

tomography angiography (Fig 1). This demonstrated an osseous lesion projecting posteromedially in continuity with the distal femoral shaft, suggestive of an osteochondroma. Irregular bone cortices with sharp spicules were indicative of fracture. The popliteal artery pseudoaneurysm measured 33 × 33 × 36 mm, with a 4-mm neck that abutted the bone projection. There was normal inflow and outflow with three-vessel runoff to the ankles.

The patient was transferred to a tertiary hospital with both a vascular surgery service and an orthopedics sarcoma service for further management. The bone lesion was considered a benign osteochondroma without malignant features. Nevertheless, given that vascular complications had occurred, resection of the bone lesion with concurrent pseudoaneurysm repair was planned.

A medial supragenicular exposure was performed. Proximal control was obtained at the superficial femoral artery in Hunter canal, and distal control was obtained at the above-knee popliteal artery (Fig 2). After systemic heparinization, the pseudoaneurysm was incised, a moderate amount of thrombus removed, and the redundant vessel wall excised. Given the laxity of the popliteal artery, the artery was repaired by direct end-to-end anastomosis of healthy normal artery (Fig 3). The osteochondroma was noted to be fractured, with a resultant sharp protuberant surface that had punctured the popliteal artery on its anterior surface. It was removed with an osteotome, and the edges were smoothed with a rasp (Fig 4). Postoperative histologic evaluation confirmed the diagnosis of a benign osteochondroma. The patient had an unremarkable recovery and was discharged on postoperative day 7.

The patient consented to the use of medical history and images for educational purposes.

## DISCUSSION

Osteochondromas are common benign bone tumors that tend to be asymptomatic and diagnosed incidentally. Many remain undiagnosed, and reported frequencies are likely to underestimate their true

From the Department of Vascular and Endovascular Surgery,<sup>a</sup> and Department of Orthopaedic Surgery,<sup>b</sup> St Vincent's Hospital.

Author conflict of interest: none.

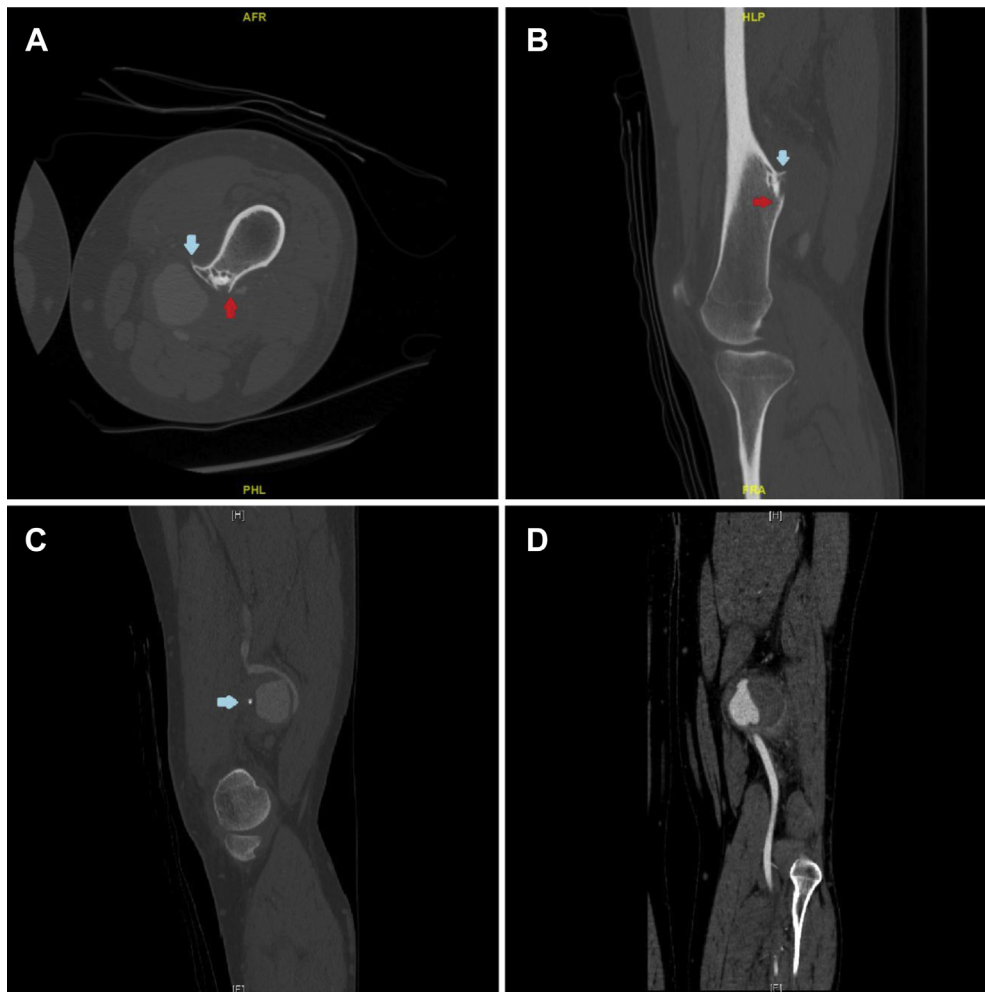
Correspondence: Reuben Jian-Yuan Chen, MBBS, MSc, Department of Vascular and Endovascular Surgery, St Vincent's Hospital, Melbourne, Victoria 3065, Australia (e-mail: reubenchen7@gmail.com).

The editors and reviewers of this article have no relevant financial relationships to disclose per the Journal policy that requires reviewers to decline review of any manuscript for which they may have a conflict of interest.

2468-4287

© 2020 The Author(s). Published by Elsevier Inc. on behalf of Society for Vascular Surgery. This is an open access article under the CC BY-NC-ND license (<http://creativecommons.org/licenses/by-nc-nd/4.0/>).

<https://doi.org/10.1016/j.jvscit.2020.01.003>



**Fig 1.** On computed tomography angiography axial (**A**) and sagittal (**B**) slices, sessile osteochondroma with bone cortical breach representing fracture (*red arrow*) and sharp bone spicule (*blue arrow*). On sagittal (**C**) and coronal (**D**) slices, considerable thrombus fills the pseudoaneurysm sac; however, opacification is seen proximally and distally. A bone spicule (*arrow*) can be seen penetrating the pseudoaneurysm in (**C**).

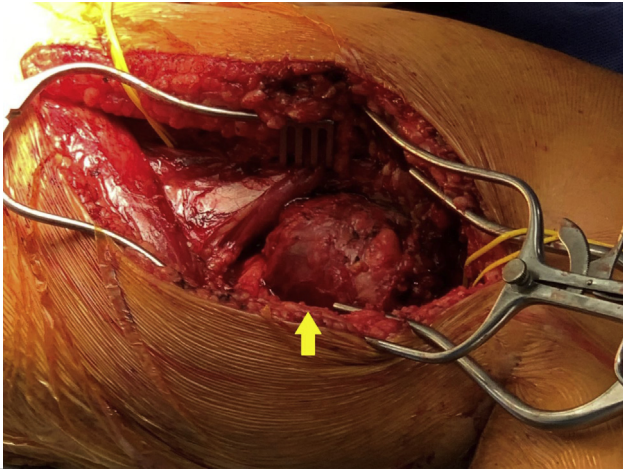
prevalence. Osteochondromas have a soft, pliable cartilage cap that later ossifies. They are usually smooth and rarely cause arterial injury; however, chronic arterial pulsation against the bone prominence may cause vessel wall injury.<sup>4</sup> Rarely, osteochondromas may be complicated by fracture secondary to strenuous physical exercise or trauma, resulting in sharp bone spicules that pierce the artery, causing pseudoaneurysm formation.<sup>3,5-7</sup>

Our review of the English literature identified 130 vascular complications from osteochondroma (Table). Vascular complications were most commonly due to femoral osteochondromas (66.2%); however, other sites included the tibia (15.4%), fibula (7.7%), humerus (5.4%), clavicle (1.5%), ribs (1.5%), pubic ramus (0.8%), scapula (0.8%), and cervical vertebra (0.8%). The popliteal artery was involved in 66% of cases, and popliteal pseudoaneurysms were the most prevalent vascular complication (49%). Nonetheless, pseudoaneurysms of the subclavian, brachial, superficial femoral, medial femoral circumflex,

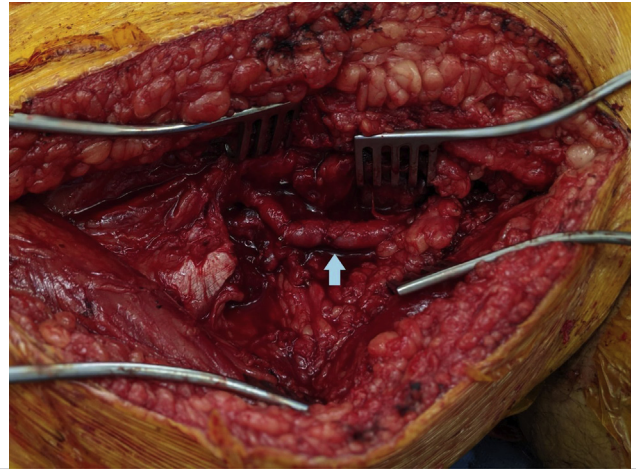
and posterior tibial arteries have also been described.<sup>8-12</sup> The popliteal artery is often injured because of the increased frequency of osteochondromas in the distal femur. Furthermore, the limited mobility of the artery at the proximal adductor canal may facilitate tethering to the osteochondroma.<sup>14</sup> In our case, the pseudoaneurysm manifested as a painful, pulsatile mass; however, pseudoaneurysms may also be manifested with claudication, acute limb ischemia, and rupture.<sup>4,13,14</sup>

Deep venous thrombosis in association with osteochondroma is infrequent.<sup>15</sup> The osteochondroma exerts mass effect on the vein and induces thrombosis. However, in cases of sessile osteochondroma, it has been observed that deep venous thrombosis formation requires additional vascular compression from a concurrent pseudoaneurysm, as occurred in our case.<sup>16</sup>

Various other vascular lesions are described. Lucarelli and Subram<sup>17</sup> reported a case of type IV popliteal entrapment treated with tibial osteochondroma resection and release of popliteus muscle fibrous bands. O'Brien et al<sup>18</sup>



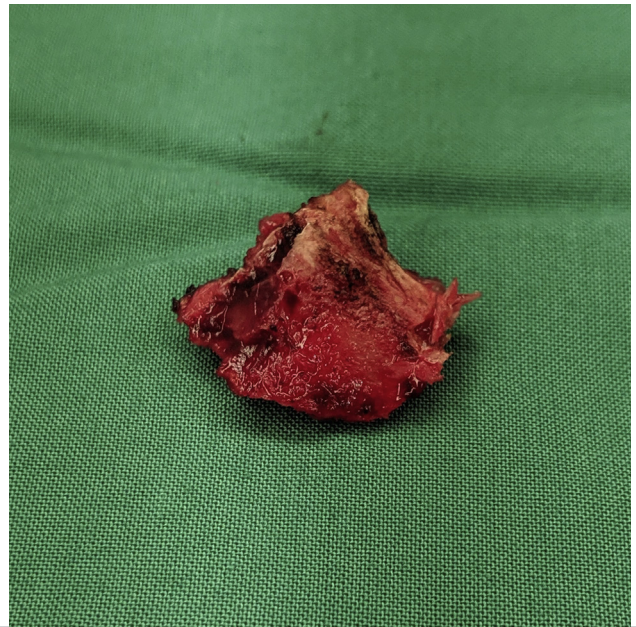
**Fig 2.** Large popliteal pseudoaneurysm (arrow). Medial supragenic exposure.



**Fig 3.** After pseudoaneurysm excision with end-to-end anastomosis (arrow).

reported venous thoracic outlet syndrome with subclavian vein thrombosis from a clavicular osteochondroma. Stroke secondary to osteochondroma has also been described. Gouicem et al<sup>19</sup> described a common carotid artery occlusion from a clavicle osteochondroma that was resected, and Altaf et al<sup>20</sup> described vertebral artery occlusion from a first cervical vertebra osteochondroma managed with anticoagulation. Sethi et al<sup>21</sup> described a popliteal vein aneurysm managed conservatively. One case of arteriovenous fistula in which a popliteal pseudoaneurysm eroded into the accompanying vein has been reported. Aneurysm resection with end-to-end anastomosis and repair of the vein defect was done. Notably, the causative osteochondroma was diagnosed 6 years earlier,<sup>22</sup> which may support prophylactic osteochondroma resection when adjacent vascular structures are present.

Most cases were managed by osteochondroma resection with or without open vascular reconstruction. Open surgical options include bypass and interposition grafting, direct repair, patch angioplasty, and aneurysm resection with direct end-to-end anastomosis. Endovascular management is infrequently described. In two hybrid procedures, one patient underwent thrombectomy for embolus in the tibioperoneal trunk with subsequent vein patching of the popliteal pseudoaneurysm, and another had coil embolization of the pseudoaneurysm followed by direct repair of the artery 1 week later.<sup>10,23</sup> Only one patient had isolated endovascular treatment, undergoing coil embolization of a medial femoral circumflex pseudoaneurysm.<sup>11</sup> One patient with intermittent claudication was managed conservatively with cilostazol and a walking program in anticipation of future collateral formation.<sup>13</sup> The paucity of endovascular use reflects the necessity of resecting the causative osteochondroma, which lends itself to concomitant open vascular repair. Patients presenting with symptoms



**Fig 4.** Resected osteochondroma specimen.

of vascular compression, such as thoracic outlet syndrome, without significant arterial injury can be satisfactorily treated with osteochondroma resection alone without specific vascular reconstruction.

Local recurrence of osteochondroma after resection is low at 1.8% but may be higher in skeletally immature patients. Delayed resection should be considered until complete skeletal development in select cases.<sup>24</sup> To avoid recurrence, all remnants of tumor cartilage, bone, and perichondrium must be removed. Two cases are reported of delayed pseudoaneurysm formation after incomplete osteochondroma resection. Otsuka et al<sup>25</sup> reported a partially resected osteochondroma that resulted in pseudoaneurysm formation 5 years later because of ongoing

**Table.** Vascular complications reported in English literature and their treatment

Vascular lesion	Vessel	Procedure
Pseudoaneurysm, 73 (56.2%)	Popliteal artery, 55 Superficial femoral artery, 8 Brachial artery, 6 Subclavian artery, 1 Collateral of popliteal artery, 1 Posterior tibial artery, 1 Medial femoral circumflex artery, 1	Angiography + thrombectomy + vein patch, 1 Embolization coiling + direct repair, 1 Coil embolization, 1 Bypass (vein), 13 Bypass (prosthetic), 2 Direct repair, 23 Aneurysm resection, end-to-end anastomosis, 11 Interposition graft, 5 Ligation, 2 Vein patch, 11 PTFE patch, 1 Cilostazol and walking program, 1 No management, 1
Pseudoaneurysm and deep venous thrombosis, 7 (5.4%)	Popliteal artery, popliteal vein, 7	Aneurysm resection, end-to-end anastomosis, 3 Bypass (vein), 1 Direct repair, 1 Interposition graft, 1 Ligation, 1
Vascular compression, 14 (10.8%)	Popliteal artery, 9 Superficial femoral artery, 2 Common femoral artery, 1 Profunda femoral artery, 1 Brachial artery, 1	Bypass (vein), 9 Osteochondroma resection, 4 End-to-end anastomosis, 1
Arterial thrombosis, 14 (10.8%)	Popliteal artery, 8 Superficial femoral artery, 2 Tibioperoneal trunk, 1 Vertebral artery, 1 Common carotid artery, 1 Anterior tibial artery, 1	Vein patch, 4 Osteochondroma resection, 4 Bypass (vein), 3 Bypass (prosthetic), 1 End-to-end anastomosis, 1 Anticoagulation, 1
Arterial thrombosis + deep venous thrombosis, 1 (0.8%)	Superficial femoral artery, popliteal vein, 1	Bypass (vein), 1
Entrapment, 5 (3.8%)	Popliteal artery, 4 Tibioperoneal trunk, 1	Osteochondroma resection, 5
Entrapment + deep venous thrombosis, 1 (0.8%)	Popliteal artery, popliteal vein, 1	Osteochondroma resection, 1
Deep venous thrombosis, 11 (8.5%)	Popliteal vein, 7 Femoral vein, 3 Subclavian vein, 1	Osteochondroma resection, 8 Interposition graft, 1 Anticoagulation, 2
Thoracic outlet syndrome, 2 (1.5%)	Subclavian artery, 2	Osteochondroma resection, 2
Arteriovenous fistula and aneurysm, 1 (0.8%)	Superficial femoral artery and femoral vein, 1	Aneurysm resection with end-to-end anastomosis and direct repair to vein, 1
Vein aneurysm, 1 (0.8%)	Popliteal vein, 1	Anticoagulation, 1

PTFE, Polytetrafluoroethylene.

arterial trauma from the residual tumor's irregular edges. Similarly, Scotti et al<sup>26</sup> reported brachial pseudoaneurysm presenting with rupture secondary to a partially resected osteochondroma 3 years earlier.

## CONCLUSIONS

The constellation of osteochondroma fracture with arterial pseudoaneurysm and deep venous thrombosis is uncommon. Although it is benign, serious vascular complications can occur because of the relationship with adjacent structures. Osteochondroma resection

must be complete to prevent residual tumor, which can lead to recurrence or ongoing vascular injury. This case underscores the arterial and venous complications of osteochondroma and the association between pseudoaneurysm and deep venous thrombosis.

## REFERENCES

1. Murphey MD, Choi JJ, Kransdorf MJ, Flemming DJ, Gannon FH. Imaging of osteochondroma: variants and complications with radiologic-pathologic correlation. *Radiographics* 2000;20:1407-34.

2. Mehta M, White LM, Knapp T, Kandel RA, Wunder JS, Bell RS. MR imaging of symptomatic osteochondromas with pathological correlation. *Skeletal Radiol* 1998;27:427-33.
3. Kose O, Ertas A, Celiktas M, Kisin B. Fracture of an osteochondroma treated successfully with total excision: two case reports. *Cases J* 2009;2:8062.
4. Vasseur MA, Fabre O. Vascular complications of osteochondromas. *J Vasc Surg* 2000;31:532-8.
5. Matsushita M, Nishikimi N, Sakurai T, Nimura Y. Pseudoaneurysm of the popliteal artery caused by exostosis of the femur: case report and review of the literature. *J Vasc Surg* 2000;32:201-4.
6. Solhaugh JH, Olerud SE. Pseudoaneurysm of the femoral artery caused by osteochondroma of the femur. A case report. *J Bone Joint Surg Am* 1975;57:867-8.
7. Tanigawa N, Kariya S, Kojima H, Komemushi A, Fujii H, Sawada S. Lower limb ischaemia caused by fractured osteochondroma of the femur. *Br J Radiol* 2007;80:e78-80.
8. Oljaca A, Hirzberger D, Bergovec M, Tiesenhausen K, Koter SH, Friesenbichler J, et al. Osteochondroma of the scapula associated with a subclavian artery pseudoaneurysm: case report. *SAGE Open Med Case Rep* 2019;7:2050313x18823089.
9. Villanueva-Garcia E, Bas-Hermida P, Espinosa-Lledo C. Pseudoaneurysm of the brachial artery caused by an osteochondroma. A report of two cases. *Int Orthop* 1995;19:248-50.
10. Wong KT, Chu WC, Griffith JF, Chan YL, Kumta SM, Leung PC. Pseudoaneurysm complicating osteochondromas: symptom relief with embolization. *Clin Orthop Relat Res* 2002;404:339-42.
11. Trivedi H, Link TM, O'Donnell RJ, Horvai AE, Motamedi D. Multiple hereditary exostoses: a pseudoaneurysm masquerading as tumor. *J Radiol Case Rep* 2016;10:50-9.
12. Chalstrey LJ. Aneurysm of the posterior tibial artery due to a tibial osteochondroma. *Br J Surg* 1970;57:151-4.
13. Shah D, Silver M. Osteochondroma: an unusual case of claudication in a young adult. *Vasc Med* 2019 Aug 23. [Epub ahead of print].
14. Vanhegan IS, Shehzad KN, Bhatti TS, Waters TS. Acute popliteal pseudoaneurysm rupture secondary to distal femoral osteochondroma in a patient with hereditary multiple exostoses. *Ann R Coll Surg Engl* 2012;94:e134-6.
15. Christensen JD, Monu JU. Multimodality imaging in the diagnosis of deep vein thrombosis and popliteal pseudoaneurysm complicating a sessile osteochondroma. *Pediatr Radiol* 2008;38:887-91.
16. Andrikopoulos V, Skourtis G, Papacharalambous G, Antoniou I, Tsolias K, Panoussis P. Arterial compromise caused by lower limb osteochondroma. *Vasc Endovascular Surg* 2003;37:185-90.
17. Lucarelli DD, Subram A. Type IV popliteal arterial entrapment associated with an osteochondroma. *J Vasc Surg Cases Innov Tech* 2017;3:66-8.
18. O'Brien PJ, Ramasunder S, Cox MW. Venous thoracic outlet syndrome secondary to first rib osteochondroma in a pediatric patient. *J Vasc Surg* 2011;53:811-3.
19. Gouicem D, Palcau L, Hello CL, Coffin O, Maiza D, Berger L. Gigantic clavicle osteochondroma with carotid compression as a rare cause of stroke. *J Vasc Surg* 2013;57:845-7.
20. Altaf F, Movlik H, Brew S, Rezajooi K, Casey A. Osteochondroma of C1 causing vertebral artery occlusion. *Br J Neurosurg* 2013;27:130-1.
21. Sethi S, Prakash M, Dhal A, Puri SK. Osteochondroma complicated by a popliteal vein aneurysm—a rare case report. *J Clin Diagn Res* 2016;10:TD05-6.
22. Lesser AJ, Greeley CE. Femoropopliteal arteriovenous aneurysm caused by fractured osteochondroma of the femur. *JAMA* 1958;167:1830-3.
23. Blazick E, Keeling WB, Armstrong P, Letson D, Back M. Pseudoaneurysm of the superficial femoral artery associated with osteochondroma—a case report. *Vasc Endovascular Surg* 2005;39:355-8.
24. Humbert ET, Mehlman C, Crawford AH. Two cases of osteochondroma recurrence after surgical resection. *Am J Orthop (Belle Mead, NJ)* 2001;30:62-4.
25. Otsuka T, Yonezawa M, Kamiyama F, Matusita Y, Matui N. Popliteal pseudoaneurysm simulating soft-tissue sarcoma: complication of osteochondroma resection. *Int J Clin Oncol* 2001;6:105-8.
26. Scotti C, Marone EM, Brasca LE, Peretti GM, Chiesa R, Del Maschio A, et al. Pseudoaneurysm overlying an osteochondroma: a noteworthy complication. *J Orthop Traumatol* 2010;11:251-5.

Submitted Oct 25, 2019; accepted Jan 11, 2020.