

- tropical dermatology evidenced by multilocus sequencing typing diagnostics. *Mycoses*. 2015;58:48–57. <https://doi.org/10.1111/myc.12273>
28. Pomares C, Santin M, Miegerville M, Espem A, Albano L, Marty P, et al. A new and highly divergent *Enterocytozoon bieneusi* genotype isolated from a renal transplant recipient. *J Clin Microbiol*. 2012;50:2176–8. <https://doi.org/10.1128/JCM.06791-11>
 29. Zhang X, Wang Z, Su Y, Liang X, Sun X, Peng S, et al. Identification and genotyping of *Enterocytozoon bieneusi* in China. *J Clin Microbiol*. 2011;49:2006–8. <https://doi.org/10.1128/JCM.00372-11>
 30. Ben Ayed L, Yang W, Widmer G, Cama V, Ortega Y, Xiao L. Survey and genetic characterization of wastewater in Tunisia for *Cryptosporidium* spp., *Giardia duodenalis*, *Enterocytozoon bieneusi*, *Cyclospora cayatanensis* and *Eimeria* spp. *J Water Health*. 2012;10:431–44. <https://doi.org/10.2166/wh.2012.204>
 31. Cotte L, Rabodonirina M, Chapuis F, Bailly F, Bissuel F, Raynal C, et al. Waterborne outbreak of intestinal microsporidiosis in persons with and without human immunodeficiency virus infection. *J Infect Dis*. 1999;180:2003–8. <https://doi.org/10.1086/315112>
 32. Decraene V, Lebbaq M, Botero-Kleiven S, Gustavsson A-M, Löfdahl M. First reported foodborne outbreak associated with microsporidia, Sweden, October 2009. *Epidemiol Infect*. 2012;140:519–27. <https://doi.org/10.1017/S095026881100077X>
 33. Scaglia M, Gatti S, Sacchi L, Corona S, Chichino G, Bernuzzi AM, et al. Asymptomatic respiratory tract microsporidiosis due to *Encephalitozoon hellem* in three patients with AIDS. *Clin Infect Dis*. 1998;26:174–6. <https://doi.org/10.1086/516264>
 34. Choukri F, Menotti J, Sarfati C, Lucet J-C, Nevez G, Garin YJF, et al. Quantification and spread of *Pneumocystis jirovecii* in the surrounding air of patients with *Pneumocystis pneumonia*. *Clin Infect Dis*. 2010;51:259–65. <https://doi.org/10.1086/653933>
 35. Kaplan JE, Benson C, Holmes KK, Brooks JT, Pau A, Masur H, et al. Guidelines for prevention and treatment of opportunistic infections in HIV-infected adults and adolescents: recommendations from CDC, the National Institutes of Health, and the HIV Medicine Association of the Infectious Diseases Society of America. *MMWR Recomm Rep*. 2009;58:1–207.

Address for correspondence: Philippe Poirier, CHU Gabriel-Montpied, Laboratoire de Parasitologie-Mycologie, 58 Rue Montalembert, 63000 Clermont-Ferrand, France; email: ppoirier@chu-clermontferrand.fr

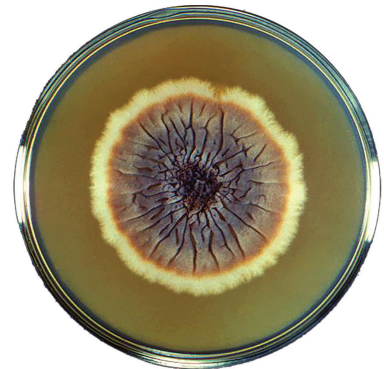
etymologia

Sporothrix [spor'ō-thriks] *schenckii*

Fábio P. Sellera, Carlos E. Larsson

From the Greek *sporotrich* and later from the Latin *spor-* (spore) + *thrix* (hair), *Sporothrix schenckii* was named as a tribute to Benjamin Schenck, a medical student at the Johns Hopkins Hospital, who first isolated the fungus from a patient who had lesions on the right hand and arm in 1896. This fungus was erroneously assigned to the genus *Sporotrichum* until 1962, when it was reclassified as *Sporothrix*.

S. schenckii is a saprophyte and pathogenic fungus that is responsible for sporotrichosis that is endemic mostly to tropical and subtropical regions. Sporotrichosis (also known as “rose gardener’s disease”) was related primarily to agricultural workers who had cuts or abrasions in the skin, and later to scratches and bites from companion and wild animals. Currently, it is recognized that *S. schenckii* is a species complex that includes *S. brasiliensis*, *S. globosa*, *S. mexicana*, *S. luriei*, and *S. schenckii sensu stricto*.



Petri dish culture of a colony of the fungus *Sporothrix schenckii* strain M-36-53. This fungus is the cause of sporotrichosis. Centers for Disease Control and Production, Dr. Lucille K. Georg, 1964

Author affiliation: Universidade de São Paulo, São Paulo, Brazil

Sources

1. Barros MB, de Almeida Paes R, Schubach AO. *Sporothrix schenckii* and sporotrichosis. *Clin Microbiol Rev*. 2011;24:633–54. <http://dx.doi.org/10.1128/CMR.00007-11>
2. Gold JA, Derado G, Mody RK, Benedict K. Sporotrichosis-associated hospitalizations, United States, 2000–2013. *Emerg Infect Dis*. 2016;22:1817–20. <http://dx.doi.org/10.3201/eid2210.160671>
3. Marimon R, Cano J, Gené J, Sutton DA, Kawasaki M, Guarro J. *Sporothrix brasiliensis*, *S. globosa*, and *S. mexicana*, three new *Sporothrix* species of clinical interest. *J Clin Microbiol*. 2007;45:3198–206. <https://doi.org/10.1128/JCM.00808-07>
4. Schenck BR. On refractory subcutaneous abscess caused by a fungus possibly related to the Sporotricha. *Bull Johns Hopkins Hosp*. 1898;9:286–90.
5. Schubach A, Schubach TM, Barros MB, Wanke B. Cat-transmitted sporotrichosis, Rio de Janeiro, Brazil. *Emerg Infect Dis*. 2005;11:1952–4. <http://dx.doi.org/10.3201/eid1112.040891>

Address for correspondence: Fábio P. Sellera, Department of Internal Medicine, School of Veterinary Medicine and Animal Science, Universidade de São Paulo, São Paulo, SP 05508-270, Brazil; email: fsellera@usp.br

DOI: <https://doi.org/10.3201/eid2509.ET2509>