

CASE REPORT

Open Access



# Non-arteritic anterior ischemic optic neuropathy with Cilioretinal artery occlusion: a case report

Ya-Yun Yang<sup>1</sup> and Ming-Shan He<sup>2\*</sup>

## Abstract

**Background:** To describe a peculiar case of concurrent non-arteritic anterior ischemic optic neuropathy (NAION) and cilioretinal arteries occlusion (CLRAO) without other causative agents which responded well to intravenous and intravitreal injection of corticosteroids.

**Case presentation:** A 41-year-old woman presented with painless vision loss in the right eye for 1 week. Fundus examinations showed marked disc swelling, flame-shaped hemorrhage over the superior nerve fiber area, and well-demarcated retinal ischemia superior to the fovea in the right eye. Under the impression of NAION with branch retinal artery occlusion, the patient was treated with intravenous and intravitreal injection of corticosteroids. Two months later, as the disc swelling and retinal ischemia resolved, we found that the occluded artery was the cilioretinal artery and not the ordinary branch retinal artery.

**Conclusions:** CLRAO may be concomitant with the setting of NAION, the physicians should be aware that CLRAO may be misinterpreted as BRAO owing to profound disc edema during the early stages of the disease.

**Keywords:** Non-arteritic anterior ischemic optic neuropathy, Cilioretinal artery occlusion, Branch retinal artery occlusion

## Background

Non-arteritic anterior ischemic optic neuropathy (NAION) is due to acute ischemia of the optic nerve head (ONH), whose main supply of blood is from the circulation of the posterior ciliary arteries (PCA). The vast majority of NAION cases result from transient non-perfusion or hypoperfusion of ONH circulation [1]. Cilioretinal arteries also arise from short PCA. Thus, if retinal vascular occlusion occurs, the presence of a cilioretinal artery can significantly influence visual morbidity. It is interesting that although both the optic nerve head and cilioretinal arteries are supplied by PCA, concomitant anterior ischemic optic neuropathy (AION) and cilioretinal arteries occlusion (CLRAO) are uncommon in clinical practice. If it does occur, it is almost always arteritic and always pathognomonic for giant cell arteritis; other causes have been reported, including overdose of Viagra® [2]. Here we report on a peculiar case

involving concurrent NAION and CLRAO without other causative agents.

## Case presentation

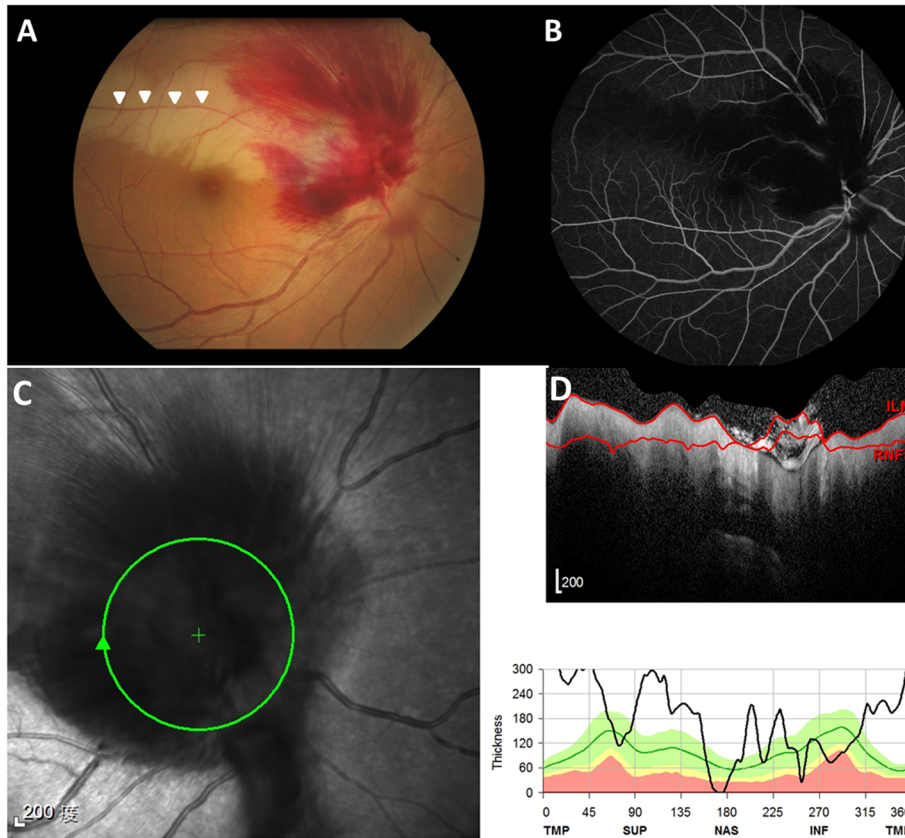
A 41-year-old woman with a history of hypertension visited our hospital due to sudden onset of painless vision loss in the right eye for 1 week. Her height is 5'; body weight is 49 Kg with a body mass index is 22 kg/m<sup>2</sup>. She doesn't have sleep apnea, and the vision loss occurred while she woke up. Visual acuity was 20/200 OD and 20/40 OS. Fundus and OCT (Optical Coherence Tomography) examinations showed marked disc swelling, flame-shaped hemorrhaging over the superior and temporal nerve fiber area (Fig. 1a, c, d), and well-demarcated retinal ischemia superior to the fovea in the right eye (Fig. 1a), with an absent optic cup appearance of the left eye. In addition, we found a relative afferent pupillary defect in the right eye. Visual field examination showed peripheral constriction and inferior arcuate defect of the right eye and normal of the left eye. Fluorescein angiography disclosed a filling defect

\* Correspondence: [mingshanher@gmail.com](mailto:mingshanher@gmail.com)

<sup>2</sup>Department of Ophthalmology and Visual Science, Tzu Chi University, Hualien, Taiwan

Full list of author information is available at the end of the article

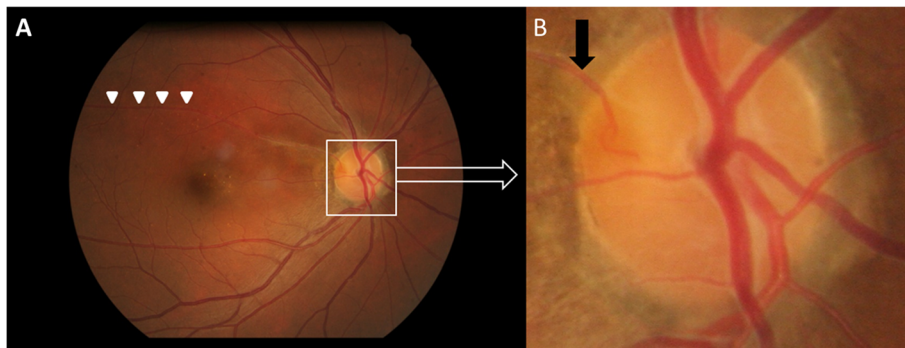




**Fig. 1** **a**. The fundus showed marked disc swelling, flame-shaped hemorrhaging over the superior nerve fiber area and well-demarcated retinal ischemia along with branch retinal artery (arrowheads) superior to the fovea in the right eye. **b**. Fluorescein angiography disclosed a filling defect of retinal arterial circulation superior to the fovea correlated with retinal ischemia. **c**. Infrared image and **d**. Corresponding OCT retinal nerve fiber layer (RNFL) scan revealed profound disc swelling over the superior and temporal nerve fiber area of the right eye

of retinal arterial circulation superior to the fovea correlated with retinal ischemia and blocked fluorescence due to profound retinal hemorrhaging over the disc in the right eye (Fig. 1b). Examination revealed blood pressure was 158/105 mmHg. Cardiac and carotid doppler sonography were normal. Laboratory examinations for the complete blood count, antinuclear antibody,

protein C/S, and homocysteine were within normal ranges; the erythrocyte sediment rate (ESR) was 6 mm/hour; total cholesterol was 234 mg/dL. Under the impression of NAION with branch retinal artery occlusion (BRAO), the patient was admitted for intravenous methylprednisolone pulse therapy for 3 days (total dose: 3000 mg) followed by gradual tapering oral



**Fig. 2** **a** Six months later, the fundus showed resolved disc swelling and retinal ischemia along with branch retinal artery (arrowheads). **b**. A high magnification image of the right disc disclosed the occluded artery was found to be the cilioretinal artery (black arrow)

prednisolone and one intravitreal injection of triamcinolone. Two months later, as the disc swelling and retinal ischemia resolved, we found that the occluded artery was the cilioretinal artery and not the ordinary branch retinal artery (Fig. 2). Visual acuity improved to 20/25 in the right eye 6 months after the treatment. Disc revealed a pale change in the superior and temporal part with an absent optic cup.

## Discussion and conclusion

The cilioretinal artery is present in 20% of the population, and the PCA supplies the optic nerve head as well as the cilioretinal artery. When CLRAO is combined with AION, it is nearly pathognomonic for giant cell arteritis associated arteritic-AION [3]. Our patient was relatively young, had normal ESR and did not have temporal tenderness or headache, which made giant cell arteritis unlikely. Furthermore, unlike small peripapillary hemorrhaging in most NAION cases, profound hemorrhaging along superior fiber area revealed poorer local circulation compared with others. In our case, marked optic disc swelling inherent to NAION may have resulted in local compartmental effects around the disc, which may have further compromised the circulation of the cilioretinal artery. This then led to concomitant CLRAO. Furthermore, the physicians should be aware that CLRAO may be misinterpreted as BRAO owing to profound disc edema during the early stages of the disease.

Little is known regarding the optimal management of NAION. The main debate in recent decades is whether or not to use steroids [4]. Although there is no consensus, steroids are thought to decrease optic disc edema and improve circulation in the optic nerve head [5]. The visual loss in NAION was investigated to be due not just to ischemia but also to associated inflammation, and this has shown in both animals with experimental NAION and in the few cases of acute NAION in humans that have been studied [6]. Some case series also showed treatment efficacy in intravitreal injection of triamcinolone for high intraocular steroid concentration without systemic adverse effects [7]. Our case showed that CLRAO may be concomitant with the setting of NAION. High dose intravenous corticosteroids and intravitreal injection of triamcinolone may decrease optic disc edema and improve circulation in both the optic nerve head and cilioretinal artery with favorable results.

In conclusion, CLRAO may be concomitant with the setting of NAION, the physicians should be aware that CLRAO may be misinterpreted as BRAO owing to profound disc edema during the early stages of the disease.

## Abbreviations

AION: Anterior ischemic optic neuropathy; BRAO: Branch retinal artery occlusion; CLRAO: Cilioretinal arteries occlusion; NAION: Non-arteritic anterior ischemic optic neuropathy; OCT: Optical Coherence Tomography; ONH: Optic nerve head; PCA: Posterior ciliary arteries

## Acknowledgments

We thank the patient for providing permission to share her information.

## Authors' contributions

YYY and MSH had full access to all of the data in the study and take responsibility for the integrity of the data and the accuracy of the data analysis. Concept and design: MSH. Acquisition, analysis, or interpretation of data: YYY and MSH. Both authors read and approved the final manuscript.

## Funding

None.

## Availability of data and materials

All the data supporting the conclusions of this article is included in the present article.

## Ethics approval and consent to participate

Not applicable.

## Consent for publication

Written informed consent was obtained from the patient for publication of this case report and any accompanying images.

## Competing interests

The authors declare that they have no competing interests.

## Author details

<sup>1</sup>Department of Ophthalmology, Buddhist Tzu Chi General Hospital, Hualien, Taiwan. <sup>2</sup>Department of Ophthalmology and Visual Science, Tzu Chi University, Hualien, Taiwan.

Received: 28 April 2019 Accepted: 6 November 2019

Published online: 14 November 2019

## References

- Hayreh SS. Ischemic optic neuropathy. *Prog Retin Eye Res.* 2009;28(1):34–62.
- Akash R, Hrishikesh D, Amith P, Sabah S. Case report: association of combined nonarteritic anterior ischemic optic neuropathy (NAION) and obstruction of cilioretinal artery with overdose of Viagra. *J Ocul Pharmacol Ther.* 2005;21(4):315–7.
- Miller NR. Current concepts in the diagnosis, pathogenesis, and management of nonarteritic anterior ischemic optic neuropathy. *J Neuroophthalmol.* 2011;31(2):e1–3.
- Lee AG, Biousse V. Should steroids be offered to patients with nonarteritic anterior ischemic optic neuropathy? *J Neuroophthalmol.* 2010;30(2):193–8.
- Hayreh SS. Role of steroid therapy in nonarteritic anterior ischemic optic neuropathy. *J Neuroophthalmol.* 2010;30(4):388–9.
- Salgado C, Wilson F, Miller NR, Bernstein SL. Cellular inflammation in nonarteritic anterior ischemic optic neuropathy and its primate model. *Arch Ophthalmol (Chicago, Ill: 1960).* 2011;129(12):1583–91.
- Kaderli B, Avci R, Yucel A, Guler K, Geliskan O. Intravitreal triamcinolone improves recovery of visual acuity in nonarteritic anterior ischemic optic neuropathy. *J Neuroophthalmol.* 2007;27(3):164–8.

## Publisher's Note

Springer Nature remains neutral with regard to jurisdictional claims in published maps and institutional affiliations.

**Ready to submit your research? Choose BMC and benefit from:**

- fast, convenient online submission
- thorough peer review by experienced researchers in your field
- rapid publication on acceptance
- support for research data, including large and complex data types
- gold Open Access which fosters wider collaboration and increased citations
- maximum visibility for your research: over 100M website views per year

**At BMC, research is always in progress.**

Learn more [biomedcentral.com/submissions](https://biomedcentral.com/submissions)

