

Case Report

A Rare Case of Mesenteric Gastrointestinal Stromal Tumor Presenting as Acute Abdomen

Anant Sadanand Ramani, Guruprasad Huske, Francisco P Noronha

Department of Surgery, Goa Medical College, Bambolim, Goa, India

ABSTRACT

Gastrointestinal stromal tumours (GIST) are rare tumours arising from mesenchyme of gastrointestinal tract and overexpress C-kit protein. Mainly seen in stomach and small bowel. Mesenteric GIST are rarely reported as they constitute less than 1% of total GIST. We here report such a rare case of GIST arising from mesentery of small bowel and presenting as acute abdomen. Good surgical clearance ensures good survival whereas incomplete resection results in a high incidence of recurrences with distant metastasis.

KEYWORDS: *Gastrointestinal stromal tumors, imatinib, mesenteric stromal tumors*

INTRODUCTION

Gastrointestinal stromal tumors (GISTs) are mesenchymal tumors of gastrointestinal tract arising from the interstitial cell of Cajal. The term was coined by Mazur and Clark in 1983, and later on it was observed that these tumors overexpress tyrosine kinase receptors due to mutation in genes C-kit (CD117 or CD34) or platelet-derived growth factor receptor A (PDGFRA) detected on immunohistochemistry.^[1] The incidence of GIST is 10–20 cases per million population and mostly seen in patients older than 50 years, accounting for <1% of all gastrointestinal tumors.^[2] Most of the tumors are seen in the stomach and rarely in the mesentery. Complete R0 resection ensures better chances of survival.^[3,4] Imatinib, a tyrosine kinase inhibitor drug, has a major role to play postoperatively, as there is a lack of response of GIST to radiotherapy or chemotherapy.

CASE REPORT

A 32-year-old male presented to us with a history of gradual abdominal distension for 5 months and acute pain of 2 days duration. There was no history of any previous investigations or any hospital admissions. Physical examination showed pulse rate of 82/min, blood pressure of 120/80 mmHg, and respiratory rate of 22/min. Abdominal examination revealed a huge tender mass occupying the periumbilical area and both lumbar

regions. Abdominal ultrasound showed 18 cm × 15 cm mass with solid and cystic components arising from small bowel mesentery with loops of bowel adherent to it. A clinical diagnosis of mesenteric cyst with small bowel obstruction was made. Emergency laparotomy done for acute abdomen showed a huge mass of 18 cm × 15 cm arising from small bowel mesentery, with involvement of few loops of proximal ileum 20 cm in length as shown in Figure 1. Debulking of the tumor was done with resection of the above loops of ileum. Small part of tumor (2 cm × 1 cm) could not be removed as it was encasing the superior mesenteric vessels.

Histopathology of the tumor revealed GIST as shown in Figure 2, with mitosis index of 17/50 high power fields (HPF) and CD117 positive. The patient postoperatively received tablet imatinib 400 mg/day. Twelve months postoperatively, the patient was re-explored as he developed recurrence with distant metastasis in the liver and peritoneum confirmed on contrast-enhanced computed tomography (CT) scan, but the same could not be re-excised. The patient survived 6 months after the second re-exploration while on tablet imatinib.

Address for correspondence: Dr. Anant Sadanand Ramani, Department of Surgery, Goa Medical College, Bambolim - 403 502, Goa, India.
E-mail: ramani.anant@rediffmail.com

This is an open access article distributed under the terms of the Creative Commons Attribution-NonCommercial-ShareAlike 3.0 License, which allows others to remix, tweak, and build upon the work non-commercially, as long as the author is credited and the new creations are licensed under the identical terms.

For reprints contact: reprints@medknow.com

How to cite this article: Ramani AS, Huske G, Noronha FP. A rare case of mesenteric gastrointestinal stromal tumor presenting as acute abdomen. *Niger J Surg* 2017;23:71-2.

Access this article online	
Quick Response Code: 	Website: www.nigerianjsurg.com
	DOI: 10.4103/1117-6806.199960

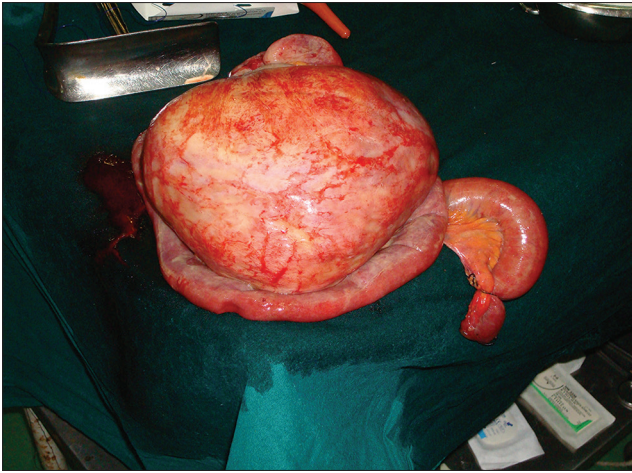


Figure 1: Gastrointestinal stromal tumors' mass excised

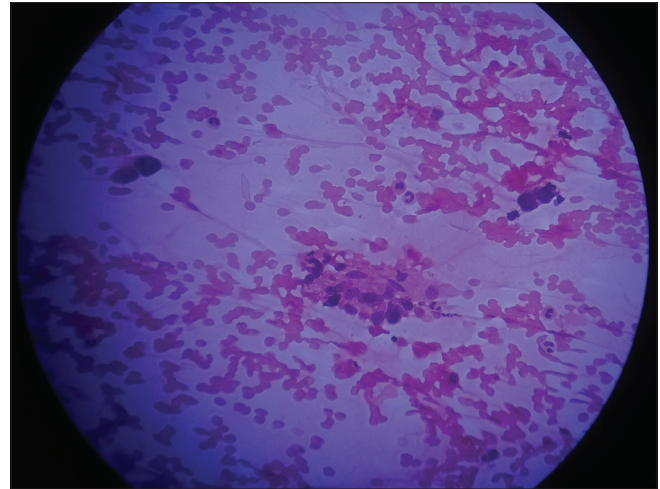


Figure 2: High power slide of gastrointestinal stromal tumors

DISCUSSION

GISTs are mostly seen in stomach (60%), followed by small bowel (30%), rectum (5%), and esophagus (5%). GISTs are rarely seen in mesentery, omentum, or retroperitoneum, comprising <1% of GISTs.^[2] GIST present as lump in abdomen, pain due to tumor necrosis or rupture, and rarely as nontraumatic hemoperitoneum due to bleeding from the tumor mass. Abdominal ultrasound and CT scan are the main diagnostic investigations. On CT scan, mesenteric GIST is a well-defined lobular mass showing heterogeneous contrast enhancement with areas of hypodensity.^[2] Surgery with R0 resection is the mainstay of treatment that shall ensure better prognosis with a good survival. Apart from this, the tumor size >5 cm, presence of tumor necrosis, mitosis >5/50 HPF, positive resection margins, and distant metastasis are all poor prognostic indices. Our patient had a large tumor (18 cm × 15 cm), mitosis of 17/50 HPF, central necrosis, and positive resection margins which must have resulted in early recurrence with peritoneal and liver metastasis, which are the common sites of spread in malignant GIST.^[5] Ninety-five percentage of GIST are C-Kit positive (CD117 or CD34) while 5% are PDGFRA-positive.^[1] Targeted chemotherapy with imatinib, a tyrosine kinase inhibitor drug, used postoperatively is believed by some to prevent or delay recurrences and improve survival.^[3] However, there is no consensus on this issue. Some believe that there is no proof that treatment with imatinib improves survival.^[4] In our case, we cannot conclude about the definite postoperative benefits of imatinib. This subject requires further research. The malignant potential of GIST varies from benign to malignant with benign having a 5-year survival of 95% whereas in the malignant type,

it is 21%.^[1,3] In recurrent disease, the median survival is 9–12 months.^[1,3] In our case, it was 6 months.

CONCLUSION

Mesenteric GIST, being a rare entity, can be clinically mistaken for mesenteric cyst and can present as acute abdomen due to tumor necrosis. In cases with short duration of abdominal mass arising from mesentery, one has to keep in mind the possibility of mesenteric GIST. Large mass (>5 cm), incomplete resection margins, mitosis >5 HPF, and central necrosis are all poor indices for survival and result in high recurrences.

Financial support and sponsorship

Nil.

Conflicts of interest

There are no conflicts of interest.

REFERENCES

1. Puneet MS, Khanna AK. Gastrointestinal stromal tumours. In: Gupta R, editor. *Recent Advances in Surgery 11*. Vol. 14. New Delhi, India: Jaypee Brothers Medical Publishers (P) Ltd; 2009. p. 278-94.
2. Sinha R, Verma R, Kong A. Mesenteric gastrointestinal stromal tumor in a patient with neurofibromatosis. *AJR Am J Roentgenol* 2004;183:1844-6.
3. Bucher P, Villiger P, Egger JF, Buhler LH, Morel P. Management of gastrointestinal stromal tumors: From diagnosis to treatment. *Swiss Med Wkly* 2004;134:145-53.
4. van der Zwan SM, DeMatteo RP. Gastrointestinal stromal tumor: 5 years later. *Cancer* 2005;104:1781-8.
5. Miettinen M, Monihan JM, Sarlomo-Rikala M, Kovatich AJ, Carr NJ, Emory TS, *et al.* Gastrointestinal stromal tumors/smooth muscle tumors (GISTs) primary in the omentum and mesentery: Clinicopathologic and immunohistochemical study of 26 cases. *Am J Surg Pathol* 1999;23:1109-18.