

Alterations in brain metabolism and function following administration of low-dose codeine phosphate: ¹H-magnetic resonance spectroscopy and resting-state functional magnetic resonance imaging studies

ZHEN CAO¹, PEI-YIN LIN², ZHI-WEI SHEN¹, REN-HUA WU¹ and YE-YU XIAO¹

¹Department of Medical Imaging, The Second Affiliated Hospital; ²Department of Medical Imaging, The First Affiliated Hospital, Shantou University Medical College, Shantou, Guangdong 515041, P.R. China

Received February 24, 2015; Accepted April 6, 2016

DOI: 10.3892/etm.2016.3358

Abstract. The aim of the present study was to identify alterations in brain function following administration of a single, low-dose of codeine phosphate in healthy volunteers using resting-state functional magnetic resonance imaging (fMRI). In addition, the metabolic changes in the two sides of the frontal lobe were identified using ¹H-magnetic resonance spectroscopy (¹H-MRS). A total of 20 right-handed healthy participants (10 males, 10 females) were evaluated, and a Signa HDx 1.5T MRI scanner was used for data acquisition. An echo planar imaging sequence was used for resting-state fMRI, whereas a point resolved spectroscopy sequence was used for ¹H-MRS. Regional Saturation Technique, Data Processing Assistant for Resting-State fMRI, and Statistical Parameter Mapping 8 were used to analyze the fMRI data. The ¹H-MRS data were analyzed using LCModel software. At 1 h after oral administration of codeine phosphate (1.0 mg/kg), the amplitude of low-frequency fluctuation (ALFF) and regional homogeneity were altered in different brain areas. The choline content was significantly increased in the right and left frontal lobes following codeine phosphate administration (P=0.02 and P=0.03, respectively), whereas the inositol content was significantly decreased in the left frontal lobe (P=0.02). There was no change in the glutamic acid content in the frontal lobes. In conclusion, the functions of different brain regions can be affected by a single, low-dose administration of codeine phosphate. The alterations in metabolite content in the two frontal lobes may be associated with changes in brain function,

whereas the ALFF in the globus pallidus may have an effect on codeine phosphate addiction. Finally, glutamic acid may be useful in the estimation of codeine dependence.

Introduction

Low-dose codeine phosphate is a widely used sedative for the management of cough and pain (1). However, to the best of our knowledge, there is a limited number of previous studies directly demonstrating the effects of codeine phosphate on brain metabolism and function in humans (2,3). In addition, the exact mechanisms of action of codeine phosphate on the brain remain unclear. Therefore, a number of side effects occurring following codeine phosphate administration, such as drug dependency and withdrawal, are not well understood (4,5).

Magnetic resonance spectroscopy (MRS) and resting-state functional magnetic resonance imaging (fMRI) can be used to investigate the effects of codeine phosphate in the brain (6). MRS enables a noninvasive assessment of the brain and other organs to identify chemical changes in a given region of interest (7). Furthermore, an accurate quantitative analysis of brain metabolites is possible using Linear Combination of Model (LCModel) software (<http://www.s-provencher.com/pages/lcmodel.shtml>) (8). MRS combined with LCModel has been widely used for the assessment of brain tumors, mental disorders and drug analysis (9-11).

Resting-state fMRI is an intricate method that is able to identify the function of different brain regions in a given status or without external stimulation (12). In addition, resting-state fMRI can be performed without the requirement of an overt task or external input; therefore, the results are reliable and the external factor effects are reduced (13,14). Compared with traditional fMRI, resting-state fMRI can be analyzed with regard to the amplitude of low-frequency fluctuation (ALFF), regional homogeneity (ReHo) and functional connectivity (15). Furthermore, previous studies have used resting-state fMRI to identify the impact of drugs, primarily strong and illicit opioid drugs, on the brain (16,17).

To the best of our knowledge, fMRI studies of codeine phosphate, which is a weak opioid drug, have not been previously reported. Functional and metabolic alterations in the

Correspondence to: Dr Ye-Yu Xiao or Dr Ren-Hua Wu, Department of Medical Imaging, The Second Affiliated Hospital, Shantou University Medical College, 69 DongXia North Road, Shantou, Guangdong 515041, P.R. China
E-mail: xyu73@163.com
E-mail: rhwu@stu.edu.cn

Key words: codeine phosphate, magnetic resonance spectroscopy, resting-state functional magnetic resonance imaging, brain function, metabolite changes

frontal lobe are the primary causes of strong and illicit opioid drug side effects (18,19). Furthermore, the functions of the human brain hemispheres are different. Advanced functions, including speaking, reading, writing, calculating, recognizing amongst others are administrated by one side of the brain hemisphere. This side of brain hemisphere is called the advantage hemisphere. Handedness is an external symbol to judge on which side is the advantage hemisphere of brain.

The present study aims to investigate the metabolite and functional data affected by the normal doses of codeine phosphate that are obtained from the experiments conducted. This data will provide accurate and reasonable background information for future studies on codeine addiction. Furthermore, it is significant to study the effect on the frontal lobe because it is the part of the brain that is responsible for thinking, drug craving and for our emotions. Previous opioid dependence studies reveal that a change in emotions and a thirst for drugs were associated with a change in the function of the frontal lobe (20). In the present study, MRS and resting-state fMRI were used to detect the functional and metabolic alterations in the frontal lobe of healthy volunteers following the administration of a single, low-dose of codeine phosphate.

Materials and methods

Participants. A total of 20 right-handed subjects (10 males and 10 females) were included in the present study. The subjects were healthy and were recruited as volunteers by our research laboratory between June 2013 and June 2014. All subjects met the following inclusion criteria: i) Right-handed subjects with a mean age of 22±2 years; ii) absence of neurological illness, which was assessed by a neurologist and confirmed by conventional brain MRI; iii) no history of psychiatric illness (Mini-Mental State Examination and Montreal Cognitive Assessment test scores, which were assessed by a psychiatrist, must be ≥27; 21); and iv) no history of drug or alcohol dependence, and no drug or alcohol intake within the previous 2 months. The MRI is recorded by GE Signa HDx 1.5T MR scanner (GE Healthcare Life Sciences, Little Chalfont, UK).

Individuals with neurological, psychiatric or organic diseases were excluded. Additional exclusion criteria were as follows: i) A past or current history of central nervous system damage caused by other diseases; or ii) severe medical illness.

The present study was approved by the Ethics Committee of the Shantou University Medical College (Shantou, China). All subjects provided written informed consent prior to study participation.

Data acquisition. Codeine phosphate (Qinghai Pharmaceutical Group Co., Ltd., Xining, China) has been previously reported to require 1 h to reach the peak plasma drug concentration in the brain (4). Thus, data from healthy participants were collected before and 1 h after oral administration of codeine phosphate (1.0 mg/kg). A Signa HDx 1.5T MRI scanner (GE Healthcare Life Sciences) was used for data acquisition. An echo-planar imaging (EPI) sequence was used for resting-state fMRI with the following conditions: Repetition time (TR), 2000 ms; echo time (TE), 25 ms; flip angle, 90°; number of slices, 39; and field of view, 192 mm.

Proton (¹H) MRS involved the use of a point resolved spectroscopy sequence (also known as PRESS) with the following conditions: TE/TR, 35/1500 ms; total scan number, 128; volume of interest, 2 cm³; full wave at half maximum, <10; and water suppression, <98%. The voxels were placed in the symmetrical frontal lobe.

Data processing. The resting-state fMRI data were processed using the Regional Saturation Technique (REST; (http://restfmri.net/forum/REST_V_1.8) (22), Data Processing Assistant for Resting-state fMRI (DPARSF) (23) and Statistical Parameter Mapping 8 (SPM8) (24). The preprocessing steps with the DPARSF toolkit (DPARSF (<http://www.restfmri.net/forum/DPARSF>)) were performed as previously described (25), and included slice timing, realignment and normalization. The first 10 volumes were discarded to ensure stable magnetization and to allow subjects to adapt to the scanning environment. The slice timing involved the number of slices (30 slices), slice order (2, 4, 6, and so on, up to 30 slices) and reference slice (30). Head motion correction was processed using the realign function, and spatial normalization was performed using EPI templates. In addition, a band-pass filter (0.01–0.08 Hz) was applied to remove physiological and high-frequency noise. The effects of the processing maps were investigated using SPM8 (<http://www.fil.ion.ucl.ac.uk/spm/software/spm8/>) (26). The processing maps refer to the magnetic resonance images following the removal of physiological and high frequency noise correction.

The values for ALFF and ReHo were calculated using REST. In the calculation of the ALFF, the data initially underwent smoothing automatically using the REST software to suppress noise and effects that resulted from residual differences in functional and gyral anatomy. The ALFF map was normalized to the global mean ALFF for each subject.

The ReHo was evaluated using Kendall's coefficient concordance (KCC), as previously described (27). The ReHo maps were generated by assigning a value for each voxel that corresponded to the KCC of its time series with the nearest 26 neighboring voxels. The ReHo maps were standardized based on the subject's mean KCC. A 4 mm full width at half maximum Gaussian function was used to smooth the images to reduce the noise and residual differences.

The MRS data were analyzed using LCModel (28). The processing included Fourier transformation and noise filtering, and zero-fill and baseline correction. The metabolite concentrations were then measured. In brief, the original magnetic resonance spectroscopy data were input into the LCModel software. The software contains a basis set in which there are various metabolite spectral lines of the brain collected under different parameters *in vitro*. These spectral lines contain metabolite concentration and chemical shift information. According to the internal basis set, the software automatically matches and compares with the inputted original spectroscopy line. Finally, the software computes the metabolite concentrations. The features of the LCModel software is highly automatic, without too much human intervention.

Statistical analysis. The MRS data were analyzed using SPSS version 17.0 (SPSS, Inc., Chicago, IL, USA). The metabolite levels were compared with the normal levels using paired

Table I. Peak MNI coordinates of clusters for the amplitude of low-frequency fluctuation.

Brain region	MNI coordinates			t-value	Cluster size
	X	Y	Z		
Right frontal lobe white matter	23	30	13	2.73	
Right parietal white matter	-21	-24	39	4.79	1,108
Left parietal white matter	-21	-21	36	4.22	
Left frontal lobe white matter	-22	33	13	2.24	1,481
Left superior parietal lobule	-36	-58	49	3.21	93
Left superior frontal gyrus	-12	57	39	3.46	47
Left cingulate	-7	45	9	2.52	99
Left insula	-39	11	8	2.36	63
Left ceneus	-33	-85	9	3.45	196
Left thalamus	-8	-20	-1	-4.03	96
Left cerebral peduncle	-11	-21	-16	-2.01	107
Left pons	-15	-25	-26	-2.08	101
Right superior parietal lobule	31	-71	49	2.74	46
Right inferior frontal gyrus	47	38	-1	2.65	104
Right limbic lobe	42	-30	-27	3.38	85
Right insula	42	11	8	2.28	89
Right ceneus	45	-81	9	3.05	321
Right parahippocampal gyrus	54	-1	-22	3.26	119
Right cerebellum crus 2	18	-93	-33	3.58	35

Paired t test; statistical threshold, $P < 0.05$ and cluster size, > 25 voxels. MNI, Montreal Neurological Institute.

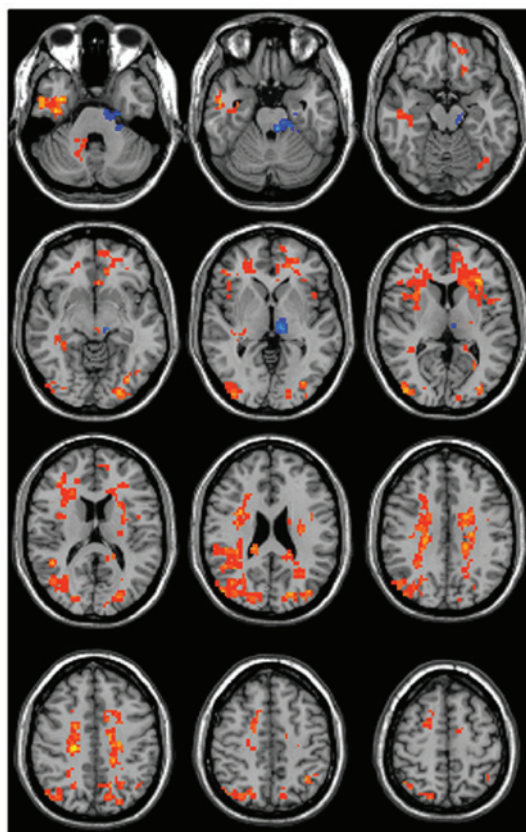


Figure 1. Brain areas with an abnormal amplitude of low-frequency fluctuation (ALFF) following a single oral administration of codeine phosphate (1.0 mg/kg) compared to images before administration. Red indicates increased ALFF and blue indicates decreased ALFF. The figure shows representative images from all of the subjects.

Table II. Peak MNI coordinates of clusters for regional homogeneity.

Brain region	MNI coordinates			t-value	Cluster size
	X	Y	Z		
Left corona radiata	-21	-21	36	4.22	1,163
Right corona radiata	21	-24	39	4.79	679
Genu of corpus callosum	-1	34	4	3.32	118
Left precentral gyrus	-45	-16	49	-4.09	105
Left cuneus	-25	-89	29	-3.59	168
Left middle frontal gyrus	-44	13	36	-3.73	100
Left inferior frontal gyrus	-45	27	27	-5.74	112
Left insular lobe	-40	13	4	3.01	80
Left thalamus	-6	-18	3	-7.06	126
Left putamen	-28	10	2	2.32	93
Left cerebral peduncle	-8	-27	-20	-3.36	96
Right precuneus	12	-73	37	-2.74	94
Right cingulated gyrus	5	-39	40	-5.27	84
Right lateral occipitotemporal gyrus	51	3	-24	7.24	79
Right parahippocampal gyrus	41	-12	-29	5.00	200
Right thalamus	9	-18	3	-7.07	98
Right middle cerebral peduncle	19	-43	-39	4.71	105
Right inferior temporal gyrus	50	-33	-22	3.02	80
Right cerebellum posterior lobe	21	-42	-39	6.11	81

Statistical analysis was performed by the paired t test; statistical threshold, $P < 0.05$ and cluster size > 25 voxels. MNI, Montreal Neurological Institute.

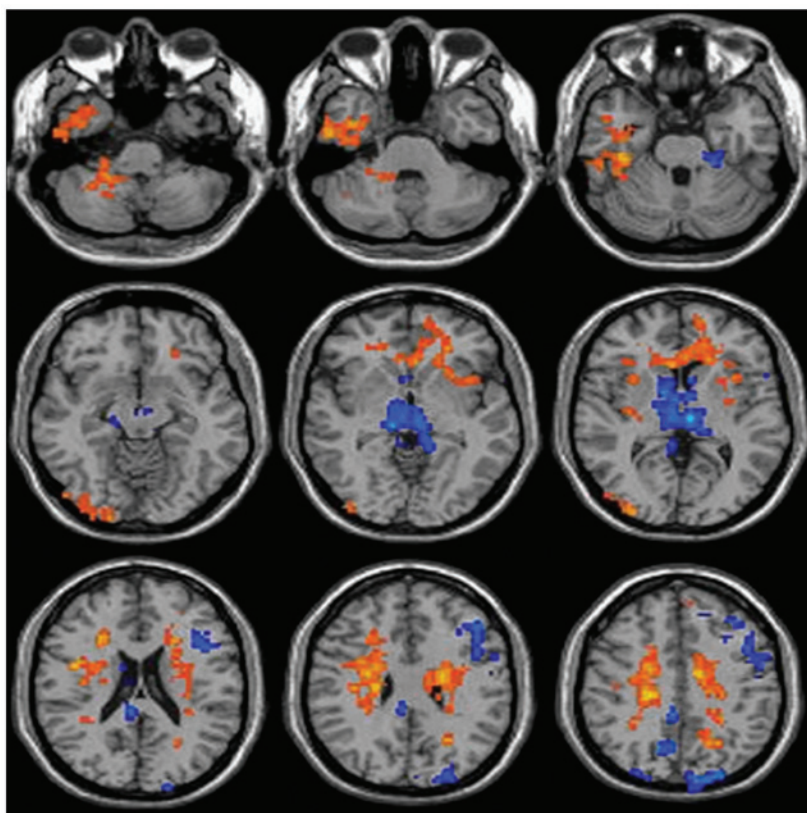


Figure 2. Brain areas with abnormal regional homogeneity (ReHo) values following a single oral administration of codeine phosphate (1.0 mg/kg), compared with images before administration. Red indicates increased ReHo and blue indicates decreased ReHo. The figure shows representative images from all of the subjects.

Table III. Concentrations of metabolites in the right frontal lobe prior to and following treatment with codeine phosphate.

Metabolite	Metabolite concentration (mmol/l)		t-value	P-value
	Prior to administration	Following administration		
Creatinine	4.90±0.71	5.14±0.99	-0.82	0.42
Glutamic acid	4.44±0.39	3.03±0.38	0.90	0.37
Inositol	4.96±0.35	4.54±0.25	0.95	0.35
N-acetyl aspartate	6.95±1.46	7.33±0.85	-0.91	0.38
Choline	1.34±0.11	1.75±0.13	-2.61	0.02

Data are presented as the mean ± standard deviation.

Table IV. Concentrations of metabolites in the left frontal lobe prior to and following treatment with codeine phosphate.

Metabolite	Metabolite concentration (mmol/l)		t-value	P-value
	Prior to administration	Following administration		
Creatinine	5.39±0.42	4.96±0.21	0.91	0.37
Glutamic acid	3.76±0.31	4.31±0.46	-0.32	0.75
Inositol	5.13±0.33	4.14±0.18	2.63	0.02
N-acetyl aspartate	7.46±0.91	7.41±0.66	0.07	0.95
Choline	1.19±0.08	1.44±0.06	-2.41	0.03

Data are presented as the mean ± standard deviation.

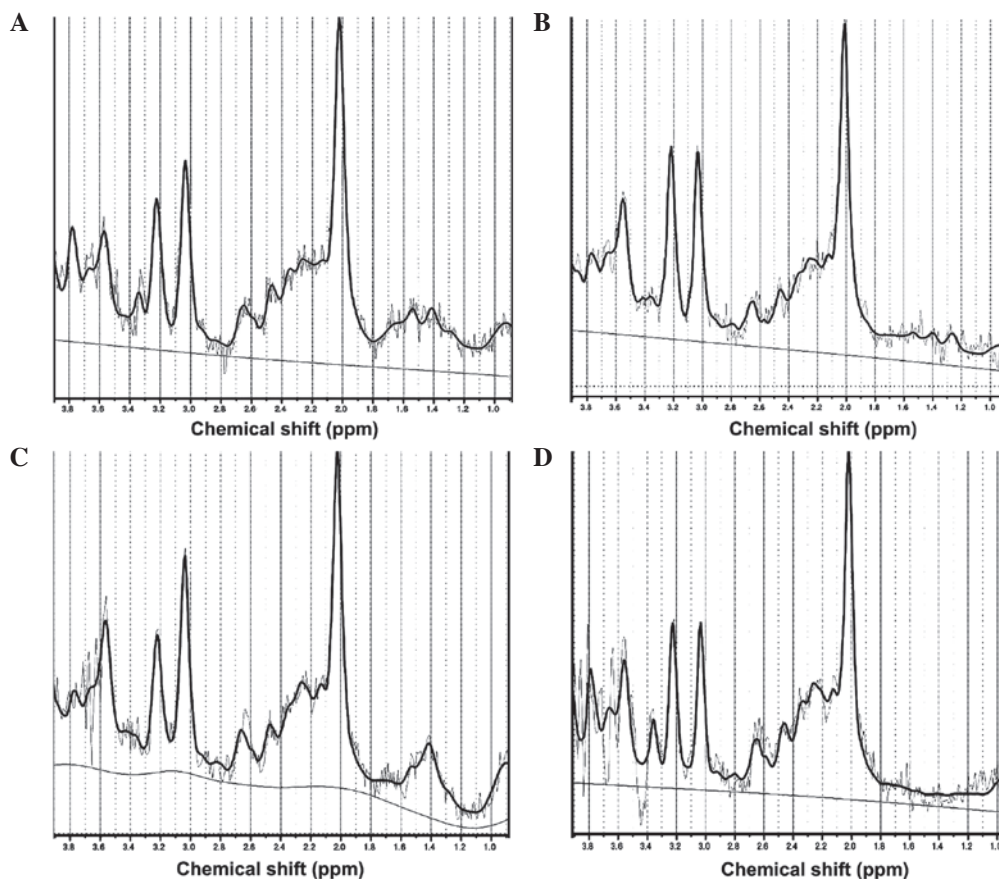


Figure 3. ¹H-MR spectra from the same subject. Magnetic resonance spectroscopy maps of the right frontal lobe (A) prior to and (B) following oral administration of codeine phosphate (1.0 mg/kg), and the left frontal lobe (C) prior to and (D) following oral administration of codeine phosphate (1.0 mg/kg).

t-tests. The ReHo and ALFF maps were compared using paired t-tests with the 'Statistical Analysis' module in REST. A P-value of <0.05 combined with a cluster size of >25 voxels was considered to indicate a statistically significant difference. All within-group statistical maps of ReHo and ALFF were superimposed on the anatomical template (Ch2.nii) for presentation purposes (29).

Results

fMRI results. At 1 h after codeine phosphate administration, the ALFF values were significantly altered in various brain regions (Fig. 1; Table I). These regions predominately included the sensorimotor system, limbic system, reward system and corona radiata. The ALFF values increased in the right frontal lobe white matter, right parietal white matter, right superior parietal lobule, right inferior frontal gyrus, right limbic lobe, right insula, right cuneus, right parahippocampal gyrus, right cerebellum crus 2, left parietal white matter, left frontal lobe white matter, left superior parietal lobule, left superior frontal gyrus, left cingulate, left insula, left cuneus, left thalamus, left cerebral peduncle and left pons. The ALFF values decreased in the left thalamus but did not change in the globus pallidus.

The ReHo values were also altered in various brain areas (Fig. 2; Table II). These regions primarily included the bilateral corona radiata, genu of the corpus callosum, left frontal lobe, right temporal lobe, bilateral parietal lobe, right cerebellum and thalamus. The ReHo values increased mainly in left corona radiata, right corona radiata, Genu of corpus callosum, Left insular lobe, Left putamen, Right insular lobe, right lateral occipitotemporal gyrus, right parahippocampal gyrus, right middle cerebral peduncle, right inferior temporal gyrus and right cerebellum posterior lobe. The ReHo values declined in left precentral gyrus, left cuneus, left middle frontal gyrus, left inferior frontal gyrus, left thalamus, left cerebral peduncle, right precuneus, right cingulated gyrus and right thalamus (Fig. 2; Table II).

¹H-MRS results. The high-quality ¹H-MRS data, which are presented in Fig. 3A-D, indicated that the metabolite peaks were located as follows: N-acetyl aspartate (2.0 ppm), creatinine (3.03 ppm), choline (3.2 ppm), inositol (3.56 ppm) and glutamic acid (2.1 ppm). These results coincide with those previously reported in the literature (30). The choline content was significantly increased in the right and left frontal lobes following oral codeine phosphate administration (P=0.02 and P=0.03, respectively; Tables III and IV). By contrast, the inositol content was significantly decreased in the left frontal lobe (P=0.02; Table IV). However, the glutamic acid content did not change significantly in the frontal lobes following codeine phosphate administration. Compared with before administering codeine phosphate, the concentrations of NAA and Cr in the both frontal lobe had no statistical significance.

In the present study, the ALFF and ReHo values of different brain regions following administration of a single, low dose of codeine phosphate in healthy volunteers were detected by R-S fMRI. The ALFF values decreased in the left thalamus but the ALFF values in the globus pallidus did not change. Moreover, the metabolic changes in the two sides of the frontal lobe were identified by ¹H MRS, particularly

the concentration changes in inositol, choline and glutamic acid contents.

Discussion

ALFF is defined as the total power of low-frequency oscillations between 0.01 and 0.1 Hz (31). It is a marker for differences between individuals or brain dysfunction (32). In the present study, the ALFF values were altered in different brain areas 1 h after a single, low-dose, oral administration of codeine phosphate in healthy volunteers; these regions included the sensorimotor system, limbic system, connection between hemispheres and reward system. Opioid receptors exist in these areas and are activated when codeine binds to them; thus, the neuronal cell functional status and structure change accordingly (33).

In a previous opioid addiction study, thalamic functions were decreased and were an area of investigation. The data of the present study indicated that the ALFF values decreased in the left thalamus after a single, low-dose, oral administration of codeine phosphate. Declined ALFF values of the left thalamus had always been seen as an important indicator for opioid addiction (34). However, based on the results of the present study this decline is believed to be a side effect of opioid drugs that extend beyond the effects associated with drug dependence. However, the ALFF values in the globus pallidus did not change in the present study. A decrease in the ALFF values of the globus pallidus has previously been suggested as a marker for opioid addiction (35). Thus, these findings indicate that a single, low-dose administration of codeine phosphate does not impact the ALFF value in the globus pallidus. Compared with other chronic opioid drug administration, the ALFF value in globus pallidus was changed (36). These findings are of potential significance for future studies regarding codeine phosphate dependence, since the ALFF values in the globus pallidus may represent a marker that has the potential to differentiate between the effects of acute and chronic codeine phosphate intake. However, the specific point at which the ALFF values in the globus pallidus change as a result of the transition to codeine phosphate addiction requires further investigation.

ReHo is a voxel-based measurement of brain activity that does not require an *a priori* definition of regions of interest and can provide information regarding the local activity of regions throughout the brain (37). ReHo values reflect the similarity of time consistency between a voxel and its neighboring voxel (38). Increased ReHo values indicate that regional brain activity is more synchronized. The synchronization of brain regions is responsible for the regulation of brain processing and the organization of information in space and time (39). In the current study, brain regions with high ReHo values indicated an increased capacity of relevant brain regions to manage information. Furthermore, brain regions with low ReHo values indicated that these brain areas were weaker in handling information. Regardless of ALFF or ReHo applications, the present study identified a small alteration in cerebrospinal fluid that appeared to be inconsequential; however, cerebrospinal fluid presented low frequency oscillations and a similar circulating consistency, which has been previously reported (40).

The results in the current study identified that inositol content decreased in the left frontal lobe following a single, low-dose administration of codeine phosphate, which may be

associated with functional alterations in brain voxels. Typically, the metabolites of the voxel exchange with external brain areas increase due to increased blood flow and blood velocity. In addition, an increased choline content in the two frontal lobes was identified following codeine phosphate administration (41,42). Choline is a constituent of cell membranes and reflects membrane turnover, while it is also a precursor of acetylcholine and phosphatidylcholine (43); thus, it is involved in membrane status, memory, cognition and mood. In the present study, the ALFF increased in voxels that exhibited metabolite changes in the frontal lobe. The ALFF-enhanced brain regions exhibit increased excitability and metabolism; therefore, the increase in choline content may explain the increase in the ALFF signal in the frontal lobe (44).

The glutamic acid content was unchanged in the frontal lobe in the current study. Thus, a single, low-dose administration of codeine phosphate did not affect the glutamate metabolite level in the frontal lobe, as identified using ¹H-MRS. Glutamic acid can function as an excitotoxin, which may cause nerve-cell injury in a variety of neurological disorders, including drug addiction (45). Strong and illicit opium drug dependence can cause glutamate concentration changes in the frontal cortex (46-48). Thus, the results in the present study are significant for future studies regarding codeine phosphate dependence, since they indicate that a single, low-dose administration of codeine phosphate induces different effects on brain glutamate concentrations in the frontal cortex when compared with the findings from more chronic administrations (49-51). Therefore, glutamate metabolites in the frontal cortex may represent a potential marker for the estimation of weak opium drug dependence.

In conclusion, the results of the current study indicated that the ALFF and ReHo values changed in different brain regions, and the content of various metabolites changed in the frontal lobe following low-dose codeine phosphate administration in healthy volunteers. These results clearly indicate that codeine phosphate affects brain function and metabolism. Furthermore, these techniques may be used in future studies to examine more specific mechanisms of codeine phosphate addiction.

Acknowledgements

The present study was supported by the key program of the National Natural Science Foundation of China (grant nos. 81471730 and 81371612) and the Natural Science Foundation of Guangdong Province (grant no. S2013010013867).

References

- Ammon S, Marx C, Behrens C, Hofmann U, Mürdter T, Griese EU and Mikus G: Diclofenac does not interact with codeine metabolism in vivo: A study in healthy volunteers. *BMC Clin Pharmacol* 27: 2:2, 2002.
- Licata SC and Renshaw PF: Neurochemistry of drug action: insights from proton magnetic resonance spectroscopic imaging and their relevance to addiction. *Ann N Y Acad Sci* 1187: 148-171, 2010.
- Magalhaes AC: Functional magnetic resonance and spectroscopy in drug and substance abuse. *Top Magn Reson Imaging* 16: 247-251, 2005.
- Paterson JR, Talwar DK, Watson ID and Stewart MJ: Codeine abuse from co-codaprin. *Lancet* 335: 224, 1990.
- Hall WD and Mattick RP: Clinical update: Codeine maintenance in opioid dependence. *Lancet* 370: 550-552, 2007.
- Cao Z, Lin PY, Shen ZW, Xiao YY and Wu RH: 7.0 T high-resolution 1H-MR spectroscopy of metabolic changes induced by chronic codeine phosphate in rat hippocampus. *Neuroreport* 26: 735-739, 2015.
- Jansen JF, Backes WH, Nicolay K and Kooi ME: 1H MR spectroscopy of the brain: Absolute quantification of metabolites. *Radiology* 240: 318-332, 2006.
- Schaller B, Xin L, Cudalbu C and Gruetter R: Quantification of the neurochemical profile using simulated macromolecule resonances at 3 T. *NMR Biomed* 26: 593-599, 2013.
- Raschke F, Fuster-Garcia E, Opstad KS and Howe FA: Classification of single-voxel 1H spectra of brain tumours using LCModel. *NMR Biomed* 25: 322-331, 2012.
- Liemburg E, Sibeijn-Kuiper A, Bais L, Pijnenborg G, Kneegting H, van der Velde J, Opmeer E, de Vos A, Dlabac-De Lange J, Wunderink L and Aleman A: Prefrontal NAA and Glx levels in different stages of psychotic disorders: A 3T (1)H-MRS study. *Sci Rep* 6: 21873, 2016.
- Westman E, Spenger C, Oberg J, Reyer H, Pahnke J and Wahlund LO: In vivo 1H-magnetic resonance spectroscopy can detect metabolic changes in APP/PS1 mice after donepezil treatment. *BMC Neurosci* 10: 33, 2009.
- Quinque EM, Karger S, Arélin K, Schroeter ML, Kratzsch J and Villringer A: Structural and functional MRI study of the brain, cognition and mood in long-term adequately treated Hashimoto's thyroiditis. *Psychoneuroendocrinology* 42: 188-198, 2014.
- Chou YH, Panych LP, Dickey CC, Petrella JR and Chen NK: Investigation of long-term reproducibility of intrinsic connectivity network mapping: A resting-state fMRI study. *AJNR Am J Neuroradiol* 33: 833-838, 2012.
- Fox MD and Greicius M: Clinical applications of resting state functional connectivity. *Front Syst Neurosci* 4: 19, 2010.
- Rosazza C and Minati L: Resting-state brain networks: Literature review and clinical applications. *Neurol Sci* 32: 773-785, 2011.
- Ma N, Liu Y, Li N, Wang CX, Zhang H, Jiang XF, Xu HS, Fu XM, Hu X and Zhang DR: Addiction related alteration in resting-state brain connectivity. *Neuroimage* 49: 738-744, 2010.
- Liu J, Qin W, Yuan K, Li J, Wang W, Li Q, Wang Y, Sun J, von Deneen KM, Liu Y and Tian J: Interaction between dysfunctional connectivity at rest and heroin cues-induced brain responses in male abstinent heroin-dependent individuals. *PLoS One* 6: e23098, 2011.
- Peregud DI, Yakovlev AA, Stepanichev MY, Onufriev MV, Panchenko LF and Gulyaeva NV: Content of mRNA for NMDA glutamate receptor subunits in the frontal cortex and striatum of rats after morphine withdrawal is related to the degree of abstinence. *Bull Exp Biol Med* 153: 835-838, 2012 (In English, Russian).
- Raungrut P, Uchaipichat V, Elliot DJ, Janchawee B, Somogyi AA and Miners JO: In vitro-in vivo extrapolation predicts drug-drug interactions arising from inhibition of codeine glucuronidation by dextropropoxyphene, fluconazole, ketoconazole and methadone in humans. *J Pharmacol Exp Ther* 334: 609-618, 2010.
- George O and Koob GF: Individual differences in prefrontal cortex function and the transition from drug use to drug dependence. *Neurosci Biobehav Rev* 35: 232-247, 2010.
- Llamas-Velasco S, Llorente-Ayuso L, Contador I and Bermejo-Pareja F: Spanish versions of the Minimental State Examination (MMSE). Questions for their use in clinical practice. *Rev Neurol* 61: 363-371, 2015.
- Yuan J, Blumen HM, Verghese J and Holtzer R: Functional connectivity associated with gait velocity during walking and walking-while-talking in aging: a resting-state fMRI study. *Hum Brain Mapp* 36: 1484-1493, 2015.
- Gao Y, Liao L and Blok BF: A resting-state functional MRI study on central control of storage: brain response provoked by strong desire to void. *Int Urol Nephrol* 47: 927-935, 2015.
- Lee YB, Lee J, Tak S, Lee K, Na DL, Seo SW, Jeong Y, Ye JC and Alzheimer's Disease Neuroimaging Initiative: Sparse SPM: Group sparse-dictionary learning in SPM framework for resting-state functional connectivity MRI analysis. *Neuroimage* 125: 1032-1045, 2016.
- Chao-Gan Y and Yu-Feng Z: DPARSF: A MATLAB toolbox for 'Pipeline' data analysis of resting-state fMRI. *Front Syst Neurosci* 4: 13, 2010.
- Clayton GM and Devasia S: Iterative image-based modeling and control for higher scanning probe microscope performance. *Rev Sci Instrum* 78: 083704, 2007.

27. Zhao L, Liu J, Dong X, Peng Y, Yuan K, Wu F, Sun J, Gong Q, Qin W and Liang F: Alterations in regional homogeneity assessed by fMRI in patients with migraine without aura stratified by disease duration. *J Headache Pain* 14: 85, 2013.
28. Cao Z, Ye BD, Shen ZW, Cheng XF, Yang ZX, Liu YY, Wu RH, Geng K and Xiao YY: 2D-1H proton magnetic resonance spectroscopic imaging study on brain metabolite alterations in patients with diabetic hypertension. *Mol Med Rep* 11: 4232-4238, 2015.
29. Palanca BJ, Mitra A, Larson-Prior L, Snyder AZ, Avidan MS and Raichle ME: Resting-state functional magnetic resonance imaging correlates of sevoflurane-induced unconsciousness. *Anesthesiology* 12: 346-356, 2015.
30. Shen ZW, Cao Z, You KZ, Yang ZX, Xiao YY, Cheng XF, Chen YW and Wu RH: Quantification of choline concentration following liver cell apoptosis using 1H magnetic resonance spectroscopy. *World J Gastroenterol* 18: 1130-1136, 2012.
31. Ni L, Liu R, Yin Z, Zhao H, Nedelska Z, Hort J, Zhou F, Wu W, Zhang X, Li M, Yu H, Zhu B, Xu Y and Zhang B: Aberrant spontaneous brain activity in patients with mild cognitive impairment and concomitant lacunar infarction: A resting-state functional MRI study. *J Alzheimers Dis* 50: 1243-1254, 2016.
32. Zou QH, Zhu CZ, Yang Y, Zuo XN, Long XY, Cao QJ, Wang YF and Zang YF: An improved approach to detection of amplitude of low-frequency fluctuation (ALFF) for resting-state fMRI: Fractional ALFF. *J Neurosci Methods* 172: 137-141, 2008.
33. Jiang GH, Qiu YW, Zhang XL, Han LJ, Lv XF, Li LM, Lin CL, Zhuo FZ, Hu SY and Tian JZ: Amplitude low-frequency oscillation abnormalities in the heroin users: A resting state fMRI study. *Neuroimage* 57: 149-154, 2011.
34. Denier N, Schmidt A, Gerber H, Vogel M, Huber CG, Lang UE, Riecher-Rössler A, Wiesbeck GA, Radue EW, Walter M and Borgwardt S: Abnormal functional integration of thalamic low frequency oscillation in the BOLD signal after acute heroin treatment. *Hum Brain Mapp* 36: 5287-5300, 2015.
35. Muskens JB, Schellekens AF, de Leeuw FE, Tendolkar I and Heparik S: Damage in the dorsal striatum alleviates addictive behavior. *Gen Hosp Psychiatry* 34: 702.e9-702.e116, 2012.
36. Chu LF, Lin JC, Clemenson A, Encisco E, Sun J, Hoang D, Alva H, Erlendson M, Clark JD and Younger JW: Acute opioid withdrawal is associated with increased neural activity in reward-processing centers in healthy men: A functional magnetic resonance imaging study. *Drug Alcohol Depend* 153: 314-322, 2015.
37. Liang P, Liu Y, Jia X, Duan Y, Yu C, Qin W, Dong H, Ye J and Li K: Regional homogeneity changes in patients with neuro-myelitis optica revealed by resting-state functional MRI. *Clin Neurophysiol* 122: 121-127, 2011.
38. Neubauer AC and Fink A: Intelligence and neural efficiency. *Neurosci Biobehav Rev* 33: 1004-1023, 2009.
39. Strik C, Klose U, Erb M, Strik H and Grodd W: Intracranial oscillations of cerebrospinal fluid and blood flows: Analysis with magnetic resonance imaging. *J Magn Reson Imaging* 15: 251-258, 2002.
40. Castillo M, Kwok L and Mukherji SK: Clinical applications of proton MR spectroscopy. *AJNR Am J Neuroradiol* 17: 1-15, 1996.
41. Feuerstein D, Takagaki M, Gramer M, Manning A, Endepols H, Vollmar S, Yoshimine T, Strong AJ, Graf R and Backes H: Detecting tissue deterioration after brain injury: Regional blood flow level versus capacity to raise blood flow. *J Cereb Blood Flow Metab* 34: 1117-1127, 2014.
42. Horita A, Carino MA and Chinn C: Codeine produces a cholinergically mediated analeptic effect in rats and rabbits. *Pharmacol Biochem Behav* 3: 115-118, 1988.
43. Yang ZX, Huo SS, Cheng XF, Xu ZF, Cao Z, Zeng JX, Xiao YY, You KZ, Chen W, Liu YY and Wu RH: Quantitative multivoxel proton MR spectroscopy study of brain metabolites in patients with amnesic mild cognitive impairment: A pilot study. *Neuroradiology* 54: 451-458, 2012.
44. Li Z, Zhu Y, Childress AR, Detre JA and Wang Z: Relations between BOLD fMRI-derived resting brain activity and cerebral blood flow. *PLoS One* 7: e44556, 2012.
45. Hermann D, Frischknecht U, Heinrich M, Hoerst M, Vollmert C, Vollstädt-Klein S, Tunc-Skarka N, Kiefer F, Mann K and Ende G: MR spectroscopy in opiate maintenance therapy: Association of glutamate with the number of previous withdrawals in the anterior cingulate cortex. *Addict Biol* 17: 659-667, 2012.
46. Gao H, Xiang Y, Sun N, Zhu H, Wang Y, Liu M, Ma Y and Lei H: Metabolic changes in rat prefrontal cortex and hippocampus induced by chronic morphine treatment studied *ex vivo* by high resolution ¹H NMR spectroscopy. *Neurochem Int* 50: 386-394, 2007.
47. Hermann D, Frischknecht U, Heinrich M, Hoerst M, Vollmert C, Vollstädt-Klein S, Tunc-Skarka N, Kiefer F, Mann K and Ende G: MR spectroscopy in opiate maintenance therapy: Association of glutamate with the number of previous withdrawals in the anterior cingulate cortex. *Addict Biol* 17: 659-667, 2012.
48. Salehi M, Zargar A and Ramezani MA: Effects of dextromethorphan on reducing methadone dosage in opium addicts undergoing methadone maintenance therapy: A double blind randomized clinical trial. *J Res Med Sci* 16: 1354-1360, 2011.
49. Garzón J, Rodríguez-Muñoz M and Sánchez-Blázquez P: Direct association of Mu-opioid and NMDA glutamate receptors supports their cross-regulation: molecular implications for opioid tolerance. *Curr Drug Abuse Rev* 5: 199-226, 2012.
50. Rao P, Yallapu MM, Sari Y, Fisher PB and Kumar S: Designing novel nanoformulations targeting glutamate transporter excitatory amino acid transporter 2: Implications in treating drug addiction. *J Pers Nanomed* 1: 3-9, 2015.
51. Krall AS and Christofk HR: Rethinking glutamine addiction. *Nat Cell Biol* 17: 1515-1517, 2015.