

Genital scabies: Haven of an unwelcome guest

Hima Gopinath, Kaliaperumal Karthikeyan¹

Department of Dermatology, All India Institute of Medical Sciences, Mangalagiri, Andhra Pradesh, ¹Department of Dermatology, Venereology and Leprosy, Sri Manakula Vinayagar Medical College and Hospital, Puducherry, India

Address for correspondence:

Dr. Hima Gopinath, All India Institute of Medical Sciences, Mangalagiri, Guntur - 522 503, Andhra Pradesh, India. E-mail: hima36@gmail.com

Abstract

The itch mite *Sarcoptes scabiei* var. *hominis* has been a menace to humanity for ages. Diagnosing scabies can be a challenge in view of the varied presentations of the disease. The male genitalia are an important area of predilection of the mite. Examination of this often overlooked area is essential as it may reveal both characteristic and atypical manifestations of scabies. Genital involvement also attains special relevance in view of the possible sexual transmission of the mite. In addition to the morbidity caused by itching, patients may have to deal with myths, stigma, and embarrassment.

Key words: Genital infection, scabies, sexually transmitted diseases

INTRODUCTION

Scabies caused by *Sarcoptes scabiei* var. *hominis* is a common health problem with a worldwide prevalence of around 300 million/year.^[1] The link between the mite and the disease was described in 1687 by Giovanni Cosimo Bonomo.^[2] Scabies affects humanity irrespective of sex, age, socioeconomic class, or ethnicity and can cause debilitating and depressing itch. It can present with typical or atypical presentations and mimic a wide range of diseases. The male genitalia are a classical site of infestation.^[3,4] Scabies can be sexually transmitted and lesions limited to the genitalia or genital itch may be among the presenting features of the disease causing diagnostic dilemmas.^[2,5,6]

ETIOLOGY

The causative agent of scabies is the burrowing obligate ectoparasite, *S. scabiei* var. *hominis*.^[7] The life cycle involves eggs, larvae, protonymphs, and tritonymphs prior to emergence of the adult mite.^[8,9]

GENITAL INVOLVEMENT IN SCABIES

Genital lesions are commonly reported (16.8%–60%) in clinical studies on human scabies.^[10–13] However, the genitalia are usually spared in animal scabies.^[14] In a case series of 886 men with scabies, Mellenby isolated 8.4% of the total mites from the penis and scrotum and 4% from the buttocks.^[15] The different structures, varying epithelium, moisture, higher temperature, and mechanical friction in the genital area may modify the presentation of dermatoses.^[16]

The exact mechanisms of host seeking and reasons for localization in specific sites are not known. Scabies mites respond to thermal, chemical, light, and odor stimuli.^[17] The mites are lesser in areas with increased density of pilosebaceous glands.^[18] Soft folded skin may be preferred by the mite.^[19] The mites, especially adult females, are attracted to 17 lipids present in or on the epidermis. These

This is an open access journal, and articles are distributed under the terms of the Creative Commons Attribution-NonCommercial-ShareAlike 4.0 License, which allows others to remix, tweak, and build upon the work non-commercially, as long as appropriate credit is given and the new creations are licensed under the identical terms.

For reprints contact: reprints@medknow.com

How to cite this article: Gopinath H, Karthikeyan K. Genital scabies: Haven of an unwelcome guest. Indian J Sex Transm Dis 2020;41:10-6.

Submitted: 20-Jan-2018

Revised: 10-Apr-2018

Accepted: 30-Dec-2019

Published: 18-Jun-2020

Access this article online

Quick Response Code:



Website:

www.ijstd.org

DOI:

10.4103/ijstd.IJSTD_69_17

included both saturated (pentanoic, hexanoic, octanoic, lauric, pentadecanoic, and stearic acid) and unsaturated fatty acids (oleic, linoleic, and arachidonic), fatty acid methyl esters, cholesterol, squalene, and tripalmitin.^[20] Mites are also attracted to nitrogenous waste and phenolic compounds that may act like pheromones and cause aggregation of mites.^[21] Scabies mite proteases assist digestion of host proteins and enable penetration and migration through skin. Ease of availability of nutrients and chemical, physical, and immunological attributes of skin in different areas may be responsible for distribution of the mite in specific areas.^[20,22]

CLINICAL FEATURES

Classical scabies usually presents with pruritus that is worse at night. Symptoms usually begin 3–4 weeks after infestation. However, pruritus may manifest immediately in previously sensitized individuals.^[23,24]

The pruritus is of two types: a generalized type and the localized type. The localized pruritus is of a burning type caused by activity of the mite. Rarely, patients may not have itch.^[25] Pruritus of the penis may be an early clue of scabies infestation.^[26] Pruritus occurring exclusively on the scrotum has also been reported.^[6]

Two main types of cutaneous lesions are seen: a generalized pruritic papular eruption and papules and vesicles associated with burrows. The latter is associated with the presence of the mite. The tiny papules (“larval papules”) and vesicles associated with the burrows may be single or grouped and are due to reaction to larvae or immature stages of the mite. Papular lesions on the penis and scrotum are of diagnostic value in scabies. The generalized eruption is profuse, severely itchy, and is mainly seen in the axilla, periareolar region, abdomen, buttocks, and thighs.^[9,23,25]

A burrow is classical sign of the disease. They are grayish, reddish, or brownish, 2–15 mm long serpiginous tunnels, wherein copulation, ovulation, and birth of larvae occur.^[2,27] Burrows are common in areas where there are no or few hair follicles and where the stratum corneum is thin and soft making the genital area an ideal site for infestation. The color of the burrow may vary with the site affected, color of skin, and cleanliness. Burrows on the penis, buttocks, elbows, and knees appear pale [Figure 1].^[25,26] Burrows can be obliterated by bathing, scratching, crust formation, or secondary infection.^[28] Many typical burrows and papules



Figure 1: Burrow on the shaft of the penis

may be seen on the glans penis, penile shaft, and scrotum.^[29] The crease in the lower part of the buttocks where it joins the upper thigh is affected in scabies. Natal cleft involvement and extension onto the buttocks may occur [Figure 2].^[30] Pustules may develop on the buttocks in those who are seated for long time.^[25] Knowles reported marked involvement of the penis with many burrows and pustules in military personnel during World War I.^[31] Burrows limited to the penis have also been reported in Japanese prisoner of war camps.^[25]

Scabies usually affects thighs and buttocks and spares vulva in females.^[32] However, scabies may cause pruritus vulvae, and vulvar nodules have been reported.^[33,34]

Secondary lesions such as excoriations, crusts, eczematization, and secondary infections may be seen [Figure 3a and b].^[35] Chronic scratching and irritation may cause hyperpigmentation.^[26]

ATYPICAL SCABIES

Nodular scabies

Nodular or granulomatous scabies presents with firm, dull-red, brownish-red, or violaceous pruritic nodules measuring up to 2 cm that persist for months despite treatment. Nodules are seen on covered areas or soft skin such as may be seen over the elbows, axilla, thighs, penis, and scrotum [Figure 4a-c]. Secondary infection or eczematization may alter the clinical appearance. The nodules do not indicate the presence of the mite. It represents a hypersensitivity response to the mite antigens.^[35-38] It has been proposed that antigenic components of the mite enter the dermis and produce nodular lesions.^[39] The histopathology of nodular scabies is similar to persistent bite

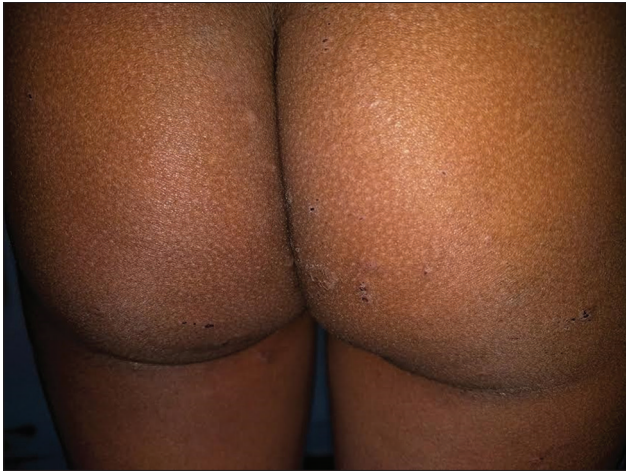

Figure 2: Excoriated gluteal papules

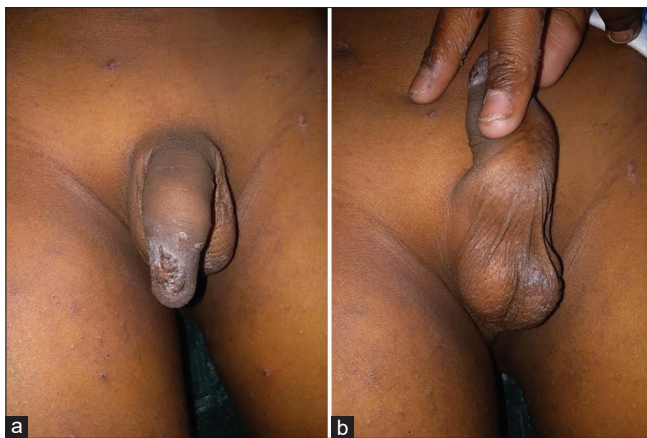

Figure 3: (a) Eczematous crusted plaque on the penis. (b) Excoriated papules over the scrotum

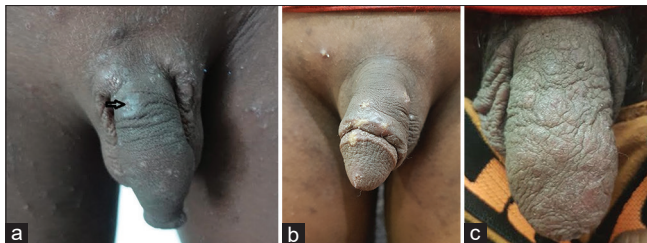


Figure 4: (a and b) Ulcerated nodules on the penis. (c) Erythematous plaques and nodules over the penis and scrotum

reactions with dense superficial and deep infiltrate of lymphocytes, macrophages, plasma cells, eosinophils, Langerhans cells, and atypical mononuclear cells. Lymphoid follicles may be present.^[40]

Nonpersistent nodules may be seen in infants. Nonpersistent hemorrhagic nodules that ulcerated and mimicked chancres have been reported on the penis.^[25]

Vesiculobullous scabies

Vesiculobullous scabies is a rare subtype predominantly affecting elderly individuals.^[36] It may

mimic bullous pemphigoid or can present with true bullous pemphigoid triggered by scabies. Bullous scabies may also be seen in very young children due to thin stratum corneum and loosely attached epithelial layers.^[38] Bullous lesions may involve the genitalia. Penile bullae that showed poor response to topical steroids but responded to topical sulfur have been reported.^[41]

Crusted scabies

Crusted scabies or Norwegian scabies presents with massive infestation of mites in immunocompromised patients and those with reduced sensations or inability to scratch. It presents with thick crusts and warty hyperkeratotic lesions. Lesions are usually extensive, atypical, and can involve atypical sites.^[38] Burrows, vesicles, and papules may be masked by the keratotic plaques. Margins of the plaques or non-keratotic areas such as a penis may reveal burrows.^[25] Crusted scabies may have generalized or localized presentations. Lesions may be limited to the genitalia in both males and females. Crusted scabies presenting as a single, asymptomatic, thick crusted plaque on the shaft of the penis has been reported in an AIDS patient.^[5] Crusted scabies of the vulva presenting with an ill-defined yellowish and beige psoriasiform plaque on the labia majora and clitoris has been reported in an HIV patient. It was proposed the weight loss, thinning, and protrusion of labia minora, and increased keratinization due to loss of moisture might have led to the unusual involvement of the vulva. Crusted scabies is a differential for scaly plaques that appear “like heaps of beige sand” in any location or of any size.^[42]

Scabies incognito

Topical and oral steroids may alter the presentation of scabies. There is cutaneous atrophy, reduced inflammation, increased vascularity, and increased secondary infection. There may be vesicles, pustules, and nodules along with manifestations of steroid use.^[38]

COMPLICATIONS

Secondary infections

Scabies can disrupt the skin barrier, and predispose to staphylococcal and streptococcal infections. There may be impetigo, ecthyma, furuncles, lymphangitis, and cellulitis. Streptococcal infections may lead to poststreptococcal glomerulonephritis.^[23]

Sepsis and death may occur in immunocompromised patients. Infections in the genital region can cause inguinal lymphadenopathy and bubo formation.^[37,43]

Psychological effects

Genital scabies has deleterious effect on the psychosexual well-being of patients. Patients may have disbelief, shame, guilt, and persistent delusions of parasitosis. Counseling on the nature of the disease and its transmission of the disease is needed.^[37]

Others

Genital scabies has also been associated with male genital edema [Figure 5].^[44]

Post-scabetic pruritus

Post-scabetic pruritus may be present for days to weeks after treatment due to hypersensitivity to the mite antigens.^[37]

SCABIES AS A SEXUALLY TRANSMITTED DISEASE

Scabies is recognized as a sexually transmitted disease.^[8] The localization of lesions over the genital area may cause diagnostic difficulties with other sexually transmitted infections.^[16] The distribution of the mite is not related to the site of infection.^[45] Scabies is transmitted by close physical contact. The fertilized female mite is implicated in transmission, but numerous immature mites on the skin surface may have a more significant role.^[43] Sexual transmission is not the common route, and the association with other sexually transmitted diseases is controversial.^[25] It does not have the classical pattern of sexually transmitted diseases, and the incidence trends do not parallel other sexually transmitted infections.^[43] Nonsexual transmission may occur among family members. Fomite transmission can occur.^[2] This is rare in classical scabies, but fomites may be important in crusted scabies. Men who have sex with men and sporadic sexual contact are risk factors for scabies.^[3]

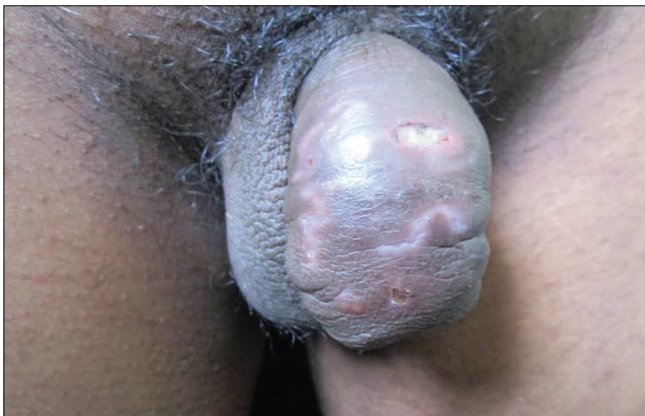

Figure 5: Penile edema with burrows of scabies

Singh *et al.* reported scabies as the most common venereal disease among juvenile inmates in a prison in India. This was attributed to common bedding and homosexual abuse by senior criminals.^[46] Otero *et al.* studied 9751 patients in a sexually transmitted infection clinic over a period of 15 years and found that the annual infestation percentage varied from 0.6% to 2.7%. A range of 0.3%–2.4% was reported by other authors. Cases were more frequent in autumn and winter. Scabies was most common in men who have sex and more common in heterosexual men compared to women.^[47]

SCABIES AND OTHER SEXUALLY TRANSMITTED INFECTIONS

Scabies is common in venereal disease clinics and has been reported to coexist with other sexually transmitted infections such as syphilis, gonorrhea, and pediculosis pubis. David *et al.* reported higher prior sexually transmitted diseases without significant coexisting sexually transmitted diseases.^[48] Evaluation of patients for other sexually transmitted disease is often recommended.^[8,49]

SCABIES AND SYPHILIS

“Chancre galeuse” is the syphilitic chancre occurring on the cutaneous lesions of scabies.^[25,49] Infiltrated papules found on the penis and scrotum may be confused with early syphilis.^[50]

SCABIES AND HIV

The prevalence of scabies in HIV is around 2%–4%.^[29] The mite does not transmit HIV.^[3] Typical scabies may be seen in HIV patients with minimal immunosuppression. As immunosuppression advances, two highly contagious and severe types of scabies are seen: papular or atypical or exaggerated scabies and crusted or hyperkeratotic or Norwegian scabies. Exaggerated scabies is intensely pruritic and characterized by generalized papules that may be topped by scaly burrows. Scabies must be suspected when there are atypical or itchy lesions in HIV and HIV should be ruled out in atypical manifestations of scabies particularly in patients with risk factors for HIV.^[51]

DIAGNOSIS

Demonstration of scabies mite, eggs, or feces in skin scrapings is the standard test for diagnosis. Web spaces, hands, feet, wrist, and penis are among the good sites to examine for the mite. Burrows and nearby vesicles and papules are scraped and examined under the microscope with mineral

oil, potassium hydroxide, or saline.^[2,37] Repeated scrapings from different sites may be needed as sensitivity is low. It is cumbersome to do and may be uncomfortable for the patient. Other tests include burrow ink test, adhesive plaster test, and polymerase chain reaction-based test for identifying the mite DNA in skin scrapings.^[52]

“Jetliner with a trail” appearance on dermoscopy can be used in the diagnosis of scabies. This may be difficult to appreciate in dark skin and hairy areas. Proximity of the examiner’s head to the genital area with handheld dermoscope may be embarrassing to the patient. Videodermoscopy can offer fast and clear demonstration of burrows, scabies mite, larvae, eggs, and feces.^[52]

Confocal reflectance microscopy and optical coherence tomography can demonstrate the burrows, scabies mite, larvae, and feces. However, both these diagnostic tests are expensive, have a long learning curve and low sensitivity, and are available only at specialized centers.^[52]

Skin biopsy may be done but is usually nonspecific.^[3] “Pink pigtail” structures connected to the stratum corneum are suggestive of scabies.^[28]

Detection of antibodies by ELISA which are present prior to onset of symptoms is a promising test.^[52]

Differential diagnosis

Scabies has been described as the easiest and yet the most difficult to diagnose.^[43] The differential diagnosis includes almost all pruritic dermatoses and includes urticarial, atopic dermatitis, lupus erythematosus, animal scabies, eczema, lichen planus, pityriasis rosea, dermatitis herpetiformis, necrotizing vasculitis, papular urticaria, delusion of parasitosis, and pruritic dermatoses of pregnancy. Sexually transmitted diseases mimicked by scabies include syphilis, pediculosis pubis, and phthiriasis pubis. The differential diagnosis of atypical manifestations of scabies is summarized in Table 1.^[23,25,36-38,53,54]

MANAGEMENT

Topical agents

Topical agents are the mainstay of therapy for genital scabies. Isolated genital involvement does not preclude from whole-body application of the agent. Genital skin is sensitive with increased systemic absorption of topical agents.^[16] Increased local absorption may occur from erosions of bullous scabies.^[38] Permethrin is the most effective agent

Table 1: Differential diagnosis of atypical scabies

Nodular scabies	Crusted scabies	Vesiculobullous scabies
Chronic lymphocytic leukemia	Psoriasis	Pemphigoid
B-cell lymphoma	Seborrheic dermatitis	Pemphigus
Lymphomatoid papulosis	Darier’s disease	Linear IgA disease
Urticaria pigmentosa	Eczema	Bullous impetigo
Cutaneous scrotal metastasis	Contact dermatitis	Acute contact dermatitis
	Langerhans cell histiocytosis	Epidermolysis bullosa
	Lichen planus	Arthropod bite reaction
	Ichthyosis	Infantile acropustulosis
		Eosinophilic pustular folliculitis

against scabies. It is synthetic pyrethroid that acts on sodium channels causing delayed repolarization, paralysis, and death. It can cause burning, stinging, and itchy, especially in sensitive eroded areas. The preservative formaldehyde may also cause allergic contact dermatitis.^[36,55] It is recommended, especially for infants, young children, and pregnant and lactating women.

Lindane is a second-line agent for scabies in view of its neurotoxicity. It is not recommended in children below 10 years. Increased absorption may occur immediately after bath or in patients with extensive dermatitis causing seizures. It may cause ulcerative irritant contact dermatitis, aplastic anemia, thrombocytopenia, and pancytopenia. Sulfur is among the oldest agents used for scabies. It can be used in pregnancy, infants, and in children but is irritant, messy, smelly, and stains clothes.^[36,56] Other agents include benzyl benzoate, malathion, esdepallethrine, monosulfiram, and crotamiton.^[57]

Compliance to topical therapy may be poor in situations where there are inadequate privacy and facilities. It may be difficult to apply in certain special situations such in aged care institutions in mentally and physically disabled individuals.^[55]

Ivermectin

Ivermectin is a synthetic macrocyclic lactone that blocks gamma-aminobutyric acid-gated chloride channels and causes paralytic death of the mite. It is a well-tolerated efficacious drug that ensures better compliance and avoids irritation of topical scabicides and convenient for bedridden patients.^[22,36] It is not recommended in pregnant and breastfeeding women and children weighing <15 kg. Moxidectin is a promising second-generation macrocyclic lactone that may be effective in a single dose. Other modalities being investigated include immunotherapy, vaccination, and direct targeting scabies mite molecules.^[55]

Special situations

Nodular scabies can be managed with topical or intralesional corticosteroids, topical pimecrolimus, and methotrexate in recalcitrant cases.

Postscabetic pruritus may require treatment with oral antihistaminics and emollients; topical and oral corticosteroids may be required in severe cases.^[36,37] The pruritus may last for several weeks, particularly in individuals with atopy. Test for cure by examination for living mite may be done, especially in crusted scabies.^[58]

Management of outbreaks, especially in institutions and epidemics, requires treatment of cases as well as at-risk population. Ivermectin along with topical scabicides is useful in such situations.^[56]

Scabies with HIV

Uncomplicated scabies in HIV-affected individuals are treated with the same regimens as HIV-negative individuals.^[56]

Crusted scabies

Combination therapy with 5% topical benzyl benzoate or 5% permethrin (daily for 1 week followed by twice-weekly till discharge or cure) along with oral ivermectin 200 µg/kg on 1, 2, 8, 9, and 15 has been recommended for crusted scabies. Severe cases can be administered additional doses on days 22 and 29. Lindane is not recommended as systemic absorption from the eroded areas can cause neurotoxicity.^[56]

The entire skin including the head should be treated. Isolation till cure is needed, along with epidemiological measures to treat contacts. Clothing and bedding may be washed at temperatures above 50°C, dry-cleaned or kept in a plastic bag for 7 days.^[58]

MANAGEMENT OF CONTACTS

Treatment of contacts at the same time as the case will reduce the chances of re-infestation.^[4] However, the Centers for Disease Control and Prevention recommends that close personal, household, and sexual contacts in the previous 1 month should be examined and treated if found to be infested.^[56] European guidelines recommend that sexual contacts in the previous two months are evaluated and treated. Sexual contact is to be avoided until both partners are treated condoms do not prevent transmission.^[58]

CONCLUSION

Genital involvement in scabies is often neglected. Awareness of the diverse manifestations of genital

scabies is needed to diagnose and manage the deceptive itch mite and its debilitating impact on humanity.

Financial support and sponsorship

Nil.

Conflicts of interest

There are no conflicts of interest.

REFERENCES

1. FitzGerald D, Grainger RJ, Reid A. Interventions for preventing the spread of infestation in close contacts of people with scabies. Cochrane Database of Syst Rev 2014. Art. No.: CD009943. DOI: 10.1002/14651858.CD009943.pub2.
2. Orion E, Matz H, Wolf R. Ectoparasitic sexually transmitted diseases: Scabies and pediculosis. Clin Dermatol 2004;22:513-9.
3. Chosidow O. Clinical practices. Scabies. N Engl J Med 2006;354:1718-27.
4. Strong M, Johnstone P. Interventions for treating scabies. Cochrane Database of Syst Rev 2007. Art. No.: CD000320. DOI: 10.1002/14651858.CD000320.pub2.
5. Perna AG, Bell K, Rosen T. Localised genital Norwegian scabies in an AIDS patient. Sex Transm Infect 2004;80:72-3.
6. Pomares C, Marty P, Delaunay P. Isolated itching of the genitals. Am J Trop Med Hyg 2014;90:589-90.
7. Karthikeyan K. Crusted scabies. Indian J Dermatol Venereol Leprol 2009;75:340-7.
8. Leone PA. Pubic lice and scabies. In: Holmes KK, Sparling PF, Stamm WE, Piot P, Wasserheit JN, Corey L, et al., editors. Sexually Transmitted Diseases. 4th ed. New York: McGraw-Hill; 2008. p. 0839-51.
9. Walton SE, Holt DC, Currie BJ, Kemp DJ. Scabies: New future for a neglected disease. Adv Parasitol 2004;57:309-76.
10. Kenawi MZ, Morsy TA, Abdalla KE, Nasr ME, Awadalla RA. Clinical and parasitological aspects on human scabies in Qalyobia governorate, Egypt. J Egypt Soc Parasitol 1993;23:247-53.
11. Sehgal VN, Rao TL, Rege VL, Vadiraj SN. Scabies: A study of incidence and a treatment method. Int J Dermatol 1972;11:106-11.
12. Jackson A, Heukelbach J, Filho AE, Júnior Ede B, Feldmeier H. Clinical features and associated morbidity of scabies in a rural community in Alagoas, Brazil. Trop Med Int Health 2007;12:493-502.
13. Das S, Chatterjee T, Banerji G, Biswas I. Evaluation of the commonest site, demographic profile and most effective therapy in scabies. Indian J Dermatol 2006;51:186-8.
14. Bandi KM, Saikumar C. Sarcoptic mange: A zoonotic ectoparasitic skin disease. J Clin Diagn Res 2013;7:156-7.
15. Johnson C, Mellanby K. The parasitology of human scabies. Parasitology. 1942;34:285
16. Meeuwis KA, de Hullu JA, Massuger LE, van de Kerkhof PC, van Rossum MM. Genital psoriasis: A systematic literature review on this hidden skin disease. Acta Derm Venereol 2011;91:5-11.
17. Arlian LG, Morgan MS, Rider SD Jr. *Sarcoptes scabiei*: Genomics to proteomics to biology. Parasit Vectors 2016;9:380.
18. Lane AT. Scabies and head lice. Pediatr Ann 1987;16:51-4.
19. Buxton PA. Parasitology of scabies. Br Med J 1941;2:397-401.
20. Arlian LG, Vyszynski-Moher DL. Response of *Sarcoptes scabiei* var. *Canis* (*Acari: Sarcoptidae*) to lipids of mammalian skin. J Med Entomol 1995;32:34-41.
21. Arlian LG, Vyszynski-Moher DL. Responses of *Sarcoptes scabiei* (*Acari: Sarcoptidae*) to nitrogenous waste and phenolic compounds.

- J Med Entomol 1996;33:236-43.
22. Hay RJ, Steer AC, Engelman D, Walton S. Scabies in the developing world – its prevalence, complications, and management. Clin Microbiol Infect 2012;18:313-23.
 23. Monsel G, Delaunay P, Chosidow O. Arthropods. In: Griffith CE, Barker J, Bleiker T, Chalmers R, Creamer D, editors. Rook's Textbook of Dermatology. 9th ed. Chichester: John Wiley and Sons; 2016. p. 34.39-34.47.
 24. McCarthy JS, Kemp DJ, Walton SE, Currie BJ. Scabies: More than just an irritation. Postgrad Med J 2004;80:382-7.
 25. Alexander JO. Scabies. Arthropods and human skin. New York: Springer-Verlag; 1984. p. 227-92.
 26. Meinking T. Infestations. Curr Probl Dermatol 1999;11:73-118.
 27. Currier RW, Walton SE, Currie BJ. Scabies in animals and humans: History, evolutionary perspectives, and modern clinical management. Ann N Y Acad Sci 2011;1230:E50-60.
 28. Golant AK, Levitt JO. Scabies: A review of diagnosis and management based on mite biology. Pediatr Rev 2012;33:e1-12.
 29. Buechner SA. Common skin disorders of the penis. BJU Int 2002;90:498-506.
 30. Orkin M. Scabies: Clinical aspects. In: Orkin M, Maibach HI, Parish LC, Schwartzman RM, editors. Scabies and Pediculosis. Philadelphia: Lippincott; 1977. p. 23-30
 31. Knowles FC. Scabies in military and civil life: Its differentiation, complications and treatment. JAMA 1918;71:1657-8.
 32. Weichert GE. An approach to the treatment of anogenital pruritus. Dermatol Ther 2004;17:129-33.
 33. Stewart KM. Clinical care of vulvar pruritus, with emphasis on one common cause, lichen simplex chronicus. Dermatol Clin 2010;28:669-80.
 34. Fischer G, Rogers M. Vulvar disease in children: A clinical audit of 130 cases. Pediatr Dermatol 2000;17:1-6.
 35. Heukelbach J, Feldmeier H. Scabies. Lancet 2006;367:1767-74.
 36. Hicks MI, Elston DM. Scabies. Dermatol Ther 2009;22:279-92.
 37. Chouela E, Abeldaño A, Pellerano G, Hernández MI. Diagnosis and treatment of scabies: A practical guide. Am J Clin Dermatol 2002;3:9-18.
 38. Cestari TE, Martignago BF. Scabies, pediculosis, bedbugs, and stinkbugs: Uncommon presentations. Clin Dermatol 2005;23:545-54.
 39. Thomson J, Cochrane T, Cochran R, McQueen A. Histology simulating reticulosis in persistent nodular scabies. Br J Dermatol 1974;90:421-9.
 40. Weedon D. Arthropod-induced diseases. In: Weedon D, editor. Weedon's Skin Pathology. 3rd ed. London: Churchill Livingstone; 2010. p. 652-63.
 41. Luo DQ, Huang MX, Liu JH, Tang W, Zhao YK, Sarkar R, *et al.* Bullous scabies. Am J Trop Med Hyg 2016;95:689-93.
 42. Bakos L, Reusch MC, D'Elia P, Aquino V, Bakos RM. Crusted scabies of the vulva. J Eur Acad Dermatol Venereol 2007;21:682-4.
 43. Leone P, Gopalkrishnan TV, Usha V. Scabies and Pediculosis. In: Gupta S, Kumar B, editors. Sexually Transmitted Infections. 2nd ed. New Delhi: Elsevier; 2012. p. 621-32.
 44. Weinberger LN, Zirwas MJ, English JC 3rd. A diagnostic algorithm for male genital oedema. J Eur Acad Dermatol Venereol 2007;21:156-62.
 45. Mellanby K. The development of symptoms, parasitic infection and immunity in human scabies. Parasitology 1944;35:197-206.
 46. Singh S, Prasad R, Mohanty A. High prevalence of sexually transmitted and blood-borne infections amongst the inmates of a District Jail in Northern India. Int J STD AIDS 1999;10:475-8.
 47. Otero L, Varela JA, Espinosa E, Sánchez C, Junquera ML, del Valle A, *et al.* *Sarcoptes scabiei* in a sexually transmitted infections unit: A 15-year study. Sex Transm Dis 2004;31:761-5.
 48. David N, Rajamanoharan S, Tang A. Are sexually transmitted infections associated with scabies? Int J STD AIDS 2002;13:168-70.
 49. Orkin M. Today's scabies. JAMA 1975;233:882-5.
 50. Obermayer ME. Medical entomology in relation to tropical dermatoses. JAMA 1943;123:454-8.
 51. Czelusta A, Yen-Moore A, Van der Straten M, Carrasco D, Tying SK. An overview of sexually transmitted diseases. Part III. Sexually transmitted diseases in HIV-infected patients. J Am Acad Dermatol 2000;43:409-32.
 52. Micali G, Lacarrubba F, Verzi AE, Chosidow O, Schwartz RA. Scabies: Advances in noninvasive diagnosis. PLoS Negl Trop Dis 2016;10:e0004691.
 53. Fujiyama T, Tokura Y. Clinical and histopathological differential diagnosis of eosinophilic pustular folliculitis. J Dermatol 2013;40:419-23.
 54. Hoyt BS, Cohen PR. Cutaneous scrotal metastasis: Origins and clinical characteristics of visceral malignancies that metastasize to the scrotum. Int J Dermatol 2013;52:398-403.
 55. Mounsey KE, Bernigaud C, Chosidow O, McCarthy JS. Prospects for moxidectin as a new oral treatment for human scabies. PLoS Negl Trop Dis 2016;10:e0004389.
 56. Workowski KA, Bolan GA. Centers for disease control and prevention. Sexually transmitted diseases treatment guidelines, 2015. MMWR Recomm Rep 2015;64:1-37.
 57. Karthikeyan K. Treatment of scabies: Newer perspectives. Postgrad Med J 2005;81:7-11.
 58. Salavastru CM, Chosidow O, Boffa MJ, Janier M, Tiplica GS. European guideline for the management of scabies. J Eur Acad Dermatol Venereol 2017;31:1248-53.