

## Case report

## Recurrence of herpes simplex encephalitis associated with temozolomide chemoradiation for malignant glioma: a case report and review of the literature

Mitalee P. Christman<sup>1</sup>, Sarah E. Turbett<sup>2</sup>, Soma Sengupta<sup>3</sup>, Khamidulla U. Bakhadirov<sup>4</sup>, Craig A. Williamson<sup>5</sup>, Lakshmi Nayak<sup>6</sup>, Tracey Milligan<sup>4</sup> and Joel T. Katz<sup>7,\*</sup>

<sup>1</sup>Harvard Medical School, Boston, MA, USA, <sup>2</sup>Division of Infectious Diseases, Massachusetts General Hospital, Harvard Medical School, Boston, MA, USA, <sup>3</sup>Department of Neurology, Beth Israel Deaconess Medical Center, Harvard Medical School, Boston, MA, USA, <sup>4</sup>Department of Neurology, Brigham and Women's Hospital, Harvard Medical School, Boston, MA, USA, <sup>5</sup>Department of Neurosurgery, University of Michigan, Ann Arbor, MI, USA, <sup>6</sup>Center for Neuro-Oncology, Dana-Farber Cancer Institute, Harvard Medical School, Boston, MA, USA and <sup>7</sup>Division of Infectious Diseases, Brigham and Women's Hospital, Harvard Medical School, Boston, MA, USA

\*Correspondence address. 75 Francis Street, Boston, MA 02115, USA. Tel: +1-617-732-5540; Fax: +1-617-264-6346; E-mail: jkatz@partners.org

Received 4 January 2014; revised 24 January 2014; accepted 29 January 2014

Although herpes simplex encephalitis is not classically considered an opportunistic infection, reactivation of herpes simplex is being seen increasingly in patients with cancer or immunosuppression. The authors present a patient with malignant glioma and HSV-1 encephalitis whose PCR-proven encephalitis recurred after temozolomide (TMZ) chemoradiation despite acyclovir therapy, and summarize details of four other cases of HSV-1 encephalitis associated with TMZ. The similarity among these cases raises the likely need for longer treatment courses and/or oral suppressive therapy in patients at risk for herpes simplex infections who are receiving TMZ.

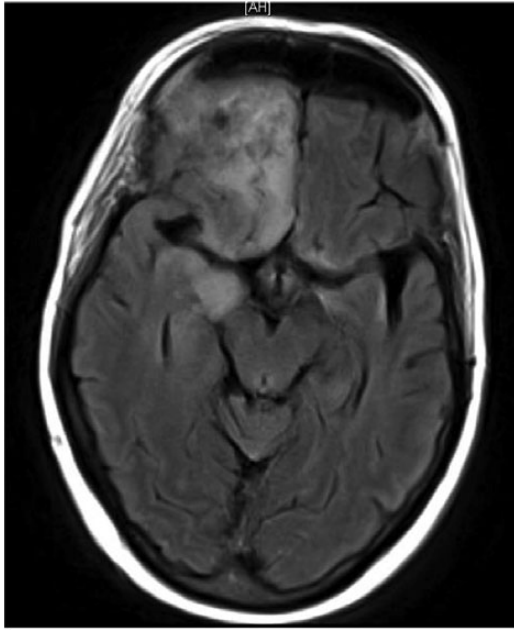
### INTRODUCTION

Temozolomide (TMZ), a DNA alkylating agent with a unique profile of gene regulation [1], in conjunction with radiation, is the standard of care for newly diagnosed patients with glioblastoma. Nausea, fatigue, alopecia and lymphopenia are common adverse reactions during treatment [2]. Case reports have demonstrated an association between TMZ and opportunistic infections such as *Pneumocystis jirovecii* pneumonia [3], hepatitis B virus reactivation [4] and cytomegalovirus [5]. One review [6] showed that ~40% of severe infections associated with TMZ were caused by herpes-class viruses (herpes simplex virus, varicella zoster virus and cytomegalovirus). Herpes simplex encephalitis (HSE) is not classically considered an opportunistic infection due to its similar incidence in immunocompromised and immunocompetent persons. However, reactivation of this virus is being seen increasingly during cancer therapy or immunosuppression [7, 8], including a few instances during TMZ chemoradiation for brain malignancies [7, 9]. We report a case of recurrence of HSE in a

patient with glioblastoma during TMZ chemoradiation and summarize characteristics of four other reported cases of HSE complicating TMZ chemoradiation for brain malignancies.

### CASE REPORT

A 57-year-old woman with a history of scleroderma presented with headaches, inattention and memory impairment and underwent resection of a newly identified right frontal contrast-enhancing lesion, pathologically consistent with grade 4 glioblastoma. One month later, she developed new aphasia and visual hallucinations. MRI showed only postsurgical changes. Lumbar puncture revealed clear fluid with an opening pressure of 10 cm H<sub>2</sub>O, glucose 78 mg/dl, protein 59 mg/dl, 19 WBC (27% neutrophils, 47% lymphocytes, 9% monocytes) and 2 RBC. CSF HSV-1 was positive by quantitative PCR. The patient recovered rapidly on acyclovir 10 mg/kg IV every 8 h, and dexamethasone 4 mg twice daily (weaned to 2 mg twice daily on discharge) and was at baseline without symptoms after



**Figure 1:** MRI axial FLAIR at time of second diagnosis of herpes simplex encephalitis with increased signal intensity in the medial temporal lobes, right greater than left.

the 21-day antiviral course. The patient subsequently initiated chemoradiation therapy with a plan for 6 weeks of TMZ ( $75 \text{ mg/m}^2$ ) and external beam radiation therapy. The dexamethasone was continued at 2 mg twice daily and reduced to 1 mg twice daily after 2 weeks due to concern for steroid myopathy. Twenty-five days after initiation of chemoradiation and  $\sim 6$  weeks after her initial diagnosis of HSE, the patient again developed aphasia and hallucinations. Lumbar puncture at this time revealed clear fluid with glucose 73 mg/dl, protein 68 mg/dl, 4 WBC (46% neutrophils, 37% lymphocytes, 9% monocytes) and 12 RBC. CSF HSV-1 quantitative PCR was again positive. MRI revealed abnormal FLAIR signal and slight restricted diffusion in the medial temporal lobes, right greater than left (Fig. 1), consistent with recurrent HSE. Chemoradiation was held and she received acyclovir 12 mg/kg IV every 8 h, for a total of 21 days. She again improved rapidly, but did not return back to her baseline. Given her recurrence, indefinite suppression with oral acyclovir 400 mg twice daily was initiated. She completed radiation therapy without TMZ and has been HSE-recurrence free to date. Unfortunately, she continued to decline neurologically, developed recurrent aspiration pneumonia, and, 13 weeks after her initial diagnosis of HSE, was transitioned to comfort care.

## DISCUSSION

The current case supports a previously reported association between TMZ and HSE [7, 10], and a single report of TMZ

associated with HSE recurrence [9]. As HSE is considered sporadic, these cases of initial infection and recurrence in the setting of TMZ suggest a clinically important association. Features of the cases are reviewed in Table 1.

We believe that this case represents recurrence of HSE rather than persistent low-level viral encephalitis. A study by Schloss *et al.* [11] showed that 85% of patients with HSV encephalitis converted to negative PCR within 15 days, and 19% of patients had a positive PCR after 20 days; long-term follow-up was not available. Our patient's clinical syndrome initially cleared completely. Her second positive HSV1-PCR was 51 days after the initial positive PCR, and this result coincided with a precipitous clinical deterioration. We therefore conclude that the syndrome was a relapse rather than persistent encephalitis. The low CSF WBC count of 4 is atypical for active encephalitis, but this might be due to the effect of TMZ on peripheral lymphocytes [2].

The association between TMZ and HSV reactivation suggests a specific vulnerability, the mechanism of which is not understood. As toll-like receptor (TLR) 2 signalling mediates activation and tissue injury in HSE; one plausible explanation is that the known TMZ-associated upregulation of a protein downstream from TLRs called IRAK-4 [1] results in enhanced TLR signalling, in turn, promoting viral replication, cell death and tissue injury.

Risk factors for recurrence of HSE are poorly understood, as are those for HSE in general. The total dose and length of acyclovir treatment might be related to the risk of relapse [12]. Dexamethasone inhibits immune-mediated damage in HSE but in doing so might pose an additional risk factor for relapse [13]. Several reports have posited a link between radiation therapy alone and HSE [7, 8]. Analyzing the individual effects of TMZ, radiation and dexamethasone on the risk of HSE will require a comparative study that is beyond the scope of this case report.

HSE is rare, and the benefits of TMZ chemoradiation outweigh the risks in patients with malignant glioma. While conclusions from a case series are subject to bias, the surprising similarity among cases reported here suggests that extreme vigilance and/or prophylactic strategies be considered in patients treated with TMZ who are at risk for herpes simplex infections. HSE complicating TMZ chemoradiation warrants oral suppressive therapy after recovery. Future studies are needed to clarify the role of prophylactic strategies in at-risk individuals facing TMZ treatment and the effectiveness of standard therapeutic guidelines in patients diagnosed with HSE.

## CONFLICT OF INTEREST STATEMENT

None declared.

**Table 1:** Herpes simplex encephalitis complicating TMZ chemoradiation for malignant glioma

Case no.	Age and sex	Cancer	Subsequent chemotherapy/dose steroid	Radiation	MRI* findings	CSF* HSV-1 PCR	CSF* WBC	Therapy*	Outcome
1 [10]	NK	Malignant glioma	s/p 1 dose of TMZ 75 mg/m <sup>2</sup> , unknown dose dexamethasone	Planned 60 Gy in 1.8–2.0 Gy fractions	NK	NK	NK	NK	Death
2 [10]	NK	Malignant glioma	s/p 16 doses of TMZ 75 mg/m <sup>2</sup> , unknown dose dexamethasone	Planned 60 Gy in 1.8–2.0 Gy fractions	NK	NK	NK	NK	Death
3 [7]	15M	Brainstem glioma	s/p TMZ, 4 mg dexamethasone twice a day	180 cGy, five times a week	Increased signal in both temporal lobes	Pos	30	Acyclovir, dose and duration unknown	NK
4 [9]	33M	Malignant glioma diagnosed after initial HSE	Recurrence s/p 34 doses of TMZ 75 mg/m <sup>2</sup> , 2 mg betamethasone daily	44 Gy cumulative dose	(1) Hyperintensity in right medial temporal lobe (2) Extensive oedema, midline shift in left temporal lobe	(1) Not done (2) Neg PCR, but CSF HSV IgG positive	NK	Acyclovir 10 mg/kg × 21 days	Recurrence as described, stable at 1 year follow-up
5	57F	Malignant glioma, followed by initial HSE	Recurrence s/p 25 doses of TMZ 75 mg/m <sup>2</sup> , 2 mg dexamethasone twice daily	s/p 36 Gy cumulative dose	(1) Post-resection changes (2) Increased signal in medial temporal lobes, right greater than left	Pos	1. 19 2. 4	(1) Acyclovir 10 mg/kg every 8 h × 21 days (2) 2. Acyclovir 12 mg/kg every 8 h × 21 days, f/b acyclovir 400 mg PO twice daily indefinitely	Recurrence as described, free from further recurrence on oral suppression with acyclovir

TMZ, temozolomide; HSE, herpes simplex encephalitis; Pos, positive; Neg, negative; NK, not known; PO, orally; IV, intravenously; WBC, white blood cells; f/b, s/p= followed by; \*, 1. and 2. indicate data for initial infection and recurrence, respectively.

## REFERENCES

1. Kumar DM, Patil V, Ramachandran B, Nila MV, Dharmalingam K, Somasundaram K. Temozolomide-modulated glioma proteome: role of interleukin-1 receptor-associated kinase-4 (IRAK4) in chemosensitivity. *Proteomics* 2013;**13**:2113–2124.
2. Schwarzberg AB, Stover EH, Sengupta T, Michelini A, Vincitore M, Baden LR, et al. Selective lymphopenia and opportunistic infections in neuroendocrine tumor patients receiving temozolomide. *Cancer Invest* 2007;**25**:249–55.
3. Yu SK, Chalmers AJ. Patients receiving standard-dose temozolomide therapy are at risk of *Pneumocystis carinii* pneumonia. *Clin Oncol (R Coll Radiol)* 2007;**19**:631–2.
4. Grewal J, Dellinger CA, Yung WK. Fatal reactivation of hepatitis B with temozolomide. *N Engl J Med* 2007;**356**:1591–2.
5. Meije Y, Lizasoain M, Garcia-Reyne A, Martinez P, Rodriguez V, Lopez-Medrano F, et al. Emergence of cytomegalovirus disease in patients receiving temozolomide: report of two cases and literature review. *Clin Infect Dis* 2010;**50**:e73–6.
6. Kizilarlanoglu MC, Aksoy S, Yildirim NO, Ararat E, Sahin I, Altundag K. Temozolomide-related infections: review of the literature. *J BUON* 2011;**16**:547–50.
7. Riel-Romero RM, Baumann RJ. Herpes simplex encephalitis and radiotherapy. *Pediatr Neurol* 2003;**29**:69–71.
8. Graber JJ, Rosenblum MK, DeAngelis LM. Herpes simplex encephalitis in patients with cancer. *J Neurooncol* 2011;**105**:415–21.
9. Okada M, Miyake K, Shinomiya A, Kawai N, Tamiya T. Relapse of herpes encephalitis induced by temozolomide-based chemoradiation in a patient with malignant glioma. *J Neurosurg* 2013;**118**:258–63.
10. Kocher M, Kunze S, Eich HT, Semrau R, Muller RP. Efficacy and toxicity of postoperative temozolomide radiochemotherapy in malignant glioma. *Strahlenther Onkol* 2005;**181**:157–63.
11. Schloss L, Falk KI, Skoog E, Brytting M, Linde A, Aurelius E. Monitoring of herpes simplex virus DNA types 1 and 2 viral load in cerebrospinal fluid by real-time PCR in patients with herpes simplex encephalitis. *J Med Virol* 2009;**81**:1432–7.
12. Valencia I, Miles DK, Melvin J, Khurana D, Kothare S, Hardison H, et al. Relapse of herpes encephalitis after acyclovir therapy: report of two new cases and review of the literature. *Neuropediatrics* 2004;**35**:371–6.
13. Ramos-Estebanez C, Lizarraga KJ, Merenda A. A systematic review on the role of adjunctive corticosteroids in herpes simplex virus encephalitis: is timing critical for safety and efficacy? *Antivir Ther* 2013.