



# Modular neck stems in total hip arthroplasty: current concepts

Giuseppe Solarino<sup>1</sup>  
Giovanni Vicenti<sup>1</sup>  
Massimiliano Carrozzo<sup>1</sup>  
Guglielmo Ottaviani<sup>1</sup>  
Biagio Moretti<sup>1</sup>  
Luigi Zagra<sup>2</sup>

- Modular neck (MN) implants can restore the anatomy, especially in deformed hips such as sequelae of development dysplasia.
- Early designs for MN implants had problems with neck fractures and adverse local tissue, so their use was restricted to limited indications.
- Results of the latest generation of MN prostheses seem to demonstrate that these problems have been at least mitigated.
- Given the results of the studies presented in this review, surgeons might consider MN total hip arthroplasty (THA) for a narrower patient selection when a complex reconstruction is required.
- Long MN THA should be avoided in case of body mass index > 30, and should be used with extreme caution in association with high offset femoral necks with long or extra-long heads. Cr-Co necks should be abandoned, in favour of a titanium alloy connection.
- Restoring the correct anatomic femoral offset remains a challenge in THA surgeries.
- MN implants have been introduced to try to solve this problem. The MN design allows surgeons to choose the appropriate degree and length of the neck for desired stability and range of motion.

**Keywords:** complications; functional outcome; modular neck stem; total hip arthroplasty

Cite this article: *EFORT Open Rev* 2021;6:751-758.

DOI: 10.1302/2058-5241.6.200064

## Introduction

Total hip arthroplasty (THA) is a beneficial surgical procedure that relieves pain, restores hip function, and improves quality of life in most patients with end-stage hip osteoarthritis or other hip diseases.<sup>1</sup> However, the procedure is

not entirely failure-free and new designs are continually developing.<sup>2,3</sup> In the late 20th century, a new design has been introduced: the modular neck (MN) femoral stem. It is intended to give the surgeon the possibility to improve restoration of the joint biomechanics by adjusting the femoral version, the lower limb length, the neck-shaft angle and the femoral offset (FO),<sup>4-7</sup> defined as the distance from the centre of rotation of the femoral head to a line bisecting the longitudinal axis of the femur.<sup>8-10</sup>

The theoretical benefits of FO restoration during total hip arthroplasty should be the reduction of bearing surface wear, implant loosening and dislocation rates.<sup>4</sup> The FO restoration is crucial to improve joint stability, functional outcome and implant longevity.<sup>11,12</sup> Therefore modularity, maximizing the options for a correct anatomic reconstruction, can be particularly useful in 'difficult' hips with advanced anatomical damage as in developmental dysplasia of the hip (DDH) to avoid complementary surgery such as osteotomies, or post-traumatic osteoarthritis, making the surgical treatment of a distorted hip easier, safer and more reproducible, reducing high morbidity and improving outcomes.<sup>13,14</sup>

Despite the benefits of modularity, there are some significant disadvantages related to an increased risk of mechanical failure: dissociation at the neck-stem junction,<sup>13</sup> neck fractures,<sup>15-17</sup> fretting and corrosion at the neck-stem junction have been described.<sup>18,19</sup> Thus, the use of modular stems has been widely questioned and some models were even removed from the global market.<sup>19,20</sup> This review aims to describe the clinical outcomes and complications of MN primary total hip arthroplasty.

## Materials and methods

The present study was conducted following the Preferential Reporting Items for Systematic Reviews and Meta-Analyses (PRISMA) guidelines.<sup>21</sup>

*Eligibility criteria*

Inclusion criteria for studies in this systematic review were as follows: (1) published in English; (2) involved patients who underwent primary total hip arthroplasty surgery with modular prosthesis (3) reported aetiology or survival rate or bone stability or clinical score or complications or blood ion levels. Research was not limited in time; reviews, studies in vitro or biomechanical and cadaver experiments were excluded.

*Information sources and search*

A systematic literature search of potentially eligible trials was conducted through online databases including PubMed-MEDLINE and the Cochrane Central Registry of Controlled Trials. The PubMed search included articles published online ahead of print. The utilized search strings were: (((modular) AND (“prosthesis implantation”[MeSH

Terms]) OR (“prosthesis” AND “implantation”)) AND hip prosthesis[MeSH Terms] AND ((hip prosthesis[MeSH Terms] OR (“hip” AND “prosthesis”)) OR ((modular) AND (“neck” AND “prosthesis implantation”[MeSH Terms])). A manual search of related references and cited articles was also performed.

*Screening and assessment of eligibility*

Three reviewers (GV, MC and GO) independently screened the titles and abstracts of all studies for eligibility. Duplicate articles were manually excluded. All reviewers evaluated the full texts of all potentially eligible studies identified by title and abstract screening to determine final eligibility. All discrepancies were resolved by a consensus decision. The study selection process, carried out in accordance with PRISMA flow chart, is shown in Fig. 1.

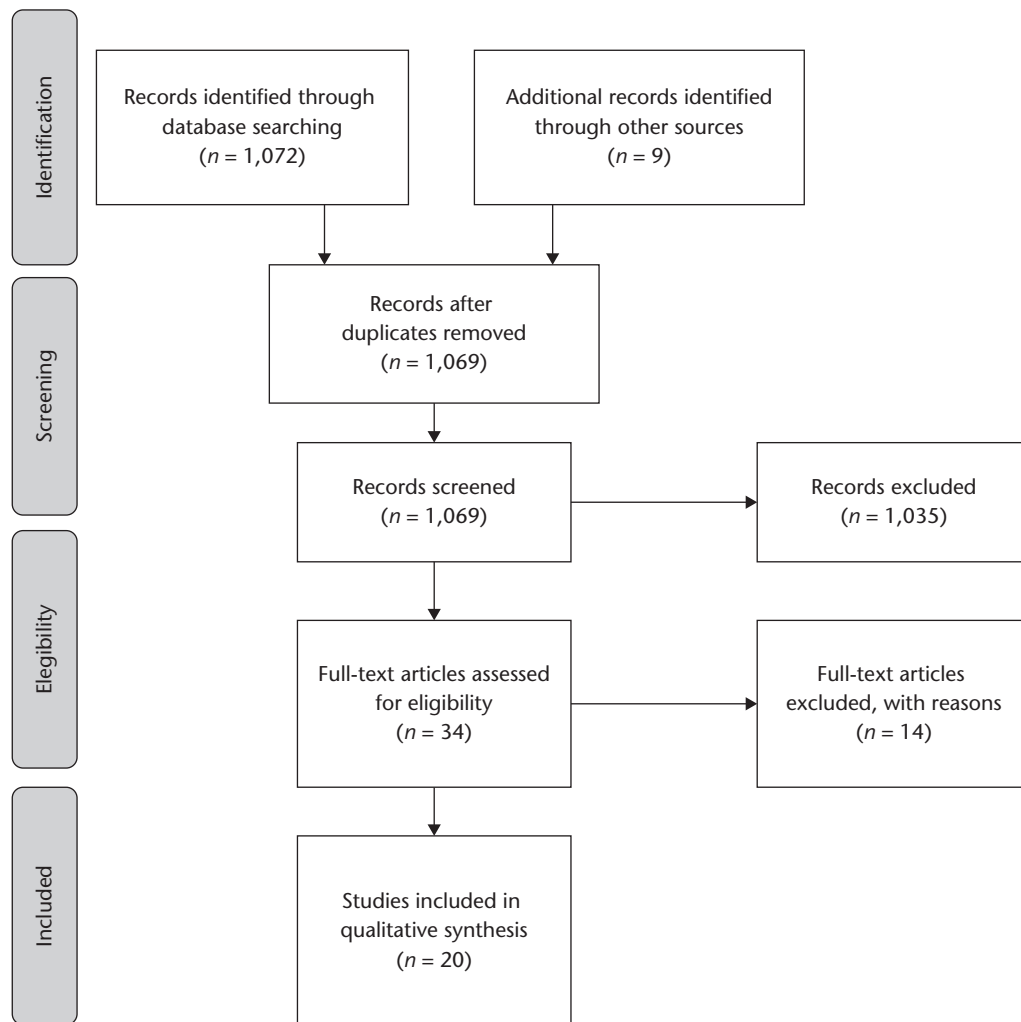


Fig. 1 Study selection process.

### Quality assessment of the studies

The quality of the studies was evaluated according to American Academy of Orthopedic Surgeons (AAOS) clinical practice guideline and systematic review methodology.<sup>22</sup> The following questions were used to evaluate the study quality of diagnostic study designs: (1) Was the patient spectrum representative of the patients who will receive the test in practice? (2) Were the selection criteria clearly described? (3) Was the execution of the index and reference tests described in sufficient detail to permit its replication? (4) Is the reference standard likely to correctly classify the target condition? (5) Are the index test results interpreted by an examiner without the knowledge of the reference tests results?

A study is considered as a high-quality study if it has < 1 flaw, as a moderate-quality study if it has  $\geq 1$  and < 2 flaws, as a low-quality study if it has  $\geq 2$  and < 3 flaws and as a very low-quality study if it has  $\geq 3$  flaws.

## Results

### Search results

The research we performed identified 1072 potentially eligible studies, and 9 additional records were found during manual searches of the reference lists. After removing 12 duplicates another 1035 studies were excluded based on their titles and abstracts. The remaining 34 articles were read in full, and 14 more articles were excluded. In the end 20 studies were included in this systematic review.<sup>23–42</sup> According to the AAOS clinical practice guideline and systematic review methodology, no studies have been rated as low or very low-quality studies.

### Cohort characteristics

All the studies were analysed, and the extracted data are summarized in Table 1. A total of 5645 primary THA in 5518 patients were reported, the average follow-up was 71.37 months. Eighteen studies reported the primary diagnosis: primary osteoarthritis in 2745 (76.2%) cases, DDH in 526 (14.6%) cases, osteonecrosis in 64 (1.7%) cases, post-traumatic arthritis in 26 (0.75%) cases, rheumatoid arthritis in 17 (0.5%) cases and other diagnosis in 224 (6.2%) cases.

### Surgical approach

Seventeen studies reported the surgical approach for a total of 3870 procedures. The most frequently used approach was the posterolateral in 1572 (40%) cases, a posterior approach was used in 895 (23%) cases, an antero-lateral approach in 622 (16%) cases, a direct anterior approach in 506 (13%) cases and a lateral approach in the last 275 (7%) cases.

**Table 1.** Details of included studies

Name	Year	N of patients	N of hips	Average follow-up (months)
Montalti et al <sup>23</sup>	2018	80	80	181.2
Pour et al <sup>24</sup>	2016	244	277	50.0
Blakey et al <sup>33</sup>	2009	288	316	86.4
Loubignac et al <sup>34</sup>	2005	68	76	80.4
Gofton et al <sup>35</sup>	2017	809	809	68.4
Haversath et al <sup>36</sup>	2017	93	93	24.0
Mikkelsen et al <sup>37</sup>	2017	33	33	27.6
Collet et al <sup>38</sup>	2017	72	74	112.8
Vanbiervliet et al <sup>39</sup>	2017	86	95	78.0
Bernstein et al <sup>40</sup>	2016	63	73	50.4
Laurençon et al <sup>41</sup>	2016	40	40	12.0
Nawabi et al <sup>42</sup>	2016	199	199	19.3
Ollivier et al <sup>25</sup>	2015	170	170	71.0
Silverton et al <sup>26</sup>	2014	152	152	54.0
Molloy et al <sup>27</sup>	2014	16	15	42.3
Duwelius et al <sup>28</sup>	2014	459	459	28.8
Cossetto et al <sup>29</sup>	2012	138	162	93.6
Traina et al <sup>30</sup>	2009	2131	2131	108.0
Pelayo-de-Tomás et al <sup>31</sup>	2018	317	317	73.2
Sakai et al <sup>32</sup>	2010	60	74	174.0
Total		5518	5645	71.4

### Survival rate and bone stability

Thirteen studies reported a Kaplan-Meier (KM) analysis of survival rate. Montalti et al<sup>23</sup> with the longest follow-up registered (15 years) presented a survival rate of 90.5%, with only two cases of aseptic loosening out of 80 implants. Also Collet et al<sup>38</sup> with a rate of 94.2%, with any revision or reoperation as endpoint, registered a good survival of the stems used. Cossetto et al<sup>29</sup> reported 10-year KM survival of 96% for the MBA stem; Blakey et al<sup>33</sup> reported five-year KM survival of 97.5% for the ANCA-Fit stem; and Silverton et al<sup>26</sup> reported eight-year KM survival of 89.4% for the uncemented modular Profemur® Z stem. Conversely Bernstein et al<sup>40</sup> in 2016 described an 86% clinical failure rate (63 of the 73 hips) at a mean follow-up of  $4.2 \pm 0.6$  years (range, 3.0 to 5.5 years). The radiographic analysis was reported in 11 studies showing a mean result of 99.56% (97.5–100%). All data extracted are summarized in Table 2.

### Clinical results

Fourteen studies reported clinical outcomes using the Harris Hip Score (HHS) and the Merle d'Aubigne Postel Score (MAPS). The HHS results are summarized in Table 3. We estimated a mean preoperative score of 45.4 and a mean postoperative score of 88.8 points (80. 7–98.6). Collet et al,<sup>38</sup> in their series, registered a mean postoperative HHS of  $93.6 \pm 8.2$  at a mean follow-up of 9.4 years, which was greater than the results reported by several other authors.<sup>26,30,33</sup> The MAPS score summarized in Table 3 improved from an average preoperative score of 10 to a postoperative mean score of 17.5 (15–18).

**Table 2. Survival rate and bone stability**

Name	Year	Survival rate (%)	Bone stability (%)
Montalti et al <sup>23</sup>	2018	90.5	97.5
Pour et al <sup>24</sup>	2016	85.0	NR
Blakley et al <sup>33</sup>	2009	97.5	98.0
Loubignac et al <sup>34</sup>	2005	90.0	NR
Collet et al <sup>38</sup>	2017	94.2	100.0
Vanbiervliet et al <sup>39</sup>	2017	100.0	100.0
Bernstein et al <sup>40</sup>	2016	0.0	NR
Nawabi et al <sup>42</sup>	2016	69.3	NR
Ollivier et al <sup>25</sup>	2015	98.9	100.0
Silverton et al <sup>26</sup>	2014	89.4	NR
Cossetto et al <sup>29</sup>	2012	99.0	100.0
Traina et al <sup>30</sup>	2009	96.8	NR
Pelayo et al-de-Tomás <sup>31</sup>	2018	95.0	99.0

Note. NR, not reported.

*Ion serum levels*

Five studies<sup>24,26,31,41,42</sup> reported cobalt and chromium ion serum levels in ng/ml, that are summarized in Table 4. Only one paper<sup>41</sup> evaluated systemic metal ion levels in a homogenous series of patients after implantation of a mixed-alloy modular neck hip prosthesis (Symbios SPS, Ti stems coupled to Co-Cr necks) compared to those of two control groups: a group of patients having received the non-modular neck version of the same stem (Ti6Al4V) and a group of patients without any metal implant.

The higher cobalt ion serum level was registered by Nawabi et al<sup>42</sup> where serum metal ion levels were obtained in 144 of the 195 patients. The mean serum cobalt was 6.1 ng/mL (range, 0.5 to 7.7 ng/mL), and the mean serum chromium was 1.3 ng/mL (range, 0.2 to 5.3 ng/mL) higher than the normal (serum cobalt < 1 ng/mL, serum chromium < 5 ng/mL). Patients who had undergone revision had significantly higher serum cobalt ion levels (mean, 8.6 ng/mL).

Also Pour et al,<sup>24</sup> in their series, described greater serum levels of Cr and Ti considering all hips requiring aseptic revision surgery for any reason (*n* = 43 of 277).

*Complications*

Thirteen studies reported complications for a total of 202 episodes in 3106 THA: adverse local tissue reaction (ALTR) in 85 (38%) cases, aseptic loosening of the stem or acetabular component in 28 (13.86%) cases, acute or chronic dislocations in 31 (15.35%) cases, periprosthetic fractures in 21 (1.4%) cases, deep infections in 10 (4.95%) cases, three studies reported neck fracture in 12 (5.94%) cases, pain and impingement respectively in two (0.99%) and two (0.99%) cases, ceramic head fractures in one (0.5%) case and one (0.5%) case of varus positioning of the stem. Other complications were reported in four (1.98%) cases. All complications have been summarized in Table 5.

**Table 3. Harris Hip Score (HHS) and Merle d’Aubigne score**

Name	Year	Preoperative Harris Hip Score	Postoperative Harris Hip Score	Preoperative Merle d’Aubigne score	Postoperative Merle d’Aubigne score
Montalti et al <sup>23</sup>	2018	35.7	82.8	9.3	15.1
Loubignac et al <sup>34</sup>	2005	NR	91.3	16.4	18.0
Haversath et al <sup>36</sup>	2017	50.9	93.8	–	–
Collet et al <sup>38</sup>	2017	NR	93.6	–	–
Vanbiervliet et al <sup>39</sup>	2017	31.0	90.0	–	–
Nawabi et al <sup>42</sup>	2016	50.7	81.8	–	–
Ollivier et al <sup>25</sup>	2015	50.4	84.5	–	–
Molloy et al <sup>27</sup>	2014	NR	80.7	–	–
Duwelius et al <sup>28</sup>	2014	52.0	91.0	–	–
Sakai et al <sup>32</sup>	2010	44.6	98.6	–	–
Cossetto et al <sup>29</sup>	2012	–	–	7.1	16.4
<i>Average</i>		45	88.8	10.0	17.5

**Table 4. CoCr ion serum levels**

Name	Year	N of patients	CoCr ion levels (ng/ml)	Material of the heads	Material of the necks
Pour et al <sup>24</sup>	2016	244	Co 5.5 Cr 3.16	62 ceramic 182 Co-Cr alloy	Co-Cr
Laurençon et al <sup>41</sup>	2016	40	Co 1.28±2.32 Cr 1.12±0.52	Ceramic	Co-Cr-molybdenum alloy
Nawabi et al <sup>42</sup>	2016	199	Co 6.1 Cr 1.3	Co-Cr alloy	Co-Cr alloy
Silverton et al <sup>26</sup>	2014	152	Co 2.4 Cr 1.7	30 ceramic 122 Co-Cr	Titanium alloy
Pelayo-de-Tomás et al <sup>31</sup>	2018	317	Co < 2.2 Cr < 2.2	297 ceramic 20 metal	79 titanium 238 Cr-Co

**Table 5. Complications**

Name	Year	N of hips	Complications
Montalti et al <sup>23</sup>	2018	80	Aseptic loosening 2 (2.5%) Dislocations 2 (2.5%) Periprosthetic fracture 1 (1.25%)
Pour et al <sup>24</sup>	2016	277	Aseptic loosening 15 (5%) Neck fractures 7 (2.5%) Periprosthetic fractures 4 (1.5%) ALTR 4 (1.5%)
Blakley et al <sup>33</sup>	2009	316	Dislocations 5 (1.5%) Aseptic loosening 4 (1.2%)
Loubignac et al <sup>34</sup>	2005	76	Dislocations 3 (4%) Periprosthetic fractures 1 (1.3%) Aseptic loosening 1 (1.3%) Other 3 (4%)
Gofton et al <sup>35</sup>	2017	809	Dislocations 9 (1.1%) Neck fractures 4 (0.05%)
Nawabi et al <sup>42</sup>	2016	199	ALTR 73 (36%) Periprosthetic fractures 5 (2.5%) Pain 2 (1%)
Ollivier et al <sup>25</sup>	2015	170	Deep infections 3 (1.7%) Periprosthetic fractures 2 (1.1%) Impingement 2 (1.1%)
Silverton et al <sup>26</sup>	2014	152	2 taper corrosion 1 cup malposition 1 ALTR 1 neck fracture (0.66%)
Molloy et al <sup>27</sup>	2014	15	ATLR 7 (46.6%)
Duwelius et al <sup>28</sup>	2014	459	Dislocations 2 (0.4%) Deep infections 2 (0.4%) Intraoperative fracture 1 (0.2%) Other 1 (0.2%)
Cossetto et al <sup>29</sup>	2012	162	Periprosthetic fractures 5 (3%) Dislocations 3 (1.8%) Deep infections 2 (1.2%) Aseptic loosening 2 (1.2%)
Pelayo-de-Tomás et al <sup>31</sup>	2018	317	Dislocations 7 (2.2%) Periprosthetic fractures 3 (0.9%) Deep infections 3 (0.9%) Intraoperative fracture 1 (0.3%)
Sakai et al <sup>32</sup>	2010	74	Aseptic loosening 6 (8%)

Note. ALTR, adverse local tissue reaction.

## Discussion

THA with MN stem appears to be a useful procedure for the treatment of hip osteoarthritis or other hip diseases.<sup>1</sup> There are remarkable improvements in functional outcomes in the form of HHS, MEPS and range of motion in the papers reviewed. MN stems can play a major role in case of anatomical abnormalities of the proximal femur.<sup>43</sup> The average improvement in HHS was 43.76 points (range 28–59 points). Nawabi et al<sup>42</sup> reported the lowest postoperative average improvement in HHS (31.1 points).

In our review, the crude overall complication rate (202 in 3106 cases) was 6.5%. This percentage was slightly higher than that reported in literature with the use of a monobloc femoral stem.<sup>44</sup> As described in the literature, comparable complication rates of deep infections 0.32% (10 in 3106 cases), periprosthetic fracture 0.68% (21 of 3106 cases) were registered by the studies of this review.

In the Australian Orthopaedic Association National Joint Replacement Registry of 2020, 10,235 primary procedures were recorded using femoral stems with

modular necks. The cumulative percent revision at 15 years was 12.5% for modular stems; double compared to 7.7% for fixed neck stems.<sup>45</sup> ALTR was the most frequent complication reported (85 cases, 2.73%). The majority of these cases (73 of 85) were recorded by Nawabi et al,<sup>42</sup> who conclude that the corrosion at the neck–stem junction in total hip arthroplasty could be a cause of ALTR. The authors confirm that their findings may apply to a particular specific modular design and suggest that surveillance utilizing metal ion levels and MRI (magnetic resonance imaging) may be indicated for follow-up patients with modular neck hip prostheses.

It is described that Cr-Co neck corrosion determines the release of metal ions that results in ALTR. This has resulted in the voluntary recall of many MN total hip arthroplasty designs. Only five of the 23 papers included in this review reported the serum metal ion levels data (Table 4)<sup>24,33,34,36,41</sup> with levels higher than the normal (serum cobalt < 1 ng/mL, serum chromium < 5 ng/mL).

In the Australian Orthopaedic Association National Joint Replacement Registry of 2020, femoral stem with modular necks still have almost twice the rate of revision compared to fixed neck stems. The titanium/cobalt chromium combination has an extremely high rate of revision compared to the titanium/titanium combination. At 15 years, the cumulative incidence of metal-related pathology was 3.9% for titanium/cobalt chromium compared to 0.1% for titanium/titanium.<sup>45</sup>

The overall dislocation rate recorded as 0.93% (29 of 3106 cases) is slightly lower in comparison to that described in the literature (2–4%).<sup>46–48</sup> Only one article, by Gofton et al,<sup>35</sup> correlated the surgical approach to the dislocation rate. In their study there was a significant difference between dislocation rates based on approach ( $p < 0.05$ ). There were no dislocations with a lateral approach, one dislocation with the anterior approach and eight with the posterior approach (2.33%, 8/343).

As described by different authors<sup>5,10,38</sup> the modularity was effective in restoring offset and leg length, and these confer stability with a good mid to long-term follow-up. Traina et al<sup>49</sup> reported that MN prostheses allow the restoration of femoral offset, abductors moment arm, leg length and joint kinematics especially in critical cases of THA, such as high-grade dysplasia. Restoring the proper offset appears to determinate an appropriate tension of the abductor muscles, which implies a better functional outcome and a better primary stability of the implant with less early migration.<sup>10</sup> These results are in contrast with those reported by Carothers et al, who found significant differences of more than 4 mm in neck length and more than 2 mm in offset in only 15% of cases in their study.<sup>48</sup>

These conclusions suggest that use of modular heads results in head centre positions also achievable with non-modular stems with a correct preoperative planning in

most cases.<sup>50</sup> Also, different studies did not demonstrate an effective impact of modularity on dislocation. In a retrospective series of 809 THAs using the Profemur TM stem (Wright®) with modular neck, Gofton et al<sup>35</sup> reported 2.3% dislocation on a posterior approach, compared to 0.3% on anterior and 0% on lateral approaches, whereas modularity was most often used in posterior approaches. Comparing two consecutive series of a single surgeon, with 284 standard and 594 modular neck THAs, Duwelius et al<sup>5</sup> found no difference in Harris or SF12 scores at a mean 2.4 years follow-up.

Fracture of the femoral component is a rare complication in total hip arthroplasty. In our review we registered 12 cases of neck fracture with a rate of 0.38%.<sup>26,28,37</sup> Traina et al<sup>49</sup> confirm that the failure of modular necks is related to neck offset, stem size (the larger the stem, the higher the risk) and body weight. The authors suggest that in the presence of a high BMI, young male patient, a caput-collum-diaphyseal (CCD) angle < 135°, and a high functional demand the risk of failure is significantly increased, and the use of modular prostheses must be evaluated case by case. Konan et al,<sup>51</sup> in their review, also confirm that the incidence of this complication is low, but the risk increases in patients with a high BMI, a high level of activity, a small medullary canal (hence small stem diameters) and those with severe bone loss and poor proximal bony support for the stem, especially medially.

In a systematic review of the literature and of English-language registries, Mihalko et al showed that stems with modular necks had significantly poorer 10-year survival than monobloc stems with cumulative revision rates between 4% and 9%,<sup>50</sup> particularly when modular neck stems were paired with metal-on-metal articulating bearing, which was reported to increase revision rates even further.<sup>45</sup> The authors conclude that it remains to be established whether this is the result of implant taper mismatch in the assembly of the added taper junction, implant material or design, or surgical technical errors.

A 2020 scoping review by Mertl et al<sup>52</sup> concludes that modular neck stems have to imperatively be reserved for difficult cases of dysplasia or severely deformed femur, due to the risk of fracture. They are to be avoided in case of obese patients (BMI > 30), Cr-Co necks should be abandoned, in favour of a Ti6Al4V connection. Cr-Co/Ti connections are associated with serious corrosion, leading to severe adverse local tissue reaction.

## Conclusion

Despite the concerns among most of surgeons in several countries, the results of our review suggest that MN

stem prosthesis in primary THA is a useful treatment for hip osteoarthritis in case of DDH or severely deformed femur. The majority of the published studies report clinical outcomes after THA with MN prosthesis comparable to those reported with the use of monobloc stems. The modularity of the necks in narrower selected cases allows the restoration of femoral offset, abductors moment arm and leg length that could result in better functioning of the joint and better primary stability of the implant. This should result in good mid to long-term follow-up outcomes. The new generations of implant and the use of the Ti6Al4V neck reduce the risk of wear and adverse local tissue reaction that remains the most common complication registered in the analysed studies.

It is a fact that the risk of wear and neck-taper fractures is higher in obese male patients with a BMI > 30 and high functional demand, and the use of modular stems in these patients is to be avoided. The use of long and extra-long necks must be carefully evaluated as well. Future high-quality prospective studies with longer follow-up are necessary to confirm the supposed advantages of the use of MN stem in difficult primary THA procedures and to highlight all disadvantages with respect to NMN THA.

### AUTHOR INFORMATION

<sup>1</sup>Department of Neuroscience and Organs of Sense, Orthopaedics Section, Faculty of Medicine and Surgery, University of Bari, Bari, Italy.

<sup>2</sup>IRCCS Istituto Ortopedico Galeazzi, Hip Department, Milan, Italy.

Correspondence should be sent to: M. Carrozzo, Policlinico, Piazza Giulio Cesare 11, 70124 Bari, Italy.

Email: doc.mcarrozzo@gmail.com

### ICMJE CONFLICT OF INTEREST STATEMENT

LZ reports consultancy fees paid by Medacta for product development; fees paid for lectures by Zimmer Biomet, Stryker, LimaCorporate and Smith & Nephew, and research fees paid to his institution by LimaCorporate, DePuy and Medacta – all for relevant financial activities outside the submitted work. All other authors declare no conflicts of interest relevant to this work.

### FUNDING STATEMENT

No benefits in any form have been received or will be received from a commercial party related directly or indirectly to the subject of this article.

### OPEN ACCESS

© 2021 The author(s)

This article is distributed under the terms of the Creative Commons Attribution-Non Commercial 4.0 International (CC BY-NC 4.0) licence (<https://creativecommons.org/licenses/by-nc/4.0/>) which permits non-commercial use, reproduction and distribution of the work without further permission provided the original work is attributed.

## REFERENCES

1. **Learmonth ID, Young C, Rorabeck C.** The operation of the century: total hip replacement. *Lancet* 2007;370:1508–1519.
2. **Bozic KJ, Kurtz SM, Lau E, Ong K, Vail TP, Berry DJ.** The epidemiology of revision total hip arthroplasty in the United States. *J Bone Joint Surg [Am]* 2009;91-A:128–133.
3. **Sanchez-Sotelo J, Berry DJ.** Epidemiology of instability after total hip replacement. *Orthop Clin North Am* 2001;32:543–552, vii.
4. **Traina F, De Fine M, Biondi F, Tassinari E, Galvani A, Toni A.** The influence of the centre of rotation on implant survival using a modular stem hip prosthesis. *Int Orthop* 2009;33:1513–1518.
5. **Duwelius PJ, Hartzband MA, Burkhart R, et al.** Clinical results of a modular neck hip system: hitting the 'bull's-eye' more accurately. *Am J Orthop* 2010;39:2–6.
6. **Asayama I, Chamnongkitch S, Simpson KJ, Kinsey TL, Mahoney OM.** Reconstructed hip joint position and abductor muscle strength after total hip arthroplasty. *J Arthroplasty* 2005;20:414–420.
7. **McGrory BJ, Morrey BF, Cahalan TD, An KN, Cabanela ME.** Effect of femoral offset on range of motion and abductor muscle strength after total hip arthroplasty. *J Bone Joint Surg [Br]* 1995;77-B:865–869.
8. **Lecerf G, Fessy MH, Philippot R, et al.** Femoral offset: anatomical concept, definition, assessment, implications for preoperative templating and hip arthroplasty. *Orthop Traumatol Surg Res* 2009;95:210–219.
9. **Charles MN, Bourne RB, Davey JR, Greenwald AS, Morrey BF, Rorabeck CH.** Soft-tissue balancing of the hip: the role of femoral offset restoration. *Instr Course Lect* 2005;54:131–141.
10. **Vicenti G, Solarino G, Spinarelli A, et al.** Restoring the femoral offset prevent early migration of the stem in total hip arthroplasty: an EBRA-FCA study. *J Biol Regul Homeost Agents* 2016;30:S207–S212.
11. **Husby VS, Bjørgen S, Hoff J, Helgerud J, Benum P, Husby OS.** Unilateral vs. bilateral total hip arthroplasty: the influence of medial femoral head offset and effects on strength and aerobic endurance capacity. *Hip Int* 2010;20:204–214.
12. **Chamnongkitch S, Asayama I, Kinsey TL, Mahoney OM, Simpson KJ.** Difference in hip prosthesis femoral offset affects hip abductor strength and gait characteristics during obstacle crossing. *Orthop Clin North Am* 2012;43:e48–e58.
13. **Kouzellis A, Georgiou CS, Megas P.** Dissociation of modular total hip arthroplasty at the neck-stem interface without dislocation. *J Orthop Traumatol* 2012;13:221–224.
14. **Mencièrè M-L, Amouyel T, Taviaux J, Bayle M, Laterza C, Mertl P.** Fracture of the cobalt-chromium modular femoral neck component in total hip arthroplasty. *Orthop Traumatol Surg Res* 2014;100:565–568.
15. **Sotereanos NG, Sauber TJ, Tupis TT.** Modular femoral neck fracture after primary total hip arthroplasty. *J Arthroplasty* 2013;28:196.e7–196.e9.
16. **Kop AM, Swarts E.** Corrosion of a hip stem with a modular neck taper junction: a retrieval study of 16 cases. *J Arthroplasty* 2009;24:1019–1023.
17. **Ellman MB, Levine BR.** Fracture of the modular femoral neck component in total hip arthroplasty. *J Arthroplasty* 2013;28:196.e1–196.e5.
18. **Gilbert JL, Buckley CA, Jacobs JJ.** In vivo corrosion of modular hip prosthesis components in mixed and similar metal combinations: the effect of crevice, stress, motion, and alloy coupling. *J Biomed Mater Res* 1993;27:1533–1544.
19. **Walsh CP, Hubbard JC, Nessler JP, Markel DC.** Revision of recalled modular neck rejuvenate and ABG femoral implants. *J Arthroplasty* 2015;30:822–826.
20. **Meftah M, Haleem AM, Burn MB, Smith KM, Incavo SJ.** Early corrosion-related failure of the rejuvenate modular total hip replacement. *J Bone Joint Surg [Am]* 2014;96-A:481–487.
21. **Moher D, Liberati A, Tetzlaff J, Altman DG; PRISMA Group.** Preferred reporting items for systematic reviews and meta-analyses: the PRISMA statement. *PLoS Med* 2009;6:e1000097.
22. **Surgeons AAOS clinical practice guideline and systematic review methodology.** OrthoGuidelines. [https://www.aaos.org/uploadedFiles/PreProduction/Quality/Guidelines\\_and\\_Reviews/guidelines/GuidelineandSystematicReviewProcesses\\_v2.0\\_Final.pdf](https://www.aaos.org/uploadedFiles/PreProduction/Quality/Guidelines_and_Reviews/guidelines/GuidelineandSystematicReviewProcesses_v2.0_Final.pdf) (date last accessed 22 September 2019).
23. **Montalti M, Castagnini F, Giardina F, Tassinari E, Biondi F, Toni A.** Cementless total hip arthroplasty in Crowe III and IV dysplasia: high hip center and modular necks. *J Arthroplasty* 2018;33:1813–1819.
24. **Pour AE, Borden R, Murayama T, Groll-Brown M, Blaha JD.** High risk of failure with bimodular femoral components in THA. *Clin Orthop Relat Res* 2016;474:146–153.
25. **Ollivier M, Parratte S, Galland A, Lunebourg A, Flecher X, Argenson J-N.** Titanium-titanium modular neck for primary THA: result of a prospective series of 170 cemented THA with a minimum follow-up of 5 years. *Orthop Traumatol Surg Res* 2015;101:137–142.
26. **Silverton CD, Jacobs JJ, Devitt JW, Cooper HJ.** Midterm results of a femoral stem with a modular neck design: clinical outcomes and metal ion analysis. *J Arthroplasty* 2014;29:1768–1773.
27. **Molloy DO, Munir S, Jack CM, Cross MB, Walter WL, Walter WK Sr.** Fretting and corrosion in modular-neck total hip arthroplasty femoral stems. *J Bone Joint Surg [Am]* 2014;96-A:488–493.
28. **Duwelius PJ, Burkhart B, Carnahan C, et al.** Modular versus nonmodular neck femoral implants in primary total hip arthroplasty: which is better? *Clin Orthop Relat Res* 2014;472:1240–1245.
29. **Cossetto DJ, Goudar A.** Mid-term outcome of a modular, cementless, proximally hydroxyapatite-coated, anatomic femoral stem. *J Orthop Surg (Hong Kong)* 2012;20:322–326.
30. **Traina F, De Clerico M, Biondi F, Pilla F, Tassinari E, Toni A.** Sex differences in hip morphology: is stem modularity effective for total hip replacement? *J Bone Joint Surg [Am]* 2009;91-A:121–128.
31. **Pelayo-de-Tomás JM, Rodrigo-Pérez JL, Novoa-Parra CD, Lizaur-Utrilla A, Morales-Suárez-Varela M, Blas-Dobón JA.** Cementless modular neck stems: are they a safe option in primary total hip arthroplasty? *Eur J Orthop Surg Traumatol* 2018;28:463–469.
32. **Sakai T, Ohzono K, Nishii T, Miki H, Takao M, Sugano N.** A modular femoral neck and head system works well in cementless total hip replacement for patients with developmental dysplasia of the hip. *J Bone Joint Surg [Br]* 2010;92-B:770–776.
33. **Blakey CM, Eswaramoorthy VK, Hamilton LC, Biant LC, Field RE.** Mid-term results of the modular ANCA-Fit femoral component in total hip replacement. *J Bone Joint Surg [Br]* 2009;91-B:1561–1565.
34. **Loubignac F, Rebouillat J.** Advantages of the bimodular neck for THR: results of the first 100 Hélianthe femoral stems to at least 5-year follow-up. *Eur J Orthop Surg Traumatol* 2005;15:90–100.

- 35. Gofton WT, Illical EM, Feibel RJ, Kim PR, Beaulé PE.** A single-center experience with a titanium modular neck total hip arthroplasty. *J Arthroplasty* 2017;32:2450–2456.
- 36. Haversath M, Wendelborn C, Jäger M, Schmidt B, Kowalczyk W, Landgraeber S.** Geometric analysis and clinical outcome of two cemented stems for primary total hip replacement with and without modular necks. *Arch Orthop Trauma Surg* 2017;137:1571–1578.
- 37. Mikkelsen RT, Fløjstrup M, Klem N, et al.** Modular neck vs nonmodular femoral stems in total hip arthroplasty: clinical outcome, metal ion levels, and radiologic findings. *J Arthroplasty* 2017;32:2774–2778.
- 38. Collet T, Atanasiu J-P, de Cussac J-B, et al.** Midterm outcomes of titanium modular femoral necks in total hip arthroplasty. *Ann Transl Med* 2017;5:395.
- 39. Vanbiervliet J, Somers JFA.** Excellent mid-term results of a new polished tapered modular cemented stem: a study of 113 hip replacements with minimum 5-year follow-up. *Hip Int* 2017;27:455–459.
- 40. Bernstein DT, Meftah M, Paraniham J, Incavo SJ.** Eighty-six percent failure rate of a modular-neck femoral stem design at 3 to 5 years: lessons learned. *J Bone Joint Surg [Am]* 2016;98-A:e49.
- 41. Laurençon J, Augsburg M, Faouzi M, Becce F, Hassani H, Rüdiger HA.** Systemic metal ion levels in patients with modular-neck stems: a prospective cohort study. *J Arthroplasty* 2016;31:1750–1755.
- 42. Nawabi DH, Do HT, Ruel A, et al.** Comprehensive analysis of a recalled modular total hip system and recommendations for management. *J Bone Joint Surg [Am]* 2016;98-A:40–47.
- 43. Zagra L.** Advances in hip arthroplasty surgery: what is justified? *EFORT Open Rev* 2017;2:171–178.
- 44. Loppini M, Grappiolo G.** Uncemented short stems in primary total hip arthroplasty: the state of the art. *EFORT Open Rev* 2018;3:149–159.
- 45. Australian Orthopaedic Association National Joint Replacement Registry.** *Annual report 2019*. Adelaide, 2020. <https://aoanjrr.sahmri.com/annual-reports-2019> (Date last accessed 28 August 2021).
- 46. Lübbecke A, Suvà D, Perneger T, Hoffmeyer P.** Influence of preoperative patient education on the risk of dislocation after primary total hip arthroplasty. *Arthritis Rheum* 2009;61:552–558.
- 47. Meek RMD, Allan DB, McPhillips G, Kerr L, Howie CR.** Late dislocation after total hip arthroplasty. *Clin Med Res* 2008;6:17–23.
- 48. Carothers JT, Archibeck MJ, Tripuraneni KR.** Modular versus nonmodular femoral necks for primary total hip arthroplasty. *Am J Orthop* 2015;44:411–414.
- 49. Traina F, De Fine M, Tassinari E, Sudanese A, Calderoni PP, Toni A.** Modular neck prostheses in DDH patients: 11-year results. *J Orthop Sci* 2011;16:14–20.
- 50. Mihalko WM, Wimmer MA, Pacione CA, Laurent MP, Murphy RF, Rider C.** How have alternative bearings and modularity affected revision rates in total hip arthroplasty? *Clin Orthop Relat Res* 2014;472:3747–3758.
- 51. Konan S, Garbuz DS, Masri BA, Duncan CP.** Modular tapered titanium stems in revision arthroplasty of the hip: the risk and causes of stem fracture. *J Bone Joint Surg [Br]* 2016;98-B:S50–S53.
- 52. Mertl P, Dehl M.** Femoral stem modularity. *Orthop Traumatol Surg Res* 2020;106:S35–S42.