

Influence of the bone block position on the tunnel enlargement in ACL reconstruction

Dominik J. Hoigne,¹ Peter M. Ballmer²

¹Chirurgische Klinik, Luzerner Kantonsspital, Switzerland; ²Orthopedic Clinic, Spital Thun-Simmental AG, Switzerland

Abstract

Tunnel enlargement can appear after anterior cruciate ligament reconstruction. We investigated the influence of the bone block position of a patellar tendon autograft on the tunnel enlargement in the femur and in the tibia from two aspects. On the one hand, we examined the influence of the tunnel position in respect to the ap-diameter. On the other hand, we examined the influence of the bone block depth in respect to the joint line. In a crossover study over three years, 103 knees with primary ACL reconstruction were included. The incidence of tunnel enlargement measured on X-rays after one year was 52% (n=103) in the femur and 81% (n=103) in the tibia. The average diameter of enlargement was 1.4 mm (14%) in the femur and 2.7 mm (27%) in the tibia. No correlation between the tunnel position and the tunnel enlargement in the sagittal plane could be found. However, there is a significant positive correlation between the size of tunnel enlargement and the bone block depth in the femur and in the tibia. There is an average tunnel enlargement of about 0.6 mm (6%) per 10 mm deeper bone plug depth. The relative excess length of the patella tendon favors the development of tunnel enlargement. The effect of the bone block depth on the tunnel enlargement is equal in the femur and the tibia.

Introduction

The optimal position for the anterior cruciate ligament replacement has been thoroughly investigated.¹⁻¹³ Even if the thus acquired knowledge is taken into consideration, bone tunnel enlargement in the femur and tibia can occur after anterior cruciate ligament replacement. Up to now, the quality of the grafts¹⁴⁻¹⁷ as well as the biomechanical effects^{15,18,23} and the biochemical path mechanisms²³⁻²⁵ are investigated in respect of the phenomenon of tunnel enlargement. Nevertheless, the phenomenon cannot be fully explained. There is not much information about the impact of the tunnel

position on the tunnel enlargement. The few conducted studies only describe the effect at the tibia.^{20,21} The depths of the bone block may also influence the tunnel enlargement. The excess length will lead to a windshield wiper effect and a direct contact of the bone with the tendon and the synovial fluid. These factors may explain part of the etiology of the tunnel enlargement, but the correlation between bone block depth and tunnel enlargement has only been investigated in respect of the tibia.^{20,26,27}

The goal of this study was to investigate the relationship of the tunnel position and the bone block depth and the development of tunnel enlargement after anterior cruciate replacement with bone-tendon-bone autograft.

Materials and Methods

Patient selection

During the study period of three years 123 anterior cruciate ligament (ACL) replacements with PTP autograft were performed in 120 patients by a single surgeon.

Inclusion criteria were all performed ACL-reconstructions in the study period of three years. Exclusion criteria were previous operations at the same knee, insufficient observation periods and a new trauma during the study period. Twenty patients were excluded due to at least one of these criteria. All of the operations were performed arthroscopically with the same method. Ultimately 103 cases (49 men, 54 women) were qualified to be retrospectively analyzed. The mean age of the patients at the time of surgery was 31 years (range 14-65). The mean follow-up period was 12.5 months (range 11-14).

Surgical procedure

A 10 mm autograft was excised from the middle third of the patellar tendon ligament together with a femoral and tibial bone block with a length of 15 mm and a width of 10 mm. Each bone block was armed through two boreholes of 2 mm non-absorbable (Nr 3 Ethibond, Ethicon, Inc.) sutures. The arthroscopy was performed through an anterolateral and an anteromedial portal. The torn ACL was removed. A 2.5 mm K-wire (Zimmer, Inc.) was placed through a short lateral supracondylar incision from outside to inside with a U-shaped femoral drill guide to the femoral insertion of the ACL. The tip was drilled exactly to the level of the cortical surface in the intercondylar notch. A second 2.5 mm K-wire was placed transtibially from outside to inside by a tibial drill guide to the origin of the tibial insertion of the ACL. Through a lateral C-arm shot the position of the K-wires in flexion and extension were observed and, when necessary,

Correspondence: Dominik J. Hoigne, Aarepark 2a, 5000 Aarau, Switzerland. E-mail: dominik.hoigne@bluewin.ch

Key words: tunnel enlargement, graft positioning, anterior cruciate ligament reconstruction, bone-tendon-bone autograft.

Received for publication: 9 September 2009.

Revision received: 24 February 2010.

Accepted for publication: 25 February 2010.

This work is licensed under a Creative Commons Attribution 3.0 License (by-nc 3.0).

©Copyright D.J. Hoigne and P.M. Ballmer, 2010
Licensee PAGEPress, Italy
Orthopedic Reviews 2010; 2:e12
doi:10.4081/or.2010.e12

corrected. The femoral and tibial tunnels are formed over the K-wires with a 10 mm cannulated drill and the edges smoothed with a milling cutter. The graft was placed from proximal to distal in the tunnels. The femoral bone block was armed with two transosseous non-absorbable sutures (Nr 3 Ethibond, Ethicon Inc.) on a 3.5 mm cortical screw (Zimmer, Inc.) with washer. The isometric placement was controlled within a range of motion of 5-0-120°. The tibial bone block was anchored under tension in the same manner as the femoral block in 20-30° flexion of the knee (Figure 1).

Post-operative treatment

Mobilization started on the first post-operative day with crutches and weight-bearing as tolerated by the patient. Hyperextension and activity of the quadriceps against resistance was avoided for six weeks. Physiotherapy was conducted for approximately twelve weeks. Complete resumption of sporting activity was allowed after six months.

Evaluation method

Determination of the tunnel position x in the sagittal plane was made through the use of the intraoperative print of the C-arm shot in the lateral projection, while the K-wires were placed on the joint surfaces and just before over drilling. The K-wires designated the center of the future femoral and tibial drill canal. The femoral tunnel exit was described using the Quadrant-Method.^{1,28} With this method, the relative anterior-posterior distance on the lateral condylar diameter where the femoral K-wire crosses the Blumensaat's line is expressed as x_f . The tibial entry point x_t was described as the relative anterior-posterior distance on the tibial plateau diameter determined through the point where the K-wire crosses the tibial joint surface³ (Figure 1). The

bone block depth y was determined through the post-operative X-rays in the lateral projection. The femoral bone block depth y_f was measured vertically to the Blumensaat's line. The tibial bone block depth y_t was measured vertically to the lateral tibial plateau (Figure 2). The femoral and tibial tunnel enlargements were measured through the X-rays in the lateral projection one year post-operatively (11-14 months). The shortest distance between the sclerotic zones surrounding the tunnel by the reference lines and perpendicular to the axis of the tunnel is defined as the current tunnel diameter d (Figure 3). The cases in which the

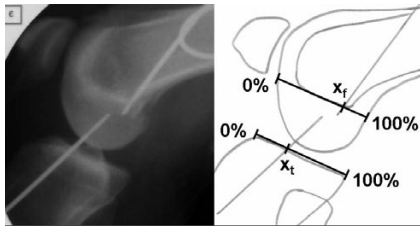


Figure 1. Assessment of the anterior-posterior position of the drill hole centre marked by k-wires on intraoperative C-arm shots. x_f expresses the femoral tunnel entry point as the relative anterior-posterior distance on the lateral condylar diameter where the femoral k-wire crosses the Blumensaat's line. x_t expresses the tibial tunnel entry point as the relative anterior-posterior distance on the tibial plateau diameter determined through the point where the k-wire crosses the tibial joint surface.

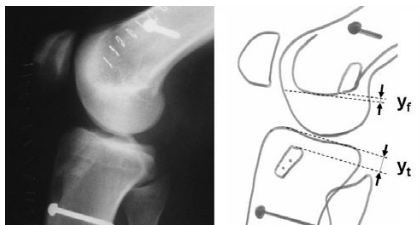


Figure 2. Assessment of the bone block depth y seen as the perpendicular distance between the bone block and the Blumensaat's line as y_f and the subchondral sclerosis zone of the tibial plateau as y_t .

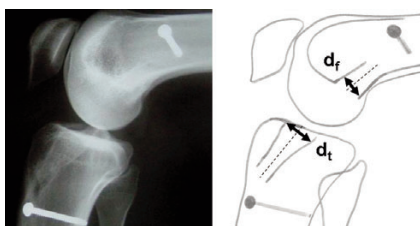


Figure 3. Assessment of the tunnel diameter one year post-operative. The shortest distance between the sclerotic zones surrounding the tunnel by the Blumensaat's line and by the subsclerotic zone of the tibial plateau are expressed as d_f and d_t .

bone block position or the tunnel enlargement could not be clearly determined on the X-rays were excluded from the related question in this study.

Statistical analysis

The descriptive statistics comprised the data in percent, mean value, standard deviation (SD) and 95% confidence intervals. The Pearson's correlation coefficient r was calculated and all P values were two-tailed. The level of statistical significance was set at $P=0.05$.

Results

Tunnel position and bone block depth

The exit of the femoral tunnels were located on average at $x_f=80\%$ ($n=103$, 57-95%, $SD\pm 8\%$) on the anterior posterior distance of the extension of the Blumensaat's line. The femoral bone blocks were located on average at $y_f=5.2$ mm ($n=100$, -10 to +21 mm, $SD\pm 5.9$ mm) proximally to the Blumensaat's line. A minus value corresponds to a bone block tip position distal to the Blumensaat's line in the lateral condyle.

The exits of the tibial tunnels were located on average at $x_t=43\%$ ($n=103$, 29-67%, $SD\pm 7\%$) on the anteroposterior tibial plateau diameter. The tibial bone block lies on average at $y_t=6.3$ mm ($n=103$, -6 to +32 mm, $SD\pm 7.6$ mm) distal to the subchondral zone of the tibial plateau. A minus value corresponds to a bone block tip over the sclerotic zone of the tibial plateau but still surrounded by bone and cartilage in the tibial eminence.

The bone block depth in the femur y_f correlates negatively with the bone block depth in the tibia y_t ($n=101$, Pearson's correlation coefficient $r=-0.56$, $P<0.01$, 95% confidence interval = -0.33 to -0.68).

Tunnel enlargement

In 52% of the cases we found a post-operative tunnel enlargement in the femur after one year. The tunnel diameter at the level of the Blumensaat's line d_f was enlarged during the observation period on average from 10.0 to 11.4 mm ($n=92$, 10-18 mm, $SD\pm 2.1$). The tunnel enlargement in the femur Δd_f positively and significantly correlates with the bone block depth in the femur y_f ($n=92$, Pearson's correlation coefficient $r_{fd}=0.3$, $P=0.005$, 95% confidence interval = +0.1 to +0.45). Tunnel enlargements occurred also in cases in which the bone blocks were located close to the joint. The enlarged tunnel diameter in this group was 10.8 mm on average ($n=32$, 10-15 mm, $SD\pm 1.3$). For every 10 mm where the bone block was more proximal in the femur there

was an additional tunnel enlargement Δd_f of approximately 0.6 mm (Figure 4).

In the tibia, we found in 81% of the cases a post-operative tunnel enlargement after one year. The tunnel diameter at the level of the subchondral sclerosis of the tibial plateau d_t was on average enlarged from 10 mm to 12.7 mm during the observation period of one year ($n=105$, 10-18 mm, $SD\pm 1.9$). The tunnel enlargement of the tibia Δd_t correlates positively and significantly with the bone block depth in the tibia y_t ($n=106$, Pearson's correlation coefficient $r_{td}=0.29$, $P=0.003$, 95% confidence interval = +0.10 to +0.45). Bone blocks lying close to the joint leads to tunnel enlargements from 10-11.7 mm on average ($n=30$, 10-16 mm, $SD\pm 1.8$). The additional tunnel enlargement in the tibia Δd_t is also approximately 0.6 mm per 10 mm deeper bone block position (Figure 4).

The tunnel position in the anteroposterior direction of the femur x_f does not correlate significantly with the tunnel enlargement Δd_f ($n=94$, Pearson's correlation $r_{fp}=-0.089$, $P=0.40$). Also the tunnel position of the tibia x_t in the sagittal plane does not correlate significantly with the tunnel enlargement in the tibia Δd_t ($n=106$, Pearson's correlation coefficient $r_{tp}=0.076$, $P=0.44$) (Figure 5).

Discussion

The incidence and the size of femoral tunnel enlargements were similar to the findings of Webster.²⁹ In 52% of the cases we found a femoral tunnel enlargement with an average enlargement of 1.4 mm or 11.4%, respectively. Webster observed a femoral tunnel enlargement in 32% of the cases with a quite similar average tunnel enlargement of 11.9%.²⁹

As suggested by the Quadrant method, the optimal femoral cruciate origin is on the extended Blumensaat's line at $x_f=75\%$ of the anteroposterior distance.¹ In our collective, the drill canal position was in the target area of $75\pm 10\%$ on the extended Blumensaat's line in 71% of the cases. But also in the 29% tunnel position out of the target area, the quantity and quality of tunnel enlargements did not differ from those well positioned.

According to Jackson and Gasser, the optimal tibial cruciate lies at $x_t=40\%$ and according to Stäubli and Rauschnig at $x_t=43\%$ along the anteroposterior distance of the tibial plateau.^{3,28} In our study, 79% of the tibial drill canals were in the targeted area of $42\pm 10\%$. Also Peyrache found no significant correlation between the tibial drill canal position and the tunnel enlargement as we did³⁰ (Figure 5). Since we had no extreme anterior drill canal

position, we were not able to observe a pronounced tunnel enlargement as described by Zijl and Segawa.^{16,31}

Tibial tunnel enlargements occurred in 81% in our study. It was more frequent in the tibia than in the femur. Also Majewski found a post-operative enlargement of the drill canals in the tibia in 81.7% of cases.³² In contrast to our collective, the transplants were fixed by interference screws. The average tibial tunnel enlargement in our study was 2.7 ± 1.9 mm and corresponds to the results of Zijl who reported a tunnel enlargement of 2.6 ± 2.4 mm.¹⁶

In our study, the average distance of the femoral bone block to the Blumensaat's line was $y_f = 5.2$ mm. The average distance between the bone block to the tibial plateau was $y_t = 6.3$ mm. Due to different operating techniques with femoral bone block anchoring close to the joint, considerably larger tibial bone block depths from 23.6-15.6 mm, respectively were described.^{26,27} Only publications concerning the effect of the bone block position on the tunnel enlargement at the tibial side are available.^{20,26,32}

The excess length of the ligament part of our transplants, calculated as the sum of the femoral and the tibial bone block depths ($y_f + y_t$) was 11.5 mm. The length of the patellar tendon varied between 48.4 ± 6.0 mm and 45.5 ± 4.7 mm respectively.^{27,33} Therefore the intraarticular portion of the transplant is mathematical between 36.9 mm and 34.0 mm, respectively. Li described a length of the native ACL in the anteromedial bundle of only 32.5 ± 2.8 mm.³⁴ This difference in length can be explained by a different ethnic group and a different method of measuring. Li used the joint surfaces as reference whereas in our study the Blumensaat's line and the subchondral sclerosis of the tibial plateau were used.

A bone block positioned 10 mm deeper was associated with an additional tunnel enlargement of about 0.6 mm (Figure 4). This correlation is identical in the femur and in the tibia. In a study from Hogervorst, in the tibia the correlation between the bone block depth and the tunnel enlargement was more pronounced than the findings in our study.²⁰

The observation period of one year used in this study is sufficient since changes in the tunnel diameter rarely occur later than three to six months.^{21,26,29,30}

A mechanical process doesn't seem to be the only reason for tunnel enlargement since no tunnel enlargement was recognized either in deeper lying bone blocks or in bone blocks at the joint surface. In this study, all patients had the same standardized analgetic therapy with Paracetamol and NSAID as required. All patients had the same post-operative treatment with a standardized rehabilitation program. So, these factors don't explain the difference. The shape of the transplant differs from

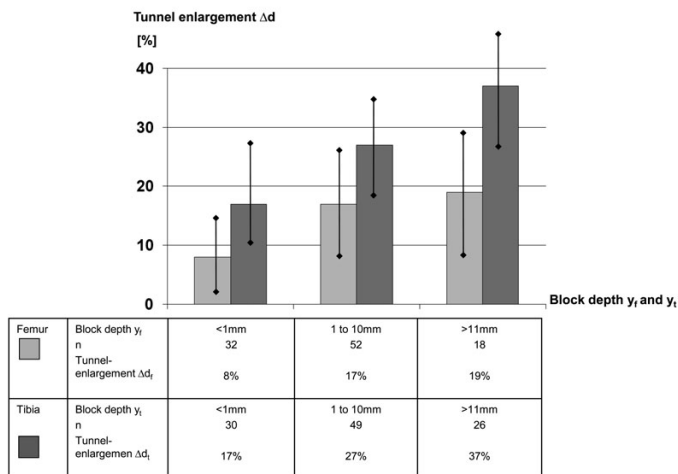


Figure 4. Tunnel enlargement in relation to the bone block depth.

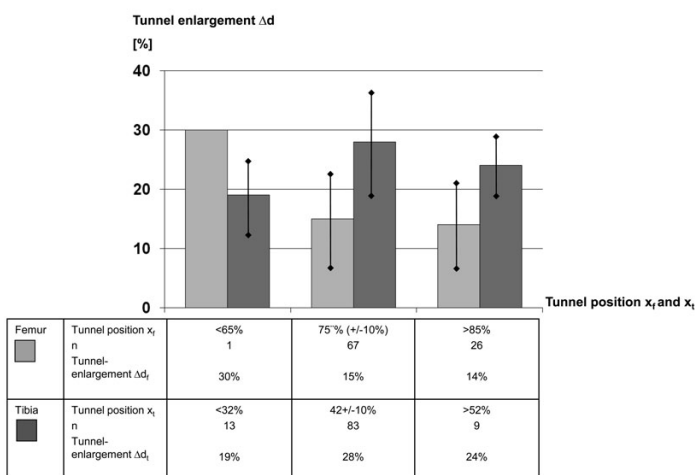


Figure 5. Tunnel enlargement in relation to the tunnel position.

that of the circular drilled bone tunnel. Synovial fluid may enter the gaps into the bone or underneath the cartilage which can lead to periarticular osteolysis.^{25,35} Thus the incomplete fitting of the ligament could maybe also account for the tunnel enlargemen.

mechanical as well as biochemical factors might be the reason for tunnel enlargement. Fixation of the transplant close to the articular surface could partially resolve the problem of tunnel enlargement.

Conclusions

The tunnel enlargement was not influenced by the anteriorposterior position of the bone tunnel as long as it lies near the recommended zone at the anatomical insertion site. The incidence of tunnel enlargement was higher in the tibia than in the femur. The relative excess length of the patellar tendon promotes tunnel enlargement. The dimension of the tunnel enlargement relates to the bone block depth in the femur and similarly in the tibia. Both

References

- Bernard M, Hertel P, Hornung H, and Cierpinski T. Femoral insertion of the ACL. Radiographic quadrant method. Am J Knee Surg 1997;10:14-21.
- Khalfayan EE, Sharkey PF, Alexander AH, et al. The relationship between tunnel placement and clinical results after anterior cruciate ligament reconstruction. Am J Sports Med 1996;24:335-41.
- Staubli HU, Rauschnig W. Tibial attachment area of the anterior cruciate liga-

- ment in the extended knee position. Anatomy and cryosections in vitro complemented by magnetic resonance arthrography in vivo. *Knee Surg Sports Traumatol Arthrosc* 1994;2:138-46.
4. Staeubli HU, Adam O, Becker W, Burkart R. Anterior cruciate ligament and intercondylar notch in the coronal oblique plane: anatomy complemented by magnetic resonance imaging in cruciate ligament-intact knees. *Arthroscopy* 1999;15:349-59.
 5. Jackson DW and Gasser SI. Tibial tunnel placement in ACL reconstruction. *Arthroscopy* 1994;10:124-31.
 6. Aglietti P, Zaccherotti G, Simeone AJ, Buzzi R. Anatomic versus non-anatomic tibial fixation in anterior cruciate ligament reconstruction with bone-patellar tendon-bone graft. *Knee Surg Sports Traumatol Arthrosc* 1998;6:S43-8.
 7. Ikeda HH, Muneta TT, Niga SS, et al. The long-term effects of tibial drill hole position on the outcome of anterior cruciate ligament reconstruction. *Arthroscopy* 1999;15:287.
 8. Morgan CD, Kalman VR, Grawl DM. Definitive landmarks for reproducible tibial tunnel placement in anterior cruciate ligament reconstruction. *Arthroscopy* 1995;11:275-88.
 9. Muneta TT, Yamamoto HH, Ishibashi TT, et al. The effects of tibial tunnel placement and roofplasty on reconstructed anterior cruciate ligament knees. *Arthroscopy* 1995;11:57.
 10. Romano VM, Graf BK, Keene JS, Lange RH. Anterior cruciate ligament reconstruction. The effect of tibial tunnel placement on range of motion. *Am J Sports Med* 1993;21:415-8.
 11. Giron F, Buzzi R, Aglietti P. Femoral tunnel position in anterior cruciate ligament reconstruction using three techniques. A cadaver study. *Arthroscopy* 1999;15:750-6.
 12. Amis A and Jakob P. Anterior cruciate ligament graft positioning, tensioning and twisting. *Knee Surg Sports Traumatol Arthrosc* 1998;6:S2-12.
 13. Friederich NF, O'Brien WR. Anterior cruciate ligament graft tensioning versus knee stability. *Knee Surg Sports Traumatol Arthrosc* 1998;6:S38-42.
 14. Fahey M, Indelicato PA. Bone tunnel enlargement after anterior cruciate ligament replacement. *Am J Sports Med* 1994;22:410-4.
 15. L'Insalata JC, Klatt B, Fu FH, Harner CD. Tunnel expansion following anterior cruciate ligament reconstruction: a comparison of hamstring and patellar tendon autografts. *Knee Surg Sports Traumatol Arthrosc* 1997;5:234-8.
 16. Zijl JA, Kleipool AE, Willems WJ. Comparison of tibial tunnel enlargement after anterior cruciate ligament reconstruction using patellar tendon autograft or allograft. *Am J Sports Med* 2000;28:547-51.
 17. Clatworthy MG, Annear P, Bulow JU, Bartlett RJ. Tunnel widening in anterior cruciate ligament reconstruction: a prospective evaluation of hamstring and patella tendon grafts. *Knee Surg Sports Traumatol Arthrosc* 1999;7:138-45.
 18. Segawa H, Koga Y, Omori, G, et al. Influence of the femoral tunnel location and angle on the contact pressure in the femoral tunnel in anterior cruciate ligament reconstruction. *Am J Sports Med* 2003;31:444-8.
 19. Hefzy MS, Grood ES and Noyes FR. Factors affecting the region of most isometric femoral attachments. Part II: The anterior cruciate ligament. *Am J Sports Med* 1989;17:208-16.
 20. Hogervorst T, van der Hart CP, Pels Rijcken TH, Taconis WK. Abnormal bone scans of the tibial tunnel 2 years after patella ligament anterior cruciate ligament reconstruction: correlation with tunnel enlargement and tibial graft length. *Knee Surg Sports Traumatol Arthrosc* 2000;8:322-8.
 21. Buelow JU, Siebold R and Ellermann A. A prospective evaluation of tunnel enlargement in anterior cruciate ligament reconstruction with hamstrings: extracortical versus anatomical fixation. *Knee Surg Sports Traumatol Arthrosc* 2002;10:80-5.
 22. Jagodzinski M, Foerstemann T, Mall G, et al. Analysis of forces of ACL reconstructions at the tunnel entrance: is tunnel enlargement a biomechanical problem? *J Biomech* 2005;38:23-31.
 23. Wilson TC, Kantaras A, Atay A and Johnson DL. Tunnel enlargement after anterior cruciate ligament surgery. *Am J Sports Med* 2004;32:543-9.
 24. Hoher J, Moller HD, Fu FH. Bone tunnel enlargement after anterior cruciate ligament reconstruction: fact or fiction? *Knee Surg Sports Traumatol Arthrosc* 1998;6:231-40.
 25. Zysk SP, Fraunberger P, Veihelmann A, et al. Tunnel enlargement and changes in synovial fluid cytokine profile following anterior cruciate ligament reconstruction with patellar tendon and hamstring tendon autografts. *Knee Surg Sports Traumatol Arthrosc* 2004;12:98-103.
 26. Fink C, Zapp M, Benedetto KP, et al. Tibial tunnel enlargement following anterior cruciate ligament reconstruction with patellar tendon autograft. *Arthroscopy* 2001;17:138-43.
 27. Denti M, Bigoni M, Randelli P, et al. Graft-tunnel mismatch in endoscopic anterior cruciate ligament reconstruction. Intraoperative and cadaver measurement of the intra-articular graft length and the length of the patellar tendon. *Knee Surg Sports Traumatol Arthrosc* 1998;6:165-8.
 28. Klos TV, Harman MK, Habets RJ, et al. Locating femoral graft placement from lateral radiographs in anterior cruciate ligament reconstruction: a comparison of 3 methods of measuring radiographic images. *Arthroscopy* 2000;16:499-504.
 29. Webster KE, Feller JA, Hameister KA. Bone tunnel enlargement following anterior cruciate ligament reconstruction: a randomised comparison of hamstring and patellar tendon grafts with 2-year follow-up. *Knee Surg Sports Traumatol Arthrosc* 2001;9:86-91.
 30. Peyrache MD, Djian P, Christel P, Witvoet J. Tibial tunnel enlargement after anterior cruciate ligament reconstruction by autogenous bone-patellar tendon-bone graft. *Knee Surg Sports Traumatol Arthrosc* 1996;4:2-8.
 31. Segawa H, Omori G, Tomita S, Koga Y. Bone tunnel enlargement after anterior cruciate ligament reconstruction using hamstring tendons. *Knee Surg Sports Traumatol Arthrosc* 2001;9:206-10.
 32. Majewski M, Schulte KR, Harner CD. Tibial tunnel enlargement after arthroscopic anterior cruciate ligament reconstruction. *Sportverletz Sportschaden* 2002;16:22-5.
 33. Shaffer B, Gow W, Tibone JE. Graft-tunnel mismatch in endoscopic anterior cruciate ligament reconstruction: a new technique of intraarticular measurement and modified graft harvesting. *Arthroscopy* 1993;9:633-46.
 34. Li G, DeFrate LE, Sun H, Gill TJ. In vivo elongation of the anterior cruciate ligament and posterior cruciate ligament during knee flexion. *Am J Sports Med* 2004;32:1415-20.
 35. Schmalzried TP, Akizuki KH, Fedenko AN, Mirra J. The role of access of joint fluid to bone in periarticular osteolysis. A report of four cases. *J Bone Joint Surg Am* 1997;79:447-52.