

Clinical Profile of Patients with Head and Neck Amyloidosis: A Single-Institution Retrospective Chart Review

Anup Singh¹  Mubashshirul Haq¹ Poonam Gautam¹ Dheeraj Gautam² Aru C. Handa¹
Kumud K. Handa¹

¹Department of Otorhinolaryngology and Head and Neck Surgery, Medanta - The Medicity, Gurugram, Haryana, India

²Department of Pathology, Medanta - The Medicity, Gurugram, Haryana, India

Address for correspondence Dr. Anup Singh, MS, Department of Otorhinolaryngology and Head and Neck Surgery, Medanta, The Medicity, 8th floor, Sector 38, Gurugram-122001, Haryana, India (e-mail: anoop.aiims1@gmail.com).

Int Arch Otorhinolaryngol 2020;24(4):e450–e456.

Abstract

Introduction Isolated amyloidosis involving the head and neck is a rare entity. The pathophysiology of the localized disease appears to be distinct from that of the systemic counterpart. Systemic progression of the localized disease is unusual, and the prognosis of the localized form is excellent.

Objective To describe the demographic and clinicopathological characteristics of patients presenting with localized head and neck subsite amyloidosis.

Methods A retrospective chart review of the patients with head and neck amyloidosis identified by the electronic search of the electronic database of the Departments of Pathology and Otorhinolaryngology was performed. The various demographic and clinical data were tabulated.

Results In total, seven patients (four females, three males) with localized head and neck amyloidosis (three supraglottic, three lingual and one sinonasal) were identified. Six patients had AL-amyloid deposits, and one patient had AA-amyloid deposits. Supraglottic involvement and that of the base of the tongue were treated surgically using CO2 laser, and these patients were disease-free at the last follow-up. The patient with sinonasal amyloidosis experienced symptom recurrence after six months of the functional endoscopic sinus surgery. All of the patients were screened for systemic amyloidosis with abdominal fat pad biopsy, and were found to be free of systemic spread.

Conclusion Isolated head and neck amyloidosis, as opposed to systemic amyloidosis, has an excellent prognosis in terms of survival. Therefore, systemic amyloidosis should be excluded in all cases. The treatment of choice remains surgical excision; however, watchful waiting may be a suitable strategy for mild symptoms or for cases in which the disease was discovered incidentally.

Keywords

- ▶ amyloidosis
- ▶ plasma cells
- ▶ laryngeal diseases
- ▶ macroglossia
- ▶ prognosis

Introduction

Amyloidosis refers to the extracellular aggregation of misfolded proteins causing cellular and organ dysfunction. It is a rare disorder, with an incidence of 5 to 10 cases per million

people per year. To date, a total of 36 types of amyloid proteins (14 involved in systemic forms, 19 involved in localized forms, and 3 subtypes in both the localized and systemic forms) have been described in humans (as well as 10 other types in other vertebrates).¹ The amyloid proteins

received
September 4, 2019
accepted
November 11, 2019

DOI <https://doi.org/10.1055/s-0039-3402494>.
ISSN 1809-9777.

Copyright © 2020 by Thieme Revinter Publicações Ltda, Rio de Janeiro, Brazil

License terms



are named using the prefix 'A' (for amyloid) followed by the name of the protein forming the fibril. The most common forms of amyloidosis encountered in the clinical practice are: AL (formed by the κ or λ light chain of immunoglobulin G, and constituting 75% of the systemic amyloidosis cases); AA (formed by the accumulation of the misfolded acute phase reactant 'serum amyloid A' protein, and constituting 5% of the systemic amyloidosis cases); ATTR (deposition of misfolded transthyretin, either normal or mutated); and $A\beta_2M$ (pathological deposition of the β_2 microglobulin protein in patients on prolonged renal dialysis).² Clinically, amyloidosis has been classified as follows:

- 1) Localized versus systemic;
- 2) Primary (plasma cell dyscrasia) versus secondary (chronic inflammatory conditions); and
- 3) Hereditary (ATTR, familial Mediterranean fever) versus acquired (multiple myeloma).

From a practical perspective, the prognosis of the localized and systemic forms lies on the two extreme ends of the spectrum, with localized amyloidosis being associated with an excellent prognosis in terms of survival (which remains nearly the same as that of the general population), and systemic dissemination resulting in a dismal outcome of a mean survival of 5 to 15 months.^{3,4}

Head and neck involvement, either in isolation or as a part of the systemic disease, occurs in up to 20% of patients, and is associated with the AL type of amyloid deposition.^{2,5} We describe our experience with seven patients presenting with head and neck amyloidosis and emphasize on keeping a high index of suspicion for the diverse faces of this rare entity. The various ways in which the disease may present are reviewed, and the management issues are discussed.

Materials and Methods

A retrospective chart review of the patients presenting with amyloidosis localized to the head and neck subsites was conducted after obtaining permission from the institutional Ethics Committee (MICR- 991/2019 [Academic]). Patient identification was performed by searching the records of the past six years in the electronic database of the Departments of Pathology and Otorhinolaryngology and Head and Neck Surgery. The details of the patient were tabulated to include the demographic data and disease-specific data, that is, age, gender, presenting complaints, associated systemic comorbidities, local examination findings, treatment, type of amyloid protein deposition on immunohistochemistry, workup for underlying systemic illness, and systemic amyloidosis. For the workup for underlying systemic illness and systemic amyloidosis, the patients were reviewed in the Department of Internal Medicine, where a complete blood count, renal & liver function tests, urine routine microscopy, biochemistry, chest X-ray, electrocardiogram, abdominal ultrasonography and more specific tests, like the C3 (complement factor 3), anti-nuclear antibody, antineutrophilic cytoplasmic antibodies, rheumatoid factor, Bence-Jones pro-

teinuria, and serum & urine electrophoresis, abdominal fat pad biopsy were done to rule out systemic amyloidosis. For the follow-up, the last follow-up clinical records were referred to, and the patients were contacted by phone and called for clinical assessment as needed.

Results

A total of 7 patients presenting with head and neck amyloidosis were identified (– **Table 1**) over a period of 6 years (from January 2013 to January 2019). Three patients had laryngeal involvement (all three with supraglottic involvement), three had involvement of the tongue (macroglossia or involvement of the base of the tongue), while one patient had diffuse involvement of the nose and paranasal sinuses. The clinical picture of laryngeal amyloidosis is depicted in – **Fig. 1**, while – **Fig. 2** shows the non-contrast computed tomography (CT) scan findings of the patient with sinonasal amyloidosis. This patient has been previously reported in another study⁶ from our institute. The ratio of female to male patients was of 1.3:1. The age of the patients ranged from 19 to 69 years, with a median of 62 years. The diagnosis of every patient was confirmed by the biopsy of the lesion showing typical apple-green birefringence under polarized light microscopy with Congo red stain (– **Fig. 3**). The immunohistochemistry showed that the amyloid deposits were of the AL type in all but one patient (this one patient presented with macroglossia and was found to have the AA type of amyloid deposits). None of the patients were found to have any causative active systemic illness (only one patient was positive for hepatitis B surface antigen [HBsAg +ve] on serology, but there was no evidence of liver dysfunction on the blood biochemistry or fibroscan). The abdominal fat pad biopsy to look for systemic involvement was negative in all of the patients.

Surgical treatment was undertaken with curative intent in five patients, and four of them (in whom disease excision was performed with CO₂ laser for supraglottic involvement or that of the base of the tongue) were free of disease at the last follow-up. The patient with sinonasal amyloidosis experienced recurrence after six months of surgery, but refused any further surgical intervention. A total of two patients (presenting with mild dysphagia and found to have macroglossia) refused surgical intervention in view of the mild symptomatology. One of them, despite being negative for systemic amyloidosis, died of a cardiac cause 18 months after the diagnosis. We could not discern whether the mortality was a result of the systemic amyloidosis or of an independent event.

Discussion

The amyloid fibrils are linear, non-branching, tubular proteins, 7.5–10 nm in diameter, formed by misfolding of normal body proteins, arranged in an antiparallel crossed β -pleated sheet ultrastructure on X-ray crystallography (instead of the normally observed α -helical structure). The fibrils autoaggregate in association with other components (glycosaminoglycans [GAGs], apolipoprotein-E and serum amyloid P [SAP]) in a ratio

Table 1 Clinical and demographic details of the patients diagnosed with head and neck amyloidosis

SN	Age (years)/ Gender	Site	Chief complaints	Examination findings	Systemic involvement	Treatment	Co-morbidities	Amyloid protein type	Follow-up
1	62/F	Larynx	Change in voice × 1 year, MLS 10 years back for similar symptoms	Nodular growth over left false vocal cord and ventricle, reaching up to the anterior commissure	No	MLS excision using CO ₂ laser	DM	AL	7 months, no recurrence
2	66/M	Larynx	Change in voice × 10 months	Broad based indurated lesion over the left false vocal cord	No	MLS excision using CO ₂ laser	HBsAg +ve	AL	18 months, no recurrence
3	29/F	Larynx	Change in voice × 18 months	Broad-based nodular lesion involving both the false vocal cord and ventricle with polypoidal changes involving the anterior commissure area	No	MLS excision using CO ₂ laser	–	AL	3 months, no recurrence
4	69/F	Oropharynx	Pain in right ear and foreign body sensation in the throat × 1 year	Firm mass involving the base of the tongue	No	CO ₂ laser excision	HTN, DM	AL	18 months, no recurrence
5	52/M	Oral cavity and oropharynx	Gradual progressive dysphagia × 2 years	Macroglossia	No	Surgical treatment refused by the patient	HTN	AA	Expired after 1.5 years following the diagnosis (suspected cardiac involvement; documents not available)
6	62/F	Oral cavity and oropharynx	Dysphagia × 1 year	Macroglossia	No	Surgical treatment refused by the patient in view of the mild symptoms	DM	AL	7 years, stable disease
7 ^a	19/M	Nasal cavity and paranasal sinuses	Nasal blockage	1) broadened nasal dorsum with telecanthus; 2) grossly edematous mucosa with polypoidal changes on the right septum, the turbinates, and both sides of the nasal wall	No	FESS and microdebrider-assisted turbinoplasty	–	AL	4 years, symptom recurrence after 6 months of surgery, further surgery refused by the patient after ruling out systemic disease

Abbreviations: +ve, positive; AL, amyloidosis formed by the κ or λ light chain of the immunoglobulin G; AA, amyloidosis formed by the accumulation of the misfolded acute phase reactant 'serum amyloid A' protein; DM, diabetes mellitus; F, female; FESS, functional endoscopic sinus surgery; HBsAg, hepatitis B surface antigen; HTN, hypertension; M, male; MLS, microlaryngeal surgery; NA, not available; SN, serial number.
 Note: ^a Patient previously reported in another study⁶ from our institute.

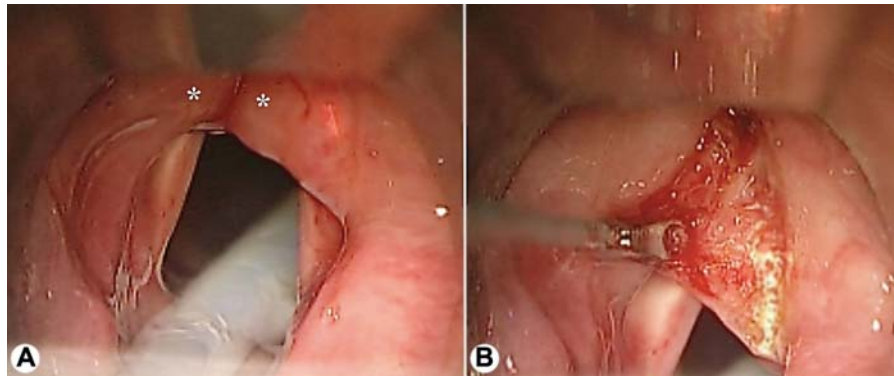


Fig. 1 (A) Microlaryngoscopic view showing the mucosa-covered bulge involving bilateral true vocal cords (*). (B) Excision of the lesion using CO₂ laser in the process. (Patient-1)

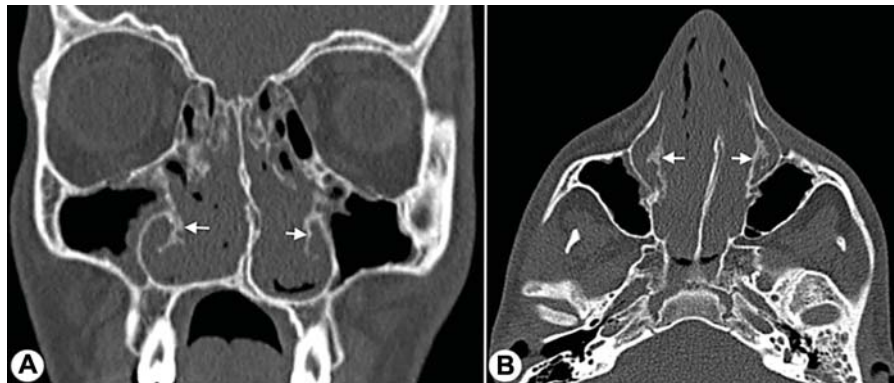


Fig. 2 Non-contrast computed tomography (CT) scan of the paranasal sinuses: (A) coronal and (B) axial views showing bulky soft-tissue density involving the bilateral nasal cavity, the middle meatus and the anterior ethmoid region, causing expansion of the nasal cavity with lateral displacement of the lateral nasal wall. The 'fluffy' bony changes, most pronounced in the inferior turbinate bone, can be appreciated (arrows). (Patient-7)

of roughly 9:1, and, being insoluble, get deposited in the extracellular/interstitial compartment, forming homogenous, eosinophilic, amorphous precipitates that exhibit the pathognomonic 'apple-green birefringence' with Congo red stain under polarized light microscopy.⁴

Localized amyloidosis constitutes ~ 9% of all the cases of amyloidosis. The AL is the type of amyloid protein commonly deposited in these patients. The pathogenesis of localized amyloid deposition is not fully understood, but there is some evidence indicating that it may be the result of a localized

collection of plasma cells producing light chains (speculated to be a burnt-out plasmacytoma) in a disordered fashion. These plasma cell deposits are not observed in systemic AL amyloidosis, in which the circulating free light chains produced from the bone marrow plasma cells (in the setting of plasma cell dyscrasia) are deposited in distant body sites. Giant cells of the foreign-body type are also often observed in the vicinity of the localized amyloid deposits, and are thought to be involved in the pathogenesis by modification of the light chains produced locally by the plasma cells.^{5,7}

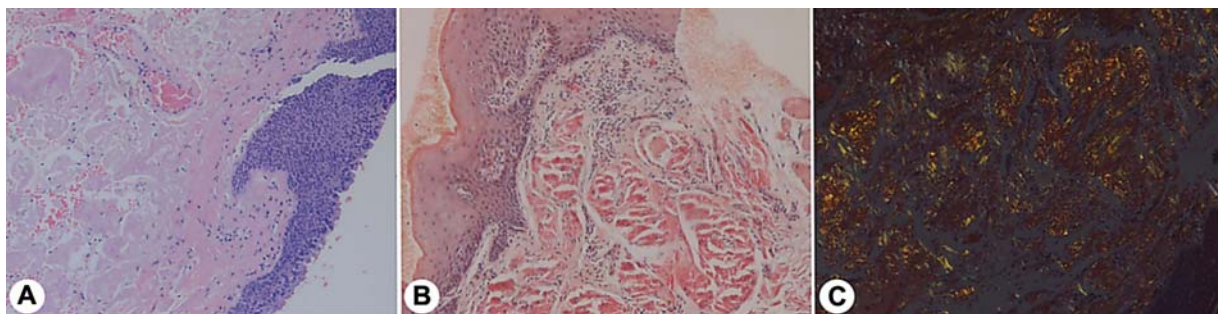


Fig. 3 (A; B) Light microscopic view showing homogenous extracellular eosinophilic amorphous subepithelial and perivascular deposition of amyloid ([A] hematoxylin and eosin stain; [B] Congo red stain, non-polarized; original magnification: 100x). (C) Polarized microscopy showing apple-green birefringence with Congo red corresponding to areas of amyloid deposition. (Original magnification: 100x.)

In the head and neck area, the larynx and the tongue are the most common sites affected. Laryngeal involvement has been estimated to occur in 9% to 15% of all cases of amyloidosis, and amyloidosis constitutes between 0.2% and 1.2% of all benign tumors involving the larynx.⁸ The most common pattern of laryngeal involvement is in the form of submucosal nodular deposits in false vocal cords/ventricles, followed by the aryepiglottic fold, and the subglottic and true vocal cord involvement. Systemic involvement with laryngeal amyloidosis is unusual, and the need for a systemic workup in the setting of clinically-isolated laryngeal amyloidosis is debated in the literature. There are opinions for and against performing systemic investigations to search for the underlying etiology and systemic dissemination of the amyloidosis, with no consensus.⁸⁻¹² In our cohort of patients, the largest proportion was constituted by the laryngeal patients, followed by those with oral tongue involvement.

The most common presentation with tongue involvement is macroglossia (it occurs exclusively in the AL type); however, focal involvement of the tongue and other oral subsites has been reported.^{2,13} Unlike isolated laryngeal disease, amyloidosis presenting with macroglossia needs to be thoroughly evaluated to rule out the common association with plasma cell dyscrasia/multiple myeloma and systemic amyloidosis. One of our patients was harboring the AA type of amyloidosis, while none of the patients were positive for systemic disease.

The differentials are site and morphology specific, and, for the usual sites of involvement, that is, the larynx and the tongue, they are listed in ►Table 2. Amyloidosis involving other head and neck subsites is rarer. In one case report,¹⁴ the amyloidosis involved the nasopharynx, the sinonasal compartment, the oropharynx (pharyngeal wall, tonsils, base of the tongue) and the hypopharynx. Some of the peculiarities associated with nasal amyloidosis can offer the clue to the diagnosis. The fluffy appearance of the surrounding sinonasal bone (probably representing the osteoblastic activity in response to the submucosally-deposited amyloid) and unusually extensive and early synechia formation postsurgery should alert the clinician to the underlying amyloidosis.^{15,16} Our

patient with sinonasal amyloidosis had extensive synechia formation intraoperatively along with the polypoidal changes, and the CT scan showed the fluffy appearance of the surrounding sinonasal bone consistent with amyloidosis. Localized amyloidosis generally does not affect life expectancy, while, with systemic amyloidosis, the prognosis is grave, with a mean survival of 5 to 15 months (it is worse with multiple myeloma than with the idiopathic cases).¹⁷

In the absence of good evidence (understandable in light of the rare occurrence of the disease), systemic symptomatology, the clinical pattern of involvement along with institutional policies continue to influence the decision-making regarding the systemic workup. The latter aims to locate the cause/source of the amyloid protein formation and to rule out systemic amyloidosis. In addition to the routine blood workup with complete blood count and renal & liver function tests, urine routine microscopy and biochemistry, chest X-ray, electrocardiogram, abdominal ultrasonography, and more specific tests, like the mantoux test, erythrocyte sedimentation rate, C3, antinuclear antibody, antineutrophilic cytoplasmic antibodies, rheumatoid factors, Bence-Jones proteinuria, serum or urine electrophoresis, as well as bone marrow biopsy should be ordered. Systemic amyloidosis may be identified by using imaging (iodine [¹²³I] SAP scintigraphy, non-invasive and fairly accurate, but used seldom in view of the limited availability) or tissue diagnosis with abdominal fat pad needle aspiration/biopsy (sensitivity ~ 80%) or rectal biopsy (sensitivity ~ 75%) as a surrogate for the detection of deeper organ involvement (since performing a biopsy directly from the vital organs may be riskier).^{2,8,12,16} We used abdominal fat pad biopsy in our patients to assess the systemic involvement in view of the easy availability, acceptable sensitivity and patient compliance with the procedure.

Differentiation of the type of amyloid protein (amyloid typing) can be performed with immunohistochemistry (IHC), immunofluorescence (IF) of formalin-fixed paraffin-embedded (FFPE) tissue or laser microdissection followed by liquid chromatography with mass spectrometry (LMD-LC-MS). The latter is the gold standard of proteomics-based

Table 2 Differential diagnosis of laryngeal and lingual amyloidosis

Serial number	Laryngeal amyloidosis	Tongue amyloidosis (localized)	Tongue amyloidosis (macroglossia)
1	Malignancies (like squamous cell carcinoma, chondrosarcoma, salivary gland tumors, metastasis from the medullary thyroid carcinoma)	Benign tumors (like granular cell tumors, minor salivary gland tumors, neurogenic tumors, fibroma, lipoma)	Endocrine abnormalities (like acromegaly and hypothyroidism)
2	Laryngeal nodule/polyp	Malignancy	Mycobacterial infection
3	Benign tumors (like schwannoma, chondroma, granular cell tumors)	Fungal infection	Lymphangioma
4	Chronic indolent fungal infection	Mycobacterial infection	Lymphoma
5	Mycobacterial infection or syphilitic gumma	Syphilitic gumma	Neurofibromatosis
6	Laryngeal sarcoidosis	Sarcoidosis	Beckwith–Wiedemann Syndrome

amyloid typing.¹⁸ The availability of these specialized investigations, however, is not universal.

The management of localized head and neck amyloidosis is symptom-directed. When there is no suspicion of systemic involvement or the systemic disease has been ruled out with appropriate tests, the treatment can include watchful waiting in patients with asymptomatic disease or conservative resection for symptomatic relief. In view of the presence of fragile capillaries because of amyloid infiltration, resection of the lesion with simultaneous hemostasis, with the laser, for example, may be the most suitable strategy wherever possible and accessible.¹⁹ Keeping in mind the slow and prolonged disease progression, conservative resection with a yearly follow-up extended for up to 10 years is advised. All of our patients were offered surgical treatment. In four of our patients (three with laryngeal amyloidosis and one with base of the tongue amyloidosis), complete excision could be performed, and they did not develop recurrence during subsequent the follow-up. Conservative debulking was performed in one of the patients with macroglossia, and the patient had a stable disease at the seven-year follow-up, while another macroglossia patient refused surgery. The sinonasal amyloidosis patient underwent palliative debridement in view of the diffuse sinonasal involvement, and did in fact develop recurrence, but opted for the routine follow-up after receiving an explanation about the nature of the disease.

Local or systemic chemotherapy (including steroids) play no role in the control of localized amyloidosis. Radiotherapy has been used sparingly, in cases not amenable to surgery, or in cases of patients refusing surgery for localized amyloidosis. The results with radiotherapy have been equivocal, with some benefits in terms of control of the progression of the local disease. However, the optimal dose of radiotherapy remains poorly defined, with dosages from 20 Gy to 40 Gy being used for cases of tracheobronchial amyloidosis.^{20–22} Sinonasal and nasopharyngeal amyloidosis are considered unsuitable for treatment with radiation in view of the close proximity to the surrounding vital structures. Oral and oropharyngeal amyloidosis are usually accessible to surgical debulking when needed, since radiotherapy is not usually contemplated in these patients.

Our study suffers from the limitations of any retrospective study and a limited patient population. The follow-up for some of the patients was limited to a few months, which is too short to comment on the recurrence rate. However, given the rarity of the isolated amyloidosis limited to the head and neck subsites, it is barely practical to involve patients prospectively or to carry out randomization. The current study focuses on the clinical profile of the patients with isolated amyloidosis in the ENT domain, and reinforces the fact that the otorhinolaryngologists and head & neck surgeons must be cognizant of the implications of localized versus systemic amyloidosis.

Conclusion

The present study describes our experience with seven patients with amyloidosis isolated to the head and neck subsites. The localized form of this disease has an excellent

prognosis in terms of survival. The workup for systemic amyloidosis should be offered to every patient with localized head and neck amyloidosis. In cases of truly localized disease, when needed, surgical excision is the treatment of choice, with prolonged follow-up to watch for disease recurrence.

Declarations

- The present work was performed at Medanta - The Medicity, Gurugram, Haryana, India.
- Informed/Written consent was waived by the Institutional Review Board.

Conflict of Interests

The authors have no conflict of interests to declare.

References

- 1 Benson MD, Buxbaum JN, Eisenberg DS, et al. Amyloid nomenclature 2018: recommendations by the International Society of Amyloidosis (ISA) nomenclature committee. *Amyloid* 2018;25(04):215–219. DOI: 10.1080/13506129.2018.1549825
- 2 Penner CR, Muller S. Head and neck amyloidosis: a clinicopathologic study of 15 cases. *Oral Oncol* 2006;42(04):421–429. DOI: 10.1016/j.oraloncology.2005.09.010
- 3 Gouvêa AF, Ribeiro ACP, León JE, Carlos R, de Almeida OP, Lopes MA. Head and neck amyloidosis: clinicopathological features and immunohistochemical analysis of 14 cases. *J Oral Pathol Med* 2012;41(02):178–185. DOI: 10.1111/j.1600-0714.2011.01073.x
- 4 Yakupova EI, Bobyleva LG, Vikhlyantsev IM, Bobylev AG. Congo Red and amyloids: history and relationship. *Biosci Rep* 2019;39(01):BSR20181415. DOI: 10.1042/BSR20181415
- 5 Biewend ML, Menke DM, Calamia KT. The spectrum of localized amyloidosis: a case series of 20 patients and review of the literature. *Amyloid* 2006;13(03):135–142. DOI: 10.1080/13506120600876773
- 6 Singh A, Handa KK, Kumar A. Idiopathic Isolated Nasal Amyloidosis: Report of a Rare Case with Review of Literature. *Indian J Otolaryngol Head Neck Surg* 2019;71(Suppl 3):2106–2109. DOI: 10.1007/s12070-018-1528-8
- 7 Yiotakis I, Georgolios A, Charalabopoulos A, et al. Primary localized laryngeal amyloidosis presenting with hoarseness and dysphagia: a case report. *J Med Case Reports* 2009;3:9049. DOI: 10.4076/1752-1947-3-9049
- 8 Rudy SF, Jeffery CC, Damrose EJ. Clinical characteristics of laryngeal versus nonlaryngeal amyloidosis. *Laryngoscope* 2018;128(03):670–674. DOI: 10.1002/lary.26846
- 9 Lewis JE, Olsen KD, Kurtin PJ, Kyle RA. Laryngeal amyloidosis: a clinicopathologic and immunohistochemical review. *Otolaryngol Head Neck Surg* 1992;106(04):372–377. DOI: 10.1177/019459989210600410
- 10 Thompson LD, Derringer GA, Wenig BM. Amyloidosis of the larynx: a clinicopathologic study of 11 cases. *Mod Pathol* 2000; 13(05):528–535. DOI: 10.1038/modpathol.3880092
- 11 Bartels H, Dikkers FG, van der Wal JE, Lokhorst HM, Hazenberg BPC. Laryngeal amyloidosis: localized versus systemic disease and update on diagnosis and therapy. *Ann Otol Rhinol Laryngol* 2004;113(09):741–748. DOI: 10.1177/000348940411300913
- 12 Hazenberg AJC, Hazenberg BPC, Dikkers FG. Long-term follow-up after surgery in localized laryngeal amyloidosis. *Eur Arch Otorhinolaryngol* 2016;273(09):2613–2620. DOI: 10.1007/s00405-016-4061-y
- 13 Serdar A, Basak D, Sercan G, Ali V. Solitary amyloid tumor of the tongue base. *Int J Otolaryngol* 2009;2009:515068. DOI: 10.1155/2009/515068
- 14 Send T, Spiegel JL, Schade G, et al. Amyloidosis of the Upper Aerodigestive Tract: Management of a Rare Disease and Review of

- the Literature. *Dysphagia* 2019;34(02):179–191. DOI: 10.1007/s00455-018-9956-x
- 15 Chin SC, Fatterpeckar G, Kao CH, Chen CY, Som PM. Amyloidosis concurrently involving the sinonasal cavities and larynx. *AJNR Am J Neuroradiol* 2004;25(04):636–638
- 16 Naidoo YS, Gupta R, Sacks R. A retrospective case review of isolated sinonasal amyloidosis. *J Laryngol Otol* 2012;126(06):633–637. DOI: 10.1017/S0022215112000503
- 17 Fahrner KS, Black CC, Gosselin BJ. Localized amyloidosis of the tongue: a review. *Am J Otolaryngol* 2004;25(03):186–189. DOI: 10.1016/j.amjoto.2004.01.007
- 18 Vaxman I, Gertz M. Recent Advances in the Diagnosis, Risk Stratification, and Management of Systemic Light-Chain Amyloidosis. *Acta Haematol* 2019;141(02):93–106. DOI: 10.1159/000495455
- 19 Deviprasad D, Pujary K, Balakrishnan R, Nayak DR. KTP Laser in Laryngeal Amyloidosis: Five Cases with Review of Literature. *Indian J Otolaryngol Head Neck Surg* 2013;65(Suppl 1):36–41. DOI: 10.1007/s12070-011-0435-z
- 20 Poovaneswaran S, Razak ARA, Lockman H, Bone M, Pollard K, Mazdai G. Tracheobronchial amyloidosis: utilization of radiotherapy as a treatment modality. *Medscape J Med* 2008;10(02):42
- 21 Neuner GA, Badros AA, Meyer TK, Nanaji NM, Regine WF. Complete resolution of laryngeal amyloidosis with radiation treatment. *Head Neck* 2012;34(05):748–752. DOI: 10.1002/hed.21626
- 22 Truong MT, Kachnic LA, Grillone GA, et al. Long-term results of conformal radiotherapy for progressive airway amyloidosis. *Int J Radiat Oncol Biol Phys* 2012;83(02):734–739. DOI: 10.1016/j.ijrobp.2011.07.036