



Received: 2015.03.22  
Accepted: 2015.04.13  
Published: 2015.06.28

**Authors' Contribution:**

- A** Study Design
- B** Data Collection
- C** Statistical Analysis
- D** Data Interpretation
- E** Manuscript Preparation
- F** Literature Search
- G** Funds Collection

## Hepatic Artery Pseudoaneurysm: Delayed Presentation after a Blunt Trauma

Abdussamet Batur<sup>A</sup>, Alpaslan Yavuz<sup>A</sup>, Osman Toktas<sup>B</sup>, Aydın Bora<sup>D</sup>, Mehmet Deniz Bulut<sup>D</sup>

Department of Radiology, Yuzuncuyil University Dursun Odabas Medical Center, Van Sehri, Turkey

**Author's address:** Abdussamet Batur, Department of Radiology, Yuzuncuyil University Dursun Odabas Medical Center, Van Sehri, Turkey, e-mail: baturabdussamet@gmail.com

Summary	
<b>Background:</b>	<p>Ruptured hepatic artery pseudoaneurysm is a rare condition that is life-threatening if not diagnosed and treated rapidly.</p> <p>We present a case of a spontaneously ruptured hepatic artery pseudoaneurysm that occurred after a blunt trauma, and provide a review of the current literature on this topic.</p> <p>This case study demonstrates a spontaneously ruptured hepatic artery pseudoaneurysm which emerged following a blunt trauma and it also presents current literature studies on the topic.</p>
<b>Case Report:</b>	<p>A man at the age of 34 years with blunt trauma dating back to 1.5 month was admitted to the emergency department of a hospital with hematemesis and epigastric tenderness. He also had a duodenal ulcer, blood in the gastric lumen and a large pseudoaneurysm that developed from the left hepatic artery. Soon after the diagnosis, the patient worsened and underwent distal gastrectomy and cholecystectomy that included removing the bleeding aneurysm.</p>
<b>Conclusions:</b>	<p>Ruptured hepatic artery pseudoaneurysm stands as a deadly condition which has to be diagnosed and managed as soon as possible. Physicians need to take aneurysms of abdominal arteries into consideration after routine diagnostic practises as long as the cause of gastrointestinal haemorrhage is unidentified.</p>
<b>MeSH Keywords:</b>	<b>Aneurysm, False • Gastrointestinal Hemorrhage • Hepatic Artery</b>
<b>PDF file:</b>	<a href="http://www.polradiol.com/abstract/index/idArt/894177">http://www.polradiol.com/abstract/index/idArt/894177</a>

### Background

Hepatic artery aneurysm (HAA) is a seldom condition and only 20 to 40% of all visceral artery aneurysms are reported to be HAA. Besides, 80% of this number are regarded as extrahepatic. These cases are generally asymptomatic, yet 30% of them end up with death and they can rupture as well [1,2]. These aneurysms carry a high risk of spontaneous rupture which results in an abdominal vascular catastrophe.

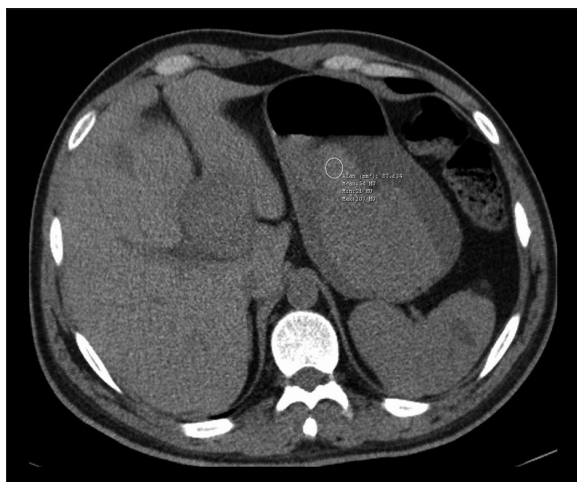The recorded death rates of any visceral artery aneurysms are predicted to fall between 25% and 70% [3]. Due to a high risk of death, in patients with a history of trauma with upper gastrointestinal bleeding it is important to take arterial aneurysm into consideration. In this study, a

34-year-old patient with a left hepatic artery pseudoaneurysm with gastrointestinal hemorrhage was presented.

### Case Report

A man, at the age of 34 years, with a 1.5-month history of a blunt trauma (apart from bilateral distal radius fractures, the patient did not show any other abnormalities on the day of the trauma) appeared to the emergency department with hematemesis and epigastric tenderness.

During the physical examination, no other abnormalities were observed. The vital signs observed during the examination were as follows: heart rate of 110 bpm, respiratory rate of 25 bpm, and blood pressure of 100/60 mmHg. Laboratory tests did not show any abnormal results either.



**Figure 1.** Unenhanced CT demonstrating blood in the gastric lumen with density of 54 HU.

A duodenal ulcer that was 3×3 cm in diameter in the duodenal bulb was detected in upper gastrointestinal endoscopy and the gastric lumen was full of blood. After endoscopic sclerotherapy, the case did not reveal any bleeding sites or sources.

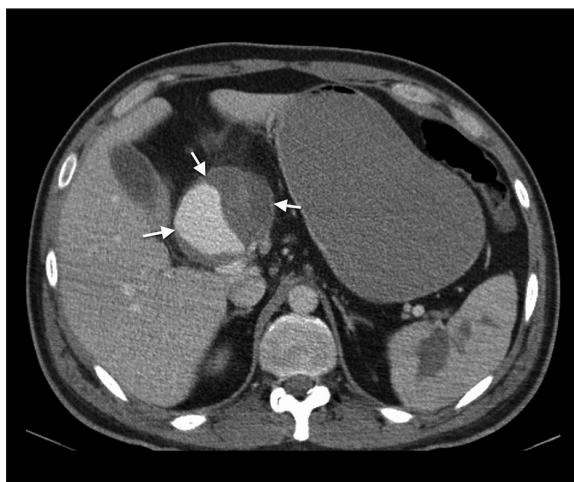
Due to recurrence of hematemesis, computed tomography was applied to search for any potential additional pathology. The gastric lumen was found to be full of blood (Figure 1) and a large pseudoaneurysm originating from the left hepatic artery was revealed with computed tomography (Figure 2). The patient worsened soon after the diagnosis and his hemoglobin value decreased from 11.4 to 8.7 mg/dL.

After the worsening of his condition, vital signs were as follows: heart rate of 140 beats/min, respiratory rate of 95 breaths/min, and blood pressure of 75/40 mmHg. He was taken for surgery and underwent distal gastrectomy and cholecystectomy that included removing the bleeding aneurysm of the left hepatic artery. He died of hypovolemia nine hours after being admitted to hospital.

## Discussion

Although hepatic artery pseudoaneurysm is a rarely seen condition, it may have serious results. Among all visceral arterial aneurysms, hepatic aneurysms (according to the literature) carry the highest risk of rupture, i.e. 44% [3]. The total death rate resulting from HAA is 35% [2] and HAAs remain the second most prevalent visceral artery aneurysms after splenic artery aneurysms. Nearly 20% of splanchnic aneurysms are HAAs. Only about 22% of these conditions are symptomatic, the presentation of gastrointestinal haemorrhage is extremely rare, just like in our case; these aneurysms generally include intraabdominal rupture and hypovolemic shock [4].

Since the clinical manifestations are not specific, the diagnosis of this condition is generally delayed. Patients with this condition generally complain of pain in the right upper quadrant and other presentations generally include haemoperitoneum, abdominal mass, jaundice and haemobilia [5].



**Figure 2.** Contrast-enhanced CT demonstrating an aneurysm arising from the left hepatic artery.

It can be seen after surgical injury, chronic damage, pancreatitis, cholecystitis or most commonly after a trauma [6].

According to the structure of the wall, it is possible to classify HAAs as true aneurysms or pseudoaneurysms [1]. They can be congenital or secondary to an acquired condition such as atherosclerosis or infection. Hepatic artery pseudoaneurysms are most of the times secondary to a penetrating trauma. HAA secondary to a blunt trauma, as in our case, presents rarely [5].

Due to its tendency to induce massive haemorrhages with minimal symptoms and signs, HAA is a potential deadly complication. In case of this study, two causes of upper gastrointestinal bleeding were combined: First a duodenal ulcer (managed by endoscopic sclerotherapy) and second – a pseudoaneurysm of the left hepatic artery, communicating with the gastrointestinal lumen.

Endoscopy is an advised method of examination in patients who show acute upper gastrointestinal bleeding. Since the bleeding site is not always accessible, it may not be the absolute diagnostic method to localize the site of bleeding but doing so is generally effective [1]. In order to monitor pain in the right upper quadrant, it is beneficial to use a Doppler ultrasound at early stages because this helps to diagnose a pseudoaneurysm [5]. Sometimes, bleeding may occur within a visceral organ and may not manifest with intraperitoneal free fluid. In these cases, ultrasound may not help in detecting aneurysm ruptures. The best way to diagnose this condition is angiography. However, development in CT and MR imaging allowed for accurate non-invasive diagnoses and precise delineation of the vascular anatomy in preparation for surgery [5].

## Conclusions

Physicians need to take aneurysms of abdominal arteries into consideration after routine diagnostic tests if the cause of gastrointestinal haemorrhage and bleeding in the upper gastrointestinal tract is unidentified. Deadly situations may occur due to delayed diagnosis and therefore CT needs to be performed as soon as possible.

---

**References:**

---

1. Nagaraja R, Govindasamy M, Varma V et al: Hepatic artery pseudoaneurysm: A single center experience. *Ann Vasc Surg*, 2013; 27: 743-49
2. Doğan R, Yıldırım E, Göktürk S: Gastrointestinal haemorrhage caused by rupture of a pseudoaneurysm of the hepatic artery. *Turk J Gastroenterol*, 2012; 23(2): 160-64
3. Reiter DA, Fischman AM, Shy BD: Hepatic artery pseudoaneurysm rupture: a case report and review of the literature. *J Emerg Med*, 2013; 44: 100-3
4. Narula HS, Kotru A, Nejim A: Hepatic artery aneurysm: an unusual cause for gastrointestinal haemorrhage. *Emerg Med J*, 2005; 22: 302
5. Gondolesi GE, Matsumoto C, Wayne M, Schwartz ME: Post-traumatic pseudoaneurysm of the common hepatic artery with duodenal fistula. *HPB* 2002; 4(4): 183-86
6. Kirschberg O, Scheduling A, Saers T, Krakamp B: Detection and treatment of an aneurysma spurium of the arteria hepatica dextra after laparoscopic cholecystectomy. *BMC Gastroenterology*, 2013; 13: 121