

Photodynamic Therapy for Malignant Brain Tumors

Jiro AKIMOTO¹

¹*Department of Neurosurgery, Tokyo Medical University, Shinjuku-ku, Tokyo*

Abstract

Photodynamic therapy (PDT) using talaporfin sodium together with a semiconductor laser was approved in Japan in October 2003 as a less invasive therapy for early-stage lung cancer. The author believes that the principle of PDT would be applicable for controlling the invading front of malignant brain tumors and verified its efficacy through experiments using glioma cell lines and glioma xenograft models. An investigator-initiated clinical study was jointly conducted with Tokyo Women's Medical University with the support of the Japan Medical Association. Patient enrollment was started in May 2009 and a total of 27 patients were enrolled by March 2012. Of 22 patients included in efficacy analysis, 13 patients with newly diagnosed glioblastoma showed progression-free survival of 12 months, progression-free survival at the site of laser irradiation of 20 months, 1-year survival of 100%, and overall survival of 24.8 months. In addition, the safety analysis of the 27 patients showed that adverse events directly related to PDT were mild. PDT was approved in Japan for health insurance coverage as a new intraoperative therapy with the indication for malignant brain tumors in September 2013. Currently, the post-marketing investigation in the accumulated patients has been conducted, and the preparation of guidelines, holding training courses, and dissemination of information on the safe implementation of PDT using web sites and videos, have been promoted. PDT is expected to be a breakthrough for the treatment of malignant glioma as a tumor cell-selective less invasive therapy for the infiltrated functional brain area.

Key words: photodynamic therapy, malignant brain tumor, photosensitizer, semiconductor laser, investigator-initiated clinical trial

Introduction

The current standard therapy for treating glioblastoma, typical of malignant brain tumors, is a combination of extended focal irradiation at 60 Gy plus chemotherapy with temozolomide (TMZ) following debulking surgery. The time to recurrence after this therapy was reported to be approximately 7 months, the 1-year survival rate at 61%, and the median survival time (MST) of 14.6 months,¹⁾ and it is one of the five worst malignancies.

The most significant pathological characteristic of glioblastoma is its infiltrative nature. Because of the coexistence of normal brain tissues and tumor cells at tumor brain interface, complete resection of infiltrating tumor cells means sacrificing normal brain tissues. Given that localized functions in the brain cannot be substituted by any other sites, tumor resection has to be relinquished to maintain the brain function if the tumor infiltrates the functional areas involved with language, motor functions, senses, vision, and memory. The tumor subsequently recurs,

expands, and results in the death of the patient. In fact, 80% of recurrent glioblastomas appear within a 2-cm periphery of the initial resection site,^{2,3)} and the control of the front of tumor infiltration is directly related to the prevention of recurrence. Nevertheless, antinomy of tumor debulking and preservation of nerve functions remain unsolved in the history of neurosurgery in the past 50 years.

What is Photodynamic Therapy?

Photodynamic therapy (PDT) uses the toxicity of singlet oxygen generated by a reaction between a highly safe photosensitizer specifically accumulated in tumor cells and light with a specific wavelength that excites the photosensitizer. Cancer research has shown that photochemical reactions damage tumor tissues by direct injury (necrosis and apoptosis) of tumor cells due to the toxicity of singlet oxygen, the occlusion of tumor vessels (thrombus formation by endothelial injury), and secondarily enhanced host immunity.^{4,5)} The life of singlet oxygen was reported to range between 0.04 μ s and 4 μ s and the distance of migration between 0.02 μ m and

1 μm , and therefore PDT is considered a less invasive therapy targeting each cell containing the photosensitizer alone while preserving the adjacent normal tissues (Fig. 1).

History of Application of PDT for Cancer Therapy

Many researchers considered that PDT would be a possible less invasive cancer therapy, and its application for cancer therapy was attempted as early as the beginning of the 1990s. After Dougherty⁶⁾ in Canada conducted PDT for the prevention of recurrence of bladder cancer in 1993, clinical studies targeting lung cancer, esophageal cancer, gastric cancer, and uterine cancer followed and PDT was approved in

Europe, the United States, and Japan as a therapy covered by health insurance based on its safety and efficacy. However, PDT did not become a globally acclaimed cancer therapy because of various issues such as poor selective accumulation of porphyrin sodium (Photofrin[®], Wyeth-Takeda, Tokyo; absorption wavelength: 630 nm), a photosensitizer used at that time for selective accumulation of tumor cells; necessity of a large (600 kg) and expensive dye laser system for excitation; and post-therapeutic light protection required for patients for 1 month or longer to prevent skin photosensitive reactions.

Talaporfin sodium (Laserphyrin[®], Meiji Seika Pharma Co., Ltd.; absorption wavelength: 664 nm), which was developed in Japan in 1992, is a high-quality photosensitizer that supplements the disadvantage of the

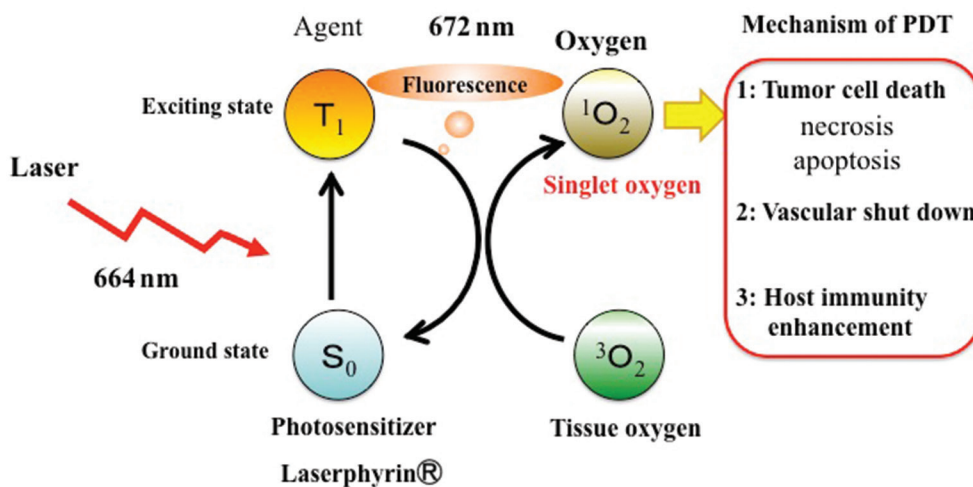


Fig. 1 Mechanism of photodynamic therapy.

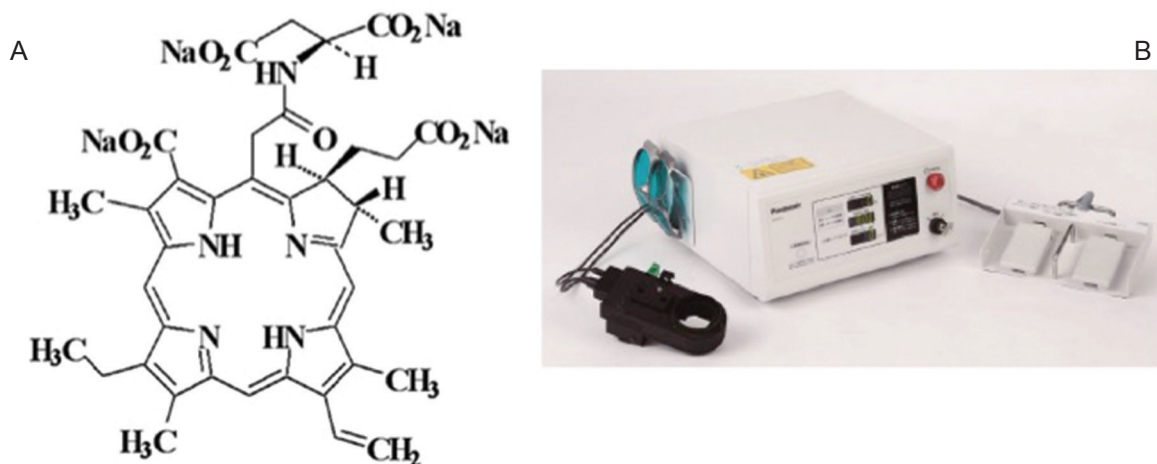


Fig. 2 A: Chemical structures of talaporfin sodium (Laserphyrin[®]; Meiji Seika Pharma Co., Ltd.), mono-L-asparthyl chlorine e6, C₃₈H₃₇N₅Na₄O₉, Molecular weight: 799.69. B: Semiconductor excitation laser (PD laser BT[®], Panasonic Healthcare). Size: 400 mm (W) × 393 mm (D) × 190 mm (H), weight: 13 kg.

preceding Photofrin® (Fig. 2A). It is highly selective against tumor cells, the semiconductor laser system for excitation is a compact A4 size (13 kg) (Fig. 2B), and light protection for about 1 week post dose is sufficient for skin photosensitive reactions. Soon after, a clinical study of PDT using Laserphyrin® in patients with early-stage lung cancer was conducted in Japan,⁷⁾ and favorable efficacy with the complete response rates (RRs) at 85% and at 95% was achieved while adverse events were very mild. Based on these results, PDT using Laserphyrin® for the treatment of early-stage lung cancer was approved in Japan for health insurance coverage in 2004.

History of PDT Research for Malignant Brain Tumors (Table 1)

Several neurosurgeons noticed the selective cytotoxicity of PDT against tumor cells and anticipated PDT to become a therapy targeting infiltrating malignant brain tumor cells. Following the report of a first-in-man study by Perria et al.⁸⁾ in Italy in 1980, treatment with PDT using Photofrin® was sought mainly by the researchers in the United States, Canada, Australia, United Kingdom, and Austria. Kaneko²⁷⁾ in Japan and Stylli et al.⁹⁾ in Melbourne conducted PDT using Photofrin® at 5 mg/kg in 145 patients with malignant glioma (61 patients with initial onset and 84 patients with recurrence) in 2005. With a combination of postoperative radiochemotherapy for all patients, an MST of 14.9 months was achieved for patients with newly diagnosed glioblastoma and 13.5 months for patients with recurrence. The 2-year survival rate and 5-year survival rate of patients with initial onset were 28% and 23%, respectively, and the patients who responded to PDT were recurrence-free for 5 years

or longer. Muller et al.¹⁰⁾ in Toronto conducted a randomized controlled trial (RCT) of Photofrin®-PDT in patients with malignant glioma in 2006 for the first time in the world. Postoperative radiotherapy was added for all patients consisting of 43 patients with PDT and 34 patients without PDT. The MST of the patients with initial-onset glioblastoma was 11 months in the PDT group and 8 months in the control group, but no statistically significant difference was observed. Stepp et al.¹¹⁾ in Munich used Gliolan® (medac GmbH; 5-ALA, absorption wavelength: 630 nm), which was approved as a photosensitizer for intraoperative photodynamic diagnosis (PDD). As for PDD laser at a wavelength of 635 nm and a light density of 200 J was irradiated into the brain parenchyma suspected to contain residual tumor tissues from the lumen where debulking was conducted. Although no significant difference in MST was observed between the PDT group and the control group, the 6-month progression-free period of 41% achieved by the PDT group was significantly higher than that of 21% achieved by the control group. Kostron et al.¹²⁾ in Innsbruck conducted PDT using Foscan® (m-Temoporfin, Biolitec Pharma Ltd.; absorption wavelength: 652 nm) for patients with recurrent glioblastoma and reported that the MST was 9 months in the PDT group and 3.5 months in the control group. Eljamel¹³⁾ in Dundee conducted Photofrin®-PDT for 27 patients with glioblastoma in 2010, and irradiated laser at a wavelength of 630 nm and a light density of 500 J into the entire circumferential surface of the resected lumen in five divided doses within 5 consecutive days. All patients received postoperative radiochemotherapy and the MST was 52.8 weeks in the PDT group and 24.2 weeks in the control group, showing a statistically significant difference.

Table 1 Summary of the history of photodynamic therapy for the treatment of malignant glioma

Author	No. of patients	GBM	AA	Photosensitizer	Dose	Light density	Median survival (months)	
							Overall	Primary
Perria et al. (1980)	8	2	4	HpD	5 mg/kg	720–2400 J	6.9	
Stylli et al. (2005)	145	78	67	HpD	5 mg/kg	70–240 J/cm ²		14.3
Muller and Wilson (2006)	96	43	24	HpD	2 mg/kg	58 ± 17		7.6
Kostron et al. (2006)	52	26		Temoporfin	0.15 mg/kg	20 J/cm ²		9
Eljamel (2010)	27	13		HpD	2 mg/kg	100 J/cm ²		13.2
Akimoto et al. (2012)	14	10	4	Talaporfin sodium	40 mg/m ²	27 J/cm ²		26
Muragaki et al. (2013)	22	13		Talaporfin sodium	40 mg/m ²	27 J/cm ²	27.9	24.8

AA: anaplastic astrocytoma, GBM: glioblastoma.

Some reports demonstrated the usefulness of adding PDT as an intraoperative adjuvant therapy, but the complexity associated with its implementation and with addressing adverse events, as well as the introduction of a potent chemotherapeutic agent, TMZ, in the same period prevented PDT from becoming an applied therapy, and consequently, PDT did not receive approval from the regulatory authorities.

PDT for Malignant Brain Tumors Using Laserphyrin®

Based on the belief that the efficacy and safety of PDT for malignant brain tumors would be established when it is coupled with talaporfin sodium (Laserphyrin®), I started the preclinical study of PDT using this photosensitizer in 2000. First, selective accumulation of Laserphyrin® in malignant glioma cells and tissues was confirmed by *in vitro* and *in vivo* studies, and PDT was verified to induce apoptosis and necrosis of tumor cells and tissues.^{14–22)} A clinical study of PDT using Laserphyrin® (provided by Meiji Seika Pharma Co., Ltd.) for malignant brain tumors was planned based on the above result, and it was approved by the Ethics Committee of Tokyo Medical University. Prior to the use of the semiconductor laser (PD laser®, provided by Panasonic Healthcare), which has been approved as a PDT device for early-stage lung cancer, as intraoperative PDT for malignant brain tumors, the irradiation method was examined. Most of the overseas methods for clinical application above employed implantation of a fiber attached with a laser diffusion balloon into the cavity after brain tumor resection for irradiation to the entire circumferential surface of the post-resection cavity. We employed a method for emitting the light of the PD laser® through a

quartz fiber inside the lens barrel of the operation microscope to mark an accurate irradiation target, and conducted circumferential surface irradiation of 15 mm in diameter.^{23–25)} This method enabled accurate irradiation to any given targets (Fig. 3A–C).

Laserphyrin® was administered for the first time on February 9, 2005 in a patient with recurrent glioblastoma of the frontal lobe. The dose of Laserphyrin® was 40 mg/m², which was approved for early-stage lung cancer, and PDT was scheduled between 22 hours and 26 hours post-dose. PDT for early-stage lung cancer is to be conducted at 4 hours post-dose, but the timing of PDT was determined in reference to the data of basic experiments¹⁵⁾ that the best result of selective accumulation in the brain tumor tissues would be achieved at 12 hours post-dose or later.

I first examined whether selective accumulation of Laserphyrin® would be evaluable as the photosensitizer for PDD. The irradiation power at 150 mW/cm², which was confirmed safe for early-stage lung cancer, was to be employed for PDT. Therefore, low irradiation power at 10 mW/cm² was used for PDD, which was unlikely to induce a significant PDT reaction. Experience obtained from 10 patients confirmed that this method would allow extended tumor resection under intraoperative PDD.²⁴⁾

PDT was conducted for the first time in May 29, 2006 in a patient with primary glioblastoma which developed at the left insular gyrus. Debulking under PDD was then conducted in six patients with primary malignant glioma and eight patients with recurrence, and 3-minute PDT (continuous wave, irradiation power at 150 mW/cm², light density at 27 J/cm²) was conducted at a couple of sites where progression to the functional fields or to the contralateral progression via the corpus callosum was confirmed

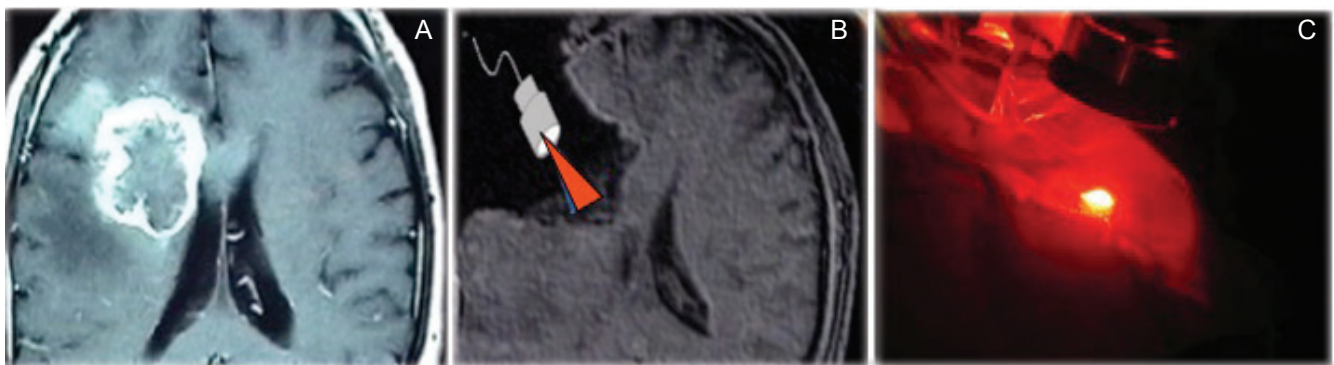


Fig. 3 PDT images. A: Contrast MRI image of malignant glioma localized in the right deep frontal lobe and infiltrated to the pyramidal tract. B: Laser irradiation to the surface of tumor cells infiltrating the pyramidal tract following debulking of the tumor. C: Laser beam of 1.5 cm in diameter is accurately emitted to the target from the lens barrel of the operation microscope. MRI: magnetic resonance imaging, PDT: photodynamic therapy.

by navigation and physiological monitoring. The RR of 83.3% and the median progression-free survival (m-PFS) time of 23 months in six patients who were newly diagnosed were very favorable, but the RR was 25%, the m-PFS was 3 months, and the MST was 9 months in patients with recurrence, and the significance of adding PDT was not shown. No notable adverse events were observed and light protection for 4 days post-dose was sufficient²³⁾ (Figs. 4, 5A–C).

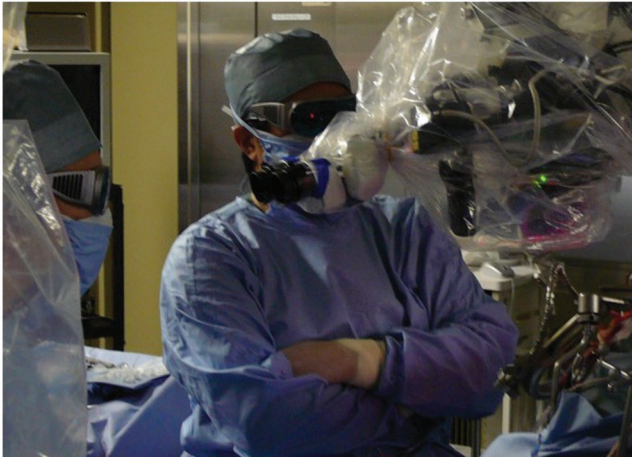


Fig. 4 Actual intraoperative photodynamic therapy procedures. Both the surgeon and the assistants wore protective eyewear before emitting a laser beam from the operation microscope to the target surface.

The First Complex, Investigator-initiated Clinical Study in Japan and Acquiring Approval by Health Insurance

The results of the above clinical studies showed PDT to be a feasible intraoperative local therapy showing efficacy and safety at least for newly diagnosed malignant glioma. When such favorable result is achieved by an interventional clinical study, a company-initiated clinical study is usually planned for obtaining approval for health insurance coverage. However, as this is a complex therapy requiring both a photosensitizer (a pharmaceutical) and a semiconductor laser (a medical device), and uses a device associated with a risk of Class III B level, neither a pharmaceutical nor a medical device company was incentivized to initiate a clinical study. Therefore, Tokyo Medical University and Tokyo Women's Medical University jointly conducted an investigator-initiated clinical study, which was established in July 2005. The drug and the medical device were supplied by respective companies and the fund and insurance for a clinical study were supported by the Center for Clinical Trials of the Japan Medical Association. The investigator surgeon was fixed at the two study sites because of the nature of the investigator-initiated study, and the protocol was determined based on sufficient discussion. The study was evaluated as appropriate by the Data and Safety Monitoring Board consisting of physicians having good understanding of the pathology of malignant brain tumors and PDT.²⁶⁾

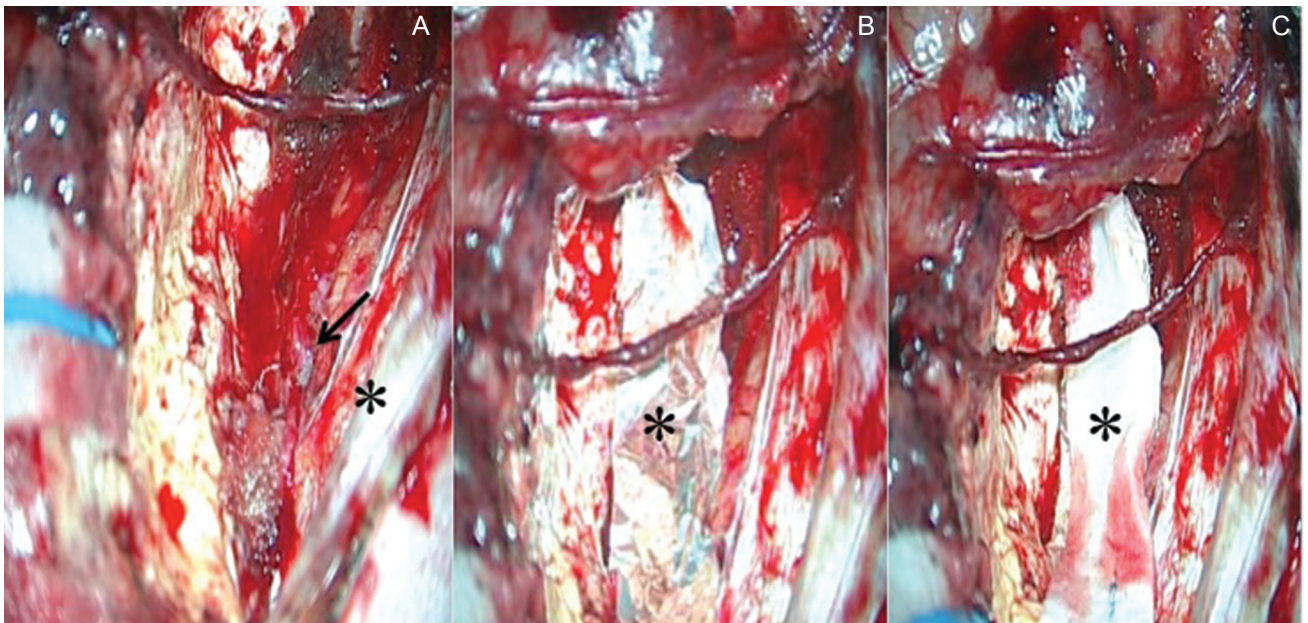


Fig. 5 Microscopic field of view during photodynamic therapy irradiation. A: Setting the irradiation targets (*asterisk*: falx, *arrow*: anterior cerebral artery). B: Anterior cerebral arteries were protected with a sterilized aluminum foil (*asterisk*). C: The aluminum foil was covered with surgical cotton (*asterisk*) avoiding the scattering effect of laser light.

Eligible subjects were patients of 20–69 years of age suspected of supratentorial glioma of performance status 0 to 2 or the World Health Organization (WHO) grade III to IV. Subject enrollment started in the middle of 2009 and continued for 2 years and the primary efficacy endpoint was the overall survival (OS) of 1 year after PDT. The safety endpoint was the incidence of adverse events including skin photosensitivity. All the enrolled 27 patients who received a photosensitizer were included in the safety analysis, but only 22 patients were included in the efficacy analysis of PDT for reasons such as exclusion by intraoperative pathological examination or by time overrun after administration of the photosensitizer. As a result of the central pathological assessment, 13 patients with newly diagnosed glioblastoma were included in the efficacy analysis. They consisted of six males and seven females with a median age of 49 years. Glioma infiltrated the functional area in seven patients, the adjacent area in two patients, and the non-functional area in four patients. The preoperative PS was 0 in three patients, 1 in eight patients, and 3 in two patients. PDT (1 to 2 sites) was conducted after total resection in five patients and after subtotal resection in the remaining eight patients. The 1-year OS, the primary efficacy endpoint, was 100%, the 2-year OS was 50%, and the MST was 24.8 months, showing favorable results. With respect to safety, Grade 3 hepatic function disorder was observed in 5 of 27 patients, but the symptom was improved early by the administration of a liver protection drug. Skin photosensitivity reactions disappeared in 78% of the patients on Day 8 post-dose and in all of them on Day 15 post-dose.²⁶⁾

An application for approval of national health insurance (NHI) coverage was submitted at the end of 2012 based on the verification of efficacy and safety of PDT for malignant glioma in this study, and approval was obtained on September 20, 2013. Since primary malignant brain tumor is an intractable rare cancer, approval would be obtained even for the investigator-initiated, single-phase, phase II exploratory study like this trial as long as considerable efficacy is demonstrated and safety is ensured.²⁶⁾

Summary

PDT for primary malignant brain tumors was approved by the Japanese government for the first time in the world, and each of the findings is noteworthy in the history or research of such tumors. With its listing on the NHI drug reimbursement price list in January 2014, PDT has been indicated for all primary malignant brain tumors in Japan. Therefore, the guidelines for the selection of eligible patients,

safe administration of photosensitizers, patient management, actions for adverse events, and efficacy evaluation²⁷⁾ have been prepared, and the system has been established where only physicians who have completed the required education and training, i.e., workshops and training courses held multiple times for appropriate management and safe implementation of semiconductor lasers, medical devices with a risk, are permitted to conduct PDT. Seeking further evidence, a multicenter joint comparative study (phase III study) is planned with the support of the Japanese Congress for Brain Tumor Surgery. This device was domestically developed with the support of the Cabinet and the Ministry of Economy, Trade and Industry, and became the first Japanese device to have passed the standards of the International Electrotechnical Commission. I hope to make this therapy one of the global standard therapies for malignant brain tumors, and I will continue further research to contribute to global health.

Acknowledgments

The author expresses his deep appreciation to Professor Hiroshi Iseki, Professor Yoshihiro Muragaki, Professor Takashi Maruyama, and Dr. Soko Ikuta of the Institute of Advanced Biomedical Engineering and Science, Tokyo Women's Medical University, for their considerable support and cooperation in the establishment of PDT, and Dr. Sadao Kaneko, the pioneer researcher of PDT for brain tumors in Japan and the director of Kashiwaba Neurosurgical Hospital. This study was conducted with Grants-in-Aid from the Ministry of Health, Labor, and Welfare, and from the Ministry of Education, Culture, Sports, Science, and Technology.

Conflicts of Interest Disclosure

The author declares that he has no conflicts of interest.

References

- 1) Stupp R, Mason WP, van den Bent MJ, Weller M, Fisher B, Taphoorn MJ, Belanger K, Brandes AA, Marosi C, Bogdahn U, Curschmann J, Janzer RC, Ludwin SK, Gorlia T, Allgeier A, Lacombe D, Cairncross JG, Eisenhauer E, Mirimanoff RO; European Organisation for Research and Treatment of Cancer Brain Tumor and Radiotherapy Groups; National Cancer Institute of Canada Clinical Trials Group: Radiotherapy plus concomitant and adjuvant temozolomide for glioblastoma. *N Eng J Med* 352: 987–996, 2005
- 2) Wilson CB: Glioblastoma: the past, the present, and the future. *Clin Neurosurg* 38: 32–48, 1992

- 3) Gasper LE, Fisher BJ, Macdonald DR, LeBer DV, Halperin EC, Schold SC Jr, Cairncross JG: Supratentorial malignant glioma: patterns of recurrence and implications for external beam local treatment. *Int J Radiat Oncol Biol Phys* 24: 55–57, 1992
- 4) Castano AP, Demidova TN, Hamblin MR: Mechanisms in photodynamic therapy: part one-photosensitizers, photochemistry and cellular localization. *Photodiagnosis Photodyn Ther* 1: 279–293, 2004
- 5) Castano AP, Demidova TN, Hamblin MR: Mechanisms in photodynamic therapy: part two-cellular signaling, cell metabolism and modes of cell death. *Photodiagnosis Photodyn Ther* 2: 1–23, 2005
- 6) Dougherty TJ: Photodynamic therapy. *Photochem Photobiol* 58: 895–900, 1993
- 7) Kato H, Furukawa K, Sato M, Okunaka T, Kusunoki Y, Kawahara M, Fukuoka M, Miyazawa T, Yana T, Matsui K, Shiraishi T, Horinouchi H: Phase II clinical study of photodynamic therapy using mono-L-aspartyl chlorin e6 and diode laser for early superficial squamous cell carcinoma of the lung. *Lung Cancer* 42: 103–111, 2003
- 8) Perria C, Capuzzo T, Cavagnaro G, Datti R, Francaviglia N, Rivano C, Tercero VE: Fast attempts at the photodynamic treatment of human gliomas. *J Neurosurg Sci* 24: 119–129, 1980
- 9) Stylli SS, Kaye AH, MacGregor L, Howes M, Rajendra P: Photodynamic therapy of high grade glioma—long term survival. *J Clin Neurosci* 12: 389–398, 2005
- 10) Muller PJ, Wilson BC: Photodynamic therapy of brain tumor—a work in progress. *Laser Surg Med* 38: 384–389, 2006
- 11) Stepp H, Beck T, Pongraz T, Meinel T, Kreth FW, Tonn JCh, Stummer W: ALA and malignant glioma: Fluorescence-guided resection and photodynamic treatment. *J Environ Pathol Toxicol Oncol* 21: 157–164, 2007
- 12) Kostron H, Fiegele T, Akatuna E: Combination of FOSCAN® mediated fluorescence guided resection and photodynamic treatment as a new concept for malignant brain tumors. *Medical Laser Application* 21: 185–290, 2006
- 13) Eljamel S: Photodynamic applications in brain tumors: a comprehensive review of the literature. *Photodiagnosis Photodyn Ther* 7: 76–85, 2010
- 14) Matsumura H, Akimoto J, Haraoka J, Aizawa K: Uptake and retention of the photosensitizer mono-L-asparthyl chlorine e6 in experimental malignant glioma. *Lasers Med Sci* 23: 237–245, 2008
- 15) Tsurubuchi T, Zoboronok A, Yamamoto T, Nakai K, Yoshida F, Shirakawa M, Matsuda M, Matsumura A: The optimization of fluorescence imaging of brain tumor tissue differentiated from brain edema—in vivo kinetic study of 5-aminolevulinic acid and talaporfin sodium. *Photodiagnosis Photodyn Ther* 6: 19–27, 2009
- 16) Tsutsumi M, Miki Y, Akimoto J, Haraoka J, Aizawa K, Hirano K, Beppu M: Photodynamic therapy with talaporfin sodium induces dose-dependent apoptotic cell death in human glioma cell lines. *Photodiagnosis Photodyn Ther* 10: 103–110, 2013
- 17) Miki Y, Akimoto J, Yokoyama S, Homma T, Tsutsumi M, Haraoka J, Hirano K, Beppu M: Photodynamic therapy in combination with talaporfin sodium induces mitochondrial apoptotic cell death accompanied with necrosis in glioma cells. *Biol Pharm Bull* 36: 215–221, 2013
- 18) Miki Y, Akimoto J, Moritake K, Hironaka C, Fujiwara Y: Photodynamic therapy using talaporfin sodium induces concentration-dependent programmed necroptosis in human glioblastoma T98G cells. *Lasers Med Sci* 30: 1739–1745, 2015
- 19) Miki Y, Akimoto J, Omata H, Moritake K, Hiranuma M, Hironaka C, Fujiwara Y, Beppu M: Concomitant treatment with temozolomide enhances apoptotic cell death in glioma cells induced by photodynamic therapy with talaporfin sodium. *Photodiagnosis Photodyn Ther* 11: 556–564, 2014
- 20) Miki Y, Akimoto J, Hiranuma M, Fujiwara Y: Effect of talaporfin sodium-mediated photodynamic therapy on cell death modalities in human glioblastoma T98G cells. *J Toxicol Sci* 39: 821–827, 2014
- 21) Miki Y, Akimoto J, Sato A, Fujiwara Y: Evaluation of laser irradiance on photodynamic therapy using talaporfin sodium-induced glioblastoma T98 cell death. *Fundamental Toxicol Sci* 2: 111–116, 2015
- 22) Namatame H, Akimoto J, Matsumura H, Haraoka J, Aizawa K: Photodynamic therapy of C6-implanted glioma cells in the rat brain employing second-generation photosensitizer talaporfin sodium. *Photodiagnosis Photodyn Ther* 5: 198–209, 2008
- 23) Akimoto J, Haraoka J, Aizawa K: Preliminary clinical report on safety and efficacy of photodynamic therapy using talaporfin sodium for malignant gliomas. *Photodiagnosis Photodyn Ther* 9: 91–99, 2012
- 24) Akimoto J, Aizawa K: Intraoperative photodynamic diagnosis and therapy for malignant glioma using second-generation photosensitizer talaporfin sodium. *Laser Therapy* 19: 208, 2010
- 25) Akimoto J: Photodynamic therapy using talaporfin sodium and diode laser for newly diagnosed malignant gliomas, in Lichtor T (ed): *Clinical Management and Evolving Novel Therapeutic Strategies for Patients with Brain Tumors*. Croatia, InTech, 2013, 263–274
- 26) Muragaki Y, Akimoto J, Maruyama T, Iseki H, Ikuta S, Nitta M, Maebayashi K, Saito T, Okada Y, Kaneko S, Matsumura A, Kuroiwa T, Karasawa K, Nakazato Y, Kayama T: Phase II clinical study on intraoperative photodynamic therapy with talaporfin sodium and semiconductor laser in patients with malignant brain tumors. *J Neurosurg* 119: 845–852, 2013
- 27) Kaneko S: Safety guidelines for diagnostic and therapeutic laser applications in the neurosurgical field. *Laser Ther* 21: 129–136, 2012

Address reprint requests to: Jiro Akimoto, MD, DMSci, Department of Neurosurgery, Tokyo Medical University, 6-7-1 Nishishinjuku, Shinjuku-ku, Tokyo 160-0023, Japan.
e-mail: jiroaki@gmail.com