



## Case report

## Advanced Coats' disease treated with intravitreal brolocizumab combined with laser photocoagulation

Nimesh A. Patel<sup>a</sup>, Audina M. Berrocal<sup>a</sup>, Timothy G. Murray<sup>b</sup>, Victor M. Villegas<sup>a,c,\*</sup><sup>a</sup> Department of Ophthalmology, Bascom Palmer Eye Institute, Miller School of Medicine, University of Miami, 900 NW 17th Avenue, Miami, FL, 33136, USA<sup>b</sup> Murray Ocular Oncology and Retina, 6705 SW 57th Ave, Miami, FL, 33143, USA<sup>c</sup> Department of Ophthalmology, University of Puerto Rico, San Juan, PR, 00921, USA

## ARTICLE INFO

## Keywords:

Coats' disease  
 Brolocizumab  
 Anti-VEGF  
 Intravitreal  
 Edema  
 Pediatrics  
 Exudative retinopathy

## ABSTRACT

**Purpose:** To report the first use the intravitreal anti-VEGF brolocizumab for the treatment of macular exudates and edema in a patient with Coats' disease.

**Observations:** A 9-year-old boy was referred with a decrease in vision in the right eye. Visual acuity was 20/400 OD on presentation, and examination was remarkable for peripheral telangiectasias, exudates, microaneurysms, macular edema, and an inferior exudative retinal detachment. A diagnosis of Stage 3A2 Coats' disease was made, and the patient was treated with intravitreal bevacizumab as well as peripheral diode laser. However, on follow up, there was persistence of subretinal fluid accompanied by a decrease in visual acuity. The patient was then treated with intravitreal brolocizumab. Post injection visual and anatomical improvements were significant with complete resolution of macular edema within two weeks. Throughout the 5 months of follow up, there has been no re-accumulation of fluid and no further required therapy.

**Conclusions and Importance:** Intravitreal brolocizumab was effective for the treatment of retinal edema and exudates in Coats' disease.

## 1. Introduction

Coats' disease, first described in 1908,<sup>1</sup> is characterized by peripheral vascular ectasia, aneurysms, and exudation.<sup>2</sup> Historically, the main treatment included repetitive laser photocoagulation to areas of non-perfusion and telangiectasias.<sup>3</sup> Recent studies have demonstrated upregulation of VEGF in patients with Coats' disease,<sup>4</sup> and this has prompted interest in intravitreal anti-vascular endothelial growth factor (anti-VEGF) therapy as an adjuvant to laser photocoagulation.<sup>5,6</sup> Multiple reports have shown safety and efficacy of intravitreal bevacizumab, ranibizumab, conbercept, and aflibercept in combination with ablative therapies.<sup>7,8</sup>

Brolocizumab is the most recently U.S. Food and Drug Administration (FDA) approved anti-VEGF agent for intraocular use. Brolocizumab inhibits all isoforms of VEGF A with a human single chain antibody fragment scaffold. It is the smallest available anti-VEGF molecule, allowing for an increase in molar concentration, and consequently, a potential for an improved effect duration.<sup>9,10</sup> Similar to other anti-VEGF agents, it may provide therapeutic benefits in patients with Coats' disease.

In this case, we report the first use of intravitreal brolocizumab combined with laser photocoagulation in a pediatric patient for the treatment of advanced recalcitrant Stage 3A2 Coats' disease with complete and maintained resolution of subretinal fluid after a single treatment.

## 1.1. Case

A 9-year-old male, without systemic disease, was referred to our clinic due to painless visual loss in the right eye (OD) of 4 months duration. Best-corrected visual acuity was 20/400 OD and 20/20 left eye (OS). Intraocular pressures were 14 in both eyes (OU). A complete ophthalmologic exam was performed. Anterior segment examination was unremarkable OU. Pupils were equally round and equally reactive to light without evidence of afferent pupillary defect. No evidence of vitreous cells was present OU. Fundusoscopic examination OD was remarkable for peripheral telangiectasias, exudates, microaneurysms, macular edema, and an inferior exudative retinal detachment (Fig. 1). Fundusoscopic examination OS was remarkable for avascular peripheral retina. Optical coherence tomography OD demonstrated intraretinal

\* Corresponding author. Bascom Palmer Eye Institute 900 NW 17th Avenue, Miami, FL, 33136, USA.

E-mail address: [v.villegas@med.miami.edu](mailto:v.villegas@med.miami.edu) (V.M. Villegas).

<https://doi.org/10.1016/j.ajoc.2020.100815>

Received 6 May 2020; Received in revised form 11 June 2020; Accepted 16 June 2020

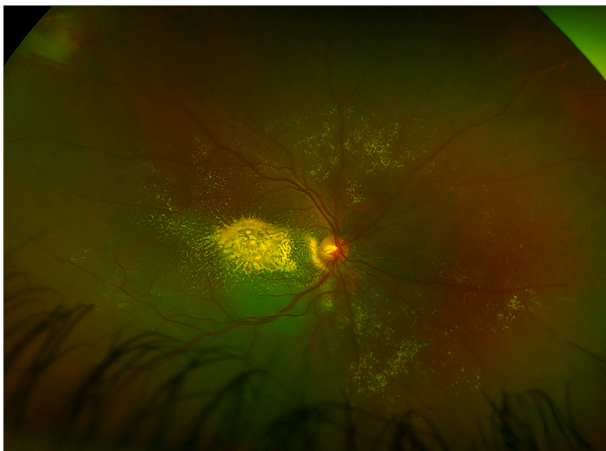
Available online 2 July 2020

2451-9936/© 2020 The Authors.

Published by Elsevier Inc.

This is an open access article under the CC BY-NC-ND license

(<http://creativecommons.org/licenses/by-nc-nd/4.0/>).



**Fig. 1.** Fundus photo of the right eye demonstrating dense sub-retinal exudates concentrated in the macula.

hard exudates, intraretinal fluid, and an exudative retinal detachment (Fig. 2). A diagnosis of Stage 3A2 Coats' disease was made.

Four weeks after initial presentation the patient underwent examination under anesthesia with diode laser ablation of all telangiectasias and intravitreal bevacizumab (2.5mg/0.1mL) therapy. Reevaluation in the clinic 1 month after initial therapy showed persistent subretinal fluid and decrease in visual acuity to counting fingers at 1 feet OD.

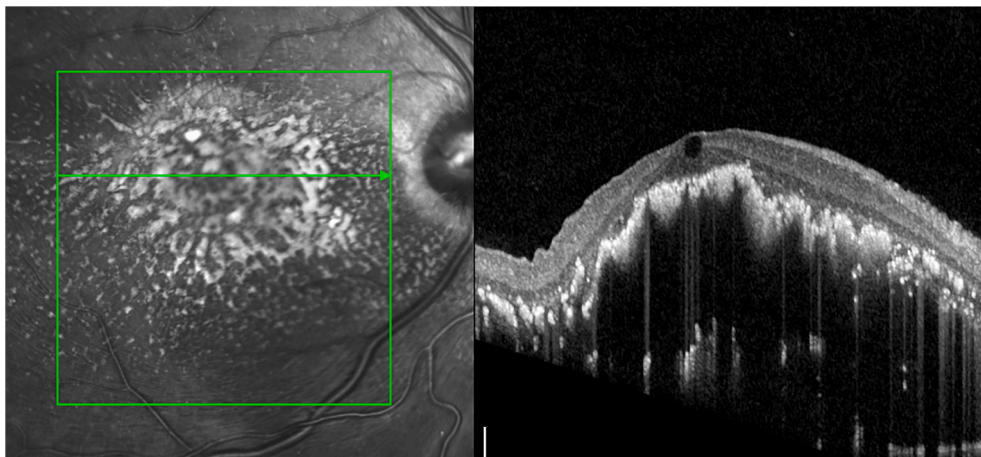
Due to decrease in visual acuity, the patient was then taken to the

operating room and additional laser was applied to skip areas. Concomitant intravitreal injection of brolucizumab (6mg/0.05mL) was undertaken. Two weeks after therapy the patient had complete resolution of sub-foveal fluid (Fig. 3) and visual acuity improvement to 20/200. Most recently, the patient has remained with stable visual acuity and without subretinal fluid re-accumulation or vascular leakage for 21 weeks (Fig. 4), avoiding the need for further therapy.

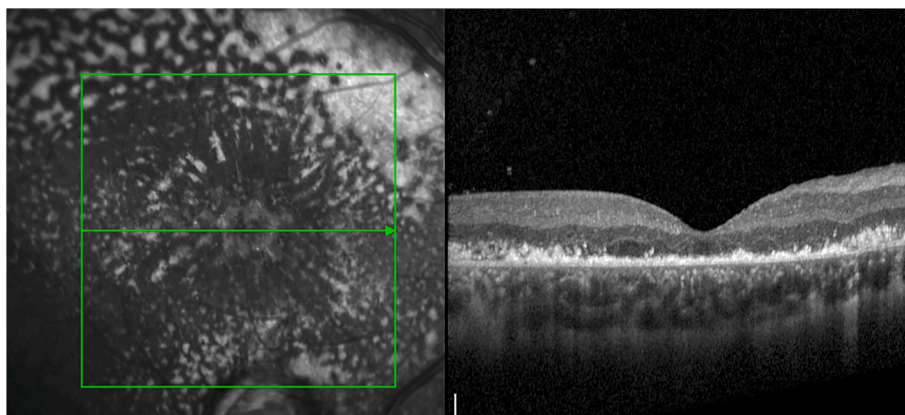
## 2. Discussion

Historically, eyes with Coats' disease have carried a poor visual and anatomical prognosis. Some authors reported enucleation in over 10% of cases.<sup>11</sup> However, the availability of intraoperative pediatric fluorescein angiography, indirect laser photocoagulation and anti-VEGF intravitreal injection has drastically changed the outcomes associated with this condition. This has created a shift in goals from globe preservation to visual function. Although there continues to be no FDA-approved pharmacologic treatment for Coats' disease, publications have demonstrated subretinal fluid reduction after intravitreal anti-VEGF.<sup>12</sup> Initial treatment in this case was performed with intravitreal bevacizumab in combination with peripheral vascular ablation. However, due to recalcitrant subretinal fluid and decrease in visual acuity an alternate anti-VEGF agent was delivered.

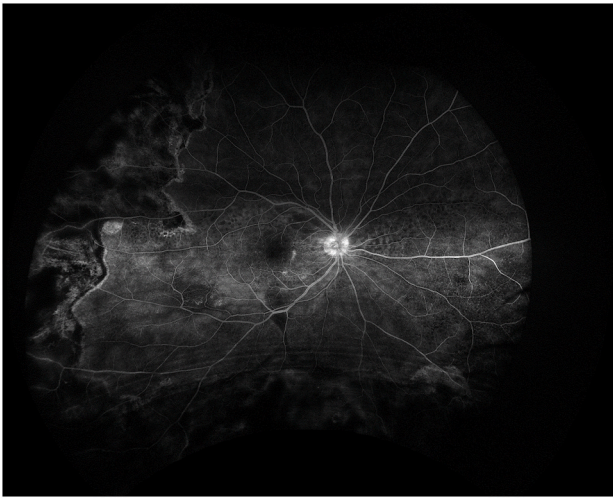
Brolucizumab is the newest-in-class anti-VEGF agent for neovascular age related macular degeneration. Two pivotal phase 3 trials, HAWK and HARRIER, demonstrated non-inferiority of intravitreal brolucizumab compared to aflibercept at 8 weeks post therapy with 50% of patients maintaining the visual and anatomical outcomes at 12 weeks<sup>9</sup> In this



**Fig. 2.** Optical coherence tomography with intraretinal hard exudates, intraretinal fluid, and an exudative retinal detachment.



**Fig. 3.** Optical coherence tomography two weeks post intravitreal injection with brolucizumab showing complete resolution of sub-foveal fluid.



**Fig. 4.** Late phase fluorescein angiography 21 weeks after intravitreal brolucizumab shows complete resolution of vascular leakage and macular edema.

case, there was a dramatic response to brolucizumab with complete resolution of the subretinal exudates within two weeks. Although it is possible that the initial bevacizumab treatment had some marginal additive effects, the acute improvement in visual acuity and decrease in subretinal fluid suggests greater efficacy of brolucizumab. In addition, the exudation associated with Coats' disease frequently recurs after anti-VEGF.<sup>12</sup> However, in this instance, there has been no recurrence thus far with over 21 weeks of follow up. It is possible that brolucizumab may have superior therapeutic effects for Coats' disease. Recent reports have noted intraocular inflammation and occlusive vasculitis in approximately 1 in 1000 injections and was included within the FDA evaluation of brolucizumab during HAWK and HARRIER.<sup>17</sup> These potential adverse events have focused our informed consent and targeted our use of brolucizumab to patients who have failed existing anti-VEGF treatments.

Post-enucleation histologic specimens have demonstrated subretinal and intraretinal lipid laden macrophages as well as giant cell reactions surrounding the cholesterol crystals.<sup>13,14</sup> This suggests that Coats' disease has an association with the inflammatory cascade. Interest in modulating this response has prompted multiple authors to perform intravitreal and sub-Tenon triamcinolone acetate with positive visual and anatomical outcomes.<sup>12,15,16</sup> Fortunately, in this case, there were no signs of intraocular inflammation or vasculitis noted post treatment. Further studies and data are required to assess the safety and efficacy of this medication in the pediatric population, and, for Coats' disease.

Several limitations are present in this case including the precise understanding of the effects of intravitreal brolucizumab in the final outcome. Since the treatment of Coats' disease is complex often requiring repetitive multimodal therapies, some additive effects may have been present. In this case, the acute resolution of subretinal fluid and improvement in vision suggests a positive effect from intravitreal brolucizumab. Future prospective studies comparing multiple anti-VEGF agents combined with laser photocoagulation for Coats' disease are needed.

### 3. Conclusion

This case demonstrates the first use of intravitreal brolucizumab in combination with laser photocoagulation for the treatment of Coats' disease. A favorable response was achieved with a single treatment with

complete resolution of subretinal fluid and exudation.

### Patient consent

Consent was obtained from the patient before the study and publication of the case report.

### Funding

No funding or grant support

### Declaration of competing interest

The authors declare that they have no known competing financial interests or personal relationships that could have appeared to influence the work reported in this paper.

### Acknowledgements

The authors want to acknowledge the work of Miss. Lizeiry Rivera and Miss. Ellen Hernandez for the photographic contributions.

### References

1. Coats G. Forms of retinal dysplasia with massive exudation. *Roy Lond Ophthalmol Hosp.* 1908;17:440–525.
2. Shields CL, Udyaver S, Dalvin LA, et al. Coats disease in 351 eyes: analysis of features and outcomes over 45 years (by decade) at a single center. *Indian J Ophthalmol.* 2019;67(6):772–783.
3. Scheffler AC, Berrocal AM, Murray TG. Advanced Coats' disease. Management with repetitive aggressive laser ablation therapy. *Retina.* 2008;28(3 Suppl):S38–S41.
4. He YG, Wang H, Zhao B, Lee J, Bahl D, McCluskey J. Elevated vascular endothelial growth factor level in Coats' disease and possible therapeutic role of bevacizumab. *Graefes Arch Clin Exp Ophthalmol.* 2010;248(10):1519–1521.
5. Zheng XX, Jiang YR. The effect of intravitreal bevacizumab injection as the initial treatment for Coats' disease. *Graefes Arch Clin Exp Ophthalmol.* 2014;252(1):35–42.
6. Villegas VM, Gold AS, Berrocal AM, Murray TG. Advanced Coats' disease treated with intravitreal bevacizumab combined with laser vascular ablation. *Clin Ophthalmol.* 2014;8:973–976.
7. Zhang L, Ke Y, Wang W, Shi X, Hei K, Li X. The efficacy of conbercept or ranibizumab intravitreal injection combined with laser therapy for Coats' disease. *Graefes Arch Clin Exp Ophthalmol.* 2018;256(7):1339–1346.
8. Shieh WS, Shah GK, Blinder KJ. Coats' disease-related macular edema treated with combined aflibercept and laser photocoagulation. *Case Rep Ophthalmol Med.* 2017;2017:2824874.
9. Dugel PU, Koh A, Ogura Y, et al. HAWK and HARRIER: phase 3, multicenter, randomized, double-masked trials of brolucizumab for neovascular age-related macular degeneration. *Ophthalmology.* 2020;127(1):72–84.
10. Dugel PU, Jaffe GJ, Sallstig P, et al. Brolucizumab versus aflibercept in participants with neovascular age-related macular degeneration: a randomized trial. *Ophthalmology.* 2017;124(9):1296–1304.
11. Shields JA, Shields CL, Honavar SG, Demirci H, Cater J. Classification and management of coats disease: the 2000 proctor lecture. *Am J Ophthalmol.* 2001;131(5):572–583.
12. Grosso A, Pellegrini M, Cereda MG, Panico C, Staurengi G, Sigler EJ. Pearls and pitfalls in diagnosis and management of coats disease. *Retina.* 2015;35(4):614–623.
13. Tripathi R, Ashton N. Electron microscopic study of Coats' disease. *Br J Ophthalmol.* 1971;55(5):289–301.
14. Fernandes BF, Odashiro AN, Maloney S, Zajdenweber ME, Lopes AG, Burnier Jr MN. Clinical-histopathological correlation in a case of Coats' disease. *Diagn Pathol.* 2006;1:24.
15. Sein J, Tzu JH, Murray TG, Berrocal AM. Treatment of coats' disease with combination therapy of intravitreal bevacizumab, laser photocoagulation, and sub-tenon corticosteroids. *Ophthalmic Surg Lasers Imaging Retina.* 2016;47(5):443–449.
16. Othman IS, Moussa M, Bouhaimed M. Management of lipid exudates in Coats disease by adjuvant intravitreal triamcinolone: effects and complications. *Br J Ophthalmol.* 2010;94(5):606–610.
17. Dugel PU, Srivastava SK, Kaiser PK. Expanded 96-week safety outcomes from HAWK and HARRIER. *Presented at the 43rd Annual Macula Society Meeting.* February 2020.