



Original Research

Following the Anatomy of the Proximal Tibia With a Standard Anatomic Technique and the Use of an Asymmetrical Tibial Base Plate can Lead to a Mismatched Internal Components' Rotation in Mechanically Aligned Total Knee Arthroplasty

Matteo Innocenti, MD, Gregorio Secci, MD, Luigi Zanna, MD*, Giacomo Sani, MD, Davide Stimolo, MD, Fabrizio Matassi, MD, Christian Carulli, MD, Roberto Civinini, MD

Orthopaedic Clinic, University of Florence, Florence, Italy

ARTICLE INFO

Article history:

Received 11 November 2023

Received in revised form

1 May 2024

Accepted 9 June 2024

Keywords:

Total knee arthroplasty

Smart insert sensor

Tibial component rotation

Reciprocal femoro-tibial rotation

Combined femorotibial rotation

Mismatched femorotibial rotation

ABSTRACT

Background: Tibiofemoral components rotational congruency affects the total knee arthroplasty (TKA) success. The smart insert sensor (I-S) helps to establish tibial component rotation reciprocally to a fixed femoral rotation. We aimed (1) to validate the use of I-S as a possible tool to reach reproducible reciprocal femorotibial rotation (RftR) in TKA independently from anatomic landmarks, reducing outliers in combined and mismatched femorotibial rotation (CftR and MMftR, respectively) positioning and (2) to validate the "curve-on-curve" method for a specific type of asymmetrical tibial component.

Methods: From February 2018, we conducted a prospective case-control study including 106 patients undergoing TKA. Patients were divided into 2 groups based on the method used to establish tibial component rotation: with the I-S use (group A, n = 53) and with the standard "curve-on-curve" technique (group B, n = 53). Rotational alignment was calculated using the Berger protocol with post-operative computed tomography scanning. Alignment parameters measured were tibial and femoral component rotations (tR, fR), the CftR, the MMftR, and the RftR.

Results: Intraoperative rotation measured by I-S correlated the best with RftR ($r = 0.84$; $P < .001$) at the post-operative CT scanning. No significant differences were found between groups A and B regarding all types of rotation (fR: $P = .774$; tR: $P = .467$; CftR: $P = .847$) except for MMftR ($P = .036$) and RftR ($P = .023$). There were no outliers in group A but 27 and 12 outliers in group B for MMftR and CftR respectively ($P < .001$; $P = .032$).

Conclusions: The TKA components' rotation established using a smart I-S intraoperatively is ascribable to the RftR at postoperative computed tomography scan. The I-S helps reduce outliers in the CftR and MMftR. An asymmetrical tibial base plate implanted using the curve-on-curve technique does not create a neutral reciprocal femorotibial rotation significantly increasing the number of cases with mismatched femorotibial internal rotation.

© 2024 The Authors. Published by Elsevier Inc. on behalf of The American Association of Hip and Knee Surgeons. This is an open access article under the CC BY-NC-ND license (<http://creativecommons.org/licenses/by-nc-nd/4.0/>).

Introduction

Total knee arthroplasty (TKA) is one of the most common surgical procedures, due to the general aging population, a long-life expectancy, and high-demand performance in the elderly [1]. However,

despite a reported survival rate greater than 90% at 10 years [2,3] it is not a foolproof procedure, with about 20% of dissatisfied patients in terms of function and pain [4,5] and about 4%-13% of unexplained painful TKAs [6]. Prosthesis components' malrotation could be one of the causes of painful TKA. In particular, the tibial component internal rotation often leads to a combined femorotibial internal rotation and/or a combined mismatched femorotibial internal rotation [6,7]. Abdelnasser et al. [8] found that all types of component rotation malalignment significantly worsen early

* Corresponding author. Orthopaedic Clinic, University of Florence, Via Largo Palagi 1, Florence, Italy 50139. Tel.: +39 349 814 1620.

E-mail address: luigizanna90@gmail.com

Patient-Reported Outcomes Measures, while coronal and sagittal limb malalignment has no significant effects on early Patient-Reported Outcomes Measures. A correct tibial component rotation allows a balanced extensor apparatus function creating the optimal contact area between the patella and femur during the knee range of motion (ROM), minimizing the risk of patellofemoral pain [7].

Generally, if the aim is to reproduce a neutral mechanical alignment of the lower limb, the femoral rotational positioning is more guided by the standard instrumentation than the tibial positioning making it more reproducible intraoperatively with less margin of error degrees [9].

Therefore, considering the femur as having less variability in the axial plane, we should then argue about the definition of appropriate components' rotation and how the tibial component can be defined as properly rotated while performing a mechanically aligned TKA. Is it more important to set the tibial component rotation by fully matching the anatomy of the tibial plateau with asymmetrical components or to copy the tibial rotation on the femoral component rotation regardless of tibial anatomic landmarks thus avoiding conditions of incorrect combined or mismatched femorotibial rotation (CftR and MMftR, respectively) potentially causing incongruent knee kinematics during the ROM? There are no proven answers in literature to such questions yet. Traditionally the tibial component rotation can be guided by lots of different methods: the "curve-on-curve" (CoC) technique based on the anterior tibial contour [10,11], the "self-seeking method" [12,13], the "maximizing tibial coverage" [14], or anatomic landmarks such as the "Akagi" line [15], the posterolateral tibial corner and many others [11,16]. We introduced the use of a smart insert sensor (I-S) to establish the tibial component rotation reciprocally to a fixed femoral rotation achieved by a standard measured resection technique in order to copy the femoral rotation on the tibia avoiding potential components' rotational mismatch.

The aims of the study were (1) to validate the hypothesis that with the use of an I-S is possible to obtain a reproducible reciprocal femorotibial rotation (RftR) in TKA independently from tibial anatomic landmarks, reducing outliers in CftR and MMftR positioning; (2) to validate the CoC method for a specific type of asymmetrical tibial component.

Material and methods

From February 2018, we conducted a randomized controlled trial following 106 consecutive patients undergoing TKA. The inclusion criteria were the presence of a grade IV Kellgren-Lawrence primary knee osteoarthritis at standing radiograph and a neutrally aligned knee or a varus knee. The exclusion criteria were patient younger than 60 years of age, a varus deformity more than 15° on the coronal plane, the presence of a valgus knee, dementia, body mass index >35 , American Society of Anaesthesiologists of physical health >3 , history of knee or femur or tibia fractures, rheumatoid diseases, previous ligamentous reconstruction, previous mayor knee surgeries such as tibial tuberosity transposition, around the knee osteotomies, and so on.

All patients were treated at the same institution by 2 orthopaedic surgeons highly specialized in knee surgery. According to the study by Tanzer and Makhdom [17], a calibrated full-leg weight-bearing radiograph, a weight-bearing anterior-posterior view, a true lateral weight-bearing view, and a Laurin patellar view were taken for every patient. A digital planning aiming for an adjusted mechanical alignment was performed with the software TraumaCad, version 2.0, system (BrainLab, Feldkirchen, Germany) by 2 operators assuming the mean of the 2 analyses as the correct values in order to reduce the interobserver reliability. The same

cemented posterior stabilized prosthesis design was implanted in every case (Legion Primary Oxinium, Smith & Nephew, London, UK) and the patella was replaced in every case.

Surgical technique

Prophylactic antibiotics were given starting from 60 minutes before the incision (1 gram of vancomycin iv 60 minutes before surgery, and 2 grams cefazolin iv 15 minutes preoperatively).

The surgical procedures were conducted under spinal anesthesia, with the patient in supine decubitus. A standard longitudinal median knee approach and a medial parapatellar arthrotomy were performed. The distal femoral cut and the tibial cut were made following the principle of the measured resection technique using an intramedullary guide both for the femoral and the tibial cuts. The femoral rotation was set at 3° of external rotation in every case.

The axial tibial component positioning (tibial rotation positioning) method was achieved with 1 between 2 different techniques: in the "case group," group A (53 patients), it was established by the use of the I-S by coupling the tibial rotation with the femoral rotation aiming to rotate the tibial component between -3° and $+3^\circ$ compared to the femur (this method was figured as "Reciprocal Femorotibial Rotation Method"); in the "control group," group B (53 patients), it was established only by the use of the CoC technique independently from the femoral rotation positioning (this method was figured as "Tibial-Based Rotation Method"). The selection to be part of the case or control group was performed randomly at the moment of the tibial trial component positioning with a surgeon assistant "blinded" in the surgery room opening a sealed envelope containing the method to be used to establish the tibial component rotation. The I-S used was the VeraSense (OrthoSensor Inc., Dania Beach, FL, USA), a smart trial insert with a microprocessor and nanosensors that wirelessly transmits data in real-time to a portable graphic display. It measures and locates the load peaks at the medial and lateral femorotibial interface and the contact points of the medial and lateral compartment during the whole ROM. The display shows in real time the tensions of the medial and lateral compartments, the femorotibial tracking during the ROM, and the rotation of the tibial component relative to the femoral one by coupling the medial and lateral femorotibial contact points (Fig. 1). For each patient, we recorded the displayed rotation taken between 10° and 20° of flexion to potentially match the position of the knee during the

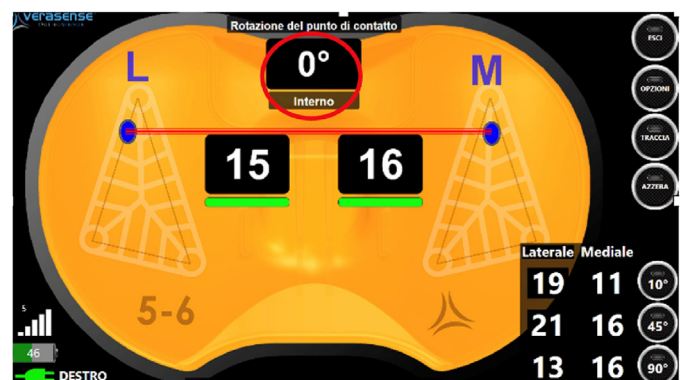


Figure 1. The screenshot of the portable VeraSense orthosensor display shows the rotation of the tibial component relative to the femoral one by connecting the medial and lateral femorotibial contact points of the medial and lateral compartments during the ROM. In this specific case, the rotation of the femorotibial contact points is 0° . ROM, range of motion.

postoperative computer tomography scan (CT scan) (see below the "Postoperative radiological evaluation").

Postoperative radiological evaluation

Two days after surgery, a rotational CT scan was taken to check the axial components' positioning. The knee was bent between 10° and 20° during the acquisition of the CT scan. The following angles were calculated by 2 independent observers:

- Femoral rotation (fR): angle formed between the surgical transepicondylar axis and posterior femoral condyle
- Tibial rotation (tR): angle formed between tibial component axis and the line between the geometric center of the tibial plateau and the tibial tubercle tip, according to the method followed in the study by Berger et al. [18].
- Combined femorotibial rotation (CftR): the result of the summation of femoral and tibial rotational angles (CftR = fR + (tR)).
- Mismatched femorotibial rotation (MMfR): the absolute value of the difference of femoral and tibial rotational angles (MMfR = |fR - (tR)|).
- Reciprocal femorotibial rotation (RftR): angle between the projected posterior femoral condyle on the tibial base plate and the posterior keel line (Fig. 2).

Internal rotation was expressed by negative values, while external rotation by positive values.

Radiological evaluations were performed by 2 knee-specialized orthopaedic surgeons who were blinded to the rotational method used and who were absent at the moment of both the surgery and randomization.

Statistics

The sample size was calculated with the Fisher formula considering a confidence interval (CI) of 95% with 5% of margin of maximum error. We used Cohen's d to calculate the effect size. All data were tested for normal distribution using the Kolmogorov–Smirnov test. The intraobserver and interobserver reliability on CT measurement was assessed using intraclass correlation coefficients with a 2-way mixed-effect model. Pearson's correlation coefficient was used in group A to find which CT scan rotational measurement correlated the best with the intraoperative

I-S measurement. A significance was accepted for *P* value of < .05. For each group, we calculated the median, first quartile (Q1), third quartile (Q3), interquartile range, and outliers. We defined the Tukey fences with the following formula: Q1-1.5·interquartile range and Q3+1.5·interquartile range. Then we identified as outliers all values located outside the 2 fences.

Results

We enrolled 106 patients, with a mean follow-up of 32 months (range: 24–38 months). Sixty-four patients were female (38 group A, 26 group B) and 42 (15 group A, 27 group B) were male. The mean age was 65 years (range: 60–78), with a mean group A age of 63 years and group B of 69 years. Comparing the intraoperatively rotational measurements showed by the I-S (mean + 2.0°; standard deviation ± 1.3) and the CT scan angles calculated postoperatively, we found that the I-S rotational values correlated the most with the RftR (RftR mean value 0.8°, standard deviation ± 1.3°; $r = 0.84$, $P < .001$). No significant differences were found between groups A and B regarding all types of rotation at the postoperative CT scan measurements (fR: $P = .774$; tR: $P = .467$; CftR: $P = .847$) except for the MMfR ($P = .036$) and RftR ($P = .023$) (Table 1). Interrater reliability of degrees of rotation was 0.93 (95% CI: 0.91–0.96) for CftR, 0.96 (95% CI 0.93–0.97) for MMfR, and 0.94 (95% CI: 0.91–0.97) for RftR. The intraclass correlation coefficient in between to observers for fR was 0.91 (95% CI: 0.88–0.94) and for tR was 0.92 (95% CI: 0.89–0.95).

There were no outliers in group A, but we found 27 and 12 outliers in group B for MMfR and CftR, respectively ($P < .001$; $P = .032$) (Fig. 3).

Discussion

The present study showed that the use of a smart I-S helps surgeons obtain a neutral reciprocal femorotibial components rotation performing a mechanically aligned TKA. We demonstrated that despite the use of an asymmetric tibial baseplate allows an anatomic coverage of the tibial plateau when the CoC technique is used it does not couple the tibial axial positioning with the femoral axial positioning creating a potential mismatch in the femorotibial rotation. This mismatch could eventually alter the knee kinematics during the ROM thus determining conditions like good-looking but painful TKAs or stiff knees [6,18]. Indeed, the internal rotation of the tibial component causes a compensatory extrarotation of the leg due to the coupling of the tibial and femoral components with an increase of the Q angle and important consequences on patellar tracking [9,19–21]. Similarly, in the case of external rotation of the tibial component, the internal rotation of the leg is increased with a reduction of the Q angle [22]. Modifying the native rotations between the femur and tibia changes the relative positions between the origins of the ligaments and their function as well as the tension of the capsule potentially resulting in postoperative pain. Modification of the knee kinematics could also contribute to premature wear and premature loosening of components [23,24]. Therefore, it appears clear that positioning the components with the right rotation is fundamental. This aspect has also been demonstrated to maintain the screw-home mechanism at the end of the extension and the femoral roll-back in the prosthetic knee [25].

Barrack and Burak [7] performed a rotational CT scan in 2 different groups, one with anterior knee pain and one pain-free after a primary TKA. The authors found that patients with a combined femorotibial component internal rotation were 5 times more likely to experience anterior knee pain after TKA. In particular, they reported a significant difference in combined component rotation with the patients with anterior knee pain averaging 4.7° internal

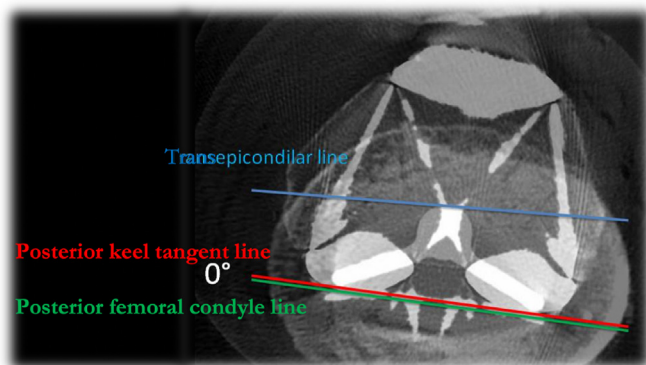


Figure 2. Superimposition of the axial CT femoral component slide where the surgical transepicondylar axis (TEA) and posterior femoral condyle (PFC) were taken, and the axial CT tibial component slide at the level of the posterior tibial component keel. The reciprocal femorotibial rotation (RftR) is defined as the angle between the projected PFC on the tibial base plate and the posterior keel line. In this specific case, the RftR is 0°. CT, computed tomography.

Table 1
Postoperative CT scan measurements.

Values	Femoral rotation		Tibial rotation		Combined FT rotation		Mismatched FT rotation		Reciprocal FT rotation	
	I-S	CoC	I-S	CoC	I-S	CoC	I-S	CoC	I-S	CoC
Average (range)	+2.0 (-1.4/+4)	+1.8 (-2.1/+4)	+2.0 (0/+4.2)	+6.8 (-8.2/+9.4)	+3.4 (-1.4/+7.8)	+2.0 (-7.9/+11.4)	-0.2 (-1.9/+1.3)	-6.0 (-10.4/+10.7)	+0.8 (-1.7/+3.8)	+2.5 (-7.2/+8.4)
± St.Dev	1.2	1.5	1.0	5.9	2.0	1.2	0.9	6.8	1.3	4.9
Test stat.	0.774		0.467		0.847		0.036		0.023	

+, external rotation; -, internal rotation; CoC, curve-on-curve group; CT, computer tomography; FT, femorotibial; I-S, insert sensor group; St.Dev, standard deviation; test stat., statistical *P* value.

rotation compared with 2.6° external rotation in the control group. The same case-control study was performed more recently by Bell et al. [6]. They confirmed that the combined femorotibial components' internal rotation correlates with pain after TKA. Moreover, they pointed out that an internal mismatched components' rotation can also worsen the outcomes.

Having said that, we should argue about what is the “right” axial components' positioning while performing a TKA with a mechanical alignment concept in order to avoid an internal combined or mis-matched components' rotation. However, in both the aforementioned studies what drove an internal combined or mismatched rotation was mostly an internally rotated tibial component. Various techniques have been described for establishing proper rotation of the femoral component resulting in a very small variability in the axial placement of the femoral component [19]. On the other hand, there is less consensus for determining the rotation of the tibial component. The main bony landmarks that can be used for the tibia are: the Akagi line with 9 variants [20], CoC technique [26], self-adapting technique [27], the transmalleolar axis of the ankle [28], the axis through second metatarsal bone [29], the axis through the first intermetatarsal space [29], the axis of the posterior tibial margin [30], mediolateral axis of the tibial plateau [31]. Nevertheless, only a few of those axes are currently used during the surgical procedure with variable results. In the systematic review made by Saffarini et al. [20] on CT scan, the best accuracy and repeatability of different axes for tibial baseplate rotation in TKA were found to be the original “Akagi line,” its variant using the sulcus of the tibial spines as anterior landmark, as well as the anterior tibial border and the CoC technique. The best

interobserver agreement was reported for “Akagi line” variants that use the geometric center of the tibial plateau posteriorly and the medial border of the tibial tuberosity, or the medial sixth of the patellar tendon anteriorly.

It must be taken into consideration that all articles were based on CT scan measurements, which may not represent the difficulties of visualizing and locating anatomic landmarks intraoperatively. Nowadays, there are a lot of assisting tools and new technologies with the aim to help the surgeon minimize mistakes in axial components' positioning. In a recent meta-analysis, Huijbregts et al. [32] compared tibial rotational positioning in patient-specific instrumentation (PSI) and conventional technique with CT or magnetic resonance imaging measurements. Of all the studies considered, only one reported better rotational positioning of the tibial component with PSI, so the authors concluded that PSI does not lead to improvement in component placement. Schmitt et al. [3] found that the numbers of rotational outliers were not significantly reduced by 2 navigation systems vs conventional surgery (9.1% and 21.7% vs 15.4%, *P* = .506). Matziolis et al. [33] showed that the rotational malalignment of the tibial component in the conventional surgery was 7.5° ± 6.0°; in navigated surgery, the tibial component showed a rotational malalignment of 6.9° ± 4.7° and the difference was not significant. In their series Hernandez-Vaquero et al. [5] compared component positioning in robot-assisted surgery (RAS) and conventional surgery with post-operative CT scan measurements. They found that in the entire patient population, the tibial rotation changed by 5.28° but no differences were found when comparing RAS and standard instrumentation surgery.

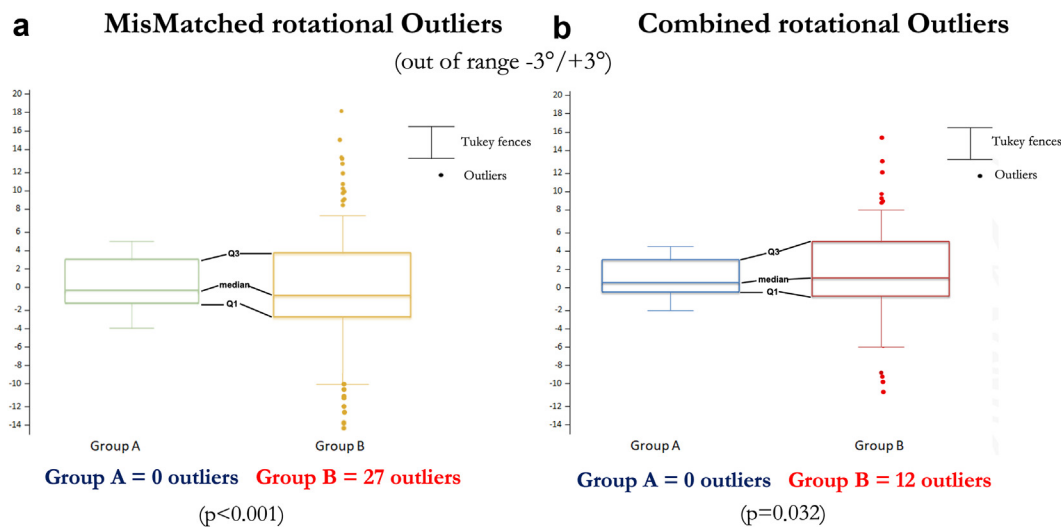


Figure 3. A. Boxplot of Mismatched rotational outliers in group A and group B. In group B there is a greater scatter of data, and there are 27 outliers. B. Boxplot of combined rotational Outliers in group A and group B. In group B there are 12 outliers.

However, the interpretation of these results must be taken with caution. In fact, all these studies using new technologies were based on the assumption of positioning the tibial component in relation to anatomic tibial landmarks, such as the Akagi line or the CoC technique, and so on. Those reports did not consider the fact that with the principle of mechanical alignment, the femur is not positioned anatomically, but usually with 3 degrees of external rotation. Therefore, by reproducing an anatomic rotation in the tibia even with asymmetrical components could collide with a femur that is not anatomically reproduced, thus leading to a rotational mismatch.

With our study, we demonstrated that following the anatomy of the proximal tibia with the standard CoC technique and the use of an asymmetrical tibial base plate can lead to a mismatched internal components' rotation in a group of TKA implanted with an adjusted mechanical alignment concept. At the same time, adding a smart I-S to set the tibial rotation coupling the rotation of the femur avoids an internal CftR or MMftR positioning. Moreover, the rotation values recorded intraoperatively with VeraSense Orthosensor significantly matched with what we have called RftR at the postoperative CT scan. This confirmed the fact that the I-S helps to position the tibial component in the axial plane by coping with the femoral component rotation achieving the goal of a neutral femorotibial rotational alignment independently from tibial anatomic landmarks and/or asymmetrical tibial base plates.

Therefore, by establishing a relative rotation of the tibial component compared to the femur of 0°, the tibial component position in the axial plane will be in line with the femoral component rotation. In our study, patients of group A had more reproducible rotations of the tibial components compared with group B. In group A we found no relative rotations of the tibial component both in internal and external rotation >5°, and no outliers. For the relative tibial rotation in group A, we had values of standard deviation smaller than that of group B (1.63 vs 7.44 $P < .05$). Group A showed much less variability in tibial rotation positioning than group B, and the difference was statistically significant. In recent studies, it has been found that PSI surgery contributes to the decrease of outliers due to rotation of the tibial component [34,35], but there is no unanimous consensus in the literature [32]. Regarding navigation and RAS, no significant reduction in outliers for tibial component rotation has been demonstrated [3,5,33].

With the present study, we demonstrated that with the principle of performing a mechanical alignment TKA respecting the anatomy of the tibia probably has less importance than with other types of coronal alignments because reciprocal alterations of the rotations between the femur and tibia are still created.

This study comes with some limitations. First, it has no comparable studies among the scientific literature, making our results difficult to compare with others; as mentioned previously, there are studies describing the axial placement of the tibial component with navigation, PSI or RAS, but the determination of the tibial component is based on bony landmarks. Second, in the control group, we did not place the tibial component with respect to the well know Akagi line as the majority of the studies show in the literature. We chose the CoC technique because of its interobserver reliability. Finally, we used a single-design prosthesis with a PS insert and an asymmetrical tibial baseplate without considering the potential influence of different implant prosthesis designs on rotational alignment. Nevertheless, there are no studies in the literature that show a significant superiority of one design over another in terms of clinical scores, ROM measures, radiographic evaluations, complication and revision rates [36–38]. The present randomized controlled trial just focused on a single prosthesis design to enhance the accuracy of measurements at the postoperative CT-scan in order to define a new method to calculate the

relationship between the femoral and tibial rotation at the postoperative axial CT scan.

Conclusions

The TKA components' rotation established using a smart I-S intraoperatively is ascribable to the RftR at postoperative CT scan. The smart I-S helps reduce the outliers in the CftR and MMftR when compared to the use of a standard technique. The use of an asymmetrical tibial base plate implanted using the CoC technique does not create a neutral reciprocal femorotibial rotation significantly increasing the number of cases with a potentially dangerous mismatched femorotibial internal rotation in mechanically aligned TKA.

Conflicts of interest

The authors declare there are no conflicts of interest.

For full disclosure statements refer to <https://doi.org/10.1016/j.artd.2024.101464>.

CRediT authorship contribution statement

Matteo Innocenti: Writing – review & editing, Writing – original draft, Methodology, Investigation, Data curation, Conceptualization. **Gregorio Secci:** Writing – original draft, Validation, Software, Resources, Methodology. **Luigi Zanna:** Writing – review & editing, Writing – original draft, Methodology, Formal analysis, Data curation. **Giacomo Sani:** Writing – original draft, Formal analysis, Data curation, Conceptualization. **Davide Stimolo:** Methodology, Investigation, Funding acquisition, Formal analysis, Data curation. **Fabrizio Matassi:** Writing – review & editing, Supervision, Investigation, Data curation, Conceptualization. **Christian Carulli:** Writing – review & editing, Validation, Supervision, Software. **Roberto Civinini:** Visualization, Validation, Supervision, Resources.

References

- [1] Gao J, Xing D, Dong S, Lin J. The primary total knee arthroplasty: a global analysis. *J Orthop Surg Res* 2020;15:190. <https://doi.org/10.1186/s13018-020-01707-5>.
- [2] Sharkey PF, Hozack WJ, Rothman RH, Shastri S, Jacoby SM. Why are total knee arthroplasties failing today? *Clin Orthop Relat Res* 2002;404:7–13. <https://doi.org/10.1097/00003086-200211000-00003>.
- [3] Schmitt J, Hauk C, Kienapfel H, Pfeiffer M, Efe T, Fuchs-Winkelmann S, et al. Navigation of total knee arthroplasty: rotation of components and clinical results in a prospectively randomized study. *BMC Musculoskelet Disord* 2011;12:16. <https://doi.org/10.1186/1471-2474-12-16>.
- [4] Bourne RB, Chesworth BM, Davis AM, Mahomed NN, Charron KDJ. Patient satisfaction after total knee arthroplasty: who is satisfied and who is not? *Clin Orthop Relat Res* 2010;468:57–63. <https://doi.org/10.1007/s11999-009-1119-9>.
- [5] Hernandez-Vaquero D, Noriega-Fernandez A, Fernandez-Carreira JM, Fernandez-Simon JM, Llorens De Los Rios J. Computer-assisted surgery improves rotational positioning of the femoral component but not the tibial component in total knee arthroplasty. *Knee Surg Sports Traumatol Arthrosc* 2014;22:3127–34. <https://doi.org/10.1007/s00167-014-3233-9>.
- [6] Bell SW, Young P, Drury C, Smith J, Anthony I, Jones B, et al. Component rotational alignment in unexplained painful primary total knee arthroplasty. *Knee* 2014;21:272–7. <https://doi.org/10.1016/j.knee.2012.09.011>.
- [7] Barrack RL, Burak C. Patella in total knee arthroplasty. *Clin Orthop Relat Res* 2001;389:62–73. <https://doi.org/10.1097/00003086-200108000-00011>.
- [8] Abdelnasser MK, Elsherif ME, Bakr H, Mahran M, Othman MHM, Khalifa Y. All types of component malrotation affect the early patient-reported outcome measures after total knee arthroplasty. *Knee Surg Relat Res* 2019;31:5. <https://doi.org/10.1186/s43019-019-0006-2>.
- [9] Bédard M, Vince KG, Redfern J, Collen SR. Internal rotation of the tibial component is frequent in stiff total knee arthroplasty. *Clin Orthop Relat Res* 2011;469:2346–55. <https://doi.org/10.1007/s11999-011-1889-8>.
- [10] Baldini A, Indelli PF, DE Luca L, Mariani PC, Marcucci M. Rotational alignment of the tibial component in total knee arthroplasty: the anterior tibial cortex is

- a reliable landmark. *Joints* 2013;1:155–60. <https://doi.org/10.11138/jjts/2013.1.4.1455>.
- [11] Indelli PF, Graceffa A, Marcucci M, Baldini A. Rotational alignment of the tibial component in total knee arthroplasty. *Ann Transl Med* 2016;4:3. <https://doi.org/10.3978/j.issn.2305-5839.2015.12.03>.
- [12] Lütznér J, Krummenauer F, Günther K-P, Kirschner S. Rotational alignment of the tibial component in total knee arthroplasty is better at the medial third of tibial tuberosity than at the medial border. *BMC Musculoskelet Disord* 2010;11:57. <https://doi.org/10.1186/1471-2474-11-57>.
- [13] Barrack RL, Schrader T, Bertot AJ, Wolfe MW, Myers L. Component rotation and anterior knee pain after total knee arthroplasty. *Clin Orthop Relat Res* 2001;392:46–55. <https://doi.org/10.1097/00003086-200111000-00006>.
- [14] Dai Y, Scuderi GR, Bischoff JE, Bertin K, Tarabichi S, Rajgopal A. Anatomic tibial component design can increase tibial coverage and rotational alignment accuracy: a comparison of six contemporary designs. *Knee Surg Sports Traumatol Arthrosc* 2014;22:2911–23. <https://doi.org/10.1007/s00167-014-3282-0>.
- [15] Akagi M, Oh M, Nonaka T, Tsujimoto H, Asano T, Hamanishi C. An anteroposterior axis of the tibia for total knee arthroplasty. *Clin Orthop Relat Res* 2004;213–9. <https://doi.org/10.1097/00003086-200403000-00030>.
- [16] Ozcelik A, Seber S, Omeroglu H. Bone anatomy and rotational alignment in total knee arthroplasty. *Clin Orthop Relat Res* 2004;270. author reply 270.
- [17] Tanzer M, Makhdom AM. Preoperative planning in primary total knee arthroplasty. *J Am Acad Orthop Surg* 2016;24:220–30. <https://doi.org/10.5435/JAAOS-D-14-00332>.
- [18] Berger RA, Crosse LS, Jacobs JJ, Rubash HE. Malrotation causing patellofemoral complications after total knee arthroplasty. *Clin Orthop Relat Res* 1998;356:144–53. <https://doi.org/10.1097/00003086-199811000-00021>.
- [19] Olcott CW, Scott RD. A comparison of 4 intraoperative methods to determine femoral component rotation during total knee arthroplasty. *J Arthroplasty* 2000;15:22–6. [https://doi.org/10.1016/S0883-5403\(00\)91051-9](https://doi.org/10.1016/S0883-5403(00)91051-9).
- [20] Saffarini M, Nover L, Tandogan R, Becker R, Moser LB, Hirschmann MT, et al. The original Akagi line is the most reliable: a systematic review of landmarks for rotational alignment of the tibial component in TKA. *Knee Surg Sports Traumatol Arthrosc* 2019;27:1018–27. <https://doi.org/10.1007/s00167-018-5131-z>.
- [21] Panni AS, Ascione F, Rossini M, Braile A, Corona K, Vasso M, et al. Tibial internal rotation negatively affects clinical outcomes in total knee arthroplasty: a systematic review. *Knee Surg Sports Traumatol Arthrosc* 2018;26:1636–44. <https://doi.org/10.1007/s00167-017-4823-0>.
- [22] Maderbacher G, Baier C, Springorum H-R, Maderbacher H, Birkenbach A-M, Benditz A, et al. Impact of axial component alignment in total knee arthroplasty on lower limb rotational alignment: an in vitro study. *J Knee Surg* 2017;30:372–7. <https://doi.org/10.1055/s-0036-1592148>.
- [23] Kessler O, Lacatusu E, Sommers MB, Mayr E, Bottlang M. Malrotation in total knee arthroplasty: effect on tibial cortex strain captured by laser-based strain acquisition. *Clin Biomech* 2006;21:603–9. <https://doi.org/10.1016/j.clinbiomech.2006.01.011>.
- [24] Dye SF. The knee as a biologic transmission with an envelope of function: a theory. *Clin Orthop Relat Res* 1996;325:10–8. <https://doi.org/10.1097/00003086-199604000-00003>.
- [25] Kim JJ, Jang J, Lee KW, Han HS, Lee S, Lee MC. Anterior tibial curved cortex is a reliable landmark for tibial rotational alignment in total knee arthroplasty. *BMC Musculoskelet Disord* 2017;18:252. <https://doi.org/10.1186/s12891-017-1609-y>.
- [26] Indelli PF, Graceffa A, Baldini A, Payne B, Pipino G, Marcucci M. Relationship between tibial baseplate design and rotational alignment landmarks in primary total knee arthroplasty. *Arthritis* 2015;2015:1–8. <https://doi.org/10.1155/2015/189294>.
- [27] Cho Y, Lee MC. Rotational alignment in total knee arthroplasty. *Asia Pac J Sports Med Arthrosc Rehabil Technol* 2014;1:113–8. <https://doi.org/10.1016/j.asmart.2014.08.001>.
- [28] Page SR, Deakin AH, Payne AP, Picard F. Reliability of frames of reference used for tibial component rotation in total knee arthroplasty. *Comput Aided Surg* 2011;16:86–92. <https://doi.org/10.3109/10929088.2011.552252>.
- [29] Yoshioka Y, Siu DW, Scudamore RA, Cooke TD. Tibial anatomy and functional axes. *J Orthop Res* 1989;7:132–7. <https://doi.org/10.1002/jor.1100070118>.
- [30] Bonnin MP, Saffarini M, Mercier P-E, Laurent J-R, Carrillon Y. Is the anterior tibial tuberosity a reliable rotational landmark for the tibial component in total knee arthroplasty? *J Arthroplasty* 2011;26:260–267.e2. <https://doi.org/10.1016/j.arth.2010.03.015>.
- [31] Graw BP, Harris AH, Tripuraneni KR, Giori NJ. Rotational references for total knee arthroplasty tibial components change with level of resection. *Clin Orthop Relat Res* 2010;468:2734–8. <https://doi.org/10.1007/s11999-010-1330-8>.
- [32] Huijbregts HJTAM, Khan RJK, Sorensen E, Fick DP, Haebich S. Patient-specific instrumentation does not improve radiographic alignment or clinical outcomes after total knee arthroplasty: a meta-analysis. *Acta Orthop* 2016;87:386–94. <https://doi.org/10.1080/17453674.2016.1193799>.
- [33] Matziolis G, Krockner D, Weiss U, Tohtz S, Perka C. A prospective, randomized study of computer-assisted and conventional total knee arthroplasty: three-dimensional evaluation of implant alignment and rotation. *J Bone Joint Surg Am* 2007;89:236–43. <https://doi.org/10.2106/JBJS.F.00386>.
- [34] Heyse TJ, Tibesku CO. Improved tibial component rotation in TKA using patient-specific instrumentation. *Arch Orthop Trauma Surg* 2015;135:697–701. <https://doi.org/10.1007/s00402-015-2157-2>.
- [35] Heyse TJ, Tibesku CO. Improved femoral component rotation in TKA using patient-specific instrumentation. *Knee* 2014;21:268–71. <https://doi.org/10.1016/j.knee.2012.10.009>.
- [36] Innocenti M, Zanna L, Akkaya M, Huber K, Christen B, Calliess T. Setting the tibial component rotation based on femoral landmarks allows congruent knee kinematics in robotic-assisted medial unicompartmental knee replacement. *J Pers Med* 2023;13:632. <https://doi.org/10.3390/jpm13040632>.
- [37] Moskal JT, Capps SG. Rotating-platform TKA No different from fixed-bearing TKA regarding survivorship or performance: a meta-analysis. *Clin Orthop Relat Res* 2014;472:2185–93. <https://doi.org/10.1007/s11999-014-3539-4>.
- [38] Smith TO, Ejtehadi F, Nichols R, Davies L, Donell ST, Hing CB. Clinical and radiological outcomes of fixed- versus mobile-bearing total knee replacement: a meta-analysis. *Knee Surg Sports Traumatol Arthrosc* 2010;18:325–40. <https://doi.org/10.1007/s00167-009-0909-7>.